

Megaoesophagus in the upper cervical oesophagus in a steer: a case report

G. JALILZADEH-AMIN, S. HASHEMIASL

Faculty of Veterinary Medicine, Urmia University, Urmia, Iran

ABSTRACT: Acquired megaoesophagus was diagnosed in a seven-month-old Holstein steer. Clinical signs included salivation, mild recurrent bloat, dysphagia or regurgitation of ingesta after swallowing and coughing lasting three days. Endoscopic examination revealed mild rhinitis and pharyngitis. Positive contrast radiography of the oesophagus outlined dilatation in the cervical oesophagus without evidence of obstruction. Treatment consisted of feeding management, oral electrolytes, intravenous fluids, and systemic antimicrobial therapy. Clinical signs of megaoesophagus resolved gradually after prolonged antimicrobial therapy and supportive care. However, the steer persisted with episodes of regurgitation and coughing. In conclusion, oesophagitis may have been the principle cause of megaoesophagus in this case but this could not be confirmed because a postmortem examination was not performed.

Keywords: megaoesophagus; oesophagitis; cattle; bloat; regurgitation

Megaoesophagus is a pathological dilatation and atony of the body of the oesophagus usually associated with asynchronous function of the oesophagus and the caudal oesophageal sphincter. There are a limited number of reports in the literature regarding this ailment in ruminants. Megaoesophagus is usually a congenital condition although the acquired condition has also been reported (Smith 2009). Functional or morphologic defects due to systemic diseases are the underlying cause of acquired megaoesophagus. The dilated oesophagus is dysfunctional and filled with saliva, feed and water. This results in regurgitation and may lead to aspiration pneumonia (Smith 2009).

The condition occurs sporadically and is uncommon in adult cattle (Alexander 1964; Verschooten and Oyaert 1977; Anderson et al. 1984; Ndikuwera et al. 1990), calves (Vestweber et al. 1985; Ulutas et al. 2006) sheep (Braun et al. 1990), goats (Parish et al. 1996), dogs (Holland et al. 1996), llamas (Watrous et al. 1995) and in horses (Murray et al. 1988). Mild oesophagitis, pharyngeal trauma, chronic partial obstruction (Morgan 1965; Singh and Migam 1980), mucosal ulceration (Singh and Migam 1980), strictures (Alexander 1964; Thrall and Brown 1971),

perioesophageal lesions (Verschooten and Oyaert 1977; Singh and Migam 1980,) and diverticulum (Verschooten and Oyaert 1977; Singh and Migam 1980) have all been associated with megaoesophagus.

This case report describes the clinical and radiographical features of megaoesophagus in the cranial cervical region of a steer.

Case description

History and clinical findings. A seven-month-old Holstein steer was referred to the Clinic of the Faculty of Veterinary Medicine of Urmia University with a history of salivation, mild recurrent bloat, diarrhoea, dysphagia and coughing lasting three days. The regurgitation occurred within several minutes of feeding. The ration had been a mixture of pasture forage and concentrate. The steer had a rectal temperature of 39.6 °C (reference range: 38–39 °C), a heart rate of 100/min (reference range: 60–80/min), a respiratory rate of 36/min (reference range: 10–30/min) and was in good condition, but slightly dehydrated. The level of dehydration was estimated to be 5%.

doi: 10.17221/7925-VETMED

Abnormal swelling was not present or palpable along the left jugular groove. There was no visual evidence of inflation of the oesophagus associated with each cycle of eructation. Resistance was not encountered to passage of a stomach tube into the rumen although accumulated gas was removed from the rumen to relieve clinical signs of bloat. Both nostrils were covered with dark, dried discharge due to frequent regurgitation. Examination of rumen fluid indicated moderate inactivation of forestomach flora and fauna. The parasitological examination of faeces revealed a few oocytes of coccidia and *Haemonchus contortus*, *Ostertagia ostertagi*, *Nematodiurs* and *Cooperia* sp. nematode eggs. No abnormalities were heard during auscultation of the trachea, heart or lungs. Pulmonary abnormalities compatible with clinical signs of bronchopneumonia were not observed. The steer's drinking and eating behaviour was normal, however, after swallowing there were episodes of head and neck extension, and rapid chewing motions of the jaw with passive regurgitation of ingesta and water as well as coughing from the mouth. A neurologic examination was performed but no abnormalities were detected involving the cranial nerves, peripheral nerves, or CNS.

Diagnostic results and treatment. Haematology and plasma biochemistry performed upon admission disclosed PCV (38%; reference range, 24–46%) and total protein concentration (9.1 g/dl; reference range, 6.6–7.8 g/dl). Leukocytosis (WBC: 15 000 μ l) with a marked neutrophilia (9000/ μ l), increased blood fibrinogen concentration (850 mg/dl) and hyperproteinaemia (91 g/l) was recorded on the haemogram. Serum chemistry showed elevated plasma sorbital dehydrogenase (22.4 IU/l) and

alkaline phosphatase (794 IU/l) concentrations. Ketonuria was not detected.

Endoscopic examination of the upper airway and oral cavity revealed a mild rhinitis and pharyngitis. There was a frothy mixture of mucus and feed material within the nasopharynx and an abnormal upper oesophagus. Approximately 40 cm of the mucosal surface of the upper cervical oesophagus was dilated with no mucosal folds visualised. No stricture, stenosis, or foreign body could be found associated with the oesophagus. The only lesions detected were discoloration and the presence of fibrinous deposits of the oesophageal mucosa.

Positive contrast radiography of the cervical oesophagus was taken in standing lateral position by a portable X-ray unit (Mobile Drive AR 30, Model TM8105, Smam X-Ray Equipment, Muggio Lombardy, Milan 20053, Italy) and oral administration of 500 ml barium sulphate in 30% suspension (Barex, Darou Pakhsh Pharmaceutical Mfg. Co. Tehran, Iran). Barium study outlined regional dilatation of the cervical oesophagus (Figure 1). A diagnosis of oesophageal dilatation or megaesophagus was made.

Treatment of the megaesophagus consisted of frequent small daily feedings of corn silage and a commercial dairy ration, limited ingestion of long stem hay, and systemic antimicrobials. Oral electrolytes and twelve litres of Ringer's solution were administered intravenously to overcome dehydration.

After ten days a slight improvement was observed but the steer continued to have episodes of regurgitation and coughing. Eventually, the medical treatment was not effective and the animal died after one month with protrusion of bones of the shoulders, ribs, back-bone and hips, sunken eyes

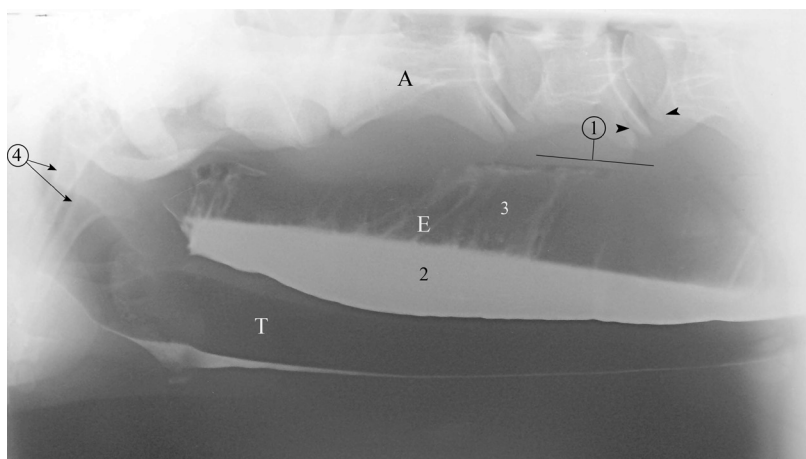


Figure 1. Dilatation of the oesophagus with barium and air proximal to the thoracic inlet. Note the pooling of barium lining the floor of the trachea and oesophagus. The oesophagus is dilated caudal to the pharynx. A = axis; T = trachea; E = oesophagus; 1 = proximal margin of the oesophagus; 2 = barium remaining in the oesophagus; 3 = air-filled oesophagus; 4 = stylohyoid bones; arrowhead, growth plates of C3 and C4 endplates

and tucked-up abdomen. The owner of the animal did not allow necropsy.

DISCUSSION AND CONCLUSIONS

The esophagus has four layers: mucosa, submucosa, muscular layers and adventitia. Oesophageal muscles, both striated and smooth, are innervated by the vagus nerve (Konig et al. 2004). The mucosa has prominent longitudinal folds that permit considerable cross-sectional dilation of the lumen to accommodate the passage of a bolus of food. These folds can be visualised with contrast radiography and endoscopy.

The aetiology of megaesophagus has been reported secondary to pharyngeal trauma and motility dysfunction of the oesophagus leading to oesophageal dilation (Blikslager and Jones 2009). Megaesophagus occurs sporadically in animals and rarely in ruminants. Pharyngeal trauma and secondary inflammatory injuries of the vagus have been reported in some cases in association with megaesophagus (Smith 2009). Dysfunction in the afferent structure of the reflex arc (receptors, neurons) of the swallowing reflex can lead to oesophageal paralysis. In such circumstances megaesophagus will have neuromuscular origin and indirect clinical signs of aspiration pneumonia (aspiration of contrast material) support a neural defect of the swallowing reflex (Holland et al. 1996). The principal clinical signs of megaesophagus are regurgitation, usually shortly after eating, with mild recurrent bloat (Smith 2009).

The differential diagnosis of regurgitation of partly chewed feed includes mandibular fractures, dental disease, listeriosis, botulism, brain stem abscess and other disorders that lead to quidding. These disorders were ruled out by careful observation and examination. The initial step in the definitive diagnosis of the site of swallowing dysfunction should include a careful observation of the animal's eating behaviour. In the steer reported here, the variable and prolonged interval between deglutition of ingesta and regurgitation suggested an oesophageal disorder. Previously reported cases of oesophageal dilatation and regurgitation in mature cattle appeared to have a neuromuscular basis in the dilated local region, flaccid appearance of the oesophagus and the endoscopic and radiographic evidence of mucosal ulceration, inflammation, stricture, diverticulum, and foreign body obstruction within the lumen of the oesophagus (Morgan 1965; Verschooten and Oyaert

1977; Singh and Migam 1980). The steer in this report exhibited endoscopic evidence of oesophagitis that may have contributed to megaesophagus. However, this could not be confirmed because the owner did not allow a necropsy.

In our case, a stenosis due to compression, a stricture, or any obstacle in the oesophageal lumen was not established. Therefore a myoneural disturbance was the suspected cause of the oesophageal dilation. The severe signs of inflammation caused by local irritation may have been responsible for this disturbance. This is supported by the report of Braun et al. (2014) who described abnormal regurgitation because of a perioesophageal abscess and inflammatory condition in three Brown Swiss cows. Supportive treatments and stomach tubing with fluids should be provided for one to two weeks until the animal is able to drink unaided. Longer-term support can be given to a valuable animal by surgically creating a ruminal fistula fitted with a rubber cannula through which feed and water can be given until normal deglutition is resumed. In cases with pharyngeal trauma history, a good prognosis is can be predicted, but megaesophagus associated with diaphragmatic hernia has a more guarded prognosis (Smith 2009).

In the steer described here the segmental nature of the oesophageal dilatation and the improvement in systemic and clinical conditions with time closely resembles the clinical features of a disease condition of the young dog referred to as idiopathic megaesophagus with unknown pathogenesis (Holland et al. 1996). Ruminants have the same type of oesophageal musculature as the dog. It was suggested that a group of neurons involved in the swallowing reflex may be affected by a toxic agent or inflammatory process. Therefore, improvement in eating ability may be due to repair of damaged tissue. In young dogs, improvement was observed due to maturation of oesophageal innervation. Oesophageal dilatation of neuromuscular origin seems to be a rare incident in cattle but it should be considered as a possible cause of dysphagia and regurgitation (Holland et al. 1996). While there are a few reports about acquired segmental megaesophagus in cattle (Anderson et al. 1984; Vestweber et al. 1985; Ross and Rebhun 1986), there has been only one reported case of an idiopathic dilation of the oesophagus in a heifer (Ndikuwera et al. 1990). The differentiation of congenital and acquired megaesophagus can be difficult, as similar defects may develop (Ulutas et al. 2006).

doi: 10.17221/7925-VETMED

According to the endoscopic findings of discoloration and fibrinous deposits detected during endoscopy, acquired megaesophagus was suspected. Moreover, megaesophagus can be a congenital condition and because of a lack of complete historical information and a post-mortem examination, such a scenario could not be ruled out in this case. Indeed, based on the age of this animal, a congenital origin should be considered. Consequently, oesophageal erosions may be secondary to chronic regurgitation and not the primary cause of the megaesophagus. Based on our findings we cannot confirm the cause of megaesophagus in this case but we suspect this abnormality was either congenital, idiopathic or due to acquired oesophagitis.

Acknowledgment

The authors wish to thank Dr. R. Mohammadi (Faculty of Veterinary Medicine, Urmia University, Urmia, Iran) for revising the manuscript.

REFERENCES

- Alexander JE (1964): Esophageal stricture in a heifer. *Journal of American Veterinary Medical Association* 145, 699–700.
- Anderson NV, Vestweber JG, Voisin AJ, Mills LJ (1984): Hiatal hernia and segmental megaesophagus in a cow. *Journal of American Veterinary Medical Association* 184, 193–195.
- Blikslager AT, Jones SL (2009): Disorders of the esophagus. In: Smith BP (eds.): *Large Animal Internal Medicine*. 4th ed. Mosby-Elsevier, St. Louis. 688–692.
- Braun U, Steiger R, Fluckiger M, Bearth G, Guscetti F (1990): Regurgitation due to megaesophagus in a ram. *Canadian Veterinary Journal* 31, 391–392.
- Braun U, Schwarzwald C, Ohlerth S, Frei S, Hilbe M (2014): Abnormal regurgitation in three cows caused by intrathoracic perioesophageal lesions. *Acta Veterinaria Scandinavica* 56, 14
- Holland CT, Satchell PM, Farrow BR (1996): Vagal esophagomotor nerve function and esophageal motor performance in dogs with congenital idiopathic megaesophagus. *American Journal of Veterinary Research* 57, 906–913.
- Konig HE, Sautet J, Liebich HG (2004): Digestive system (apparatus digestorius). In: Konig HE, Liebich HG (eds.): *Veterinary Anatomy of Domestic Mammals: Textbook and Colour Atlas*. Schattauer GmbH, Holderiinstra, Germany. 302–303.
- Morgan JP (1965): Esophageal obstruction and dilatation in a cow. *Journal of American Veterinary Medical Association* 147, 411–412.
- Murray MJ, Ball MM, Parker GA (1988): Megaesophagus and aspiration pneumonia secondary to gastric ulceration in a foal. *Journal of American Veterinary Medical Association* 192, 381–383.
- Ndikuwera J, Odiawo GO, Usenik EA (1990): Idiopathic megaesophagus in a pregnant heifer. *Veterinary Record* 126, 165–166.
- Parish SM, Middleton JR, Baldwin TJ (1996): Clinical megaesophagus in a goat with thymoma. *Veterinary Record* 139, 94.
- Ross CE, Rebhun WC (1986): Megaesophagus in a cow. *Journal of American Veterinary Medical Association* 188, 623–624.
- Singh AP, Migam JM (1980): Radiography of bovine esophageal disorders. *Modern Veterinary Practice* 61, 867–869.
- Smith BP (2009): Esophageal dilation (megaesophagus) and hiatal hernia. In: Smith BP (ed.): *Large Animal Internal Medicine*. 4th ed. Mosby-Elsevier, St. Louis. 805.
- Thrall DE, Brown MD (1971): Esophageal stenosis and diverticulum in a calf. *Journal of American Veterinary Medical Association* 159, 1040–1042.
- Ulutas B, Sarieler M, Bayramli G, Ocal K (2006): Macroscopic findings of idiopathic congenital megaesophagus in a calf. *Veterinary Record* 158, 26.
- Verschooten F, Oyaert W (1977): Radiologic diagnosis of esophageal disorders in the bovine. *Journal of American Veterinary Radiology Society* 18, 85–89.
- Vestweber JG, Leipold HW, Knighton RG (1985): Idiopathic megaesophagus in a calf: clinical and pathologic features. *Journal of American Veterinary Medical Association* 187, 1369–1370.
- Watrous, BJ, Pearson EG, Smith BB, Snyder SP, Blythe LL, Riebold TW, Hedstrom OR (1995): Megaesophagus in 15 Llamas: A Retrospective Study (1985–1993). *Journal of Veterinary Internal Medicine* 9, 92–99.

Received: 2014–07–06

Accepted after corrections: 2014–12–08

Corresponding Author:

Ghader Jalilzadeh-Amin, Urmia University, Faculty of Veterinary Medicine, Department of Internal Medicine and Clinical Prathology, P.O. Box 57155/1177, Urmia University, Urmia, Iran; E-mail: g.jalilzadeh@urmia.ac.ir