

CASE REPORT

[Previous Article](#) [ToC](#) [Next Article](#)

Search

SEARCH

Year : 2006 | Volume : 40 | Issue : 1 | Page : 57

Calcific tendinitis : An infrequent and misdiagnosed cause of acute wrist pain - A case report

N Hulse, A Kumar

Department of Trauma and Orthopaedics, Manchester Royal Infirmary, Manchester, United Kingdom

Click [here](#) for **correspondence address** and email







How to cite this article:

Hulse N, Kumar A. Calcific tendinitis : An infrequent and misdiagnosed cause of acute wrist pain - A case report. Indian J Orthop 2006;40:57

How to cite this URL:

Hulse N, Kumar A. Calcific tendinitis : An infrequent and misdiagnosed cause of acute wrist pain - A case report. Indian J Orthop [serial online] 2006 [cited 2008 Nov 25];40:57. Available from: <http://www.ijoonline.com/text.asp?2006/40/1/57/34437>

Introduction

Acute calcific tendinitis in the shoulder joint is a wellknown clinical condition. This condition has been reported around the wrist joint and in the hand with the tendon of the flexor carpi ulnaris being the commonest site ^[1]. We present a case of acute calcific tendinitis of the flexor carpi ulnaris tendon at the wrist joint.

Case report

A 68-year old retired right-handed teacher presented to the accident and emergency department with sudden onset of pain, swelling and redness in the left wrist. There was no previous history of wrist pain or involvement of any other joint. There was no history trauma or any significant medical problems in past. On physical examination, the patient was pyrexial with a temperature of 37.5 degrees. The left wrist was swollen, erythematous and warm. There was local tenderness mainly around the ulnar side of the wrist. The wrist movements were painful and restricted. The radiographs of the wrist joint did not

Similar in PUBMED

Search Pubmed for

- Hulse N
- Kumar A

Email Alert *

Add to My List *

* Registration required (free)

Introduction

Case report

Discussion

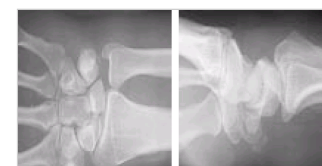References

Article Figures

Article Access Statistics

Viewed	1779
Printed	8
Emailed	0
PDF Downloaded	51
Comments	[Add]

Figures and Tables



show any obvious bone or joint pathology. Clinically, the patient was suspected to have septic arthritis of the wrist joint.

Radiographs of the wrist showed calcific deposit on the volar aspect of the wrist near the pisiform bone [Figure - 1]. Blood investigations showed mildly elevated inflammatory markers with a WBC count of $11.5 \times 10^9/L$, ESR 36 and CRP 48mg/L. On the basis of radiographic findings and blood results, the patient was treated for calcific tendinitis of the flexor carpi ulnaris tendon with a wrist splint and anti-inflammatory agents. The patient responded to the treatment with complete resolution of symptoms in 48 hours. At two months follow up, the patient was completely asymptomatic.



Discussion

The patient usually presents with acute symptoms of pain, swelling, restricted movements around the affected joint and may be afebrile or run a low-grade temperature. This condition can be easily confused with septic arthritis [2],[3], which is more likely to happen if calcific tendinitis occurs at an uncommon site leading to unnecessary investigations, treatment and delay in diagnosis [4]. Unlike in septic arthritis inflammatory markers may be normal or only slightly elevated. Radiologically, calcific tendinitis appears as amorphous deposits with irregular margins and absent bony trabeculations, which can be mistaken for an avulsion fracture, sesamoid bone, bony ossicle, gout and arthritis.

The natural history of calcific tendinitis is that of a self-limited condition. Patients are usually treated symptomatically although aspiration of deposits and local injection of anaesthetic with or without steroid are other suggested remedies. Calcific tendinitis should be one of the differential diagnoses in patients presenting with acute symptoms around the wrist joint.

References

1. Dille DF, Tonkin MA. Acute calcific tendinitis in the hand and wrist. *J Hand Surg (Br)*. 1991; 16: 215-6. [↑](#)
2. Selby CL. Acute calcific tendinitis of the hand: an infrequently recognized and frequently misdiagnosed form of peri-arthritis. *Arthritis Rheum*. 1984; 27: 337-40. [↑](#)
3. Shaw JA. Acute calcific tendonitis in the hand. *Orthop Rev*. 1986; 15: 482-5. [↑](#)
4. Moyer RA, Bush DC, Harrington TM. Acute calcific tendinitis of the hand and wrist: a report of 12 cases and a review of the literature. *J Rheumatol*. 1989; 16: 198-202. [↑](#)

Correspondence Address:

A Kumar
170, Woodhouse Lane, Sale, Cheshire, M33 4LN
United Kingdom

Login to access the email ID

Source of Support: None, Conflict of Interest: None

Figures


[Figure - 1]

 [Download Article \(pdf\)](#)

 [Email Article](#)

 [Print Article](#)

 [Read / Write a Comment](#)

 [Citation Manager](#)

[◀ Previous Article](#) [Next Article ▶](#)

[Contact us](#) | [Sitemap](#) | [Advertise](#) | [What's New](#) | [Feedback](#) | [Copyright and Disclaimer](#)

© 2006 - Indian Journal of Orthopaedics | A journal by [Medknow](#)

Online since 9th November, 2006