

TUMOUR

[Previous Article](#) [ToC](#) [Next Article](#)

Year : 2006 | Volume : 40 | Issue : 2 | Page : 115-118

Claviclectomy for bone tumors

Mayilvahanan Natarajan¹, I Meller², MM Malawer³

¹ Madras Medical College & Government General Hospital, Chennai, India,

² Director, National Unit of Orthopaedic Oncology, Sourasky Medical Centre, Tel-Aviv, Israel,

³ Director, Orthopaedic Oncology, Washington Hospital Centre, Washington, USA,

Click [here](#) for **correspondence address** and email







Abstract

Background: Total or partial excision of the clavicle has been advocated for many neoplastic and non neoplastic conditions. But the functional outcome after claviclectomy for tumours, has not been clearly described. By this study, we aim to analyze the oncological and functional outcome after claviclectomy for tumours of the clavicle.

Methods: Between 1991 and 1998, twelve patients underwent claviclectomy for various tumours. Histopathologically, Ewing's sarcoma was the commonest. These patients were followed up for a variable period ranging from 2 to 9 years with a mean follow up of 4.9 years.

Results: Functional results were analyzed using AMSTS scoring system. Functional outcome was excellent in 5 cases and good in 7 cases. Two patients of Ewing's sarcoma died of disease and the rest were continuously disease - free at their latest follow up.

Conclusion: Partial or total claviclectomy can be successfully employed for bone tumours with good oncological and functional results. A new classification system for claviclectomy is reported, based on the extent of resection

Keywords: Clavicular tumours; Resections; Classification; Outcomes.

How to cite this article:
Natarajan M, Meller I, Malawer MM. Claviclectomy for bone tumors. Indian J Orthop 2006;40:115-8

How to cite this URL:
Natarajan M, Meller I, Malawer MM. Claviclectomy for bone tumors. Indian J Orthop [serial online] 2006 [cited 2008 Nov 25];40:115-8. Available from: <http://www.ijoonline.com/text.asp?2006/40/2/115/34454>

Search

SEARCH

Similar in PUBMED

Search Pubmed for

- Natarajan M
- Meller I
- Malawer MM

Email Alert *

Add to My List *

* Registration required (free)

Abstract

Introduction

Materials and Me...

Results

Discussion

References

Article Figures

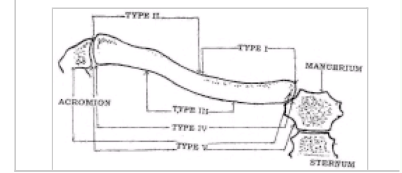
Article Tables

Article Access Statistics

Viewed	2293
Printed	13
Emailed	1
PDF Downloaded	50
Comments	[Add]



Figures and Tables



Recommend
this journal
for your library



Clavicle is the bone, which connects the upper limb to the axial skeleton. Gurd^[1] described the clavicle as a surplus part of the skeleton. No significant defect in the shoulder function has been described following clavicular resections^{[2],[3]}. Hence it is considered as an accessory baggage of the skeleton^{[2],[4]}. Still the following few functions can be assigned to this bone: (a) it provides bony protection to the brachial neurovascular bundle. (b) it provides bony attachment for many muscles of the shoulder girdle. (c) it acts as a strut to maintain the distance between the shoulder joint and the sternum. This enables rhythmic, arcuate motion of the shoulder joint without which the shoulder movements are more linear than arcuate^{[4],[5]}. (d) it transmits supporting force of the trapezius muscle to the scapula through coracoacromial ligaments^[6]. Hence if trapezius muscle is paralysed or damaged, claviculectomy may produce poor cosmetic and functional results^[6]. (e) it serves a cosmetic function by providing a graceful curve to the base of the neck^[4].

Abbott and Lucas^[2] have demonstrated that there was no functional deficiency after claviculectomy. Srivastava^[7] et al in a series of patients aged from 6 years to 22 years with osteomyelitis have noted no abnormality in the shoulder function following claviculectomy.

Spar^[8] has described total claviculectomy for 2 cases of pathological fractures. He noted complete relief of pain but persistence of mild weakness of the extremity. Lewis et al described 4 cases of en bloc claviculectomy, operative procedure and post-operative testing of functions^[9]. This study confirmed that claviculectomy did not impair the normal activity of daily living. But mechanical testing revealed some weakness in shoulder abduction, flexion and adduction, but not in internal rotation or extension. In most of the studies, post-claviculectomy functional status of the shoulder was good to excellent.

Claviculectomy has been indicated in tumour and tumour like lesion^[10], infection^[7], pathological fractures, non unions, severely comminuted fractures^[8], surgical exposure of the neurovascular structures^[11] and an adjunct to surgical collapse of the chest wall^[12].

We describe the results of 12 cases of clavicular tumors treated by claviculectomy with a review of the literature and a new classification for clavicular resections.

Materials and Methods

Between 1991 and 1998, twelve patients underwent claviculectomy for various tumors. Age of the patients ranged from 4 years to 70 years. Eight patients were females and 4 were males. Histopathological diagnosis was Ewing's sarcoma in six patients, aneurysmal bone cyst in three, chondroma in one, adeno-carcinoma of unknown primary in one and post-irradiation sarcoma in one patient [Table - 1].

Swelling with or without pain was the commonest presentation. Anatomical location of the tumor was medial third of the clavicle in four patients, shaft in five, lateral third in two and medial third of the clavicle with sternum in one patient. Staging studies included plain X-ray films; CT scan and technetium bone scan in all patients. Open incisional biopsy was performed through a linear incision along the longitudinal axis of the clavicle so that it can be incorporated in the definitive surgical procedure. All patients with Ewing's sarcoma had received neoadjuvant chemotherapy.

Post operatively standard dressings and arm sling were applied. Immobilization was continued for 2 weeks. Then both active and passive exercises were started. These patients were followed up for

variable periods ranging from 2 years to 9 years with mean follow up of 5 years.

Extent of resection of clavicle is dependent on the location, histopathological type and stage of the tumor according to new classification system evolved for clavicular resections [Figure - 1] and [Table - 2].

Results

Shoulder function was evaluated by measurement of shoulder motion and by manual muscle power testing. Patients were assessed for the neurovascular status. Functional results were analysed using AMSTS [13] scoring system and found to be excellent in 5 cases and good in 7 cases. The strength of abduction and flexion was limited in 2 patients but did not impinge on the overall functional outcome. Oncologically, ten patients were continuously disease free at their latest follow up. Two patients (Cases 2 and 4) of Ewing's sarcoma died of disseminated disease at 5 and 3 years respectively. All patients were satisfied with their cosmetic outcomes. [Table - 3] depicts the functional and oncological outcomes of all the twelve patients.

In case 6, we encountered an accidental tear of the subclavian vein, which was repaired primarily. One patient had (case 3) superficial wound infection, which was managed conservatively. Case number 11 developed chylothorax because of the injury to the thoracic duct which resolved with conservative measures. There were no permanent neurovascular complications.

Discussion

Primary tumors and tumor like lesions of the clavicle are uncommon. Klein [14] in a review of the literature found that only 0.45 percent of more than 13,000 primary bone tumors involved the clavicle. Nevertheless, most types of bone tumor and tumor like lesions have been described in this location [10],[14],[15]. Malignant tumors are more common than benign tumours [10]. A large nation wide series from the Bone Registry of Japan [16] however, demonstrated that occurrence of benign primary bone tumor of the clavicle was almost equal to that of malignant tumors. Frequently reported lesions include Ewing's sarcoma, lymphomas, myeloma, metastatic and eosinophilic granuloma.

Movements of the shoulder girdle involve a complex mechanism where clavicle scapula, head of the humerus and posterior thoracic wall participate [14]. Loss or defect in any one of the components of this synchronised system may result in an altered shoulder mechanism. It is the impression from the literature that the clavicle is functionless because its removal leads to no apparent defect in the shoulder function [1],[17]. But some studies have shown mild weakness in abduction, flexion and adduction [12],[13]. Analysis of this series of claviclectomy conforms that shoulder function is not impaired following claviclectomy. Measurement of shoulder motion has shown no limitation in any of the patient. Manual muscle testing has revealed mild weakness of abduction and flexion. This is because of partial loss of the deltoid attachment over the clavicle and due to the loss of clavicular head of the pectoralis major muscle. Other than inherent complications of any major surgical operation, proximity of the clavicle to important neurovascular structures, imparts additional risks. We had encountered injury to subclavian vein in one patient. Thoracic duct was injured in a case of post irradiation sarcoma, where type V resection was performed with the excision of the upper sternum. There were no permanent neurovascular complications in our series.

A classification system has been described for clavicular resections. This system is primarily based on the location of the tumor and the extent of the bone resection [Figure - 1] and [Table - 2]. In type I resection,

along with the whole clavicle, either a part of the adjacent sternum or the acromion process is also resected as necessary for tumor clearance.

Tumors of dispensable bones like clavicle, fibula, scapula, patella are treated by enbloc removal without significant functional impairment. Even though controversies exist, it appears from the review of the literature that results of total claviculectomy are good and encouraging [3],[7],[8],[9],[13].

Our study again confirms that post claviculectomy functions and oncological results are good and cosmetically acceptable. Thus removal of clavicle is not a disaster; in fact, clavicle is an accessory baggage in the skeleton [2].

References

1. Gurd F. Surplus parts of the skeleton. *Am J Surg*. 1947; 74: 705. ↑
2. Abbott LC, Lucas DB. The Function of the clavicle : its surgical significance. *Ann Surg*. 1954; 140 : 583. ↑
3. Wood VI. The results of total claviculectomy. *Clin Orthop*. 1986; 207:186-190. ↑
4. Moseley HF. The Clavicle - Its anatomy and function. *Clin Orthop*. 1968 ; 58 : 17. ↑
5. Jenkins F. The movement of shoulder in claviculate and aclaviculate mammals. *J Morphol*. 1974 ; 144 (1) : 71. ↑
6. Kumar R, Madewell JE, Swischuk LE, Lindell MM, David R. The clavicle and abnormal. *Radiographics*. 1989 ; 9 : 677-706. ↑
7. Srivastava G, Kochklar V. Osteomyelitis of the clavicle. *Acta Orthop Scand*. 1974 ; 45 (5) : 662. ↑
8. Spar L. Total claviculectomy for pathological fractures. *Clin Orthop*. 1977; 129 : 236. ↑
9. Lewis MM, Ballet FL, Kroll PG, Bloom N. Enbloc clavicular resection; Operative procedure and post operative testing of function. *Case Reports Clin Orthop*. 1985 ; 193 : 214-220. ↑
10. Smith J, Melachlan DL, Huvos AG, Higginbotham NL. Primary tumors of the clavicle and scapula. *Am J Roentgeno*. 1975 ; 124 : 113-123. ↑
11. Elkin DC, Cooper FW. Resection of the clavicle in vascular surgery. *J Bone Joint Surg*. 1946 ; 28 : 117. ↑
12. Lambert A. Claviculectomy as adjunct to surgical collapse of the chest wall. *Thorac Surg*. 1946 ; 15 : 66. ↑
13. Enneking WF, Dunham W, Gebhardt MC, Malawer M, Pritchard DJ. A system for the functional evaluation of the reconstructive procedures after surgical treatment of the tumours of the musculoskeletal system. *Clin Orthop*. 1993 ; 286 : 241-246. ↑
14. Klein MJ, Lusskin R, Becker MH, Antopol SC. Osteoid osteoma of the clavicle. *Clin Orthop*. 1979 ; 143 : 162-164. ↑
15. Smith J, Juppa F, Watson RC. Primary tumors and tumor like lesions of the clavicle. *Skel Radiol*. 1988 ;17 : 235-246. ↑
16. Japanese Orthop Assoc Musculo Skeletal Tumor Committee. Bone Tumor Registry in Japan, Tokyo, National Cancer Centre, 1994. ↑

Correspondence Address:

Mayilvahanan Natarajan
Madras Medical College & Government General Hospital, Chennai, India

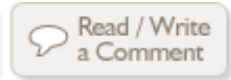
 Login to access the email ID

Source of Support: None, Conflict of Interest: None

Figures

Tables

[Table - 1], [Table - 2], [Table - 3]



[Previous Article](#)

[Next Article](#)

[Contact us](#) | [Sitemap](#) | [Advertise](#) | [What's New](#) | [Feedback](#) | [Copyright and Disclaimer](#)

© 2006 - Indian Journal of Orthopaedics | A journal by Medknow

Online since 9th November, 2006