

## TRAUMATOLOGY

[Previous Article](#) [ToC](#) [Next Article](#)

Year : 2006 | Volume : 40 | Issue : 3 | Page : 183-184

### Retrograde interlocking nailing in diaphyseal fractures of humerus

RK Goyal, Harish Chandra, KK Pruthi, A Kumar

Department of Orthopaedics, SN Medical College, Agra, India

Click [here](#) for **correspondence address** and email

[Download Article \(pdf\)](#)
[Email Article](#)
[Print Article](#)
[Read / Write a Comment](#)
[Citation Manager](#)

#### Abstract

**Background** : Retrograde interlocking nailing for humeral fracture is technically difficult but has advantage of sparing the involvement of rotator cuff and subacromial bursa.

**Methods** : A total number of 12 cases (9 closed, 3 compound - Grade I and II), having diaphyseal fractures of upper (3 cases) and middle third (9 cases ) of humerus were treated by retrograde interlocking nailing. Out of 12 cases, 11 were fresh and 1 was old fractures. Cases were followed up for 3 year.

**Results** : Excellent results were seen in 8, good in 3 and fair in one case ( delayed union). One case developed elbow stiffness, whereas none developed shoulder stiffness.

**Conclusions** : Apart from the overall advantages of conventional locked nailing technique, retrograde locked nailing has additional advantage of sparing the rotator cuff and subacromial bursa, thus preserving the shoulder functions.

**Keywords:** Retrograde interlocking nailing, rotator cuff, subacromial bursa.

#### How to cite this article:

Goyal RK, Chandra H, Pruthi KK, Kumar A. Retrograde interlocking nailing in diaphyseal fractures of humerus. Indian J Orthop 2006;40:183-4

#### How to cite this URL:

Goyal RK, Chandra H, Pruthi KK, Kumar A. Retrograde interlocking nailing in diaphyseal fractures of humerus. Indian J Orthop [serial online] 2006 [cited 2008 Nov 25];40:183-4. Available from: <http://www.ijonline.com/text.asp?2006/40/3/183/34489>

#### Search

SEARCH

Similar in PUBMED

Search Pubmed for

- Goyal RK
- Chandra H
- Pruthi KK
- Kumar A

Email Alert \*

Add to My List \*

\* Registration required (free)

Abstract

Introduction

Material and methods

Results

Discussion

References

Article Figures

Article Tables

#### Article Access Statistics

Viewed	1217
Printed	6
Emailed	2
PDF Downloaded	59
Comments	[Add]

#### Introduction

**Figures and Tables**

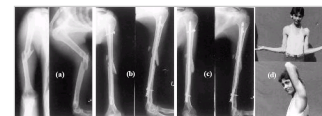


Fig. 1. (a) Preoperative X-ray...

Recommend  
this journal  
for your library



## Material and methods



Twelve patients with diaphyseal fractures of humerus were included in the study and treated by retrograde locked nailing during the period of 2002-2005. Criteria for the selection of patients were: patients after skeletal maturity having fractures of upper and middle third of the shaft of humerus. Patients with fractures of distal third of humerus were excluded from the study. Preoperative planning was done to assess the proper nail length and diameter.

*Operative technique:* Procedure was done either under G.A. or brachial block anaesthesia. Patient was placed in prone position. After cleaning and drapping, approx. 6cm long incision extending proximally from the tip of olecranon process was made. After retracting the triceps muscle, olecranon fossa was identified. Approx 2-2.5 cm. proximal to the tip of olecranon fossa, a portal of entry (2cm longx1 cm wide) was made in posterior cortex of humerus by using a drill. Reaming was done under image control. Nail of appropriate length and diameter was assembled and introduced into the distal fragment; fracture reduced under image control and nail was further introduced into the proximal fragment. Distal screw was inserted from posterior to anterior and proximal screw from lateral to medial side. Then the incision was closed in layers. POP cast was applied if required. Post operatively limb elevation and active finger movements were advised. Shoulder and elbow exercises within the limit of tolerance were started as soon as the pain subsided. Stitches were removed from 11th -14th post operative day.

## Results



There were 8 male and 4 female patients. Right extremity was involved in 8 cases and left in 4 cases. Fractures were closed in 9 cases and 3 cases had compound fractures (Grade I, Grade II). Eleven fractures were fresh and one case had 4 weeks old fracture with misalignment. Nine fractures were in middle third and 3 cases had fracture in proximal third of humerus. Fractures were of transverse type in 8 cases, comminuted in 2 cases and oblique in 2 cases. Two cases required open reduction and in one case that had 4 weeks old fracture bone grafting was also done. Shoulder and elbow physiotherapy was started within the limits of tolerance as soon as the pain subsided. The patients were followed for an average period of 36 months. 8 cases united within 12 weeks, 2 cases within 12-16 weeks, one case in 16-20 weeks. Once case was in the process of union even after 20 weeks time and labelled as delayed union. Half of the cases (6 cases) returned to their daily routine works without any or minimal discomfort within 5-7 weeks after surgery. During follow up, one case who went in delayed union was treated by bone grafting and proceeded to union, one case had partial neurological deficit (partial radial nerve injury) treated conservatively and recovered within 6 weeks, one case had elbow stiffness due to poor physiotherapy compliance and one case developed triceps irritation and fracture at nail insertion site, this case had history of fall during follow-up, fracture was undisplaced and treated conservatively. Excellent results were seen in 8 cases, good in 3 cases and fair in one case.

None of the case developed shoulder stiffness. All cases had nearly full range of movements at shoulder (abduction > 150°, internal rotation 50°-60°, external rotation 45°-55°). All cases except one had full range of flexion and extension movements at elbow. One case had restricted elbow flexion (upto 90°).

## Discussion

Fractures of the shaft of humerus are more common in adults and middle aged group. Road traffic accidents were the predominant mode of injury. Half of the cases had other associated injuries. No deep infections developed even in compound fracture cases. Most of the fractures cases (8 cases) got union in 12 weeks time. Time of union has been reported as between 5 and 12 weeks <sup>[3]</sup> and 8.2 weeks <sup>[2]</sup> in other studies. Four cases developed complications during followup, one delayed union, one partial radial nerve injury, one elbow stiffness and one fracture at nail insertion site.

Retrograde locked nailing is a technically demanding procedure but besides all other advantages of conventional locked nailing, it preserves the shoulder functions. Recovery of shoulder functions after retrograde locked nailing is complete and only few had mild loss of elbow movements 1-6. In study of Loitz et al only one patient out of 39 had loss of 15° at elbow <sup>[3]</sup>, 2 patients out of 39 had supracondylar fracture during nail insertion. None of the case developed deep infections, shortening, angulation, nonunion, implant failure and shoulder stiffness.

So we conclude that retrograde locked nailing is a useful option in the treatment of diaphyseal fractures of humerus where preservation of shoulder function is a demand <sup>[6]</sup>.

## References

1. Ingman AM, Waters DA. Locked intramedullary nailing of humeral shaft fractures, implant design, surgical technique and clinical result. *J. Bone Joint Surg.* 1994; 76: 23-29. [↑](#)
2. Lin J, Hou SM, Hang YS, Chao EY. Treatment of humeral shaft fractures by retrograde locked nailing. *Clin Orthop.* 1997 Sept; (342): 147-155. [↑](#)
3. Loitz D, Weinberg AM, Koennecker W, Kretteck C, Reilmann, H. Trauma department- stad. Klinikum Braunschweig, Germany; Medical School Hannover, Hannover, Germany. Retrograde Interlocking nailing of proximal humerus fracture, *OTA 1996 posters*, Poster 91. [↑](#)
4. Borrens O, Moushine E, Chevalley F. Preliminary results of retrograde nailing of the humerus. *Electronic Journals (Swiss Surgery)* 2001. [↑](#)
5. Rommens et al. Retrograde locked nailing of humeral shaft fractures *JBJS*, Br. 1995; 77: 84-89. [↑](#)
6. Scheerlinck T, Handelberg F. Shoulder and elbow function after nailing of humeral shaft fractures. Retrograde nailing compared to antegrade nailing. *Folia Traumatologica Lovaniensia* 2001. [↑](#)

### Correspondence Address:

R K Goyal  
51, Gajanan Nagar, Kothi Meena Bazar, Shahganj, AGRA-282 010  
India

 [Login to access the email ID](#)

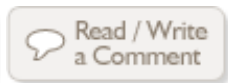
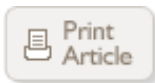**Source of Support:** None, **Conflict of Interest:** None

## Figures

[Figure - 1]

## Tables

[Table - 1]



[◀ Previous Article](#)

[Next Article ▶](#)

[Contact us](#) | [Sitemap](#) | [Advertise](#) | [What's New](#) | [Feedback](#) | [Copyright and Disclaimer](#)

© 2006 - Indian Journal of Orthopaedics | A journal by Medknow

Online since 9<sup>th</sup> November, 2006