

MISCELLANEOUS

◀ Previous Article ToC Next Article ▶

Year : 2006 | Volume : 40 | Issue : 1 | Page : 38-40

## Pigmented villo nodular synovitis

S Radha, T Afroz, JVS Vidya Sagar

Departments of Pathology and Orthopaedics, Kamineni Hospital, Hyderabad, India

Click [here](#) for correspondence address and email

### Abstract

**Background:** Pigmented villonodular synovitis is a rare disorder affecting joints.

**Methods :** We reviewed 19 cases of pigmented villonodular synovitis out of 481 arthroscopic synovial biopsies over a period of ten years. A common presenting symptom was locking. Both diffuse and localized forms were diagnosed. Duration of symptoms varied from 5 months to 3 years. We report our experience of patients treated by arthroscopic excision for localized villonodular synovitis and arthroscopic synovectomy for diffuse villonodular synovitis followed by intraarticular Yttrium.

**Results :** In diffuse villonodular synovitis arthroscopic total synovectomy was done using special angular and straight motorized shaver through different portals to reach all corners of the joint. Localized variety was treated by excising the pedicle attached to the synovium. In our series none of the patients with localized villonodular synovitis showed recurrence till date. Three cases of diffuse variety presented with effusion and swelling three to six months after treatment and were managed by arthroscopic synovial shaving. Two cases who showed recurrence after one year were subjected to intraarticular <sup>90</sup>Y isotope injection.

**Conclusion :** Arthroscopic synovectomy helps in reducing morbidity. Radiation and intraarticular injection of <sup>90</sup>Y are alternative modes of treatment.

**Keywords:** Pigmented villonodular synovitis; Synovectomy; Adjuvant treatment.

**How to cite this article:**

Radha S, Afroz T, Vidya Sagar J. Pigmented villo nodular synovitis. Indian J Orthop 2006;40:38-40

**How to cite this URL:**

Radha S, Afroz T, Vidya Sagar J. Pigmented villo nodular synovitis. Indian J Orthop [serial online] 2006 [cited 2008 Nov 27];40:38-40. Available from: <http://www.ijoonline.com/text.asp?2006/40/1/38/34073>

Search

SEARCH

Similar in PUBMED

Search Pubmed for

- Radha S
- Afroz T
- Vidya Sagar J

Email Alert \*

Add to My List \*

\* Registration required (free)

Abstract

Introduction

Materials and me...

Results

Discussion

References

Article Figures

Article Tables

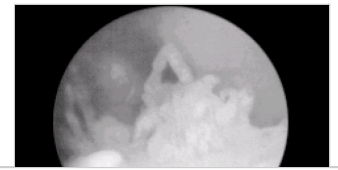
Article Access Statistics

Viewed	1893
Printed	9
Emailed	0
PDF Downloaded	65
Comments	[Add]



Figures and Tables

## Introduction



Recommend  
this journal  
for your library



Villonodular synovitis is a rare lesion that may affect any joint, but is frequently found in the knee joint. Definitive diagnosis is always made histologically on synovial biopsy specimen. Treatment needs complete excision or even synovectomy. We diagnosed villonodular synovitis in nineteen cases out of total number of 481 arthroscopic synovial biopsies over a period of ten years. Out of these, four were localized masses and seven were of diffuse variety. In the present paper the clinical, arthroscopic and histological features are correlated. These lesions are discussed because of the rarity.

## Materials and methods

Patients presenting to the Orthopaedic department of our hospital with monoarticular involvement during the period 1994-2004 were evaluated. Those who were subjected to arthroscopic synovial biopsy for final diagnosis formed the material of this study. In all the patients detailed clinical history was taken and routine haematological, radiological investigations and immuno-serological tests were done. Arthroscopic evaluation was done in these cases for diagnosis and evaluation of synovial appearance, and for obtaining synovial biopsy. Synovial fluid analysis was done. Biopsy specimens were processed routinely and paraffin sections were stained with hematoxylin, eosin and perls.

## Results

The age and gender distribution, type of clinical presentation and clinical diagnosis before arthroscopic synovial biopsy is detailed in [Table - 1]. All the lesions were from knee joint, seven were from right knee and twelve from left knee. The mean age of patients was 39 years (range 18 to 70 yrs). All the patients were treated with arthroscopic excision and synovectomy. The mean follow up period was 5 to 60 months. There was no recurrence till date. The duration of symptoms was 5 months to 3 yrs.

At arthroscopy the localized lesions seen were pedunculated masses different from the surrounding synovium. Typically, these lesions were ovoid and fish shaped masses attached with a thin pedicle to the synovium nearby and moving within the joint producing locking of joint, behaving like meniscal tears. The diffuse lesions had multiple filiform, fingers like projections with pointed or blunt tips without any evidence of coalescence or bulbous appearance [Figure - 1].

There was invariably brownish pigment deposition on the villi, articular surfaces, meniscal surfaces and over the ligaments. All the patients had moderate hemorrhagic effusion. Synovial fluid analysed revealed cell counts ranging from 2000-5000cells/cumm and predominant cells on cytology were neutrophils. In diffuse villonodular synovitis arthroscopic total synovectomy was done a using special angular and straight motorized shaver through different portals to reach all corners of the joint. Localized variety was treated by excising the pedicle attached to the synovium. In our series none of the patients with localized villonodular synovitis showed recurrence till date. Three cases of diffuse variety presented with effusion and swelling three to six months after treatment and were managed by arthroscopic synovial shaving. Two cases who showed recurrence after one year were subjected to intraarticular <sup>90</sup>Y isotope injection. These patients are on regular follow up with no recurrence till date.

**Pathology:** The localized lesions presented as flattened masses. The largest mass measured 5x3 cms. Cut section had yellowish areas speckled with brownish areas. [Figure - 2]. In diffuse villonodular

synovitis the lesion consisted of multiple bits of gray brown soft tissue. Diffuse and localized varieties had similar histological features. There was villous hypertrophy of synovial lining. Sub synovial tissue had nodules of round to oval cells with interspersed multinucleate giant cells. [Figure - 3]. Groups of foamy cells and variable amount of pigment were seen. This pigment was perls positive. There was variable amount of fibrosis. The population of giant cells, foam cells, stromal cells, neutrophils and degree of iron deposition varied. There was no correlation between duration of symptoms and fibrosis.

## Discussion

Pigmented villo nodular synovitis is a proliferative process that is found in the synovial joints and tendon sheaths and is most commonly seen in the knee [1]. It is usually monoarticular and polyarticular involvement is rare [2]. All the patients in the present study had monoarticular knee joint involvement. Localized and diffuse forms of synovial involvement may occur [3]. In the knee joint it not only mimics internal derangement, but is also misdiagnosed as malignant lesions prompting needless amputations [4]. The arthroscopic features and histology are characteristic of diagnosis in our series. The histological characteristics of nodular and diffuse lesions suggest that they have common histogenesis. The exact pathogenesis remains unclear. The lesions are characterized by proliferation of fibroblastic and histiocytic mesenchymal cells below the synovial lining cells. Foam cells and Iron deposits are secondary changes. The localized forms have a relatively high cure rate compared to diffuse forms. The etiology of pigmented villonodular synovitis is not exactly known. Inflammatory process is the most widely held theory of pathogenesis. The histological features of stromal cells, abundant collagen and hyalinization led Jaffe to conclude that the findings closely resemble an inflammatory process [5]. Cytogenetic data has shown various results. Xchromosome inactivation analysis showed that the lesion was polyclonal in origin. This report suggests reactive proliferation than a true neoplasm [6].

Immunohistochemical profile is not well characterized. CD68 is consistently seen in mononuclear cells and histiocytes. Scattered dendritic cells expressing S-100 were seen in 67% cases [7]. In most cases diagnosis is straight forward and ancillary studies are not needed. Awareness of this entity helps to avoid misdiagnosis and radical surgery.

Complete excision of the mass in the affected joint is the treatment of choice in the localized form [8]. For diffuse villonodular synovitis traditional effective treatment is surgical synovectomy. It can be done by either arthroscopy or arthrotomy. Arthroscopic synovectomy has reduced morbidity and is well-tolerated [9]. The recurrence rate in open surgical synovectomy is between 25-45% [10]. This is the reason that other treatment modalities such as radiation and intraarticular Injection of <sup>90</sup>Y have been tried. The success rate reported is 77.3+/-25.3% [11]. The side effects of intraarticular 90Y injection are few, predictable and avoidable [12].

## References

1. Docken WP. Pigmented villonodular synovitis: A review with illustrative case reports *Sem Arthrit Rheumat.* 1979; 9: 1-22. ↑
2. Flandry F, Hughston JC, McCann SB, Kurtz DM. Diagnostic features of Diffuse Pigmented Villonodular Synovitis of Knee. *Clin Orthop.* 1994; 298: 212 - 220. ↑
3. Granowitz SP, D'Antonio J, Mankin HL. Pathogenesis and Longterm end results of PVNS. *Clin Orthop.* 1976; 114: 335 - 351. ↑
4. Jergesen, HE, Mankin HJ, Schiller AL. Diffuse Pigmented Villonodular synovitis of knee mimicking primary bone neoplasm. *J Bone Joint Surg (Am).* 1978; 60: 825 - 829. ↑
5. Bravo SM, Winalski CS, Weissman BN. Pigmented villonodular synovitis. *Radiol Clin North*

Am.1996; 34-2: 311- 326. [↑](#)

6. Sackers RJB, Jung DDe, Heul RO Van Der. The Netherlands. XChromosome inactivation in patients who have pigmented villonodular synovitis. *J Bone Joint Surg (Am)*.1991; 73: 1532 - 1535. [↑](#)
7. Perka C, Labs K, Zippel H, Buttgereit F. Localised pigmented villonodular synovitis of the knee joint. *Rheumatol*. 2000; 39: 172 - 178. [↑](#)
8. Schwartz HS, Unni KK, Pritchard DJ. Pigmented villonodular synovitis. A retrospective review of affected large joints. *Clin Orthop*.1989; 247:243-55. [↑](#)
9. Sim FH. Synovial proliferative disorders: role of synovectomy. *Arthroscopy*. 1985; 1:198-204. [↑](#)
10. Flandry FC, Hughston JC, Jacobson KE et al. Surgical treatment of diffuse pigmented villonodular synovitis of the knee. *Clin Orthop*.1994; 300:183-192. [↑](#)
11. Kresnik E, Mikosch P, Gallowitsch HJ et al. Clinical outcome of radiosynoviorthesis: a meta-analysis including 2190 treated joints. *Nucl Med Comm*.2002; 23(7): 683-688. [↑](#)
12. Wiss DA. Recurrent villonodular synovitis of the knee. Successful treatment with Yttrium 90. *Clin Orthop*.1982; 169:139-144. [↑](#)

#### Correspondence Address:

S Radha  
Plot No: 20, Road No: 1, Alakapuri, Hyderabad – 35  
India

 [Login to access the email ID](#)

**Source of Support:** None, **Conflict of Interest:** None

#### Figures

[\[Figure - 1\]](#), [\[Figure - 2\]](#), [\[Figure - 3\]](#)

#### Tables

[\[Table - 1\]](#)

 [Download Article \(pdf\)](#)

 [Email Article](#)

 [Print Article](#)

 [Read / Write a Comment](#)

 [Citation Manager](#)

[◀ Previous Article](#)

[Next Article ▶](#)

[Contact us](#) | [Sitemap](#) | [Advertise](#) | [What's New](#) | [Feedback](#) | [Copyright and Disclaimer](#)

© 2006 - Indian Journal of Orthopaedics | A journal by Medknow

Online since 9<sup>th</sup> November, 2006