

Search



Similar in PUBMED

 Search Pubmed for

- Kuhl S
- Schulze RK
- Hansen T
- Muller-Hermelink HK
- Hans-Ullrich V

Article in PDF (158 KB)

Citation Manager

Access Statistics

Reader Comments

Email Alert \*

Add to My List \*

\* Registration required (free)

Abstract

Introduction

Case History

Discussion

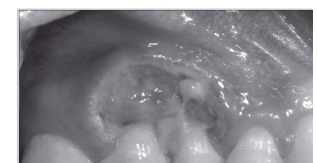
References

Article Figures

#### Article Access Statistics

Viewed	244
Printed	1
Emailed	0
PDF Downloaded	25
Comments	<a href="#">[Add]</a>

#### Figures and Tables



## CASE REPORT

[◀ Previous Article](#)
[ToC](#)
[Next Article ▶](#)

Year : 2008 | Volume : 12 | Issue : 1 | Page : 34-37

### Granuloma Riga-Fede (eosinophile traumatic ulcerative granuloma): A variant of a monoclonal CD30+ lymphoproliferative disorder

Sebastian Kuhl<sup>1</sup>, Ralf Kurt Willy Schulze<sup>1</sup>, Torsten Hansen<sup>2</sup>, Hans Konrad Muller-Hermelink<sup>3</sup>, Volker Hans-Ullrich<sup>3</sup>


<sup>1</sup> Department of Oral Surgery, Johannes Gutenberg-University, Mainz, Germany

<sup>2</sup> Department of Pathology, Johannes Gutenberg-University, Mainz, Germany

<sup>3</sup> Department of Pathology, University Würzburg, Würzburg, Germany

#### Correspondence Address:

Sebastian Kuhl  
Poliklinik für Zahnärztliche Chirurgie, Augustusplatz 2, 55131 Mainz  
Germany

 Login to access the email ID

Source of Support: None, Conflict of Interest: None

## Abstract

The granuloma Riga-Fede (GRF) belongs to benign self-healing ulcerative lesions, usually located in the oral mucosa. Histological characteristics are eosinophilia accompanied by a population of large mononuclear cells, leading to synonyms as eosinophilic ulcer of the oral mucosa, traumatic eosinophilic granuloma, or traumatic ulcerative granuloma with stromal eosinophilia. Its rare appearance and clinical similarity to squamous cell carcinoma cause difficulties in diagnosis and can lead to severe overtreatment. Recent publications have revealed that GRF could be included within the spectrum of CD30+ lymphoproliferative disorders due to the positivity of CD30 antigen in some reported cases. We present a case of a 19-year-old patient with GRF localized in the attached gingiva of the upper left first molar with CD30 antigen positivity and monoclonal T cell receptor-gamma (TCR-g) gene rearrangement. It is suggested that GRF can represent a subset of CD30+ lymphoproliferative disorders.

**Keywords:** Clonality, eosinophilia, granuloma Riga-Fede, traumatic, ulceration

#### How to cite this article:

Kuhl S, Schulze RK, Hansen T, Muller-Hermelink HK, Hans-Ullrich V. Granuloma Riga-Fede (eosinophile traumatic ulcerative granuloma): A variant of a monoclonal CD30+ lymphoproliferative disorder. J Oral Maxillofac Pathol 2008;12:34-7

#### How to cite this URL:

Kuhl S, Schulze RK, Hansen T, Muller-Hermelink HK, Hans-Ullrich V. Granuloma Riga-Fede (eosinophile traumatic ulcerative granuloma): A variant of a monoclonal CD30+ lymphoproliferative disorder. J Oral Maxillofac Pathol [serial online] 2008 [cited 2008 Oct 23];12:34-7. Available from: <http://www.jomfp.in/text.asp?2008/12/1/34/42196>

Recommend  
this journal  
for your library



## Introduction

---

Granuloma Riga-Fede is characterized clinically by ulcerations of the oral mucosa and histologically by eosinophilia accompanied by a population of large mononuclear lymphoid cells, leading to synonyms as eosinophilic ulcer of the oral mucosa (EUOM), traumatic eosinophilic granuloma (TEG), or traumatic ulcerative granuloma with stromal eosinophilia (TUGSE).

Though it belongs to the category of benign self-healing ulcerative lesions, the clinical appearance often mimics a malignant process such as lymphoid neoplasm or squamous cell carcinoma. Not only clinical appearance, but also histological findings can cause difficulties in excluding malignancy. Definite diagnosis can mostly only be achieved by combining histological findings with clinical follow-up.

Recent publications have revealed a new debate about the histogenesis of GRF, as immunohistochemical analysis showed CD30 positivity in nearly half of all cases. [1],[2],[3],[4],[5] Thus the question arises, whether GRF could be the oral counterpart of CD30+ lymphoproliferative disorders. We present a case of a 19-year-old patient with GRF localized in the facial attached gingiva of the upper left first molar with CD30 antigen positivity. A monoclonal TCR-gamma gene rearrangement was found, though clinical course indicated a reactive nature. It is suggested that GRF can represent a subset of CD30+ lymphoproliferative disorders.

## Case History

---

A 19-year-old man was referred because of ulceration in the facial region of the upper left first molar, which had developed within 1 week without any traumatic history. The ulceration had been unsuccessfully treated with local antimycotics by the referring physician for 2 weeks. Extraoral examination showed no pathological findings, though the patient reported general fatigue with night sweat and a weight loss of 2 kg during the previous 4 weeks. No regional lymphadenopathies could be found.

Intraoral examination revealed a painless, yellowish fibrinous ulceration of 1 × 1.5 cm diameter and 0.5 cm depth, limited to the attached gingiva of the vital teeth 25 and 26 [Figure 1]. The ulceration had indurated borders with central necrosis that tended to bleed on contact and appeared firm to palpation. The teeth 25 and 26 had no mobility, and no radiological abnormalities could be found in intraoral radiographs.

Blood analysis was negative to hepatitis A, B, C; human immunodeficiency virus (HIV); Lues; and herpes simplex virus (IgG, IgM) and showed only a slight neutrophilic granulocytosis associated with lymphocytopenia and leukocytosis. C-reactive protein concentration was 41 mg/L. Candida could not be verified in either the blood culture or smear test. The patient was initially treated with amoxicillin (3 g/day) and local application of chlorhexidine (0.3%) for 1 week, without positive effect [Figure 2]. A biopsy was taken for histological, immunohistochemical (Institute of Pathology, Mainz, Germany), and molecular (Institute of Pathology, Würzburg, Germany) analysis. Histological analysis revealed a sharply defined lesion with superficial ulceration [Figure 3A]. The lesion contained a polymorphic lymphoid infiltration dominated by

medium-sized polymorphic blasts with round to oval nuclei and scattered chromatin with prominent nucleoli [Figure 3B]. Furthermore, eosinophile granulocytes, followed by fewer regular lymphocytes and plasma cells, were seen in deeper regions [Figure 3B]. In immunohistochemical analysis, the blastic cells expressed lineage-specific T-cell antigen CD3 and also, CD4 and CD30 [Figure 3C], whereas CD20 was negative. Cytotoxic granules (Perforin, TIA-1, and GranzymB) and Alk-1 were not expressed; therefore, an anaplastic large cell lymphoma was ruled out. The proliferative index was high (up to 80%) [Figure 3D]. Molecular-pathological clonality test of the IgH gene of B-lymphocyte population was performed by polymerase chain reaction (PCR), and polyclonal rearrangement was found at the regions CDR II and CDR III. The amplification of the T-cell receptor (TCR-g) gene using a multiplex PCR showed a monoclonal rearrangement with a length of 201 base pairs.

Four weeks after the initial presentation, the ulceration spontaneously disappeared without any treatment. The lesion has not recurred after 6 months of follow up. The patient remains in regular follow-up.

## Discussion

---

The GRF was first described in children by Riga and Fede at the beginning of the 19<sup>th</sup> century. [5] Since then, different synonyms such as eosinophilic ulcer of the oral mucosa (EUOM), traumatic eosinophilic granuloma (TEG), and traumatic ulcerative granuloma with stromal eosinophilia (TUGSE) have been used to describe an entity of mucosal lesions, characterized by benign self-limited ulcerations of the oral mucosa with histological eosinophilia. [5],[6] Typical localizations of GRF are the tongue, gingiva, buccal or lip mucosa. [4] Therefore, trauma is assumed to play an important role in the genesis of GRF. [4] In the present case, however, a traumatic cause could be excluded, which is in accordance with roughly 50% of the reported cases. [7]

Diagnosis can cause difficulties, especially because of the clinical similarity to squamous cell carcinoma and its rare appearance. This may result in severe overtreatment. Clinical differential diagnoses of GRF include squamous cell carcinoma; infectious disorders like syphilis, tuberculosis, histoplasmosis, or necrotizing bacterial infections; as well as Langerhans cell histiocytosis, lupus erythematosus, or Wegner's granulomatosis and sarcoidosis. [5]

In the present case, the lesion appeared to be a spontaneously regressing, clonal CD30+ lymphoid proliferation. However, despite the irregularity of the proliferating cells, mitoses, uniform CD30 reactivity and strong MIB-1 staining, monoclonal TCR rearrangement, the presence of preceding constitutional signs and symptoms, the lesion was estimated as being benign as clinical follow-up showed no recurrence or further signs of malignancy for 6 months. In contrast, Rosenberg *et al.* reported on two cases with primary extranodal CD30+ non-Hodgkin's lymphomas of the oral mucosa which mimicked multifocal traumatic eosinophilic granuloma and periodontitis. [4]

The exact pathomechanism of GRF remains still unknown. Recent publications have disclosed a new debate about the histogenesis of GRF, as immunohistochemical analysis showed CD30 positivity in nearly half of all the cases. [1],[2],[3],[4],[5] The lymphoid activation antigen CD30 is recognized by the monoclonal antibodies Ki-1 or Ber-H2. It was being found to expressed in Hodgkin's disease (HD) [3] and was subsequently found in different entities of non-Hodgkin's lymphomas [4] and in activated lymphoid cells of nonneoplastic disorders, e.g., in mononucleosis. Furthermore, a group of cutaneous CD30+ lymphoproliferative diseases exists, [2] belonging to the category of anaplastic large cell lymphoma and lymphomatoid papulosis. Thus the question arises whether GRF could be the oral counterpart of primary cutaneous CD30+ lymphoproliferative disorders. Cepeda *et al.* examined 28 specimens of common neutrophil-rich and eosinophil-rich nonneoplastic CD30+ skin infiltrates. They came to the conclusion that large atypical CD30+ cells are a component of a reactive rather than a neoplastic process. [2] The presence of CD30+ atypical lymphoid cells in nonneoplastic settings is particularly relevant in the

differential diagnosis of lymphomatoid papulosis and anaplastic large cell lymphoma. [2] However, lymphomatoid papulosis and anaplastic large cell lymphoma might express CD30. Therefore, the investigation of the morphological presentation of the whole process allows differential diagnosis. Furthermore, an analysis of clonality can help. Anaplastic large cell lymphomas are monoclonal disorders, whereas lymphomatoid papulosis is more often polyclonal. However, a clonal rearrangement of the TCR-gamma-receptor does not prove malignancy. Steinhoff *et al.* found a monoclonal rearrangement in cases of CD30+ lymphomatoid papulosis of the skin associated with favorable clinical behavior. [8] It seems coherent that also clonal CD30+ cell populations are detectable in GRF, which perhaps could be interpreted as a mucosal counterpart of lymphomatoid papulosis on the basis of clinical, histological, and immunohistochemical similarities. [1] Hirshberg *et al.* confirmed a clonal subset of GRF in their study, as did Alobeid. [1],[9]

In summary, the diagnosis of GRF can only be made by a combination of clinical, histological, and immunohistochemical analysis. Molecular investigations are necessary for completeness, but monoclonal rearrangement does not prove malignancy. The dignity of the lesion is not identified by the appearance of large atypical CD30+ lymphoid cells. More studies are necessary to identify the role of differences in the clonal origin. It still remains unclear whether or not GRF can be regarded as an oral counterpart of primary cutaneous lymphoproliferative disorder. Because of the clinical, histological, and immunohistochemical similarity to lymphoproliferative disorders, one may suggest that GRF represents a subset of lymphoproliferative disorders. To confirm this hypothesis, further research including a higher number of patients is required.

## References

---

1. Alobeid B, Pan LX, Milligan L, Budel L, Frizzera G. Eosinophil-rich CD30+ lymphoproliferative disorder of the oral mucosa. *Am J Clin Pathol* 2004;121:43-50. † [PUBMED] [FULLTEXT]
2. Cepeda LT, Pieretti M, Chapman SF, Horenstein MG. CD30-positive atypical lymphoid cells in common non-neoplastic cutaneous infiltrates rich in neutrophils and eosinophils. *Am J Surg Pathol* 2003;27:912-8. † [PUBMED] [FULLTEXT]
3. Ficarra G, Prignano F, Romagnoli P. Case report: Traumatic eosinophilic granuloma of the oral mucosa: A CD30+ (Ki-1) lymphoproliferative disorder? *Oral Oncol* 1997;33:375-9. † [PUBMED] [FULLTEXT]
4. Rosenberg A, Biesma DH, Sie-Go DM, Slootweg PJ. Primary extranodal CD30-positive T-cell non Hodgkin's lymphoma of the oral mucosa: Report of two cases. *Int J Oral Maxillofac Surg* 1996;25:57-9. † [PUBMED]
5. Segura S, Romero D, Mascaro JM, Colomo L, Ferrando J, Estrach T. Eosinophilic ulcer of the oral mucosa: Another histological simulator of CD30+ lymphoproliferative disorders. *Case Report. Br J Dermatol* 2006;155:460-3. †
6. Regezi JA, Zarabo JR, Daniels TE, Greenspan JS. Oral traumatic granuloma: Characterization of the cellular infiltrate. *Oral Surg Oral Med Oral Pathol Oral Radiol Endod* 1993;75:723-7. †
7. Elzay RP. Traumatic ulcerative granuloma with stromal eosinophilia (Riga-Fede disease and traumatic eosinophilic granuloma). *Oral Surg Oral Med Oral Pathol Oral Radiol Endod* 1983;55:497-506. †
8. Steinhoff M, Hummel M, Anagnostopoulos I, Kaudewitz P, Seitz V, Assaf C, *et al.* Single-cell analysis of CD30+ cells in lymphomatoid papulosis demonstrates a common clonal T-cell origin. *Blood* 2002;100:578-84. † [PUBMED] [FULLTEXT]
9. Hirshberg A, Amariglio N, Akrish S, Yahalom R, Rosenbaum H, Okon E, *et al.* Traumatic ulcerative granuloma with stromal eosinophilia: A reactive lesion of the oral mucosa. *Am J Clin Pathol* 2006;126:522-9. † [PUBMED] [FULLTEXT]

## Figures

---



**Print this article**



**Email this Article  
to your friend**

[◀ Previous Article](#)

[Next Article ▶](#)

[Sitemap](#) | [What's New](#) | [Feedback](#) | [Copyright and Disclaimer](#)

© 2007 - Journal of Oral and Maxillofacial Pathology | Published by Medknow

Online since 15<sup>th</sup> August, 2007

