

[\[Print Version\]](#)
[\[PubMed Citation\]](#) [\[Related Articles in PubMed\]](#)

TABLE OF CONTENTS

[\[INTRODUCTION\]](#) [\[MATERIALS AND...\]](#) [\[RESULTS\]](#) [\[DISCUSSION\]](#) [\[CONCLUSIONS\]](#) [\[REFERENCES\]](#) [\[TABLES\]](#) [\[FIGURES\]](#)

doi: 10.2319/021507-73.1

The Angle Orthodontist: Vol. 78, No. 1, pp. 32-37.

Mandibular Asymmetry in Class II Subdivision Malocclusion

Gökmen Kurt;^a Tancan Uysal;^b Yildiray Sisman;^c Sabri İlhan Ramoğlu^d

ABSTRACT

Objective: To evaluate the condylar and ramal mandibular asymmetry in a group of patients with Class II subdivision malocclusion to identify possible gender differences between male and female subjects.

Materials and Methods: Mandibular asymmetry measurements (condylar, ramal, and condylar-plus-ramal asymmetry values) were performed on the panoramic radiographs of 80 subjects (34 male and 46 female). The study group consisted of 40 Class II subdivision patients (18 male and 22 female; mean age 14.53 ± 3.14 years). The control group consisted of 40 subjects with normal occlusion (16 male and 24 female; mean age 14.43 ± 3.05 years). The Kruskal-Wallis test was used to determine the possible statistically significant differences between the groups for condylar, ramal, and condylar-plus-ramal asymmetry index measurements. Identified differences between groups were further analyzed using the Mann-Whitney *U*-test at the 95% confidence interval ($P < .05$).

Results: No gender-related difference was found for any of the asymmetry indices. Comparison of condylar, ramal, and condylar-plus-ramal asymmetry index values and gonial angle measurements for Class I and Class II sides in the Class II subdivision group and for right and left sides in the Class I group showed no statistically significant differences. However, the Class II subdivision group has longer values for condylar, ramal, and condylar-plus-ramal height measurements and only these differences were statistically significant ($P < .001$).

Conclusions: Except for condylar ramal and condylar-plus-ramal height measurements, Class II subdivision patients have symmetrical condyles when compared to normal occlusion samples according to Habbet's mandibular asymmetry indices.

KEY WORDS: Condylar asymmetry, Class II subdivision, Mandibular asymmetry, Orthopantomograph.

Accepted: March 2007. Submitted: February 2007

INTRODUCTION [Return to TOC](#)

Unilateral Class II cases were classified as subdivision cases by Angle.¹ He reported that a Class II molar relationship developed because of the distal eruption of the mandibular first molars in relation to normally positioned maxillary first molars.²

Asymmetry in the face and dentition is a naturally occurring phenomenon. Before planning orthodontic treatment to correct subdivision problems, the origin of the asymmetry must be identified. The treatment of Class II malocclusions characterized by dentoalveolar asymmetries presents difficulties for clinicians because of the determination of the source of the malocclusion. A question arises as to whether subdivision malocclusions caused by dentoalveolar or skeletal deviations or any compromise treatment plans lead to additional complications, such as tipping of the occlusal plane, dental instability, or temporomandibular disharmonies.³

Alavi et al⁴ showed that the unilateral distal positioning of the mandibular first molars was the primary contributor to an anteroposterior discrepancy in this type of malocclusion, but they did not define that the mandibular molar position was due to a skeletal asymmetry or a dentoalveolar asymmetry. Rose et al⁵ concluded that the mandible in Class II subdivision malocclusions did not exhibit unusual skeletal positioning or skeletal asymmetry. Only the mandibular dentition was found to be asymmetric, resulting in a relative distal positioning of the lower first molar on the Class II side. Janson et al⁶ found similar findings with Rose et al⁵ indicating that mandibles showed no unusual skeletal or positional asymmetries. In a recent study, Azevedo et al⁷ found results similar to those of Janson et al.⁶ However, in another study, Janson et al⁸ found that there was a tendency for mandibular asymmetry in subgroups of Class II subdivision subjects compared with the control group.

Habets et al⁹ described a method for evaluating condylar and ramal asymmetry. This method has been used to calculate the condylar and ramal heights for comparing the right and left sides of the mandible for asymmetries in temporomandibular disorder (TMD) patients, Class I, Class II, and Class III malocclusions,

A review of the literature revealed no studies that measured the condylar and ramal asymmetry of Class II subdivision patients and compared it with that of normal subjects using the method described by Habets et al.⁹

Therefore, the objectives of this study were to determine the condylar and ramal mandibular asymmetry in a group of patients with Class II subdivision malocclusion and compare these data with similar measurements from a sample with normal occlusion. The intent is to identify possible gender differences between male and female subjects.

MATERIALS AND METHODS [Return to TOC](#)

Two groups were selected from the archives of the Erciyes University, Faculty of Dentistry and Department of Orthodontics. The present study was performed on orthopantomograms (OPG) of 40 normal occlusion and 40 Class II subdivision malocclusion subjects. The distributions of age and ANB in different groups for all subjects are shown in [Table 1](#).

Normal Occlusion Sample

The OPGs of the 40 adolescent control subjects (16 male and 24 female) with normal occlusion met the following criteria¹⁹:

- Class I canine and molar relationship with minor or no crowding; normal growth and development; well-aligned upper and lower dental arches;
- All teeth present except third molars;
- Good facial symmetry determined clinically;
- No significant medical history;
- No history of trauma, or any previous orthodontic, prosthodontic treatment, maxillofacial or plastic surgery.

Class II Subdivision Sample

The OPGs of the 40 subjects (18 male and 22 female) with Class II subdivision malocclusion were selected from patient records and met the following criteria²:

- A complete Class I molar relationship on one side of the dental arch with a full Class II relationship on the other side;
- No previous orthodontic treatment;
- No lateral mandibular shift during closure, as determined by clinical examination;
- No history of facial trauma or medical conditions that could have altered the growth of the apical bases;
- The absence of any severely malaligned or blocked out teeth.

Intraoral photographs and plaster models were used to classify the patients according to their malocclusion. These subjects were also evaluated with clinical histories and examinations. These were selected in clinical evaluations by three examiners.

Since OPGs are routinely used as a screening procedure in this clinic, all subjects had films available for review. These radiographs were exposed with Orthopantomography OP100 (Tuusula, Finland) which had been standardized previously. All were taken in standard manner by the same operator. The subjects were positioned with the lips in rest position and the head oriented to the Frankfort horizontal plane.²

All the films were traced and measured by the same author (YS). The outline of the condyle, the ascending ramus, and corpus of both sides were traced on acetate paper. On the tracing paper, A-line was drawn between the most lateral points of the condylar image (O_1) and of the ascending ramus image (O_2) ([Figure 1](#)). To the A-line (the ramus tangent) from the most superior point of the condylar image, a perpendicular B-line was drawn. The vertical distance from B-line on the “ramus tangent” to the O_1 projected on the ramus tangent was measured. This distance was called the condylar height (CH). The distance between the O_1 and O_2 was called the ramus height (RH). A C-line was constructed as a tangent on corpus mandible of each side, and the angle between A-line and C-line was measured as the gonial angle ([Figure 1](#)). To measure the condylar, ramal, and condylar-plus-ramal asymmetry, the following formula was used:

$$\text{Asymmetry index} = \frac{CH_{\text{right}} - CH_{\text{left}}}{CH_{\text{right}} + CH_{\text{left}}} \times 100$$


Statistical Analysis


Four weeks after the first measurements, 20 randomly selected OPGs were remeasured. A paired-samples *t*-test was applied to the measurements. The difference between the first and second measurements of the 20 radiograms was insignificant. Correlation analysis yielded the highest *r* value, 0.995, for right gonial angle measurement and the lowest *r* value, 0.878, for left condylar height measurements. The method error was calculated by using Dahlberg's formula. Values ranged from 0.399 to 0.974 and were within acceptable limits.

All statistical analyses were performed using the SPSS software package (Statistical Package for Social Sciences for Windows, version 10.1, SPSS Inc, Chicago, Ill). Descriptive statistics were computed. The Kruskal-Wallis test was used to determine the possible statistically significant differences between the groups for condylar, ramal, and condylar-plus-ramal asymmetry index measurements. Identified differences between groups were further analyzed using the Mann-Whitney *U*-test at the 95% confidence interval ($P < .05$).

RESULTS [Return to TOC](#)

According to the Mann-Whitney *U*-test, no gender-related difference was found for any vertical height, for the gonial angle, and for any of the asymmetry indices in intragroup comparisons. Therefore, data for both genders were pooled.

Comparison of condylar, ramal, and condylar-plus-ramal measurements and gonial angle for Class I and Class II sides in the Class II subdivision group and for right and left sides in the Class I group did not show any statistically significant differences ([Table 2](#) ) .

Descriptive statistics (mean, standard deviation, minimum, and maximum) and statistical comparisons of variables between normal occlusion and Class II subdivision groups are shown in [Table 3](#)  . The statistical analysis showed that asymmetry measurements were affected by the investigated occlusion type. Condylar, ramal, and condylar-plus-ramal height measurements showed statistically significant differences ($P < .001$) between groups. However, gonial angle and index measurements did not show any statistically significant differences.

DISCUSSION [Return to TOC](#)

OPG has been used for the assessment of side-to-side height differences and the measurement of condylar, ramal, and total heights to define side-to-side asymmetries.⁹⁻¹⁸ Bilateral views of the mandible can be obtained with OPG, and vertical measurements can be achieved.²⁰ The use of panoramic radiographs to evaluate side-to-side differences is questionable, but a number of studies have been made that supported the use of the panoramic technique.^{9,10,21} These reports suggested that acceptable results can be achieved with panoramic radiographs which are noninvasive, have a favorable cost-benefit relationship, and expose subjects to relatively low doses of radiation.²²

Studies²³⁻²⁴ have shown the posteroanterior cephalometric (PA) film to have some limitations of methodology and reliability. The submental vertex (SMV) view has been suggested²⁵⁻²⁶ as a better alternative for the cephalometric assessment of asymmetry. However, the SMV is capable of significant distortion,^{23,27} especially in the analysis of mandibular asymmetry, since the mandible is positioned farthest from the film plane. While still useful in comparative research studies of asymmetry, both PA and SMV roentgenograms may have limited value in orthodontic diagnosis and treatment planning for the individual.²⁸ In a recent study, Kambylafkas et al²² showed that OPGs could be used to assess vertical posterior mandibular asymmetries.

The reproducibility of vertical and angular measurements on OPG is acceptable if the patient's head is positioned properly in the equipment.^{17,29,30} Habets et al¹⁰ concluded that the headholder must be fixed well to the orthopantomograph, and the head has to be well centered in the headholder of the orthopantomograph when a clinical orthopantomograph is to be evaluated. In this study, all the films were taken in ideal conditions and inadequate or poor quality films were excluded.

Studies of the etiology of condylar asymmetries in which gender differences have been investigated also revealed no statistically significant differences.^{9,15} In this study, no gender related statistically significant differences were found between compared sides and investigated groups. These findings support the studies of Habets et al,⁹ Kiki et al¹⁷ and Sezgin et al¹⁸ that used the same method described in the present study.

Condylar, ramal, and condylar-plus-ramal height values were higher in the Class II subdivision group than the normal occlusion group, and the differences were statistically significant ($P < .001$). In the literature,^{9,17,18} all investigations were carried out on only condylar, ramal, and condylar-plus-ramal asymmetry index, and there is no study that evaluated the posterior vertical heights with the method used in this study, so that our findings could not be compared. However, the measurements done in different studies regarding the ramus length showed that vertical measurements in ramus have higher values in Class II subdivision patients compared with normal occlusion patients.^{6,7}

The method described by Habets et al⁹ has been used for evaluating condylar and ramal asymmetries in TMD patients and in different malocclusions.⁹⁻¹⁸ Habets et al¹⁰ found that asymmetry index values greater than 3% must be taken into consideration as vertical asymmetries because of technical errors during film exposure. In this study, in Class II subdivision and control groups, condylar asymmetry indexes were found above 3% ($11.56 \pm 10.75\%$ and $7.57 \pm 8.39\%$, respectively) indicating asymmetry, but the difference was statistically insignificant.

Other studies evaluating condylar asymmetry with this method in different malocclusions and in TMD patients also found asymmetry values greater than 3% both in study and control groups.¹²⁻¹⁶ These high values indicating asymmetry both in experimental and control groups can be attributed to shape, angular and positional differences between right and left condyles without any pathology or without any related malocclusion.³¹ Cohlmia et al³² found that left condyle was positioned more anteriorly than the right condyle and Yale³¹ showed the shape and angular differences of condyles. On the other hand, Kambylafkas et al²² stated in a recent study that condylar height was unreliable when determining asymmetry from the panoramic radiograph because of the small dimension of the measurement and operator error in tracing and identifying landmarks.

Gonial angle, ramal index, and condylar-plus-ramal index measurements used for evaluating posterior vertical dimensions of the mandible were found similar between the two groups and any differences were statistically insignificant. The findings of our study support the other studies that concluded the mandible in Class II subdivision malocclusions does not exhibit unusual skeletal positioning or skeletal asymmetry.⁴⁻⁷ In the present study, no dentoalveolar measurements were done, but the absence of any vertical asymmetry in the vertical posterior heights of the mandible supports the idea that the contributing factor of asymmetrical anteroposterior molar relationship on the Class II side is mainly dentoalveolar. Azevedo et al⁷ compared the degree of skeletal asymmetry between subjects with Class II subdivision malocclusion and subjects with normal occlusion. They reported that the main component of the Class II subdivision is dentoalveolar, primarily distal positioning of the first mandibular molar on the Class II side and secondarily mesial positioning of the maxillary molar on the same side even though the patients had apparent facial asymmetry.

In the absence of moderate to severe skeletal asymmetries in Class II subdivision patients, dentoalveolar treatment approaches must be taken into consideration. Janson et al³³ suggested three premolar asymmetric extraction treatments in Class II subdivision patients. This treatment protocol can yield to shorter treatment time than four premolar extractions and tends to correct midline deviations due to asymmetric molar relationship with minimum incisor retraction more successfully.³ In the existence of moderate to severe skeletal asymmetries, ie, hemifacial microsomia patients, more diagnosis is needed for understanding the source of the problem.

CONCLUSIONS [Return to TOC](#)

- Ramal index, condylar-plus-ramal index, and gonial angle measurements representing posterior vertical mandibular heights were similar between the two groups.
- Condylar asymmetry index values in the Class II subdivision group and the normal occlusion group were not statistically significantly different. This indicates that the mandibles in Class II subdivision malocclusions do not exhibit unusual skeletal positioning or skeletal asymmetry.

REFERENCES [Return to TOC](#)

1. Angle EH. Classification of malocclusion. *Dental Cosmos*. 1899; 41:248–264.
2. Wertz RA. Diagnosis and treatment planning of unilateral Class II malocclusions. *Angle Orthod*. 1975; 45:85–94.
3. Turpin DL. Correcting the Class II subdivision malocclusion, Commentary. *Am J Orthod Dentofacial Orthop*. 2005; 128:555–556.
4. Alavi DG, BeGole EA, Schneider BJ. Facial and dental arch asymmetries in Class II subdivision malocclusion. *Am J Orthod Dentofacial Orthop*. 1988; 93:38–46.
5. Rose JM, Sadowsky C, BeGole EA, Moles R. Mandibular skeletal and dental asymmetry in Class II subdivision malocclusions. *Am J Orthod Dentofacial Orthop*. 1994; 105:489–495.
6. Janson GR, Metaxas A, Woodside DG, de Freitas MR, Pinzan A. Three-dimensional evaluation of skeletal and dental asymmetries in Class II subdivision malocclusions. *Am J Orthod Dentofacial Orthop*. 2001; 119:406–418.
7. Azevedo AR, Janson G, Henriques JF, Freitas MR. Evaluation of asymmetries between subjects with Class II subdivision and apparent facial asymmetry and those with normal occlusion. *Am J Orthod Dentofacial Orthop*. 2006; 129:376–383.
8. Janson G, de Lima KJ, Woodside DG, Metaxas A, de Freitas MR, Henriques JF. Class II subdivision malocclusion types and evaluation of their asymmetries. *Am J Orthod Dentofacial Orthop*. 2007; 131:57–66.
9. Habets LL, Bezuur JN, Naeiji M, Hansson TL. The Orthopantomogram, an aid in diagnosis of temporomandibular joint problems. II. The vertical symmetry. *J Oral Rehabil*. 1988; 15:465–471.
10. Habets LLMH, Bezuur JN, VanOoij CP, Hansson TL. The orthopantomogram, an aid in diagnosis of temporomandibular joint problems. I. The factor of vertical magnification. *J Oral Rehabil*. 1987; 14:475–480.
11. Miller VJ. Condylar asymmetry and handedness in patients with temporomandibular disorders. *J Oral Rehabil*. 1997; 24:549–551.
12. Miller VJ, Zeltser R, Zeltser CH, Yoeli Z. The condylar asymmetry-age relationship in determining myogenous or arthrogenous origin of pain in patients with temporomandibular disorders. *J Oral Rehabil*. 1996; 23:392–394.
13. Miller VJ, Smidt A. Condylar asymmetry and age in patients with an Angle's Class II division 2 malocclusion. *J Oral Rehabil*. 1996; 23:712–715.
14. Miller VJ, Bodner L. Condylar asymmetry measurements in patients with an Angle's Class III malocclusion. *J Oral Rehabil*. 1997; 24:247–249.
15. Saglam AM. The condylar asymmetry measurements in different skeletal patterns. *J Oral Rehabil*. 2003; 30:738–742.
16. Saglam AA, Sanli G. Condylar asymmetry measurements in temporomandibular disorders. *J Contemp Dent Pract*. 2004; 5:59–65.
17. Kiki A, Kilic N, Oktay H. Condylar asymmetry in bilateral posterior crossbite patients. *Angle Orthod*. 2007; 77:77–81.
18. Sezgin OS, Celenk P, Arici S. Mandibular asymmetry in different occlusion patterns. *Angle Orthod*. 2007; 77:803–807.
19. Uysal T. Erişkin Türk Toplumunda Dentofacial Yapıların İdeal Transversal Boyutlarının Model ve Posteroanterior Sefalometrik Filmler Aracılığıyla Değerlendirilmesi [PhD thesis]. Konya, Turkey: Selcuk University, Health Science Institute; 2003.
20. Wabeke KB, Spruijt RJ, Habets LL. Spatial and morphologic aspects of temporomandibular joints with sounds. *J Oral Rehabil*. 1995; 22:21–27.
21. Bezuur JN, Habets LL, Hansson TL. The recognition of craniomandibular disorders; condylar symmetry in relation to myogenous and arthrogenous origin of pain. *J Oral Rehabil*. 1989; 16:257–260.
22. Kambylafkas P, Murdock E, Gilda E, Tallents RH, Kyrkanides S. Validity of panoramic radiographs for measuring mandibular asymmetry. *Angle Orthod*. 2006; 76:388–393.
23. Cook JT. Asymmetry of the craniofacial skeleton. *Br J Orthod*. 1980; 7:33–38.
24. Richardson ME. The reproducibility of measurements on depressed posteroanterior cephalometric radiographs. *Angle Orthod*. 1967; 37:48–51.
25. Berger H. Problems and promises of basilar view cephalograms. *Angle Orthod*. 1961; 31:237–245.
26. Forsberg CT, Burstone CJ, Hanley KJ. Diagnosis and treatment planning of skeletal asymmetry with the submental-vertical radiograph. *Am J Orthod*. 1984;

27. Williamson EH, Simmons MD. Mandibular asymmetry and its relation to pain dysfunction. *Am J Orthod.* 1979; 76:612-617.

28. Peck S, Peck L, Kataja M. Skeletal asymmetry in esthetically pleasing faces. *Angle Orthod.* 1991; 61:43-48.

29. Larheim TA, Svanaes DB. Reproducibility of rotational panoramic radiography: mandibular linear dimensions and angles. *Am J Orthod Dentofacial Orthop.* 1986; 90:45-51.

30. Larheim TA, Svanaes DB, Johannessen S. Reproducibility of radiographs with the orthopantomograph 5: tooth length assessment. *Oral Surg Oral Med Oral Pathol.* 1984; 58:736-741.

31. Yale SH. Radiographic evaluation of the temporomandibular joint. *J Am Dent Assoc.* 1969; 79:102-107.

32. Cohlma JT, Ghosh J, Sinha PK, Nanda RS, Currier GF. Tomographic assessment of temporomandibular joints in patients with malocclusion. *Angle Orthod.* 1996; 66:27-35.

33. Janson G, Cruz KS, Woodside DG, Metaxas A, de Freitas MR, Henriques JFC. Dentoskeletal treatment changes in Class II subdivision malocclusions in submentovertex and posteroanterior radiographs. *Am J Orthod Dentofacial Orthop.* 2004; 126:451-463.

TABLES [Return to TOC](#)

Table 1. Mean and Standard Deviation of Chronological Ages and ANB for Each Group^a

| Groups | Gender | N | Age, Years | | ANB, Degree | |
|----------------------|--------|----|------------|------|-------------|------|
| | | | Mean | SD | Mean | SD |
| Normal occlusion | Male | 16 | 13.38 | 2.31 | 2.42 | 1.14 |
| | Female | 24 | 15.13 | 3.33 | 2.20 | 1.03 |
| | Total | 40 | 14.43 | 3.05 | 2.29 | 1.06 |
| Class II subdivision | Male | 18 | 14.67 | 3.24 | 3.77 | 2.95 |
| | Female | 22 | 14.41 | 3.13 | 3.95 | 2.46 |
| | Total | 40 | 14.53 | 3.14 | 3.87 | 2.66 |

^a N indicates sample size; SD, standard deviation.

Table 2. Statistical Side Comparisons of Normal Occlusion Sample and Class II Subdivision Patients^a

| Variable | Class I Group | | | | Test | Subdivision Group | | | | Test |
|--------------|---------------|------|-----------|------|------|-------------------|------|---------------|------|------|
| | Right Side | | Left Side | | | Class I Side | | Class II Side | | |
| | Mean | SD | Mean | SD | | Mean | SD | Mean | SD | |
| CH | 5.16 | 1.27 | 4.99 | 1.21 | NS | 5.83 | 1.62 | 6.24 | 1.68 | NS |
| RH | 34.28 | 3.65 | 33.61 | 3.94 | NS | 41.55 | 7.66 | 41.04 | 7.72 | NS |
| CH + RH | 39.44 | 3.83 | 38.60 | 3.91 | NS | 47.36 | 7.93 | 47.29 | 8.31 | NS |
| Gonial angle | 125.80 | 7.78 | 126.18 | 7.23 | NS | 124.84 | 6.55 | 125.04 | 6.26 | NS |

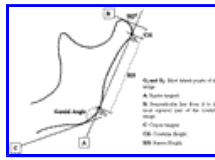
^a SD indicates standard deviation; NS, not significant.

Table 3. Statistical Comparisons of All Asymmetry Measurements Between Class II Subdivision Patients and Normal Occlusion Sample^a

| Variable | Class I Group | | | | Test | Class II Subdivision Group | | | |
|---------------|---------------|-------|--------|--------|------|----------------------------|-------|--------|--------|
| | Mean | SD | Min | Max | | Mean | SD | Min | Max |
| CH | 7.66 | 1.74 | 5.25 | 12.50 | *** | 9.16 | 1.98 | 5.25 | 13.00 |
| RH | 51.09 | 5.43 | 37.50 | 64.50 | *** | 61.91 | 11.33 | 42.75 | 85.25 |
| CH + RH | 58.74 | 5.65 | 45.00 | 72.00 | *** | 71.07 | 11.81 | 53.75 | 95.50 |
| Gonial angle | 188.89 | 11.01 | 166.75 | 212.00 | NS | 187.55 | 9.13 | 170.75 | 207.75 |
| CH index | 7.57 | 8.39 | 0.00 | 38.46 | NS | 11.56 | 10.75 | 0.00 | 41.67 |
| RH index | 2.52 | 2.29 | 0.00 | 8.11 | NS | 2.67 | 2.41 | 0.00 | 11.90 |
| CH + RH index | 2.06 | 1.50 | 0.00 | 5.41 | NS | 2.63 | 2.17 | 0.00 | 10.56 |

^a SD indicates standard deviation; Min, minimum; Max, maximum; NS, not significant.

*** $P < .001$.



[Click on thumbnail for full-sized image.](#)

Figure 1. Measuring method according to Habets et al.⁹

^a Assistant Professor, Department of Orthodontics, Faculty of Dentistry, Erciyes University, Kayseri, Turkey

^b Associate Professor and Chair, Department of Orthodontics, Faculty of Dentistry, Erciyes University, Kayseri, Turkey

^c Assistant Professor and Chair, Department of Oral Diagnosis and Radiology, Faculty of Dentistry, Erciyes University, Kayseri, Turkey

^d Research Assistant, Department of Orthodontics, Faculty of Dentistry, Selcuk University, Konya, Turkey

Corresponding author: Dr Tancan Uysal, Erciyes Üniversitesi Dişhekimliği Fakültesi, Ortodonti A.D. Melikgazi, Kampüs Kayseri, 38039 Turkey (E-mail: tancanuysal@yahoo.com)