

[\[Print Version\]](#)

[\[PubMed Citation\]](#) [\[Related Articles in PubMed\]](#)

TABLE OF CONTENTS

[\[INTRODUCTION\]](#) [\[MATERIALS AND...\]](#) [\[RESULTS\]](#) [\[DISCUSSION\]](#) [\[CONCLUSIONS\]](#) [\[REFERENCES\]](#) [\[TABLES\]](#) [\[FIGURES\]](#)

doi: 10.2319/011707-24.1

The Angle Orthodontist: Vol. 78, No. 1, pp. 95-100.

Duration and Anchorage Management of Canine Retraction with Bodily Versus Tipping Mechanics

Nir Shpack;^a Moshe Davidovitch;^a Ofer Sarne;^a Narchos Panayi;^b Alexander D. Vardimon^c

ABSTRACT

Objective: To compare tipping mechanics (TM) and bodily mechanics (BM) with respect to duration, angulation, and anchorage loss during canine retraction.

Materials and Methods: TM and BM brackets were bonded to the upper right and left canines, respectively, of 14 subjects requiring maxillary first premolar extractions. The upper canines were retracted with variable nickel titanium closed coil springs ($F = 0.50$ or 0.75 N) attached posteriorly to a Nance anchorage appliance through the first molars. Panoramic radiographs and dental casts were taken at five time points. Canine angulation was assessed with custom metallic jigs inserted into the vertical slots of the canine brackets prior to radiographic exposure.

Results: The canine crown contacted the second premolar after 102.2 ± 106 and 99.0 ± 80.0 days, and achieved root uprighting in 72.0 ± 31.3 and 37.2 ± 42.7 additional days with the TM and BM groups, respectively. Only the uprighting stage differed significantly between the two mechanics ($P < .05$). During retraction, tooth angulation differed significantly ($P < .001$) between the TM (6°) and BM (-0.8°) groups. Anchorage loss, as assessed by mesial molar movement, was 1.2 ± 0.3 mm and 1.4 ± 0.5 mm for the TM and BM groups, respectively.

Conclusions: Bodily canine retraction occurred faster (38 days) than tipping due to a shorter duration of root uprighting. Anchorage loss (17%–20%) was similar for both retraction methods, ie, maximum anchorage could not be provided by the Nance appliance. Both TM and BM brackets had inadequate rotational control of the retracted canine.

KEY WORDS: Anchorage, Retraction, Bodily, Tipping, Canine.



Accepted: February 2007. Submitted: January 2007

INTRODUCTION [Return to TOC](#)

Modern orthodontics employs various fixed appliance systems, each with its own advantages and disadvantages. Two of these systems are the edgewise and Begg appliances. The design of the edgewise bracket permits bodily mechanics (BM) resulting in nearly pure bodily movement of teeth due to creation of force couples in the bracket resulting from its rectangular arch wire slot. In contrast, the Begg

bracket, a modified version of Angle's "ribbon arch" appliance, maintains only a point contact with the arch wire, thus facilitating tipping mechanics (TM) of the dental crown or root.¹

Proponents of TM claim that it has several unique advantages. These include, reduced (molar) anchorage loss, decreased treatment time, elimination of extraoral appliances, and reduced risk of root resorption.¹ However, the BM group of appliances has become the most popular fixed orthodontic appliance to date due to its simplified method of exerting first, second, and third order control.²

In an effort to combine aspects of both the classic Begg and edgewise designs, Kesling³ developed the Tip-Edge bracket ([Figure 1](#) ) originally intended for canine retraction in premolar extraction cases. The Tip-Edge bracket is a single wing bracket with a 0.022 × 0.028 inch arch wire slot with disto-incisal and mesio-gingival corners chamfered at a 25° angle. The chamfered corners of the bracket allow for a large amount of tipping during retraction as is practiced in the Begg technique. The Tip-Edge bracket also contains a 0.016 × 0.022 inch vertical slot for the insertion of auxiliaries such as elastic hooks, and uprighting or rotation springs. In the Begg technique the latter tools are used to cause a tendency to rotate in order to affect root uprighting and tooth rotation.³ Additional rotational control is provided by the wing-like extensions of the arch wire slot which serve to increase the mesial-distal dimension of this single-wing bracket ([Figure 1](#) )

The most time-consuming stage of premolar extraction-based orthodontic treatment is canine retraction. Any procedure which reduces the time required to perform this stage will also serve to shorten overall treatment time. Lotzof et al⁴ compared rates of canine retraction using Tip-Edge and edgewise brackets utilizing a 2 N force delivered by frequent replacement of elastic chain. They reported that the rate of canine retraction using the Tip-Edge bracket was slightly faster, and that the anchorage loss with the edgewise bracket was greater than that found with the Tip-Edge bracket. However, they were not able to confirm this claim statistically, nor were differences in root position during canine retraction reported. Kesling⁵ claimed that the conclusions of Lotzof et al⁴ were invalid because of improper levels of force application to the Tip-Edge bracket, reducing its efficiency as a result of an unfavorable biological response (ie, hyalinization).⁵


Smith and Storey⁶ and Streed⁷ reported that during canine retraction 5%–55% of the extraction space can be taken up by mesial movement of the anchorage unit (ie, the first molar and second premolar). Ziegler and Ingervall⁸ compared sliding and nonsliding mechanics during canine retraction and concluded that the mean anchorage loss was 30% for both methods without any significant differences between them. They also found that in both TM and BM approximately 30° of mesiolabial rotation of the canines typically occurred during retraction.


Paulson and Ingervall⁸ performed a laminographic investigation of molar anchorage during canine retraction. A force of 0.50–0.75 N between the molars and canines was used for retraction against a transpalatal arch and cervical headgear (worn nightly). They reported that in five out of the six subjects forward movement of the molars was not significant and concluded that anchorage loss was prevented by the steps taken to counteract it as well as the application of a light force. Geron et al¹⁰ found that anchorage loss is a multifactorial response that is primarily affected by the amount of crowding and mechanics (labial vs lingual), and secondarily by age, location of extraction site, and overjet, in declining order of importance.

The objective of the present study was to compare canine retraction undertaken with tipping and bodily mechanics. Four variables were compared including duration, angulation, rotation, and anchorage loss. The null hypothesis of this study is that no differences exist between TM and BM in the duration of canine retraction at all five time points, nor is there any difference in angulation, rotation, and anchorage loss.

MATERIALS AND METHODS [Return to TOC](#)

This prospective study comprised 14 subjects presenting for orthodontic therapy to the Department of Orthodontics of the University of Tel Aviv, School of Dental Medicine. Their treatment was determined to include the extraction of both maxillary first premolars. Inclusion in the study was pursuant to the receipt of each subject's consent in accordance with the Helsinki protocol.

Prior to undergoing dental extractions, a Nance (button) appliance soldered to the bands of the maxillary first permanent molars was inserted. After extraction of the maxillary first premolars, each subject had 0.022 × 0.028 inch Victory (3M-Unitek, Monrovia, Calif) orthodontic brackets bonded to the incisors and second premolars. For the BM, an edgewise bracket with a vertical slot (Victory #017919 3M Unitek) was bonded to the maxillary left canine. For the TM, a Tip-Edge bracket (#296016; TP Orthodontics, LaPorte, Ind) was bonded to the right ([Figure 2](#) )

A polyvinyl–siloxane impression of the canines with their respective brackets was made to act as a matrix should bracket failure occur in order to facilitate rebonding in the original bracket position. Active canine retraction did not commence until a 0.018-inch stainless steel arch wire was engaged. Canine retraction was accomplished using 0.5 and 0.75 N nickel-titanium closed coil springs (GAC, Central Islip, NY) from the TM and BM brackets, respectively, to the gingival hooks of each respective molar band ([Figure 2](#) )

Root uprighting of the TM canine (right) was achieved with a preformed uprighting spring (TP Orthodontics) inserted into the vertical slot of the bracket and activated by hooking onto the arch wire, whereas the BM canine (left) underwent any necessary root uprighting by the

placement of appropriate second order bends in the arch wire.

Retraction Duration

Experimental data were gathered at the following five time points (comprising three stages):

- T0: prior to canine retraction;
- T1a: when one of the canine crowns contacts the second premolar;
- T1b: when the other canine comes into contact with the second premolar;
- T2a: when one of the canine roots was uprighted; and
- T2b: when the other canine root was deemed to be uprighted.

At each time point, dental cast of the maxillary arch, a panoramic radiograph, and intraoral photographs were obtained for each patient.

Canine Angulation

The panoramic radiographs were taken with jigs made of 0.016 × 0.022 inch stainless steel wire inserted in the vertical slots of the canine brackets. Canine angulation was defined as the angle formed by the intersection of the infraorbital line and a line extending from the jig placed into the vertical slots of each canine ([Figure 3](#)).¹¹

Canine Rotation

Rotational change in canine position was measured from the dental casts using the method of Ziegler and Ingervall.⁸ The angle formed between a line through the distal and mesial contact points of the canine, and the midpalatal raphe was measured at T0 and T2 ([Figure 4](#)).

Anchorage Loss

Change in sagittal position of the maxillary first molar was also assessed from the dental casts. A transferable reference was fabricated using an acrylic mold of the palatal raphe, anatomically fitted for each subject, in which were embedded and had extending from it wires directed to the central fossa of the first permanent molar of the pretreatment dental cast ([Figure 5](#)).⁴ This device was hence placed on the same site on final dental casts (T2) upon which could be measured differences in the location of the molars from T0 to indicate the extent of anchorage loss.

Statistic Analyses

Descriptive statistics including mean values and standard deviations were calculated. Multivariate analysis of variance (MANOVA) with repeated measures and paired *t*-test were performed to evaluate the differences between the groups. A *P* value < .05 was considered statistically significant.


RESULTS [Return to TOC](#)

Duration of Canine Retraction


The time required to retract the canine crown until its contact with the second premolar (T0–T1), is shown in [Table 1](#). This took 102.2 ± 106 and 99.0 ± 80.0 days in the TM and BM groups, respectively. Root uprighting (T1–T2) took 72.0 ± 31.3 and 37.2 ± 42.7 days in the TM and BM groups, respectively ([Table 1](#)). Comparison of the mean values between the groups during T0–T1 and T1–T2 determined that their differences were statistically significant only during the uprighting stage (*P* < .05). The mean time required to achieve crown retraction and root uprighting (T0–T2) was 174.2 ± 98.3 and 136.2 ± 104.5 days for the TM and BM groups, respectively. However, the difference in total time between the two types of mechanics was not statistically significant ([Table 1](#)).


Angulation

Angular changes in canine position were measured from the panoramic radiographs using the radiopaque jigs ([Figure 3](#)). During retraction (T0–T1) the canine tipped by 6.1° (from 91° ± 5.7° to 97.1° ± 8.5°) in the TM group and by –0.8° (from 93.8° ± 4.9° to 93.0° ±

6.0°) in the BM group, demonstrating a significant intergroup difference ($P < .001$). During root uprighting (T1–T2), the canine moved by -3.3° (from $97.1^\circ \pm 8.5^\circ$ to $93.8^\circ \pm 5.6^\circ$) in the TM group and by 1.2° (from $93.0^\circ \pm 6.0^\circ$ to $94.2^\circ \pm 6.5^\circ$) in the BM group, demonstrating a significant intergroup difference ($P < .05$) ([Table 2](#) )


Rotation

During retraction (T0–T1), the canine rotated distopalatally by 15.4° (from $151.2^\circ \pm 12.3^\circ$ to $166.6^\circ \pm 16.0^\circ$) in the TM group, and by 18° (from $148.8^\circ \pm 12.1^\circ$ to $166.8^\circ \pm 17.9^\circ$) in the BM group. During root uprighting (T1–T2), the canine continued to rotate by 3.1° (from $166.6^\circ \pm 16.0^\circ$ to $169.7^\circ \pm 16.0^\circ$) in the TM group and by 2.2° (from $166.8^\circ \pm 17.9^\circ$ to $169.0^\circ \pm 16.6^\circ$) in the BM group ([Table 3](#) )

No statistically significant difference existed when comparing the amounts of rotation between groups ([Table 3](#) )

However, within each group the amount of rotation, as canine retraction progressed, was found to be statistically significant ($P < .001$).

Anchorage Loss

Anterior movement of the maxillary first permanent molar (ie, loss of anchorage) as a result of total canine retraction (T0–T2) as measured directly from dental casts was 1.2 ± 0.3 mm in the TM group and 1.4 ± 0.5 mm in the BM group ([Table 4](#) )

Differences in the amount of forward movement of the first molars between the two groups were not statistically significant.


DISCUSSION [Return to TOC](#)

The velocity of tooth movement during orthodontic treatment depends on various factors. For example, the level of cellularity or density of alveolar bone,¹² formation of hyalinized tissue adjacent to the dental root due to the application of “excessive” mechanical force,¹³ or the discontinuation of force application¹⁴ causing an interruption of the “initial strain-lag phase-undermining resorption” cycle of tooth movement,¹⁵ as well as the magnitude of force applied.¹⁶ Differences in the methodology of force application have been proposed to maximize the speed of orthodontic treatment while eliciting a biologically sound response.

Using constant force levels (nickel titanium closed coil springs) together with anchorage enhancement (Nance button), the responses of canine retraction into maxillary first premolar extraction sites using Tip-Edge and edgewise mechanics were compared. Differing levels of force (lighter on the TM side) were employed in order to resolve the criticism of previous investigations,^{4,17} which did not differentiate between the bracket types and the forces applied. Under these conditions, it was found that the crowns of canines in each group contacted the second premolar within similar times (99 vs 102 days, ie, a 3-day difference). However, in this study it was found that the need for root uprighting of canines retracted with tipping mechanics, resulted in significantly greater time (38 days) for complete canine retraction in comparison to the bodily mechanics, thus rejecting the null hypothesis. It is possible that the center of rotation using TM bracket lies inferior to the apex, ie, the apex is displaced mesially. If the apex is displaced mesially, obviously this will increase the total time involved, as there will be more uprighting required.

The findings regarding crown retraction are in agreement with those of Lotzof et al⁴ and Huffman and Way.¹⁷ However, the time required to accomplish root uprighting, which was not evaluated by previous studies, but analyzed here, differentiates between the two groups ($P < .05$). The additional time required to upright the root during the uprighting phase (T1–T2) in the TM group can be explained by the greater distal crown tip (6.1°) observed in this group as compared to the essentially parallel root movement of the BM group (-0.8°) during the retraction phase (T0–T1). These findings reject the null hypothesis and correspond to the effect for which each of these bracket types was designed to achieve.

Retraction of the canine tooth with a force labial to its center of resistance will cause a tendency for the tooth to rotate distopalatally. Rotation control with single wing brackets is thought to be less than that of twin/Siamese brackets. However, the amount of rotation incurred by the canines during retraction was not found to differ significantly between the two groups, corroborating the null hypothesis. Of interest is the fact that during the uprighting stage (T1–T2), the rotation did not correct. This emphasizes the need to apply compensating rotation measures subsequent to the uprighting stage (after T2).

The effect of the strain on the posterior anchorage teeth used to retract the canines was determined from initial (T0) and final (T2) dental casts. It was found that molar anchorage loss occurred to the same extent in both groups accepting the null hypothesis ([Table 4](#) )

Geron et al¹⁰ found an anchorage loss of 3.9 ± 2.3 mm by the end of orthodontic treatment in patients treated with extraction of upper first premolars. This suggests that the majority of molar anchorage loss does not occur during canine retraction when the Nance appliance is in place (33%), rather during incisor retraction when the Nance appliance is removed (67%). However, in calculating space management, 17%–20% of the extraction space is lost due to protraction of the anchorage segment despite the placement of a Nance button appliance. Perhaps an appliance, which rests on the palatal mucosa, should not be relied upon to provide maximum anchorage.

CONCLUSIONS [Return to TOC](#)

- Retraction of the maxillary canine into the first premolar extraction site using nickel titanium closed coil springs occurred faster with BM brackets than with TM brackets.
- Significantly greater time was required to fully upright the canines with TM brackets. This greater time corresponded with the amount of distal crown tipping expressed by these teeth during retraction.
- No differences were found in the amount of molar anchorage loss between the two groups.
- The Nance appliance was not found to provide absolute (maximum) anchorage.
- Rotational control of the retracted canines was similar and insufficient within both groups. A derotation phase should be followed once canine retraction has been completed.

REFERENCES [Return to TOC](#)

1. Begg PR. Light arch wire technique. *Am J Orthod.* 1961; 47:30–48.
2. Proffit W. *Contemporary Orthodontics.* St Louis, Mo: Mosby; 1992:344–346.
3. Kesling PC. Expanding the horizons of the edgewise arch wire slot. *Am J Orthod Dentofacial Orthop.* 1986; 94:26–37.
4. Lotzof L, Fine H, Cisneros G. Canine retraction. A comparison of two preadjusted bracket systems. *Am J Orthod Dentofacial Orthop.* 1996; 110:191–196.
5. Kesling PC. Comments on canine retraction and bracket angulations. *Am J Orthod Dentofacial Orthop.* 1997; 111:14A–16A.
6. Smith R, Storey E. Force in orthodontics and its relation to tooth movement. *Austr J Dent.* 1952; 56:11–18.
7. Streed S. *A Method of Measuring Clinical Orthodontic Tooth Displacement* [thesis]. Minneapolis, MN: University of Minnesota; 1964.
8. Ziegler P, Ingervall B. A clinical study of maxillary canine retraction with a retraction spring and with sliding mechanics. *Am J Orthod Dentofacial Orthop.* 1989; 95:99–106.
9. Paulson R, Speidal T, Isaacson R. A laminographic study of cuspid retraction versus molar anchorage loss. *Angle Orthod.* 1970; 40:110–115.
10. Geron S, Shpack N, Kandos S, Davidovitch M, Vardimon AD. Anchorage loss—a multifactorial response. *Angle Orthod.* 2003; 73:730–737.
11. Weber J, Almeida R, Tavano O, Fernando H. Assessment of mesiodistal inclination through panoramic radiography. *J Clin Orthod.* 1991; 24:304–306.
12. Reitan K. Effects on force magnitude and direction of tooth movement on different alveolar bone types. *Angle Orthod.* 1964; 34:244–247.
13. Reitan K. Clinical and histological observation on tooth movement during and after orthodontic treatment. *Am J Orthod.* 1967; 53:721–745.
14. Graber T, Vanarsdall R. *Orthodontics, Current Principles and Techniques.* St Louis, Mo: Mosby; 1994:215–216.
15. Burstone CJ. The biomechanics of tooth movement. In: Krauss BS, Riedel RA, eds. *Vistas in Orthodontics.* Philadelphia, PA: Lea & Febiger; 1962:197–213.
16. Reitan K. Some factors determining the evaluation of forces in orthodontics. *Am J Orthod.* 1957; 43:32–45.
17. Huffman JD, Way D. A clinical evaluation of tooth movement along arch wires of two different sizes. *Am J Orthod.* 1983; 83:453–459.

TABLES [Return to TOC](#)

Table 1. Duration of Canine Retraction (T0–T1), Uprighting (T1– T2), and Total Treatment (T0–T2) and Level of Significance for the

Stage	Duration of Retraction		P Value
	Tipping Mechanics, Days	Bodily Mechanics, Days	
T0-T1	102.2 ± 106.0	99.0 ± 80.0	.93
T1-T2	72 ± 31.3	37.2 ± 42.7	.02
T0-T2	174.2 ± 98.3	136.2 ± 104.5	.33

Table 2. Change in Canine Angulation During Retraction (T0-T1), Uprighting (T1-T2), and Total Treatment (T0-T2) and Level of Significance for the Tipping Mechanics (TM) and Bodily Mechanics (BM) Systems

Stage	Angulation		P Value
	Tipping Mechanics, Degrees	Bodily Mechanics, Degrees	
T0	91.0° ± 5.7°	93.8° ± 4.9°	
T1	97.1° ± 8.5°	93.0° ± 6.0°	
T0-T1	6.1°	-0.8°	.001
T2	93.8° ± 5.6°	94.2° ± 6.5°	
T1-T2	-3.3°	1.2°	.018
T0-T2	2.8°	0.4°	.05

Table 3. Change in Canine Rotation During Retraction (T0-T1), Uprighting (T1-T2), and Total Treatment (T0-T2), and Level of Significance for the Tipping Mechanics (TM) and Body Mechanics (BM) Systems


Stage	Rotation		P Value
	Tipping Mechanics, Degrees	Bodily Mechanics, Degrees	
T0	151.2° ± 12.3°	148.8° ± 12.1°	
T1	166.6° ± 16°	166.8° ± 17.9°	
T0-T1	15.4°	18°	NS
T2	169.7° ± 16.0°	169.0° ± 16.6°	
T1-T2	3.1°	2.2°	NS
T0-T2	18.5°	20.2°	NS

NS indicates not significant.

Table 4. Anchorage Loss for the Total Treatment Time (T0-T2) and Level of Significance for the Tipping Mechanics (TM) and Bodily Mechanics (BM) Systems

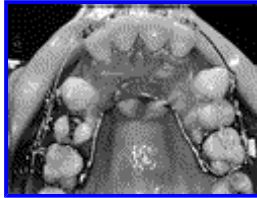Stage	Anchorage		P Value
	Tipping Mechanics, mm	Bodily Mechanics, mm	
T0-T2	1.2 ± 0.3	1.4 ± 0.5	NS

NS indicates not significant.



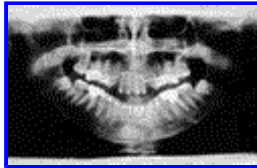
[Click on thumbnail for full-sized image.](#)

Figure 1. Tip-Edge bracket. Vertical slot (a) for the insertion of auxiliaries such as hooks, uprighting and rotation springs. Disto-incisal and mesio-gingival corners chamfered at 25° (b), and wing-like extensions of the arch wire slot (c)



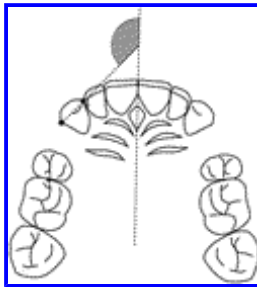
[Click on thumbnail for full-sized image.](#)

Figure 2. Canine retraction carried out with a tipping mechanics (TM, right) and bodily mechanics (BM, left) bracket using nickel-titanium closed coil springs. The left canine has contacted the second premolar and root uprighting is occurring. A Nance appliance is also present




[Click on thumbnail for full-sized image.](#)

Figure 3. Panoramic radiograph with jigs inserted in the vertical slots as landmarks for canine angulation in relation to the infra-orbital line



[Click on thumbnail for full-sized image.](#)

Figure 4. Canine rotation, defined as the angle formed by a line through the distal and mesial contact points of the canine to the mid-palatal raphe



[Click on thumbnail for full-sized image.](#)

Figure 5. The acrylic mold of the palate with two wires projected to the central fossa of the first molars of the initial dental cast (a = T0), and transferred to the final dental cast (b = T2) to determine the amount of anchorage loss

^a Instructor, Department of Orthodontics, The Maurice and Gabriela Goldschleger School of Dental Medicine, Tel Aviv University, Tel Aviv, Israel

^b At present, private practice, Limassol, Cyprus; former Graduate student (MS), Department of Orthodontics, The Maurice and Gabriela Goldschleger School of Dental Medicine, Tel Aviv University, Tel Aviv, Israel

^c Professor and Department Head, Department of Orthodontics, The Maurice and Gabriela Goldschleger School of Dental Medicine, Tel Aviv University, Tel Aviv, Israel

Corresponding author: Dr Nir Shpack, School of Dental Medicine, Department of Orthodontics, Tel Aviv University, Tel Aviv, Israel 69978 (E-mail: nshpack@post.tau.ac.il)