

[\[Print Version\]](#)

[\[PubMed Citation\]](#) [\[Related Articles in PubMed\]](#)

TABLE OF CONTENTS

[\[INTRODUCTION\]](#) [\[MATERIALS AND...\]](#) [\[RESULTS\]](#) [\[DISCUSSION\]](#) [\[CONCLUSIONS\]](#) [\[REFERENCES\]](#) [\[TABLES\]](#) [\[FIGURES\]](#)

doi: 10.2319/071007-320.1

The Angle Orthodontist: Vol. 78, No. 5, pp. 778-785.

Incisor Root Resorption Due to Ectopic Maxillary Canines

A Long-Term Radiographic Follow-Up

Babak Falahat,^a Sune Ericson,^b Rozmary Mak D'Amico,^c Krister Bjerklin^d

ABSTRACT

Objective: To document the long-term fate of maxillary incisors with resorbed roots after correction of the associated ectopic canines.

Materials and Methods: The subjects were recruited from 107 children and adolescents age 9–15 years (mean 12.5 years) at initial registration, with 156 ectopically positioned maxillary canines. The children were referred to the specialist orthodontic clinic for consultation because of the risk of incisor root resorption. Of 51 patients contacted, 16 failed to attend. Eight of the remaining 35 were excluded because their lateral incisors had been extracted, leaving 27 subjects for follow-up registration. At initial consultation, all subjects had undergone radiographic examination, including computed tomography (CT) scans. At the follow-up consultation, the radiographic examination was limited to intraoral films.

Results: No resorbed incisor was lost during the 2- to 10-year follow-up period. The resorptive lesions had undergone repair in 13 teeth, remained unchanged in 12 teeth and progressed in 7 teeth. In the 13 teeth exhibiting signs of repair, no resorption was detectable in 11 teeth and minor resorption was detected in 2 lateral incisors. At the initial registration, severe or moderate resorption had been diagnosed in 12 lateral and 5 central incisors, compared with 11 lateral and 6 central incisors at follow-up. In 10 subjects initially diagnosed with resorption of 13 incisors, the lesions were no longer discernible on intraoral radiographs at follow-up.

Conclusions: Even in cases of severe resorption, the incisor roots show good long-term healing. Incisors with root resorption can be used in an orthodontic appliance system.

KEY WORDS: Maxillary canine, Root resorption, Maxillary incisor, Computed tomography, Ectopic eruption, Tooth root.

Accepted: September 2007. Submitted: July 2007

INTRODUCTION [Return to TOC](#)

The frequency of unerupted ectopic maxillary canines is 1%–2%,^{1–6} with ethnic variations.⁷ Associated root resorption of permanent maxillary incisors occurs in 48% of children between 9 and 15 years of age.⁸

Resorption of the incisor roots is almost impossible to diagnose clinically because of lack of symptoms. A further complication is that it is often difficult to detect the condition on conventional radiographs, such as intraoral and panoramic films, because of superimposition of the malpositioned canine. Especially when the canine is buccal or palatal to the incisor root, the injury may be obscured.^{9–11} Even in cases without overlapping teeth, resorption on the palatal side of the incisor root may be difficult to detect on intraoral radiographs.¹²

The use of computed tomography (CT) circumvents the limitations of conventional radiography since CT detects 50% more cases of resorption than intraoral and panoramic radiography.⁹ A study comparing treatment plans compiled with and without information from a CT investigation disclosed that the

evidence obtained from the CT investigation¹³ resulted in changes in the treatment plans 43% of the time.

In cases of ectopic, impacted canines, associated root resorption of the adjacent maxillary incisors is a serious complication which may lead to extraction of incisors, or time-consuming and expensive treatment, including surgical exposure of the canine and orthodontic repositioning of the maxillary teeth, or both.^{13–16} When root resorption occurs, various factors determine the choice of therapy for the particular child, not least of which is the severity and site of the resorptive lesion on the incisor root. Thus, orthodontic treatment planning should include detailed examination to determine the presence of resorption of incisor roots and if so, the site and severity of the resorption.

With respect to the response of incisors with resorbed roots following treatment of impacted canines, a 1-year follow-up study of a small sample of children (11 girls) by Becker and Chaushu¹⁷ suggested that once the impacted canine has been treated, there is no risk for further resorption.

As to whether in the long term the resorptive lesions undergo progression, arrest, or repair, little information is available. Analysis of the long-term outcomes in a larger sample would allow the compilation of evidence-based guidelines to support the orthodontist in therapy planning.


The aim of this study was to use radiographs to evaluate and describe the long-term fate, healing, and restitution of resorbed maxillary incisor roots after correction of the adjacent ectopically positioned canine.


MATERIALS AND METHODS [Return to TOC](#)

Subjects

The original subjects comprised 107 children and adolescents, 9–15 years old (mean age 12.5 years) at initial registration, with 156 ectopically positioned maxillary canines. The children had been referred to the specialist orthodontic clinic for consultation because of the risk of incisor root resorption associated with the ectopically positioned canines. Clinical and radiographic examinations established the diagnoses. The radiographic examinations included CT scanning in all cases in order to determine the possible presence, site, and severity of resorptive lesions on the incisor roots. The examinations resulted in a diagnosis of resorption in 51 children: the affected teeth comprised 58 lateral and 14 central incisors.⁸

For the follow-up study, we were able to examine 35 of the 51 children (10 boys and 25 girls); the other 16 failed to appear for scheduled appointments or had moved out of the district. Of the 35 subjects we examined, 8 with bilateral resorption of the maxillary lateral incisors were excluded because these teeth had been extracted. Thus, for the follow-up we are able to report on the results in 27 subjects.

The 27 children (7 boys and 20 girls) had root resorption on 24 lateral and 8 central incisors. Severe resorption, ie, resorption to or through the pulp was diagnosed in 11 teeth and slight, superficial resorption in 15 teeth ([Table 1](#) ) .

The resorptive lesions were located lingually or distolingually in 17 of the 32 incisors and on the buccal or distobuccal aspects of 6 incisors. In 17 of the 32 resorbed incisor roots, the lesion was in the middle third ([Table 2](#) ) . All resorbed incisors responded positively to vitality testing. The impacted canines had been surgically exposed and treated with fixed orthodontic appliances.²²

The interval elapsing between completion of treatment and the follow-up registrations ranged from 2 to 10 years, with a mean of 3.5 years. The mean age at follow-up was 18.8 years (SD 3.51).

Methods


All children had undergone a radiographic examination, including CT scans at the initial consultation, to determine the presence, location, and severity of any resorption on the incisor roots. The severity of resorption was graded as:


Slight—up to half the dentine thickness

Moderate—midway to the pulp or more, the pulp lining being unbroken, and

Severe—the pulp is exposed.

For a detailed description of the CT procedure and the accuracy of CT in imaging root resorption, see Ericson and Kurol.⁸

Radiographic examination at follow-up was limited to intraoral films (Kodak Ultraspeed), partly because of the lower radiation dose associated with intraoral radiographs, but also because the crown of the canine was no longer superimposed over the incisor root. We exposed three to five films from the right to the left lateral incisor, using a modified parallel technique. The teeth were imaged orthoradially, mesially (mesiocentric projection), and distally (distocentric projection) ([Figure 1](#) ) . In a few cases the intraoral films were complemented by some CT scans for a more detailed description.

Two independent observers, specialists in oral and maxillofacial radiology (Drs Falahat and Ericson) analyzed the radiographs. In case of disagreement, consensus was reached by discussion. During the initial interpretation the observers had no access to the primary radiographs and no knowledge of which incisors had been resorbed, nor the resorption site. In a second phase comparisons were made with the radiographs taken before orthodontic treatment or extraction of the canines and with contralateral teeth ([Figure 2](#) ) .

From the follow-up radiographs the following variables were recorded:

- Identification of the resorbed area

- Changes within the resorption site
- Signs of inflammatory changes
- Pulp chamber width
- Signs of ankylosis
- Periodontal membrane and lamina dura
- Root length

We used percussion tests from the right to the left maxillary first premolars to analyze whether the sounds were normal or ankylosed. We also conducted vitality tests on each tooth from the right to the left maxillary lateral incisors using an electric vitality scanner (Analytic Technology, model 2006, Redmond, WA). For clinical report, see Mak D'Amico et al.²²

Statistical Analysis

We analyzed the data using an SPSS computer program (version 13.0, SPSS Inc, Chicago, Ill) and studied distribution and relationships with chi-square test with Fisher's exact test.¹⁸

RESULTS [Return to TOC](#)

The results showed that no resorbed incisor had been lost during the 2- to 10-year follow-up period.

The resorptions had undergone repair in 13 teeth, remained unchanged in 12 teeth and increased in 7 teeth ([Table 3](#)). Of the 7 incisors with increased resorption, none exhibited reduced vitality or ankylosis percussion sounds. In the 13 teeth exhibiting signs of repair, no resorption was detectable in 11 teeth and slight resorption in 2 lateral incisors. At the initial registration, severe or moderate resorption had been diagnosed in 12 lateral and 5 central incisors, compared with 11 lateral and 6 central at follow-up ([Table 4](#)).

There were no clinical or radiographic signs of periradicular (apical) periodontitis. In one case in which the ectopically positioned canine had been extracted, the marginal bone was intact, but there had been some loss of bone height. For the other incisors, even if the resorption site was in the cervical part of the root, there was no marginal bone loss and the restitution of the root cementum was evident ([Figures 3](#) and [4](#)).

One lateral incisor showed reduced vitality and pulpal obliteration ([Figure 2](#)). In all other resorbed incisors the pulpal width was unchanged even when the resorption cavity touched the pulpal chamber ([Figure 4](#)).

The results of the present study indicated that root resorption associated with ectopic canines did not threaten 2 to 10 years of long-term viability of the affected incisors.

One lateral and one central incisor exhibited ankylosis percussion sounds, and the latter also showed radiographic evidence of ankylosis ([Figure 3](#)). Except in the latter case, the periodontal contour of the incisors was intact, within normal limits and with reestablished lamina dura ([Figures 1](#), [2](#), [4](#), and [5](#)).

There had been remodeling of the damaged root surfaces at the site of the resorption and the primary resorption cavities had become shallower. In 10 subjects with 13 resorbed incisors the resorption defects were no longer discernible on intraoral radiographs ([Table 4](#); [Figure 6](#)).

Compared with unaffected contralateral teeth, the root lengths of the resorbed incisors were normal in 20 of the 32. In three incisors the root was shorter, less than half the length of the contralateral tooth ([Table 5](#)).

DISCUSSION [Return to TOC](#)

Root resorption of permanent maxillary incisors adjacent to ectopically positioned canines, is probably caused by inherent pressure due to migration of the displaced, erupting canine combined with physical contact between the root of the incisor and prominences on the canine crown.^{15,19}

Early detection of canine impaction, diagnosis and assessment of the extent of resorption is of fundamental importance for prevention or early intervention to reduce subsequent complications.^{9,20} Careful clinical supervision is recommended from the age of 9–11 years. In 7%–10% of cases radiographic analysis was necessary to detect the position of the canines.^{5,6,9,21} In some patients intraoral and panoramic radiographs must be complemented with CT investigation in order to determine the presence of root resorption on adjacent incisors.

Orthodontic treatment of cases in which an ectopically positioned maxillary canine is complicated by associated resorption of an incisor root varies according to such individual factors as the position of the canine, lack of space and guidance, developmental stages of neighboring teeth, and site and severity of the root resorption.¹⁵ The most common approach is surgical exposure of the impacted canine and orthodontic repositioning, sometimes in combination with extraction of premolars. The question arises as to whether in the long term the root resorption progresses, ceases, or undergoes repair.

This follow-up comprised 27 subjects with 32 resorbed incisors: 8 individuals had been excluded because of extraction of both lateral incisors as part of the orthodontic treatment.

The number of boys (7) and girls (20) is in agreement with the average sex ratio for resorbed incisors.⁹ This was in contrast to the study by Becker and Chaushu¹⁷ where all 11 subjects were female. The limited number of subjects may explain the difference.

The results in our study are uniform and show good clinical and radiographic evidence of healing in all cases except for one ankylosed tooth and one with pulpal obliteration (Figures 2 and 3). This is in accordance with the result of Becker and Chaushu¹⁷ in their 1-year follow-up.

In 13 of the 32 incisors, no lesions were discernible at follow-up. This may be attributable to the size and location of the original lesions on the roots, to remodeling and formation of the new root cementum and periodontal contour, but also to the relative lack of details on intraoral radiographs compared to CT scan (Table 3; Figure 6). CT scans, undertaken in some of the cases, indicate residual but healed defects on the roots, not discernible on the intraoral films.

Whether the resorbed but healed incisors will continue to function in the long term has yet to be determined. It is likely that small to moderate defects have a good prognosis because of restitution of protecting tissues around the defect, while incisors with extensive resorption involving the pulp are probably more vulnerable and less amenable to repair. However, even severely resorbed incisors may function as temporary space maintainers during the growth period until final treatment can be undertaken.

No resorbed incisor needed endodontic treatment. None of the seven teeth with increased resorption showed reduced vitality or ankylotic percussion sounds (Table 3). Orthodontic forces may be responsible at least in part for continued resorption (Figure 5).

Clinically, it can be difficult to identify orthodontically treated retained canines. In an earlier study it was found that in subjects with unilateral retained canines, five experienced orthodontists were able to identify such teeth in only 35% of the cases.²² With respect to esthetic outcome, an earlier study of 61 subjects disclosed that only four were dissatisfied: in all four patients, canines replaced the lateral incisors.²² It is important to distance the canine from the resorbed incisor root as early as possible in the orthodontic treatment.

Based on the follow-up intraoral radiographic examination, there was no significant difference in the severity of the resorptive lesion between the ectopic canine experienced extraction or orthodontic repositioning. However, in this context, there is always the possibility of minor changes not discernible on intraoral radiographs.

In certain individuals a shortening of the root length could be seen on maxillary incisors where fixed orthodontic appliances had been used. (Figure 5D,E). Of course, this is also true in patients who undergo fixed appliance therapy for other anomalies.

The benefits of complementing conventional radiographs with CT as a diagnostic aid in disclosing resorptive lesions has been demonstrated in a recent study of 80 patients.¹⁶ Orthodontic treatment plans were compiled before and after complementary CT data resulted in modification of the treatment plans in 43% of patients. Based on information from intraoral radiographs and panoramic films only, the treatment plan was to extract lateral incisors in 11 patients because of the risk of root resorption. With the additional information from the CT investigation, it was evident that no root resorption was present.¹⁶

The results of the present study indicate that root resorption associated with ectopic canines does not threaten the long-term viability of the affected incisors. Our results suggest that treatment with fixed orthodontic appliances after surgical exploration of the impacted canine is the treatment of choice in such cases. To confirm these results, further studies are warranted on a larger material and with longer follow-up. It is recommended that such studies should include CT investigations.

CONCLUSIONS [Return to TOC](#)

- The long-term prognosis for maxillary incisors with root resorption associated with ectopically positioned canines is good. In most cases the resorption heals after management of the ectopic canine by surgical exposure and orthodontic repositioning, or by surgical removal.
- Even in cases with severe resorption, the incisor roots show good long-term healing.
- Resorption sites, which are recorded at initial registration and subsequently undergo repair, might be difficult to identify at follow-up if evidence is limited to intraoral radiographs.
- Incisors with root resorption can be used in an orthodontic appliance system.
- No indications are present for endodontic treatment to arrest further root resorption.

REFERENCES [Return to TOC](#)

1. Dachi SF, Howell FV. A survey of 3874 routine full mouth radiographs. II. A study of impacted teeth. *Oral Surg Oral Med Oral Pathol.* 1961;1165–1169.
2. Thilander B, Jakobsson SO. Local factors in impaction of maxillary canines. *Acta Odontol Scand.* 1968; 26:145–168.

3. Kramer RM, Williams AC. The incidence of impacted teeth. A survey at Harlem Hospital. *Oral Surg.* 1970; 29:237–241.
4. Thilander B, Myrberg N. The prevalence of malocclusion in Swedish schoolchildren. *Scand J Dent Res.* 1973; 81:12–20.
5. Ericson S, Kurol J. Longitudinal study and analysis of clinical supervision of maxillary canine eruption. *Community Dent Oral Epidemiol.* 1986; 14:172–176.
6. Ericson S, Kurol J. Radiographic assessment of maxillary canine eruption in children with clinical signs of eruption disturbance. *Eur J Orthod.* 1986; 8:133–140.
7. Becker A. *The Orthodontic Treatment of Impacted Teeth.* London, UK: Martin Dunitz Ltd; 1998:85.
8. Ericson S, Kurol J. Resorption of incisors after ectopic eruption of maxillary canines: a CT-study. *Angle Orthod.* 2000; 70:415–423.
9. Ericson S, Kurol J. Radiographic examination of ectopically erupting maxillary canines. *Am J Orthod Dentofacial Orthop.* 1987; 91:483–492.
10. Preda L, La Fianza A, Di Maggio EM, Dore R, Schifino MR, Campani R, Segù C, Sfondrini MF. The use of spiral computed tomography in the localization of impacted maxillary canines. *Dentomaxillofac Radiol.* 1997; 26:236–241.
11. Krennmaier G, Lenglinger FX, Traxler M. Imaging of unerupted and displaced teeth by cross-sectional CT scans. *Int J Oral Maxillofac Surg.* 1995; 24:413–416.
12. Follin ME, Lindvall AM. Detection of lingual root resorptions in the intraoral radiographs. An experimental study. *Swed Dent J.* 2005; 29:35–42.
13. Kurol J, Ericson S, Andreassen JO. The impacted maxillary canine. In: Andreassen JO, Petersson JK, Laskin DM, eds. *Textbook and Color Atlas of Tooth Impactions.* Copenhagen, Denmark: Munksgaard; 1997:129–130.
14. Andreassen GF. A review of the approaches to treatment of impacted maxillary cuspids. *Int J Oral Surg.* 1971; 31:479–484.
15. Becker A, Shteyer A, Lustman J. Surgical exposure of impacted teeth. In: Becker A, ed. *The Orthodontic Treatment of Impacted Teeth.* London, UK: Martin Dunitz Ltd; 1998: 26–35.
16. Bjerklin K, Ericson S. How a computerized tomography (CT) examination changed the treatment plans of 80 children with retained and ectopically positioned maxillary canines. *Angle Orthod.* 2006; 76:43–51.
17. Becker A, Chaushu S. Long-term follow-up of severely resorbed maxillary incisors after resolution of an etiologically associated impacted canine. *Am J Orthod Dentofacial Orthop.* 2005; 127:650–654.
18. Armitage P, Berry G. *Statistical Methods in Medical Research.* 2nd ed. Oxford, UK: Blackwell Science Publications; 1987:125–132.
19. Ericson S, Bjerklin K. Does the canine dental follicle cause resorption of permanent incisor roots? A computed tomographic study of erupting maxillary canines. *Angle Orthod.* 2002; 72:95–104.
20. Ericson S, Kurol J. Early treatment of palatally erupting maxillary canines by extraction of the primary canines. *Eur J Orthod.* 1988; 10:283–295.
21. Kurol J, Ericson S, Andreassen JO, Petersson JK, Laskin DM. eds. *Textbook and Color Atlas of Tooth Impactions.* Copenhagen, Denmark: Munksgaard; 1997:129–131.
22. Mak D'Amico R, Bjerklin K, Kurol J, Falahat B. Long-term results of orthodontic treatment of impacted maxillary canines. *Angle Orthod.* 2003; 73:231–238.

TABLES [Return to TOC](#)

Table 1. Number and Resorption Level at the First Registration of Incisors, Resorbed Because of Ectopically Positioned Maxillary Canines in 27 Children

Incisors	Number of Teeth	Root Resorption		
		Slight	Moderate	Severe
Lateral	24	12	4	8
Central	8	3	2	3
Total	32	15	6	11

Table 2. The Resorption Sites on 32 Incisor Roots in 27 Children

Incisors	Buccal, Distobuccal	Lingual, Distolingual	Distal	Apical	Total	Cervical Third	Middle Third	Apical Third	Apical Tip	Total
Lateral	6	11	2	5	24	2	13	5	4	24
Central	0	6	2	0	8	1	4	1	2	8
Total	6	17	4	5	32	3	17	6	6	32

Table 3. Resorption on the Incisor Roots at the Follow-Up Registrations in Comparison with the First Registration

Incisors	Normalized	Unchanged	Increased	Total
Lateral	13	6	5	24
Central	0	6	2	8
Total	13	12	7	32

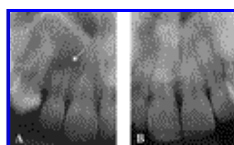
Table 4. Thirty-Two Resorbed Incisor Roots at the First Registration (Reg) and at the Follow-Up

Incisors	Not Detectable		Slight		Detectable/ Severe–Moderate	
	First Reg	Follow-Up	First Reg	Follow-Up	First Reg	Follow-Up
	Lateral	0	11	12	2	12
Central	0	2	3	0	5	6
Total	0	13	15	2	17	17

Table 5. Root Length of the Incisors Resorbed Due to Ectopically Positioned Maxillary Canines Compared with the Unresorbed Contralateral

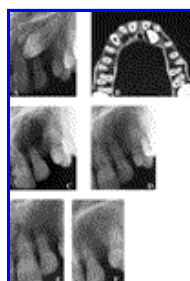
Incisors	Normal Equal With Contralateral	∅ of Contralateral	\bar{x} of Contralateral	$<\bar{x}$ of Contralateral	Total
Lateral	14	4	3	3	24
Central	6	1	1	0	8
Total	20	5	4	3	32

FIGURES [Return to TOC](#)



Click on thumbnail for full-sized image.


Figure 1. (A–B) Periapical intraoral radiographs after orthodontic correction of the maxillary ectopically positioned canines. The resorption areas are healed at the follow up, arrow



Click on thumbnail for full-sized image.

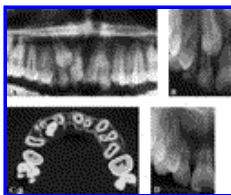
Figure 2. (A) Periapical radiograph of the ectopically positioned maxillary left canine. Suspected resorption on the distal of the maxillary left central incisor adjacent to the cusp. No resorption is seen on the maxillary left lateral incisor. (B) CT shows moderate resorption on the lingual aspect of both the left central and lateral incisor roots. (C) Radiograph exposed immediately after the removal of the canine. Resorption is visible on both incisor roots. (D)

Control 1 year later with signs of healing. (E, F) Radiographs 10 years after the first examination show normalization of the contour but obliteration of the pulp cavity in the maxillary left lateral incisor



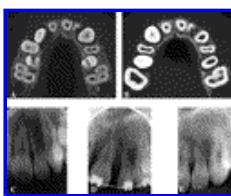
[Click on thumbnail for full-sized image.](#)

Figure 3. (A) Intraoral radiograph showing ectopically positioned maxillary left canine, overlapping the central incisor. The central incisor shows a distally located root resorption. (B) CT verifies severe resorption of the central incisor with pulpal involvement. (C) Control radiograph 9 years later shows healing of the resorbed root with ankylosis. There is no sign of marginal bone involvement



[Click on thumbnail for full-sized image.](#)

Figure 4. (A,B) Panoramic and intraoral radiographs show resorptive lesions on the right lateral and central incisors. (C) CT discloses severe resorption extending to the pulp on the palatal root surface of the lateral incisor and moderate resorption on the central incisor. (D) Periapical radiograph at the control shows shortened roots with intact lamina dura and no sign of resorption activity on either of the incisors, indicating healing. The maxillary right canine has been extracted. The irregular architecture of the trabecular bone in this area marks the position of the impacted canine crown in the vicinity of the resorption sites



[Click on thumbnail for full-sized image.](#)

Figure 5. (A) CT scan shows severe resorption reaching the pulp on the left lateral incisor. (B, C) CT and periapical radiographs 2 years after the removal of the canine show the root of maxillary left lateral incisor during the healing process. The lamina dura is under repair. (D) Periapical radiograph taken during orthodontic treatment. The apex of the root of the maxillary left lateral incisor is shortened and remodeled. (E) Periapical radiograph of the maxillary left lateral incisor, 4 years after orthodontic treatment. The root of the maxillary left lateral incisor is shortened and healing is complete. The root of the central incisor is also shortened after the orthodontic treatment



[Click on thumbnail for full-sized image.](#)

Figure 6. (A) Periapical radiograph. Left maxillary canine is overlapping the lateral incisor. Resorption on the left maxillary lateral incisor cannot be diagnosed. (B) CT illustrates slight resorptive damage on the buccal aspect of the root surface. (C) Intraoral radiograph at follow-up: there is no discernible defect on the root of the lateral incisor and the initially resorptive lesion is considered normalized

^a Lecturer, Department of Oral and Maxillofacial Radiology, Karolinska Institutet, Stockholm, Sweden

^b Associate Professor, Department of Oral and Maxillofacial Radiology, Institute for Postgraduate Dental Education, Jönköping, Sweden

^c Orthodontic private practice, Bolzano, Italy

^d Associate Professor, Department of Orthodontics, Institute for Postgraduate Dental Education, Jönköping, Sweden

