

[\[Print Version\]](#)

[\[PubMed Citation\]](#) [\[Related Articles in PubMed\]](#)

TABLE OF CONTENTS

[\[INTRODUCTION\]](#) [\[CASE REPORT\]](#) [\[DISCUSSION\]](#) [\[CONCLUSION\]](#) [\[REFERENCES\]](#) [\[FIGURES\]](#)

doi: 10.2319/121007-581.1

The Angle Orthodontist: Vol. 78, No. 6, pp. 1110-1118.

An Adolescent Patient with Multiple Impacted Teeth

Eiji Tanaka;^a Aki Kawazoe;^b Saika Nakamura;^b Goshi Ito;^b Naoto Hirose;^b Yuki Tanne;^b Nobuhiko Kawai;^c Kotaro Tanimoto;^d
Kazuo Tanne^e

ABSTRACT

Multiple impacted permanent teeth is uncommon and rarely reported in the literature. This article reports the treatment of an adolescent patient with multiple impacted teeth without systemic disease. A 9-year 2-month-old boy complained of a delay of eruption of the first molars. All first molars were unerupted, and the left deciduous second molar was a submerged tooth. The panoramic radiograph showed all permanent teeth except the incisors were unerupted and, especially for the first molars, spontaneous eruption was not expected. His medical history was uneventful. A lingual arch appliance and a segmental arch were placed on the mandibular and maxillary dentitions, respectively, to guide eruption of the impacted first molars. After traction of the first molars, eruption of the impacted lower premolars was induced. Furthermore, at 15 years the impacted mandibular second molars were also positioned properly by use of the lingual arch with auxiliary wires. After achieving traction of the impacted teeth, tooth alignment was initiated using multibracket appliances after the bilateral extraction of the second premolars. After 22 months of treatment with multibracket appliances, an acceptable occlusion was achieved with a Class I molar relationship. After 2 years of retention an acceptable occlusion was maintained without any relapse in the occlusion. Since a delay in the treatment of impacted teeth may induce secondary problems such as root dilacerations and ankylosis, it is highly recommended to perform early treatment of multiple impacted teeth during adolescence.

KEY WORDS: Multiple impacted teeth, Orthodontic traction, Early orthodontic treatment.

Accepted: January 2008. Submitted: December 2007


INTRODUCTION [Return to TOC](#)


Tooth impaction occurs in 1% to 2% of orthodontic patients,¹ and the maxillary canine exhibits the highest incidence.² According to a review by Bishara,³ the causes of tooth impaction are divided into generalized and localized factors. The common causes are usually localized: lack of space for eruption, prolonged retention or early loss of the deciduous tooth, abnormal position of the tooth bud, the presence of alveolar cleft, ankylosis, cystic or neoplastic formation, alveolar or dental trauma, and dilaceration of the root.³ As for the general factors, the most common syndrome for tooth impaction is cleidocranial dysplasia (CCD).^{4,5} CCD is a rare inherited form of skeletal dysplasia, and the most obvious dental abnormality of CCD is prolonged retention of deciduous teeth with failure in the eruption of permanent teeth.^{4,5}


Although impaction of the multiple permanent teeth occurs less frequently than that of a single tooth, multiple impactions cause serious problems in terms of treatment time and outcome. Age at the start of treatment, the degree of dilacerations, stage of root formation, position of the tooth, and the distance of the tooth from the occlusal plane are factors reported to increase treatment time and complexity.^{6,7} The success rate of an impacted tooth thus depends on these factors. In addition, orthodontists often hesitate to align impacted teeth because of a high possibility of failure due to ankylosis, external root resorption, and root exposure during or after orthodontic tooth movement.⁸ Therefore, it is of great importance for an acceptable treatment outcome to diagnose when and how the impacted tooth is moved to a proper position. To develop an effective treatment protocol and remedy for multiple impacted teeth, clinical evidence is necessary, but impaction of multiple permanent teeth is an uncommon condition and rarely reported in the literature.⁹


The purpose of this article is to report a treatment of multiple permanent impacted teeth, and to discuss the association between the period of tooth traction and treatment outcome.

CASE REPORT [Return to TOC](#)

The patient, a 9-year 2-month-old boy, complained of a delay in eruption of both the upper and lower first molars. His facial profile was convex and no facial asymmetry was observed ([Figure 1](#) ) . He was in good health and had no history of dental trauma. His medical history was uneventful.

Overjet and overbite were 6.7 mm and 2.8 mm, respectively ([Figure 1](#) ) . The maxillary and mandibular dental arches were parabolic and symmetrical. All first molars were unerupted, and the left upper deciduous second molar was submerged.

From the model analysis, the mandibular midline was shifted to the right 2.4 mm, whereas the maxillary midline was almost coincident to the facial one. This was due to early loss of the right lower deciduous canine. Accordingly, the space for the permanent canine eruption was deficient. On a panoramic radiograph, all teeth except for the incisors were impacted and, especially for the first molars, spontaneous eruption was not expected ([Figure 2](#) ) . The impacted lower first molars appeared mesial to the distal root apex of the deciduous lower second molars. No congenital missing teeth were found.


Analysis of the lateral cephalometric radiograph revealed a skeletal Class I malocclusion ($ANB = 5.2^\circ$) with a reference to Japanese standards¹⁰ ([Figure 3](#) ) . The mandibular plane and gonial angles were slightly larger compared to the Japanese control. The facial-lingual inclinations of the maxillary and mandibular incisors were also within the normal range.


From these findings, this case was diagnosed as a skeletal Class I malocclusion (a mild high angle case) with multiple impacted teeth and a tooth-jaw discrepancy. The main treatment objective was to properly position the impacted teeth as much as possible. The treatment plan for this case was:


- Surgical exposure and traction of the impacted first molars.
- After traction of the first molars, eruption of the other impacted teeth was guided, if available.
- After the completion of permanent dentition, multibracket appliances were placed on both dentitions for tooth alignment.

In the informed consent, it was well understood that extraction of some impacted teeth might be necessary if ankylosis occurred.

Treatment Progress

A lingual arch appliance was placed on the lower deciduous second molars. Then, both lower first molars were surgically exposed and attachments were bonded ([Figure 4](#) ) . A lingual arch was used to exert continuous traction on the first molars for a year. The right lower first molar was successfully exposed into the oral cavity, but the left one was still untreated.

At age 10 years 2 months, both upper first molars were surgically exposed and attachments were bonded. In order to guide eruption of the upper and lower first molars, elastic chains were utilized between the attachments. Five months after initiating the traction of the upper first molars, the left upper and lower first molars could not be successfully guided to eruption. Then, the left upper and lower deciduous second molars were extracted and segmental arch wires were placed on both dentitions. After more than 1 year of traction, all first molars were properly positioned ([Figure 5](#) ) .

At age 12 years 9 months, a lingual arch appliance was placed on the lower first molars and orthodontic traction of the impacted lower premolars was initiated using an elastic chain. The force to the impacted tooth was controlled to 60 g or less. The upper canine and the first premolars erupted naturally. In the meantime, a segmental arch was placed on the upper dentition. One year after initiating the traction, the lower premolars were exposed in the oral cavity, although the lower left second premolar was not erupted completely because of a lack in eruption space ([Figure 6](#) ) .

At age 14 years and 8 months, a panoramic radiograph ([Figure 6](#)) showed no indication of spontaneous eruption of the lower second molars since no substantial changes in the impacted position were observed during the preceding 1 year. Then, a lingual arch appliance was again placed on the lower first molars. Immediately after surgical exposure of the lower second molars, attachments were bonded and orthodontic traction was initiated using an elastic chain from the auxiliary wire soldered on the base wire of the lingual arch appliance ([Figure 7A](#)). Eight months after initiation of the traction, both second molars were positioned properly.

When the patient was 15 years 9 months old, cephalometric analysis revealed a skeletal Class I ($ANB = 3.5^\circ$), indicating normal maxillary and mandibular growth ([Figure 8](#)). Then, 0.018 × 0.025 inch edgewise appliances were placed on both the upper and lower dentitions except for the lower incisors ([Figure 7B](#)). The initial leveling was performed with a 0.016 inch Ni-Ti wire. After the leveling, a plain stiff wire with 0.016 × 0.022 inch size was placed on the upper arch. Simultaneously, a 0.016 × 0.022 inch retraction wire was applied at the lower arch. On the upper arch, a retraction wire of 0.016 × 0.022 inch was applied at age 17 years 1 month. After 22 months of orthodontic treatment with a multibracket appliance, an acceptable and stable occlusion was achieved and all appliances were removed. Immediately after removal, bonded lingual retainers were placed on both dentitions. In addition, a wraparound type retainer was placed on the upper dentition.

Treatment Results

Facial photographs showed that facial balance overall did not change markedly ([Figure 8](#)). Acceptable occlusion was achieved, and the overjet and overbite were improved to 3.0 mm and 1.5 mm, respectively ([Figure 9](#)). The molar relationships were changed to Class I on both sides.

Panoramic radiograph showed an apical root resorption in the upper incisors ([Figure 10](#)). Cephalometric analysis revealed a skeletal Class I ($ANB = 3.4^\circ$), which indicated normal growth of the maxilla and mandible during orthodontic treatment ([Figure 10](#)). The labiolingual inclination of the upper and lower central incisors was retained within the normal range.

Three years after retention, an acceptable occlusion was maintained without any marked relapse in occlusion, indicating long-term stability of the occlusion ([Figures 11](#) and [12](#)).

DISCUSSION [Return to TOC](#)

The primary treatment procedure for an impacted tooth is orthodontic traction after surgical exposure of the tooth crown. There are several approaches for the treatment of impacted molars. Orthodontic appliances may be available without surgery for partially impacted teeth.¹¹ A combination of surgical and orthodontic treatment will be selected for severe impactions. Although surgical transplanting may be another selection,¹² surgical transplanting or repositioning of teeth generally has a high risk of complications, such as pulp necrosis, ankylosis, and root resorption. If the molars are deeply impacted in the mandible, similar to this patient, inferior alveolar nerve damage by surgery is also possible.

Based on these considerations, we selected orthodontic extrusion assisted by surgical access to the impacted teeth using a lingual arch for the lower dentition. The lower primary second molars were used effectively as anchors for extrusion of the impacted first molars. However, if the lower primary second molars are not available, implant-anchors are available alternatively as an effective anchorage.^{5,13}

There are actually some failures of traction due to ankylosis and external root resorption. Furthermore, even the successful cases probably end with an irregular root formation and/or an unesthetic gingival margin of the tooth after orthodontic treatment.

In daily clinical practice, the following factors are used to determine whether an impacted tooth can be successfully aligned in proper position: the position and direction of the impacted tooth, the amount of root formation, and the degree of root dilacerations. Furthermore, an impacted tooth is likely to have a dilacerated root, which becomes worse with time.¹⁴⁻¹⁶ For the management of developing dentition, the ability and trained skill to predict tooth eruption accurately is of great importance. This ability will make it possible to answer such questions as to whether a treatment should be conducted for helping proper eruption of the teeth and when a particular therapy should be instituted for the best treatment outcomes.

By Nolla's mean stage of tooth development, the maxillary and mandibular first molars emerge in the mouth at 6 or 7 years of age when two-thirds of their roots are complete; their roots are completed at 12 to 13 years of age.¹⁷ Therefore, the tooth, if impacted, is likely to have a dilacerated root which becomes more severe with a lapse of time. Thus, earlier treatment of impacted teeth is recommended.

In the present patient, at 9 to 10 years of age, the traction of lower and upper first molars was initiated, and the traction succeeded at age 12 years 9 months, which just matched the time of the root completion. As the result, the first molars showed no pathological findings in their root development. If the spontaneous eruption of the impacted tooth was not expected, the early treatment including impacted tooth traction was highly anticipated.

- It is highly recommended to perform early treatment of multiple impacted teeth during adolescence since a delay in the treatment of impacted teeth may induce the secondary problems such as root dilacerations and ankylosis.

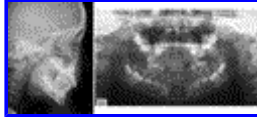
REFERENCES [Return to TOC](#)

1. Johnston W. Treatment of palatally impacted canine teeth. *Am J Orthod.* 1969; 56:589–596. [[PubMed Citation](#)]
2. McDonald F, Yap WL. The surgical exposure and application of direct traction of unerupted teeth. *Am J Orthod.* 1986; 89:331–340. [[PubMed Citation](#)]
3. Bishara SE. Impacted maxillary canines: a review. *Am J Orthod Dentofacial Orthop.* 1992; 101:159–171. [[PubMed Citation](#)]
4. Becker A, Lustmann J, Shteyer A. Cleidocranial dysplasia: part 1—general principles of the orthodontic and surgical treatment modality. *Am J Orthod Dentofacial Orthop.* 1997; 111:28–33. [[PubMed Citation](#)]
5. Kuroda S, Yanagita T, Kyung H-M, Takano-Yamamoto T. Titanium screw anchorage for traction of many impacted teeth in a patient with cleidocranial dysplasia. *Am J Orthod Dentofacial Orthop.* 2007; 131:666–669. [[PubMed Citation](#)]
6. Stewart JA, Heo G, Glover KE, Williamson PC, Lam EWN, Major PW. Factors that relate to treatment duration for patients palatally impacted maxillary canines. *Am J Orthod Dentofacial Orthop.* 2001; 119:216–225. [[PubMed Citation](#)]
7. Becker A, Chaushu S. Success rate and duration of orthodontic treatment for adult patients with palatally impacted maxillary canines. *Am J Orthod Dentofacial Orthop.* 2003; 124:509–514. [[PubMed Citation](#)]
8. Lin Y-TJ. Treatment of an impacted dilacerated maxillary central incisor. *Am J Orthod Dentofacial Orthop.* 1999; 115:406–409. [[PubMed Citation](#)]
9. Conley RS, Boyd SB, Legan HL, Jernigan CC, Starling C, Potts C. Treatment of a patient with multiple impacted teeth. *Angle Orthod.* 2007; 77:735–741. [[PubMed Citation](#)]
10. Wada K, Otani S, Sakuda M. Morphometric analysis in maxillary protrusion [in Japanese]. In: Yamauchi K, Sakuda M, eds. *Maxillary Protrusion*. Tokyo, Japan: Ishiyaku Publishing Co; 1989:95–130.
11. Sawicka M, Racka-Pilszak B, Rosnowska-Mazurkiewicz A. Uprighting partially impacted permanent second molars. *Angle Orthod.* 2007; 77:148–154. [[PubMed Citation](#)]
12. McAboy CP, Grumet JT, Siegel EB, Iacopino AM. Surgical uprighting and repositioning of severely impacted mandibular second molars. *J Am Dent Assoc.* 2003; 134:1459–1462. [[PubMed Citation](#)]
13. Tseng YC, Chen CM, Chang HP. Use of a miniplate for skeletal anchorage in the treatment of a severely impacted mandibular second molar. *Br J Oral Maxillofac Surg.* In press.
14. Tanaka E, Watanabe M, Nagaoka K, Yamaguchi K, Tanne K. Orthodontic traction of an impacted maxillary central incisor. *J Clin Orthod.* 2001; 35:375–378. [[PubMed Citation](#)]
15. Uematsu S, Uematsu T, Furusawa K, Deguchi T, Kurihara S. Orthodontic treatment of an impacted dilacerated maxillary central incisor combined with surgical exposure and apicoectomy. *Angle Orthod.* 2004; 74:132–136. [[PubMed Citation](#)]
16. Tanaka E, Hasegawa T, Hanaoka K. et al. Severe crowding and a dilacerated maxillary central incisor in an adolescent. *Angle Orthod.* 2006; 76:510–518. [[PubMed Citation](#)]
17. Moyers RE. Development of the dentition and occlusion. In: *Handbook of Orthodontics*. 2nd ed. Chicago, Ill: Year Book Medical Publishers; 1963:51–126.



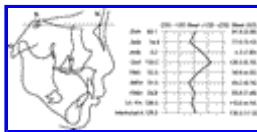
[Click on thumbnail for full-sized image.](#)

Figure 1. Facial and intraoral photographs before treatment (age 9 years 2 months)



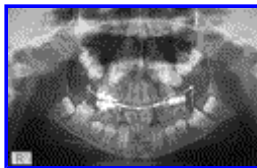
[Click on thumbnail for full-sized image.](#)

Figure 2. Lateral cephalometric and panoramic radiographs before treatment (age 9 years 2 months)



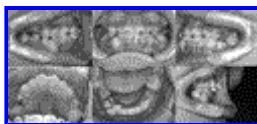[Click on thumbnail for full-sized image.](#)

Figure 3. Cephalometric tracing before treatment (age 9 years 2 months)



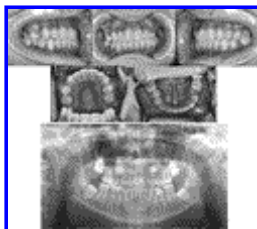[Click on thumbnail for full-sized image.](#)

Figure 4. Panoramic radiograph during traction of the lower first molars (age 9 years 3 months)



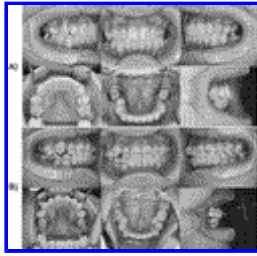[Click on thumbnail for full-sized image.](#)

Figure 5. Intraoral photographs during treatment. All first molars were properly positioned at the age of 12 years 4 months



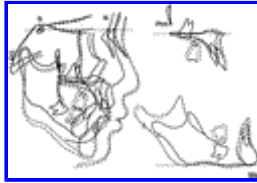
[Click on thumbnail for full-sized image.](#)

Figure 6. Intraoral photographs and panoramic radiograph at the age of 14 years 8 months



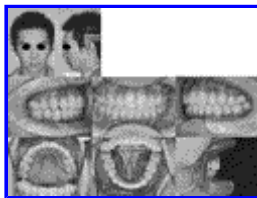
[Click on thumbnail for full-sized image.](#)

Figure 7. Intraoral photographs during treatment. (A) During traction of the lower second molars. (B) Immediately after initiating orthodontic treatment with conventional fixed appliance



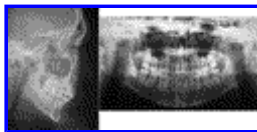
[Click on thumbnail for full-sized image.](#)

Figure 8. Superimposition of cephalometric tracings before treatment (solid line, age 9 years 2 months), and before (small dotted line, age 15 years 9 months) and after treatment with multibracket appliances (large dotted line, age 17 years 8 months)



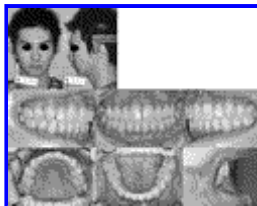[Click on thumbnail for full-sized image.](#)

Figure 9. Facial and intraoral photographs after treatment (age 17 years 8 months)



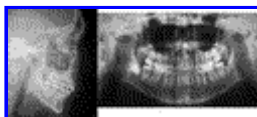
[Click on thumbnail for full-sized image.](#)

Figure 10. Cephalometric and panoramic radiographs after treatment (age 17 years 8 months)



[Click on thumbnail for full-sized image.](#)

Figure 11. Facial and intraoral photographs 3 years after retention (age 20 years 8 months)



[Click on thumbnail for full-sized image.](#)

Figure 12. Cephalometric and panoramic radiographs 3 years after retention (age 20 years 8 months)

- ^a Associate Professor, Department of Orthodontics and Craniofacial Developmental Biology, Hiroshima University Graduate School of Biomedical Sciences, Hiroshima, Japan
- ^b Graduate PhD student, Department of Orthodontics and Craniofacial Developmental Biology, Hiroshima University Graduate School of Biomedical Sciences, Hiroshima, Japan
- ^c Resident, Department of Orthodontics and Craniofacial Developmental Biology, Hiroshima University Graduate School of Biomedical Sciences, Hiroshima, Japan
- ^d Assistant Professor, Department of Orthodontics and Craniofacial Developmental Biology, Hiroshima University Graduate School of Biomedical Sciences, Hiroshima, Japan
- ^e Professor and Department Chair, Department of Orthodontics and Craniofacial Developmental Biology, Hiroshima University Graduate School of Biomedical Sciences, Hiroshima, Japan

Corresponding author: Dr E. Tanaka, Department of Orthodontics and Craniofacial Developmental Biology, Hiroshima University Graduate School of Biomedical Sciences, 1-2-3 Kasumi, Minami-ku, Hiroshima, Hiroshima 734-8553 Japan (E-mail: etanaka@hiroshima-u.ac.jp)