

[\[Print Version\]](#)

[\[PubMed Citation\]](#) [\[Related Articles in PubMed\]](#)

## TABLE OF CONTENTS

[\[INTRODUCTION\]](#) [\[CASE REPORT\]](#) [\[DISCUSSION\]](#) [\[REFERENCES\]](#) [\[FIGURES\]](#)

doi: 10.2319/122205-454R.1

*The Angle Orthodontist*: Vol. 77, No. 1, pp. 176-180.

# A Fused Maxillary Central Incisor with Dens Evaginatus as a Talon Cusp

Gholamreza Danesh;<sup>a</sup> Tine Schrijnemakers;<sup>b</sup> Carsten Lippold;<sup>c</sup> Edgar Schäfer<sup>d</sup>

## ABSTRACT

This report presents a rare case of concurrence of dens evaginatus and dental fusion affecting the maxillary right upper central incisor of a 9-year-old male patient. An association of dens evaginatus and dental fusion within the same tooth is rare. In this case, an orthopantomogram, a lateral cephalogram, intraoral radiographs, and a magnetic resonance tomogram were made to obtain a proper diagnosis and to confirm the exact path of the root canals. Because of a forced bite, an orthodontic treatment involving cusp reduction was initiated. During the cusp reduction, no traumatic intraoperative exposure of pulp tissue occurred, and no endodontic or surgical treatment procedures were necessary. After a multibracket treatment, a harmonious integration of the tooth in the upper dental arch was achieved.

**KEY WORDS:** Dental malformation, Grinding, Magnetic resonance tomography.

Accepted: February 2006. Submitted: December 2005

## INTRODUCTION [Return to TOC](#)

A malformation of a tooth characterized by the presence of an accessory cusp is called dens evaginatus.<sup>1</sup> According to Hülsmann,<sup>2</sup> dens evaginatus is first described by Mitchell as a hornlike-shaped process curving from the base downward to the cutting edge on the lingual surface of an upper central incisor of a female patient. Moreover, Hülsmann stated that it is a relatively rare developmental anomaly characterized by the presence of an accessory cusplike structure, starting from the cingulum area or cemento-enamel junction of the maxillary or mandibular anterior teeth in both the primary and permanent dentitions. The premolars are the most commonly affected of the posterior teeth.<sup>2-4</sup>

Although the extraordinary form of teeth with dens evaginatus cannot be overstated, the diagnosis is mostly unproblematic.<sup>2</sup> Nevertheless, dental radiographs are necessary to achieve a proper diagnosis to analyze the extension of the pulp chamber.<sup>2</sup> A thermal pulp sensitivity test is obligatory. Treatment considerations should include the sealing of the pits and fissures (caries prevention)<sup>5</sup> and an early orthodontic treatment (grinding).<sup>6</sup>



According to de Siqueira et al,<sup>7</sup> dental fusion is defined as "a union of 2 adjacent teeth at the crown level (enamel and dentin), causing



the formation of a single tooth with an enlarged clinical crown.” The differential diagnosis of gemination is confirmed if two separate units in tooth development were created out of one single germ.<sup>7,8</sup> The diagnosis can be proven by the number of permanent teeth.<sup>9</sup> However, the differentiation is sometimes uncertain if a fusion might have taken place involving a regular and a supernumerous tooth.<sup>10</sup>


Although there are several reports in the literature concerning dens evaginatus<sup>1-5</sup> and dental fusion,<sup>8-10</sup> concurrence of dens evaginatus and dental fusion in the same tooth is a rarity.<sup>7</sup> In this report, the orthodontic treatment of an unusual concurrent combination of dental anomalies affecting both the crown and the root of a permanent central upper incisor is described.



## CASE REPORT [Return to TOC](#)

A 9-year-old male patient was referred to the Department of Orthodontics by the Department of Maxillofacial Surgery because of the unusual form of tooth 11. The main complaints of this patient were the compromised esthetics and the problems in biting off food.

A clinical examination revealed a caries-free mixed dentition with a Class II division 2 malocclusion and a straight profile. The patient also showed a distal jaw relation, a deep bite, and crowding in the mandibular anterior dentition. The distal occlusion was caused by a palatal accessory cusp on the right upper central incisor ([Figure 1 a-c](#) ). The vestibular facet of the crown exceeded the normal width (14 mm, tooth 21 only 11 mm) and had a median vertical fissure from which two diagonally placed facets went ventrally and laterally at an angle of 120° ([Figure 1g](#) ). The pulp sensitivity test with cold spray was positive, and periodontal probing did not show any deepened sulcus.

The patient's history was not contributory and did not show any genetic phenomena. To obtain a more specific diagnosis, a three-dimensionally orientated model was elaborated together with an orthopantomogram, a lateral cephalogram, dental radiographs, and intra- and extraoral photographs. All permanent teeth were detectable, and the patient had a neutral growth pattern. The exact structures of tooth 11 could not be clearly identified, but it was possible to recognize a complex structure of the pulp ([Figure 2 a,b](#) ). A magnetic resonance tomogram was made ([Figure 3 a-f](#) ) to confirm the exact path of the root canal. This tomogram revealed two root canals coronal (palatal and buccal) joining in the apical part of the root.

Grinding therapy was performed to reduce the cusp. No exposure of the pulp tissue occurred during this procedure; therefore, the dentine was covered with an adhesive bonding (OptiBond FL, Kerr Corp, Orange, Calif) and a flowable composite resin (Tetric Flow, Vivadent, Bad Sörgeheim, Germany) ([Figure 1h](#) ).

The forced distal occlusion corrected itself spontaneously ([Figure 1d-f](#) ). To correct the setting of the teeth in a vestibular and a transverse direction, a segmented 2 × 4 multibracket appliance was used in the maxilla. Further thermal pulp sensitivity tests remained positive. After 6 months of orthodontic treatment, a correction of the forced distal occlusion and an almost harmonious integration of tooth 11 in the upper dental arch could be observed ([Figure 1i](#) ).

After a retention period with removable appliances, the goal of further orthodontic treatment after the eruption of the secondary dentition consisted of the adjustment of a bilaterally Angle Class I occlusion and corrected front teeth with canine guidance.



## DISCUSSION [Return to TOC](#)

The etiology of dens evaginatus is not fully understood and is thought to be multifactorial.<sup>2</sup> Genetic influences can be assumed,<sup>11,12</sup> though a combination of both genetic and environmental factors is more reasonable.<sup>2</sup>

According to the findings of Hattab et al,<sup>4</sup> the tooth in this report was classified as a talon cusp. Dens evaginatus occurs more often in the maxilla than in the mandible.<sup>1,13</sup> The maxillary lateral incisors are the most frequently involved teeth, followed by the central incisors and canines.<sup>4</sup>

Although fusion is described in the literature as a developmental occurrence, its etiology is uncertain.<sup>14</sup> The morphology of fused teeth varies, and complex forms with separated or fused coronal pulp chambers are present. Even separated chambers can meet in the radicular area or can remain separated.

Clearly, a careful clinical and radiographic examination is beneficial for optimal treatment planning. However, the normal dental radiographs usually are not sufficient to establish a proper diagnosis and treatment plan.<sup>15</sup> In this specific case, a magnetic resonance tomogram could confirm the exact path of the root canal. This technique seems to have the potential to visualize the topography of the root canals and offers new perspectives for dental imaging for special clinical cases.<sup>16</sup> However, it has not been recommended for routine use because of the insufficient cost-to-benefit ratio.

On the basis of the analysis of radiographic and magnetic resonance tomography findings of the presented case showing two separate root canals ([Figure 3 a-f](#) ) and the clinical appearance of the tooth ([Figure 1 a, b, and g](#) ) , the diagnosis of fusion along with talon

cusps were tentatively made. The evagination is oriented perpendicular to the palatal surface, as is usually seen in cases of talon cusps.

Related to Mader's "two-tooth rule,"<sup>17</sup> the anomaly may represent a fusion between a normal tooth and a supernumerary tooth. Because no missing permanent tooth was seen in this patient, it can be presumed that a fusion with a supernumerary tooth occurred.

The treatment of fused teeth can be complex and contain various treatment protocols that may include interdisciplinary endodontic, surgical, and periodontal interventions.<sup>14</sup> Depending on the localization and the extension of the occlusal interferences of the tooth, the tooth can be improved by orthodontic and prosthetic procedures.

Clinically, talon cusps may cause problems attributed to caries developing in the groove.<sup>18</sup> They may cause occlusal interference and subsequent loosening or displacement of the involved tooth.<sup>1,18</sup> Evaginations leading to an occlusal disturbance or cosmetic or phonetic problems may be an indication for grinding treatment.<sup>4</sup> The evagination should be decreased every 6 to 8 weeks. It is necessary to let some time pass between two appointments in order to allow for the production of tertiary dentine.<sup>4</sup> After each recontouring, the dentine should be covered with dentine bonding or fluoride gel.<sup>5</sup> In this case the talon cusps in the maxillary incisor did interfere with the patient's occlusion.

Because of the forced bite, an orthodontic treatment was indicated to avoid the risk of a distal skeletal relation of the upper and lower jaw. Therefore, a grinding therapy was indicated. It was important that the pulp chamber was not exposed, for an artificial exposure of the pulp tissue might lead to an endodontic or surgical treatment with an unclear prognosis. The aim of the grinding was to reduce the additional palatal cusps and the mesiodistal dimension of the tooth. However, if grinding leads to exposure of the pulp chamber, endodontic treatment options could be considered. Endodontic implications include prophylactic endodontic therapy if recontouring or physiologic reconstruction of the dens evaginatus is anticipated to prevent intraoperative pulpal exposure.<sup>15</sup>

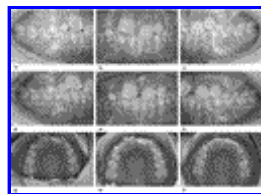
When neither conventional nor microscopic endodontic treatment is possible because of anatomical problems or the failure to gain access to all parts of the root canal system, surgical treatment should be a consideration.<sup>19,20</sup>

## REFERENCES [Return to TOC](#)

1. Oehlers FA, Leek KW, Lee EC. Dens evaginatus (evaginated odontome): its structure and responses to external stimuli. *Dent Pract Dent Rec.* 1967; 17:239–244.
2. Hülsmann M. aetiology and therapy of dens evaginatus. *Endodontie.* 2004; 13:363–372.
3. Karaca I, Toller M. Multiple bilateral dens in dente involving all the premolars. Case report. *Aust Dent J.* 1992; 37:449–452. [[PubMed Citation](#)]
4. Hattab FN, Yassin OM, al-Nimri KS. Talon cusp—clinical significance and management: case reports. *Quintessence Int.* 1995; 26:115–120.
5. Richardson DS, Knudson KG. Talon cusp: a preventive approach to treatment. *J Am Dent Assoc.* 1985; 110:60–62. [[PubMed Citation](#)]
6. Davis PJ, Brook AH. The presentation of talon cusp: diagnosis clinical features, associations and possible aetiology. *Br Dent J.* 1985; 160:84–88.
7. de Siqueira VC, Braga TL, Martins MA, Raitz R, Martins MD. Dental fusion and dens evaginatus in the permanent dentition: literature review and clinical case report with conservative treatment. *J Dent Child (Chic).* 2004; 1:69–72.
8. Velasco LFL, Araujo FB, Ferreira ES, Velasco LEL. Esthetic and functional treatment of a fused permanent tooth: a case report. *Quintessence Int.* 1997; 28:677–680.
9. Surtont PA, Martens LC, De Craene LG. A complete fusion in the primary human dentition: a histological approach. *J Dent Child.* 1988; 55:362–367.
10. Blaney TD, Hartwell GR, Bellizzi R. Endodontic management of a fused tooth: a case report. *J Endod.* 1982; 8:227–230. [[PubMed Citation](#)]
11. Garn SM, Leweis AB, Kerewski RS. Genetic, nutritional and maturational correlates of dental development. *J Dent Res.* 1965; 44:228–242. [[PubMed Citation](#)]
12. Rantanen AV. Talon cusp. *Oral Surg Oral Med Oral Pathol Oral Radiol Endod.* 1971; 32:398–400.
13. Curzon ME, Curzon JA, Poyton HG. Evaginated odontomes in the Keewatin Eskimo. *Br Dent J.* 1970; 129:324–328. [[PubMed Citation](#)]

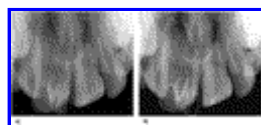
14. Taloumis LJ, Nishimura RS Jr. Treatment of an unusual instance of fusion with a talon cusp. *Gen Dent.* 1989; 37:208–210. [[PubMed Citation](#)]
15. Mupparapu M, Singer SR, Goodchild JH. Dens evaginatus and dens invaginatus in a maxillary lateral incisor: report of a rare occurrence and review of literature. *Aust Dent J.* 2004; 49:201–203. [[PubMed Citation](#)]
16. Weglarz WP, Tanasiewicz M, Kupka T, Skorka T, Sulek Z, Jasinski A. 3D MR imaging of dental cavities-an in vitro study. *Solid State Nucl Magn Reson.* 2004; 25:84–87. [[PubMed Citation](#)]
17. Mader CL. Fusion of teeth. *J Am Dent Assoc.* 1979; 98:62–64. [[PubMed Citation](#)]
18. McNamara CM, Garvey MT, Winter GB. Root abnormalities, talon cusps, dentes invaginati with reduced alveolar bone levels: case report. *Int J Paediatr Dent.* 1998; 8:41–45. [[PubMed Citation](#)]
19. Gutmann JL, Pitt Ford TR. Management of the resected root end: a clinical review. *Int Endod J.* 1993; 26:273–83. [[PubMed Citation](#)]
20. Hülsmann M, Radlanski R. Conservative treatment possibilities of dens invaginatus. *Dtsch Zahnärztl Z.* 1994; 49:804–808.

**FIGURES** [Return to TOC](#)



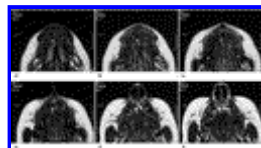
Click on thumbnail for full-sized image.

**Figure 1.** (a) Intraoral photograph of the right side, showing the forced distal occlusion. (b) Frontal intraoral photograph, showing an abnormal morphology of tooth 11. (c) Intraoral photograph of the left side, showing the forced distal occlusion. (d) Intraoral photograph of the right side after grinding, showing nearly Class I occlusion. (e) Frontal intraoral photograph after grinding of tooth 11. (f) Intraoral photograph of the left side after grinding, showing a Class I occlusion. (g) Intraoral photograph of the upper dental arch, showing an abnormal morphology of tooth 11 and a reclamation of tooth 21. (h) Intraoral photograph of the upper dental arch after grinding. (i) Intraoral photograph of the upper dental arch after grinding and orthodontic 2 × 4 multibracket treatment, showing an almost harmonious dental arch



Click on thumbnail for full-sized image.

**Figure 2.** (a) Dental radiograph of tooth 11, showing a complex morphology of the root canal. (b) Marking lines showing a possible contour of the root canal



Click on thumbnail for full-sized image.

**Figure 3.** Magnetic resonance tomography showing two root canals in the coronal part of the root of tooth 11; layers from coronal (a) to apical (f)

<sup>a</sup>Research Scientist, Department of Orthodontics, Dental School of Westfälische Wilhelms University, Münster, Germany

<sup>b</sup>Resident, Department of Orthodontics, Dental School of Westfälische Wilhelms University, Münster, Germany

<sup>c</sup>Research Scientist, Department of Orthodontics, Dental School of Westfälische Wilhelms University, Münster, Germany

<sup>d</sup>Professor, Department of Operative Dentistry, Dental School of Westfälische Wilhelms University, Münster, Germany

Corresponding author: Dr Gholamreza Danesh, Department of Orthodontics, Dental School of Westfälische Wilhelms University, Waldeyerstr 30, Münster, NRW 48149, Germany (E-mail: [siamak@uni-muenster.de](mailto:siamak@uni-muenster.de))

---

[© Copyright by E. H. Angle Education and Research Foundation, Inc. 2007](#)