

[\[Print Version\]](#)
[\[PubMed Citation\]](#) [\[Related Articles in PubMed\]](#)

TABLE OF CONTENTS

[\[INTRODUCTION\]](#) [\[MATERIALS AND...\]](#) [\[RESULTS\]](#) [\[DISCUSSION\]](#) [\[CONCLUSIONS\]](#) [\[REFERENCES\]](#) [\[TABLES\]](#) [\[FIGURES\]](#)

doi: 10.2319/0003-3219(2007)077[0244:PAAFME]2.0.CO;2
The Angle Orthodontist: Vol. 77, No. 2, pp. 244-253.

Premolar and Additional First Molar Extraction Effects on Soft Tissue

Effects on High Angle Class II division 1 Patients

Takemasa Ozaki;^a Shusaku Ozaki;^b Kumi Kuroda^c

ABSTRACT

Objective: To determine the effects of premolar and additional first molar extractions (AFMEs) on soft tissue changes after four premolar extractions in high Angle Class II division 1 patients.

Materials and Methods: Thirty-three AFME patients, 24 of who had maxillary-only AFME and 9 of who had all-four AFME, were studied by cephalometric analysis and compared with 43 patients treated with four premolar-only extractions (PRMEs) as a control group. Lateral cephalograms taken at four time points—pretreatment, before AFME, posttreatment, and retention—were utilized for statistical analysis by Student's *t*-test.

Results: AFME significantly contributed to the maxillary incisor retraction and subsequent soft tissue change as measured by the Z-angle and lower lip E line. In addition, the bivariate correlation analysis revealed that the soft tissue changes correlated more with maxillary incisor retraction than with mandibular incisor retraction in both the AFME and PRME groups. This finding suggests that, in Class II patients, the lower lip position is most affected by reduction of maxillary incisor proclination.

Conclusions: The AFME approach is useful to improve profiles in severe high Angle Class II division 1 patients who are borderline between PRME treatment and a premolar extraction plus orthognathic surgery approach.

KEY WORDS: Additional first molar extraction, High angle, Class II division 1, Z-angle.

Accepted: March 2006. Submitted: October 2005

INTRODUCTION [Return to TOC](#)

Premolar extraction is effective in changing the soft tissue profile for Class II division 1 patients.¹⁻⁵ However, in many Class II patients the clinician must sometimes deal with difficult problems, such as nongrowing adults with a large ANB or a severe discrepancy. Premolar extraction alone does not yield enough space for the correction of excessive overjet, a Class II molar relationship, and a protrusive profile because the space obtained is totally consumed by correction of the space discrepancy.

In 1975, Anderson⁶ surveyed cases where multiple extractions were performed in patients with severe discrepancies and proposed the upper first molar as one of the choices for additional extraction after first premolar extractions were undertaken. Merrifield⁷ suggested that in the Class II patient with an anterior deficit larger than 16 mm and with an ANB difference larger than 9° the first molars could be extracted after four premolar extractions. Gramling⁸ developed a Probability Index to aid in identifying difficult Class II malocclusions that may require other treatment methods, such as extraction of the maxillary first or second molars in addition to the premolar extractions. Many other clinicians^{9,10} have reported that additional molar extractions could be effective for the treatment of these patients who need more than premolar extractions but who do not want to undergo orthognathic surgery. Practically, however, additional first molar extractions (AFMEs) have rarely been a treatment option because the first molar is regarded as "a keystone of occlusion." As a result, no research has been undertaken with large-enough sample sizes to prove the effectiveness of AFMEs.

Here we report a retrospective cephalometric study of 33 patients who had AFMEs to correct residual overjet and Class II molar relationships after four premolar extractions. In all cases, the third molars were aligned to compensate for the loss of the first molars. The reasons for choosing to extract the first molar rather than the second or third molars¹¹⁻¹⁴ are twofold. First, moving first molars distally is difficult and requires the patient to wear headgear. This may not be practical, especially for adult patients. As a result, if the third or second molars are extracted, the net space available for anterior retraction is much smaller. Second, moving the first molars distally produces a "wedge effect" and worsens the high-angle and open-bite tendency.

MATERIALS AND METHODS [Return to TOC](#)



Samples

The subjects of this study were all Japanese Class II division 1 patients who were treated with AFME (n = 33) or premolar-only extractions (PRMEs) (n = 43) in the author's (TO) private practice ([Table 1](#)). The AFME group consisted of 24 maxillary-only AFME (U-AFME) patients and 9 all-four AFME (UL-AFME) patients. Five patients in the AFME group and six patients in the PRME group were younger than 14 years of age at the beginning of active treatment. The diagnostic decisions concerning extractions were made according to the Tweed-Merrifield differential diagnostic protocols.^{7,8}

The AFME treatment plan was suggested at the pretreatment stage to the patients who showed an anterior discrepancy (>16 mm, ANB $> 8^\circ$ and FMA $> 30^\circ$). After the premolar space closure, patients who still exhibited a Class II dental relationship and either a significant overjet (>4.5 mm) or protrusive profile (lower lip E line [LLip-E] > 3.0 mm) were advised to undergo AFME treatment. Over the past 20 years, the author (TO) has treated 44 patients with AFME (4.1% of all Class II division 1 patients treated); however, only cases started and completed by the author were included in this study. The 43 PRME samples were selected randomly to match the age of the AFME patients to a group of patients who achieved Class II dental relationship after four premolar extractions. In most of these PRME cases, their posttreatment overjet and LLip-E were less than those of the Japanese norm¹⁵ (overjet = 3.5 mm and LLip-E = 1.1 mm). All the samples were treated with 0.022-inch standard edgewise appliances and by the directional force system.^{2,4,16}

Cephalometric Analysis

Lateral cephalograms were taken at four time points: pretreatment (T_A), after premolar space closure (progress before AFME) (T_P), at the end of active treatment (T_B), and after retention of at least 1 year (T_C). The intervals from T_A to T_P , T_P to T_B , and T_B to T_C were designated as the premolar, AFME, and retention stages. In the PRME samples, the value of T_P was always equal to the value of T_B . Cephalograms were traced¹⁷ and digitized by using a digitizing software procedure (Dentofacial Planner Plus, Dentofacial Software Inc, Toronto, Ontario, Canada).

Landmarks suggested by Ricketts et al¹⁸ were manually placed on each tracing. Twenty-two parameters were measured and subjected to statistical analysis (Figure 1 ; Table 2 ). In addition, the Facial Height Index (FHI) was calculated as PFH divided by AFH.¹⁹ Linear displacements of the lips and incisors during treatment were examined by using the following four parameters: upper lip E line, LLip-E, U1 to APo (in millimeters), and L1 to APo (in millimeters).¹⁸

Measurement Reliability





Each landmark was identified by the author (TO) and checked for accuracy by repeating landmark selection on 10 randomly selected cephalometric radiographs. The combined tracing and measurement errors were not significant ($P < .05$) when compared by using paired two-tailed t -tests.

Statistical Analysis




Statistical analyses were performed by SPSS10.0J software (SPSS Japan, Tokyo, Japan). The mean, standard deviation of the mean, and standard error of the mean of each cephalometric value were calculated and compared by using either independent or paired Student's t -tests. All the raw data that resulted from the cephalometric analysis after the AFME treatment can be downloaded at www.t-ozaki-ooc.com/afme.html (table S1). To explore potential relationships between the soft tissue profile change and the retraction of the lips and the incisors, bivariate correlation analyses were performed and Pearson correlation coefficients were calculated.

RESULTS [Return to TOC](#)







Comparison of Pretreatment Characteristics Between the AFME Group and the PRME Group

For diagnosis and treatment planning, the following four indices (Table 1 ) were calculated at T_A : anterior discrepancy, total arch length discrepancy, Craniofacial Difficulty Index (the Probability Index proposed by Gramling,⁸ which is calculated with FMA, ANB, Z-angle, occlusal plane, SNB, and FHI), and Total Difficulty Index.⁸ There was no significant difference in the age of the sample at T_A (18 years 6 months). However, the amount of anterior discrepancy (19.53 mm, $P < .01$) and the cephalometric parameters reflecting skeletal difficulties such as Craniofacial Difficulty Index, Total Difficulty Index, ANB, and FMA at T_A were significantly larger in the AFME group than in the PRME group. In addition, the FMIA, Z-angle, and FHI of the AFME group were significantly smaller than those of the PRME group at T_A (see Figures 3  and 4 ) , as described below. These statistics confirm retrospectively that the AFME group consisted of patients with more skeletally difficult malocclusions with significantly higher FMA (37.09°) and an open-bite tendency (Table 1 ).



Skeletal Changes


No significant differences were observed in most of the cephalometric parameters reflecting the skeletal index such as FMA (Figure 2B ) , SNA, SNB, PFH, and FHI (Table 2 ) in the premolar stage or in the AFME stage. Only the ANB (Figure 2A ) and AO-BO (namely, Wits Appraisal) showed a mild decrease, suggesting a tendency toward point A retraction (SNA changed from 8.0° to 7.5°, $P < .05$; and AO-BO changed from 5.4 mm to 3.3 mm, $P < .001$).

Dental Changes


U1 to APo (Figure 3A ) and U1-FH (Figure 3B ) , indices of U1 by means of distance and angle, respectively, showed significant improvement in measurements during both the premolar and the AFME stages. L1 to APo (Figure 3C ) and FMIA (Figure 3D ) , indices of L1, also changed consistently and improved significantly in all groups during the premolar stage but improved further during the AFME stage only in the UL-AFME group (Figure 3C,D ) , white lines). At T_B , FMIA of the UL-AFME group reached the PRME value by exceeding the Japanese FMIA average of 57° after AFME, though it did not reach the Caucasian average of 65°. ²⁰ A significant decrease in overjet occurred during the AFME stage (from 6.49 mm to 2.78 mm, $P < .001$) but not in the PRME stage (Table 2 ).



Soft Tissue Changes

In the PRME group, the Z-angle increased significantly during the premolar stage (Figure 4A ) , black line). In the AFME group, the Z-angle showed no significant difference in measurements during the premolar stage but increased markedly after AFME (increasing from 53.08° at T_A to 55.03° at T_P and finally to 62.25° at T_B). This was an increment of 1.95° (20.2%, $P < .05$) during the premolar stage and 7.22° (79.8%, $P < .001$) during the AFME stage (Table 2 ). The UL-AFME contributed more to profile improvement than did the U-AFME.

The LLip-E showed a significant difference only during the AFME stage in all AFME subgroups, as did the Z-angle (changing from 5.95 mm to 4.64 mm and then to 1.14 mm). The nasolabial angle increased significantly as the maxillary incisors underwent retraction, displaying an improvement during both the premolar and AFME stages (Table 2 ).

Relationship Between Lip and Incisors

To determine which hard tissue parameters contributed most to the soft tissue profile, bivariate correlation analyses were performed on the total progress cephalometric data (between T_A and T_B) of all 76 patients. As expected, the Z-angle showed the strongest correlation with the LLip-E ($P < .001$, Pearson $r = -0.829$). Neither the Z-angle nor the LLip-E, the two most important quantifiers of the facial profile, correlated with the parameters reflecting lower incisor position (ie, L1 to APo or FMIA); however, they strongly correlated with the parameters reflecting upper incisor position (ie, U1 to APo and U1 to FH) (Table 3 ).

Correlation between U1 to APo and LLip-E is shown as the scattered plot in all 76 patients (Figure 5A ) and in the 33 AFME patients (Figure 5B ). Both the correlation coefficient (r) and the linear regression slope were larger in the AFME group. The calculated ratio of LLip-E to U1 to APo in the AFME group was 64.4%.

Stability of the AFME Approach

The cephalometric values showed no significant difference in measurements between posttreatment (T_B) and after retention for more than 1 year (T_C) (Table 2). The only statistically significant changes detected during this period were for the overbite, which increased from 3.29 mm to 4.03 mm ($P < .001$) because of denture recovery.

Case Examples of AFME

Figure 6A shows the actual profile change in one UL-AFME patient. The Z-angle changed from 48.7° (at T_A) to 52.3° (at T_P) and finally to 63.7° (at T_B). After retention (at T_C), the Z-angle was 66.9°. Figure 6B shows the superimposition of the cephalometric tracings in the Figure 6A sample.

DISCUSSION [Return to TOC](#)

The cephalometric analyses in each treatment showed that, in general, premolar extraction was less effective for the AFME group than for the PRME group. This is not surprising, for in more severe malocclusions the space gained from premolar extraction is totally consumed by correction of the Class II discrepancy and cannot be used for incisor retraction. This effect was most evident in the soft tissue profile as indicated by the Z-angle and LLip-E, which significantly improved only after AFME (Figure 4).

Bivariate correlation analyses revealed that the soft tissue profile (Z-angle) correlated most strongly with the lower lip position (LLip-E), and the lower lip retraction correlated most strongly to upper incisor movement but not to lower incisor movement (Table 3; Figure 5). This finding indicates that, for profile improvement for Class II patients, it is indispensable to move the maxillary incisors distally as much as possible in order to release the "outward curl" of the lower lip. The factors influencing the soft tissue profile changes are still controversial today.²¹⁻²³ However, this finding, together with some previous reports by Rains and Nanda²¹ and others,^{24,5,9} gives strong evidence to Angle's original suggestion and Merrifield's notion that the lower lips are pushed outward in Class II patients by the protrusive maxillary incisors.^{24,25}

It should be noted that almost all the patients in the PRME group needed their third molars extracted during or after the active treatment for Class II mechanics or posterior discrepancy, respectively. On the other hand, the treatment mechanics of AFME included subsequent third molar alignment. After the premolar extraction space closed, the maxillary (and mandibular, in some cases) first molars were extracted. The reciprocal forces of intramaxillary elastic chain and J-hook headgear forces were then applied for the distal movement of maxillary canines and incisors. The second molars were moved mesially and the third molars erupted in the former position of the second molars. The roots of third molars often developed to resemble the roots of second molars. In the final occlusion, the second premolars abutted on the second molars in a Class I dental relationship. Therefore, the total number of remaining teeth is the same in the AFME and PRME groups.

The risk of root resorption in the AFME group seemed similar to that in the PRME group. Gingival tissues appeared healthy, and no pathological problems were seen in the AFME group.

AFME is contraindicated for (1) patients younger than 15 years of age (see "Supplementary Discussion" at www.t-ozaki-oo.com/afme.html) and (2) patients with severe Class II malocclusions and a very short mandible. The UL-AFME group included two such patients whose profiles were still poor after AFME. Such patients should be referred for orthognathic surgery, because AFME cannot change the underlying skeletal pattern.²⁶

With good case selection and careful management throughout the treatment, the more severe Class II patients can obtain acceptable soft tissue profiles without orthognathic surgery. Orthodontists should be careful not to order removal of the third molars too early in these types of malocclusions before considering a possible orthodontic treatment plan with AFME in nongrowing patients.²⁷

CONCLUSIONS [Return to TOC](#)

- AFME contributed significantly to maxillary incisor retraction and a subsequent favorable soft tissue change as quantified by the Z-angle and LLip-E.
- The soft tissue changes correlated more with maxillary incisor retraction than with mandibular incisor retraction in both AFME and PRME groups.
- Moving maxillary incisors distally as much as possible, which is facilitated by AFME, is of the key importance in soft tissue improvement.

ACKNOWLEDGMENTS

We thank Shigeki Iijima for his contribution and express our sincere appreciation to James Vaden for professional discussions and suggestions.

REFERENCES [Return to TOC](#)

1. Luppapornlarp S, Johnston LE Jr. The effects of premolar-extraction: a long-term comparison of outcomes in "clear-cut" extraction and nonextraction Class II patients. *Angle Orthod*. 1993; 63:257-272.
2. Vaden JL. Sequential directional forces treatment: two Class II case reports. *Am J Orthod Dentofacial Orthop*. 1991; 99:491-504.
3. Boley JC, Pontier JP, Smith S, Fulbright M. Facial changes in extraction and nonextraction patients. *Angle Orthod*. 1998; 68:539-546.
4. Klontz HA. Facial balance and harmony: an attainable objective for the patient with a high mandibular plane angle. *Am J Orthod Dentofacial Orthop*. 1998; 114:176-188.
5. James RD. A comparative study of facial profiles in extraction and nonextraction treatment. *Am J Orthod Dentofacial Orthop*. 1998; 114:265-276.
6. Anderson BD. Multiple extraction patterns in severe discrepancy cases. *Angle Orthod*. 1975; 45:291-303.
7. Merrifield LL, Klontz HA, Vaden JL. Differential diagnostic analysis system. *Am J Orthod Dentofacial Orthop*. 1994; 106:641-648.
8. Gramling JF. The Probability Index. *Am J Orthod Dentofacial Orthop*. 1995; 107:165-171.
9. Taylor MC. *Differential Diagnosis: The Clinician's Key to Malocclusion*. Vol. 9. Tucson, AZ: Journal of the Charles H Tweed Foundation; 1981:54-66.
10. Ortial PJ. *Treatment Planning for Molar Extraction Cases*. Vol. 18. Tucson, AZ: Journal of the Charles H. Tweed Foundation; 1992:75-82.
11. Bishara SE, Ortho D, Burkey PS. Second molar extractions: a review. *Am J Orthod*. 1986; 89:415-424.
12. Basdra EK, Stellzig A, Komposh G. Extraction of maxillary second molars in the treatment of Class II malocclusion. *Angle Orthod*. 1996; 4:287-292.

13. Isaacson RJ, Lindauer SJ, Rubenstein LK. Case report: four permanent second molar extractions. *Angle Orthod.* 1993; 2:87–90.
14. Safirstein GR. Case report SB: long-term follow-up on Class II treatment with first molar extractions. *Angle Orthod.* 1996; 66:89–94.
15. Nezu H, Nagata K, Yoshida Y, Kikuchi M. *Japanese Cephalometric Visual Norms: Diagnosis of Bioprogressive Therapy.* Tokyo, Japan: Rocky Mountain Co Ltd; 1984:86–87.
16. Vaden JL, Dale JG, Klontz HA. The Tweed-Merrifield edgewise appliance: philosophy, diagnosis and treatment in orthodontics. In: *Current Principles and Techniques.* 2nd ed. Graber T, ed. St Louis, Mo: Mosby; 1994:627–684.
17. Baumrind S, Frantz RC. The reliability of head film measurements. 2. Conventional angular and linear measures. *Am J Orthod.* 1971; 60:505–517.
18. Ricketts RM, Bench RW, Hilgers JJ, Schulhof R. An overview of computerized cephalometrics. *Am J Orthod.* 1972; 61:1–28.
19. Horn AJ. Facial height index. *Am J Orthod Dentofacial Orthop.* 1992; 102:180–186.
20. Bowman SJ, Johnston LE Jr. The esthetic impact of extraction and nonextraction treatments on Caucasian patients. *Angle Orthod.* 2000; 70:3–10.
21. Rains MD, Nanda R. Soft-tissue changes associated with maxillary incisor retraction. *Am J Orthod.* 1982; 81:481–488.
22. Lo FD, Hunter WS. Changes in nasolabial angle related to maxillary incisor retraction. *Am J Orthod.* 1982; 82:384–391.
23. Talass MF, Talass L, Baker RC. Soft-tissue profile changes resulting from retraction of maxillary incisors. *Am J Orthod Dentofacial Orthop.* 1987; 91:385–394.
24. Angle EH. *Malocclusion of the Teeth.* 7th ed. Philadelphia, Pa: SS White Dental Manufacturing Co; 1907:78.
25. Merrifield LL. Dimensions of the denture: back to basics. *Am J Orthod Dentofacial Orthop.* 1994; 106:535–542.
26. Cassidy DW Jr, Herbosa EG, Rotskoff KS, Johnston LE Jr. A comparison of surgery and orthodontics in “borderline” adults with Class II, division 1 malocclusions. *Am J Orthod Dentofacial Orthop.* 1993; 104:455–470.
27. Hicks EP. Third molar management: a case against routine removal in adolescent and young adult orthodontic patients. *J Oral Maxillofac Surg.* 1999; 57:831–836.

TABLES [Return to TOC](#)

Table 1. Pretreatment Characteristics of the Study and the Control Groups^a

Groups and Extraction Sites	n	Male	Female	Age T _A , y		Anterior Discrepancy	
				Mean	SD	Mean	SD
Control group (PRME) (U4/4, L4/4) or (U4/4, L5/5)	43	9	34	18.85	4.76	15.32	6.21
Study group (AFME)							
Total	33	2	31	18.57	4.44	19.52**	5.06
U-AFME (U4/4, L4/4) or (U4/4, L5/5) and (U6/6, L8/8)	24	1	23	19.04	4.77	19.26**	4.50
UL-AFME (U4/4, L4/4) or (U4/4, L5/5) and (U6/6, L6/6) or (U6/6, L6/-, or L/6) ^b	9	1	8	17.31	3.31	20.23*	6.60

^a T_A indicates pretreatment; FHI, Facial Height Index; PRME, premolar-only extraction; AFME, additional first molar extraction; U-AFME, maxillary-only AFME; and UL-AFME, all-four AFME.

^b Missing lower first molars on either side before the beginning of active treatment (three of nine patients).

* $P < .05$; ** $P < .01$; *** $P < .001$.

Table 1. Extended

Craniofacial Difficulty Index		Total Difficulty Index		ANB		FMA		FHI	
Mean	SD	Mean	SD	Mean	SD	Mean	SD	Mean	SD
101.28	60.25	133.73	64.23	6.09	1.41	32.306	7.26	0.66	0.08
168.59***	87.11	212.70***	87.47	8.01***	2.11	37.08**	6.32	0.62*	0.06
164.80**	91.99	210.88***	91.45	8.04***	1.72	36.57*	6.60	0.62*	0.06
178.70**	76.58	217.56**	80.75	7.92**	3.04	38.47*	5.64	0.61*	0.06

Table 2. Study Group: T_A (Pretreatment), T_P (Before Additional First Molar Extraction), T_B (Posttreatment), and T_C (Retention) Mean Values and Standards Deviations of Cephalometric Measurements and Results of Statistical Comparisons

	T _A (n = 33)		T _P (n = 33)		T _B (n = 33)		T _C (n = 31)		P-Value of Paired t-Test ^a		
	Mean	SD	Mean	SD	Mean	SD	Mean	SD	T _A -T _P	T _P -T _B	T _B -T _C
Angular measurements (in degrees)											
1. FMIA	46.22	5.32	54.89	6.93	55.92	7.33	55.65	7.79	***	NS	NS
2. FMA	37.09	6.32	37.16	6.33	36.87	7.08	37.39	6.84	NS	NS	NS
3. IMPA	96.71	5.55	87.95	5.38	87.21	5.02	86.96	5.07	***	NS	NS
4. SNA	82.39	3.48	82.19	3.46	81.9	3.48	81.7	3.24	NS	NS	NS
5. SNB	74.39	3.54	74.13	3.56	74.36	3.87	74.25	3.84	NS	NS	NS
6. ANB	8.01	2.11	8.06	1.85	7.54	2.03	7.21	2.39	NS	*	NS
7. Occlusal plane	13.21	5.02	14.21	5.17	15.36	5.34	15.67	5.58	*	*	NS
8. Z angle	53.08	7.69	55.03	6.54	62.25	7.22	61.61	7.58	*	***	NS
9. U1 to FH	114.92	7.5	105.37	6.62	93.66	6.23	93.52	6.23	***	***	NS
10. Interincisal	111.66	7.36	131.29	8.53	142.11	8.13	141.78	9.18	***	***	NS
11. Nasolabial	100.95	11.33	105.06	10.41	111.91	9.79	112.24	11.17	**	***	NS
Linear measurements (in millimeters)											
12. AO-BO	5.42	4.01	4.86	2.91	3.32	2.82	3.32	3.36	NS	***	NS
13. Upper lip	11.53	1.47	13.04	1.8	14.19	2.43	14.09	2.62	***	***	NS
14. Total chin	12.48	3.04	13.4	2.21	13.4	2.32	13.18	1.98	**	NS	NS
15. AFH	71.25	5.69	72.08	5.22	71.91	5.09	72.46	4.87	**	NS	NS
16. PFH	44.01	4.51	44.84	4.59	45.47	5.13	45.5	4.38	NS	NS	NS
17. Overjet	7.27	2.92	6.49	2.33	2.78	0.81	2.76	0.83	NS	***	NS
18. Overbite	2.85	2.67	3.48	1.87	3.29	1.33	4.03	1.72	NS	NS	***
19. U1 to APo (mm)	14.17	2.39	10.43	2.74	5.52	1.6	6.03	2.18	***	***	NS
20. L1 to APo (mm)	6.26	2.62	3.08	3.25	1.95	2.05	2.21	2.29	***	**	NS
21. Upper lip E line	2.64	2.66	1.5	2.11	-0.92	2.18	-0.59	2.32	***	***	*
22. Lower lip E line	5.95	4.69	4.64	2.57	1.14	2.6	1.4	3.26	**	***	NS
Calculation											
23. FH I = PFH/AFH	0.62	0.06	0.62	0.06	0.63	0.07	0.63	0.06	NS	NS	NS

^a NS indicates not significant; * $P < .05$; ** $P < .01$; *** $P < .001$.

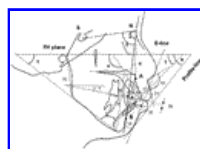Table 3. Bivariate Correlation Analysis Between Soft Tissue Changes and Incisor Movement (Pretreatment to Posttreatment)^a

	Z-angle	Lower Lip E Line
U1 to FH		
<i>r</i>	-.265	.322
<i>P</i> (two tails)	.021*	.004**
FMIA		
<i>r</i>	.183	-.133
<i>P</i> (two tails)	.114	.252
U1 to APo		
<i>r</i>	-.511	.577
<i>P</i> (two tails)	<.001***	<.001***
L1 to APo		
<i>r</i>	-.150	.181
<i>P</i> (two tails)	.197	.117

^a *r* indicates Pearson correlation coefficient.


* $P < .05$; ** $P < .01$; *** $P < .001$.

FIGURES [Return to TOC](#)




Click on thumbnail for full-sized image.

Figure 1. Cephalometric measurements. The numbers correspond to the numbered parameters in the first column of [Table 2](#)




Click on thumbnail for full-sized image.

Figure 2. Representative cephalometric skeletal parameters that did not change significantly. Each line graph represents the mean \pm standard error of the mean value of the parameters in the premolar-only extraction group (black diamond), maxillary-only additional first molar extraction (AFME) group (gray square), or all-four AFME group (white triangle). The progress during the premolar (T_A to T_P), AFME (T_P to T_B), and retention (T_B to T_C) stages were examined by the paired *t*-test, and the significance is shown in asterisks: **P* < .05; ***P* < .01, ****P* < .001



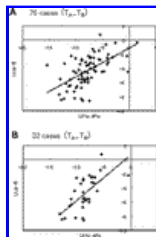
Click on thumbnail for full-sized image.

Figure 3A–D. Representative cephalometric dental parameters that changed significantly both in premolar and AFME stages. See the legend of [Figure 2](#) and the text for details



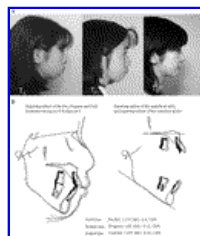
Click on thumbnail for full-sized image.

Figure 4A–B. Representative cephalometric soft tissue parameters that changed in the AFME stage but not in the premolar stage



Click on thumbnail for full-sized image.

Figure 5. Correlation between upper incisor retraction and lower lip displacement. The scattered plot shows significant correlation between U1 to APo and lower lip E line in all (AFME + PRME) samples (A) and AFME samples (B). The linear regression is superimposed, and the slope and square of the correlation coefficients (*r*) are as follows: (A) $y = 0.4082x - 1.1218$, $r^2 = 0.3332$; (B) $y = 0.6442x + 0.7692$, $r^2 = 0.4295$



Click on thumbnail for full-sized image.

Figure 6. Case example of additional first molar extraction (AFME). (A) Profile change in the all-four AFME sample. (B) Superimposed cephalometric tracing of the same sample on S-N at S, and the superimposition on palatal plane at ANS and on the mandibular plane at Me. Solid line indicates pretreatment, broken line indicates progress before AFME, and dotted line indicates posttreatment

^aPrivate Practice, Ozaki Orthodontic Clinic, Toshima-Ku, Tokyo, Japan

^bAssistant Professor, Yokohama City University General Medical Center, Department of Dental, Oral Surgery and Orthodontics, Yokohama-shi, Kanagawa, Japan

^cResearch Fellow, RIKEN Brain Science Institute, Molecular Dynamics of Mental Disorder, 2-1 Hirosawa Wako-shi, Saitama, Japan

