

[\[Print Version\]](#)
[\[PubMed Citation\]](#) [\[Related Articles in PubMed\]](#)

TABLE OF CONTENTS

[\[INTRODUCTION\]](#) [\[MATERIALS AND...\]](#) [\[RESULTS\]](#) [\[DISCUSSION\]](#) [\[CONCLUSIONS\]](#) [\[REFERENCES\]](#) [\[TABLES\]](#) [\[FIGURES\]](#)

doi: 10.2319/0003-3219(2007)077[0404:OSOIPW]2.0.CO;2
The Angle Orthodontist: Vol. 77, No. 3, pp. 404–409.

Orthodontic Space Opening in Patients with Congenitally Missing Lateral Incisors

Timing of Orthodontic Treatment and Implant Insertion

Anika Beyer;^a Eve Tausche;^b Klaus Boening;^c Winfried Harzer^d

ABSTRACT

Objective: To determine the best time to begin orthodontic treatment for patients scheduled for implants to replace congenitally missing upper lateral incisors. The aim of timing is to maximize the amount of bone available for implant insertion and to improve incisors inclination.

Materials and Methods: Seventy-three plaster casts of 14 patients with 26 missing lateral incisors were cross sectioned in the center of the planned insertion of the implant, and the implant profile was projected into the area at three different times: T1—beginning of orthodontic treatment, T2—end of orthodontic treatment, and T3—implant insertion. Deficiency of alveolar ridge volume needed for implantation was determined by Leica Quin analySIS software.

Results: An increase of ridge-volume deficiency from 0.26 mm² at T1 to 3.77 mm² at T3 was found. During orthodontic treatment the incisors protruded about 9.4° (differing from the O1-NA standard of 7.5°). To ensure optimal esthetic and functional implantation results, time management concerning orthodontic treatment has to be done carefully.

Conclusions: To avoid a high degree of alveolar bone atrophy and the risk of relapse and retreatment, orthodontic treatment involving tooth movement should not be initiated before the age of 13 years. Furthermore, it is important to maintain anchorage of the upper incisors because high incisor proclination causes extra-axial stress on the implant. An interdisciplinary approach is essential to provide the best treatment outcome.

KEY WORDS: Congenitally missing lateral incisor, Single-tooth implant, Orthodontic space opening.

Accepted: August 2006. Submitted: May 2006

INTRODUCTION [Return to TOC](#)

functional problems can arise when orthodontic space closure is realized and the canine is moved into the missing lateral incisor's space.⁴⁻⁶

If the morphological and functional conditions for orthodontic space closure are not present,³ space for the lateral incisor that has to be substituted must first be created orthodontically. The edentulous ridge can later be restored with a bridge. The resin-bonded bridge should be given particular consideration for that purpose because of its low invasiveness for the adjacent teeth. The complete survival ratio of resin-bonded bridges with anterior location is about 53% for 10.5 years.^{7,8} In some cases resin-bonded bridges have to be rebonded or be succeeded by a conventional bridge, and healthy teeth have to be prepared.

With the introduction of osseointegrated implants, new, long-lasting space management that is noninvasive for the adjacent teeth can be realized.⁹ Moreover, the canine's natural leadership function can be preserved. The patient's skeletal age determines the earliest time for implantation.¹⁰⁻¹³ There also must be enough bone on the alveolar ridge to ensure that the implant is placed in an optimal position.¹⁴⁻¹⁶ Thus, the timing of the orthodontic space opening must be carefully planned to ensure a maximum amount of available bone and adequate mesiodistal distance between the crowns and roots of the neighboring teeth.¹⁷⁻¹⁹

The purpose of this study was to determine the best time to start preprosthetic orthodontic treatment for the single-tooth implant in order to optimize the amount of bone available and the inclination incisor.

MATERIALS AND METHODS [Return to TOC](#)




Fourteen Caucasian patients (nine girls, five boys) with 26 sites of missing lateral incisors (two patients had only one missing lateral incisor) were included in the investigation. All patients with congenitally missing lateral incisors were treated at the University Hospital of Dresden between the years 1991 and 2001. Patients were transferred from GPs (general practitioners).


The primary lateral incisor was selectively extracted to encourage the permanent canine to erupt adjacently to the central incisor. This procedure avoids bone loss in the germless region. The canine erupted either between the central incisor and the deciduous canine or between the central incisor and the first premolar in cases where the primary canine was removed by resorption. After loss of the primary canine, the permanent canine was bodily moved distally to open the space for a single-tooth implant. When space is opened between the crowns, the root tips tend to move in closer. During finishing, the apices of these roots have to be moved apart from each other to provide adequate space for the surgeon to position the implant between the roots of these teeth.


The amount of bone represented by the volume of the ridge (tissue and bone) missing for an implantation was identified at the beginning of orthodontic treatment (T1: mean age 13.02 ± 1.49 years), at the end of orthodontic treatment (T2: mean age 15.55 ± 1.38 years), and at the time of implantation (T3: mean age 18.67 ± 2.83 years).

Data were obtained from 73 stone casts because 5 of the 26 sites were available only at T1 and T2, and three patients were lost in the follow-up study at T3. The casts were cross sectioned perpendicularly in the middle of the connecting line between the adjacent teeth and 90° to the occlusal plane.

Lateral incisors usually are 5.5 to 6.7 mm wide at their contact point, with an average size of 6 mm.^{15,20} Currently, the recommended diameter for a lateral incisor implant has a shaft dimension of 3.75 mm and a collar diameter of 4 mm.²¹ It is also possible to replace lateral incisors with smaller implants (3.0–3.25 mm).¹⁵ It is recommended that the implant shoulder and the adjacent root surface should be at least 1 mm apart. The shoulder should be positioned in the comfort zone to avoid the danger zone, which is located close to the adjacent root surface and is about 1.0 to 1.5 mm wide.²¹ For that reason, the needed surface calculated for implantation and sufficient bony support was 6.0 mm in the buccolingual and mesiodistal dimensions and 12.0 mm in the axial direction.

An average implant surface in the buccolingual direction measuring 6 mm by 12 mm was calculated as 72 mm^2 .^{6,21,22} This surface was projected onto the cross section of the casts ([Figure 1](#) ). The implant's inclination was matched with the inclination of the incisors in the lateral cephalogram ([Figure 2](#) ). The angle between the occlusal plane and the axial inclination of the incisors was measured and transferred to the cast ([Figure 1](#) .

The depth of the implant was determined in relation to the free gingival margin of the central incisor after orthodontic treatment. This is important, for the free gingival margin is often not in the correct position before treatment, and there can be significant changes in the nature and location of the free gingival margin during treatment. Because the lateral incisor's gingival margin is located 1 mm farther incisally than that of the central incisor, the implant had to be placed 1 mm below the gingival margin of the central incisor to position the implant's shoulder 2 mm below the prospective gingival margin as required^{18,22-25} ([Figure 1](#) .

The missing surface at T1, T2, and T3 was calculated by Leica Quin analySIS software (Soft Imaging System GmbH, Münster, Germany) ([Figure 1](#) .

For evaluating the statistical significance, the *t*-test (α -adjusted multiple testing) and Student-Newman-Keuls procedure (multiple-test procedure) were used.

RESULTS [Return to TOC](#)

Alveolar bone deficiency at T1 was on average $0.26 \text{ mm}^2 (\pm 0.69)$, increasing to $1.92 \text{ mm}^2 (\pm 1.54)$ at T2 and to $3.77 \text{ mm}^2 (\pm 3.07)$ at T3. The increase of bone deficiency at T2 and T3 was significant when compared with T1, with a level of significance of $P < .05$ (*t*-test) ([Table 1](#); [Figure 3](#)).

When categorizing the patients into early (<13.5 years) and late (≥ 13.5 years) treatment groups according to the time of orthodontic intervention, a greater ridge deficiency of $0.44 \text{ mm}^2 (\pm 0.97)$ was observed at T1 in the early treatment group compared with the late treatment group. Ridge deficiency was $2.05 \text{ mm}^2 (\pm 1.72)$ in the early treatment group at T2, which higher than the deficiency of $1.78 \text{ mm}^2 (\pm 1.64)$ in the late treatment group. However, at the time of implantation (T3) the late treatment group showed a greater deficiency of $4.93 \text{ mm}^2 (\pm 3.93)$ with wide variation in comparison with $2.61 \text{ mm}^2 (\pm 1.57)$ in the early treatment group ([Table 2](#)).

During treatment, an average increase of 9.4° in incisor protrusion was observed. Inclination averaged $22.1^\circ (\pm 6.9)$ at the beginning of treatment and $31.5^\circ (\pm 7.2)$ at the end of treatment, differing from the standard by $-0.5^\circ (\pm 7.2)$ and $+7.5^\circ (\pm 6.2)$, respectively. As a result, the inclination of the incisors increased significantly from the beginning to the end of treatment and to the time of implantation (*t*-test $P < .05$; Student-Newman-Keuls procedure $P < .05$) ([Table 3](#); [Figure 4](#)).

DISCUSSION [Return to TOC](#)

The calculated alveolar ridge deficiency can be ascribed to the vertical and most particularly buccal volume loss of the toothless alveolar ridge, which consisted of bone and soft tissue loss. Ridge deficiency increased 14-fold between T1 and T3, that is, from 0.4% at T1 to 2.7% at T2 to 5.2% at T3. When compared with the early treatment group, the late treatment group's bone deficit was less at the end of the orthodontic treatment (T2) but increased more at the time of implantation (T3). However, there were no significant differences between an early or late start of treatment at all three points in time of treatment. Probable reasons for the high variability are genetic growth factors and dentition with dominance after the end of the orthodontic treatment. The interindividual difference was greatest at T3. This strong congenital component of alveolar ridge atrophy must be kept in mind when planning implant insertion.

An important issue to focus on is the guided eruption of the canine. After the primary lateral incisor is removed, the canine erupts into the vacuum. The primary canine guides the permanent canine and should be extracted just before moving the permanent canine distally to avoid any buccolingual resorption of the ridge. As the canine is moved distally to open the space for the lateral incisor's implant, its root creates an adequate alveolar ridge through stretching of the periodontal ligament.^{15,16}

In a study of 20 patients with congenitally missing lateral incisors, Kokich²⁶ observed the amount of change that occurred across the edentulous ridge by evaluating dental casts and tomograms. The amount of bone loss was less than 1% from the end of treatment up to 4 years after treatment. These minor resorptive changes of the ridge were ascribed to this procedure of "implant site development" by the orthodontic separation of two teeth. This result differs from that of the present investigation, but it has to be considered that in our study the part of the ridge for the prospective implant area was calculated with an assumed surface of 6 to 12 mm. There are no data in the study about the detailed measurement procedure and the recommended bone volume. Previous studies show that the alveolar ridge narrows by 34% if maxillary anterior teeth are extracted.²⁷

Another study of congenitally missing mandibular second premolars demonstrated that the alveolar ridge width decreased approximately 25% over a 3-year period after extraction of the primary molar. Ridge resorption is reduced over the next 4 years, so that there is an additional 4% loss of ridge width. These findings permit extraction of the primary molar with little concern about the patient's age or the timing of implant placement.²⁸ It is difficult to compare these findings with those of the present study because we measured a surface and not a distance in the buccolingual direction. In the present study, only the upper and not the lower jaw or the premolar region was investigated. It is difficult to compare different jaw regions and conditions of bone and blood supply.

From the present point of view, it seems favorable to start active orthodontic treatment and the distal movement of the canine late. Patients starting treatment late, 16.5 years of age at the end of orthodontic treatment, are 2 years older than those who get an early start. As a result, they are closer to the potential time of implantation, and the period in which continued bone atrophy and space relapse can occur is shorter. It can be assumed that the decrease of the alveolar ridge dimension at the implant site would have been worse without using the procedure of implant site development. How to improve the development of implant site in order to create more stable bone is a question that has to be investigated. Perhaps there could have been even more bone created if the canine was first bodily moved next to the central incisor and then the root of the canine was paralleled next to the root of the central one. Only then the canine should be moved bodily backwards to open the lateral incisors space and create bone at the whole edentulous ridge.

The protrusion of the incisors (averaging 9.4°) during treatment—differing from the standard of 7.5° —can be explained by the reciprocal

space opening. Alveolar protrusion leads to unwanted extra-axial stress on the implant, resulting in a thin cervical bone lamella, which in turn raises the risk of gingival recession and the crown's margin becoming visible. There is also the added risk of implant loss as a result of the extra-axial stress. Besides the adequate bone quality with an adequate mesiodistal and buccolingual space and the inclination of the incisors, the space between the roots of the adjacent teeth also has to be taken into account. After tooth movement relating to the crowns is completed, roots often have to be moved apart from the prospective implantation site by archwire bending or bracket relocating.

Because an implant reacts like an ankylosed tooth, it should not be placed before the completion of facial growth. This time can be evaluated by superimposing cephalometric radiographs. A cephalometric radiograph is taken when a patient has completed growth in height, and another one is taken 6 months later. Facial growth can be considered as completed if there are no more changes in facial height represented by nasion to menton.^{[10–13,15](#)}

CONCLUSIONS [Return to TOC](#)

- a. Orthodontic therapy for space opening should not be started before the age of 13 years so as to prevent the relapse and progression of bone atrophy.
- b. The time of implantation should be close to the end of orthodontic treatment. As opposed to starting orthodontic space closure early, orthodontic space opening before implantation should be started late.

REFERENCES [Return to TOC](#)

1. Carlson H. Suggested treatment for missing lateral incisor cases. *Angle Orthod.* 1952; 22:205–216.
2. McNeill RW, Joondeph DR. Congenitally absent maxillary lateral incisors: treatment-planning considerations. *Angle Orthod.* 1973; 43:24–29.
3. Senty EL. The maxillary cuspid and missing lateral incisors: esthetics and occlusion. *Angle Orthod.* 1976; 46:365–371.
4. Rosa M, Zachrisson BU. Integrating esthetic dentistry and space closure in patients with missing lateral incisors. *J Clin Orthod.* 2004; 38:563–567.
5. Ward DH. Proportional smile design using the recurring esthetic dental (red) proportion. *Dent Clin North Am.* 2001; 45:143–154.
6. Sabri R. Management of missing lateral incisors. *J Am Dent Assoc.* 1999; 130:80–84.
7. Boyer DB, Williams VD, Thayer KE, Denehy GE, Diaz-Arnold AM. Analysis of debond rates of resin-bonded bridges. *J Dent Res.* 1993; 72:1244–1248.
8. Creugers NHJ, De Kanter RJAM, van't Hof MA. Long-term survival data from clinical trial on resin-bonded bridges. *J Dent.* 1997; 25:239–242.
9. Kinzer GA, Kokich VO. Managing congenitally missing incisors. Part III: single-tooth implants. *J Esthet Restor Dent.* 2005; 17:202–210.
10. Iseri H, Solow B. Continued eruption of maxillary incisors and the first molars in girls from 9 to 25 years, studied by the implant method. *Eur J Orthod.* 1996; 18:245–256.
11. Oesterle LJ, Cronin RJ. Adult growth, aging and single tooth implant. *Int J Oral Maxillofac Implants.* 2000; 15:252–260.
12. Thilander B, Ödman J, Lekholm U. Orthodontic aspects of the use of oral implants in adolescent: a 10-year follow-up study. *Eur J Orthod.* 2001; 23:715–731.
13. Westwood RM, Duncan JM. Implant in adolescents: a literature review and case reports. *Int J Oral Maxillofac Implants.* 1993; 11:377–387.
14. Kokich VG, Spear FM. Guidelines for managing the orthodontic-restorative patient. *Semin Orthod.* 1997; 3:3–20.
15. Spear FM, Mathews DM, Kokich VG. Interdisciplinary management of single-tooth implants. *Semin Orthod.* 1997; 3:45–72.
16. Zachrisson BU. Orthodontic tooth movement to regenerate new alveolar tissue and bone for improved single implant aesthetics. *Eur J*

17. Lombardi R. The principles of visual perception and their application to dental esthetics. *J Prosthet Dent.* 1973; 29:358–382.
18. Rufenacht CR. *Fundamentals of Esthetics.* Chicago, Ill: Quintessence Publishing; 1992.
19. Thilander B, Ödman J, Jemt T. Single implants in the upper incisor region and their relationship to the adjacent teeth: an 8-year follow-up study. *Clin Oral Implants Res.* 1999; 10:346–355.
20. Wexler G. Missing upper lateral incisors: orthodontic considerations in young patients. *Ann R Australas Coll Dent Surg.* 2000; 15:136–140.
21. Dickinson R. Space for missing maxillary lateral incisors— orthodontic perceptions. *Ann R Australas Coll Dent Surg.* 2000; 15:127–131.
22. Kokich VG. Maxillary lateral incisor implants: planning with the aid of orthodontics. *J Oral Maxillofac Surg.* 2004; 62:48–56.
23. Buser D, Martin W, Belser UC. Optimizing esthetics for implant restorations in the anterior maxilla: anatomic and surgical considerations. *Int J Oral Maxillofac Implants.* 2004; 19:43–61.
24. Kois JC, Kan JYK. Predictable peri-implant gingival aesthetics: surgical and prosthodontic rationales. *Pract Proced Aesthet Dent.* 2001; 13:691–698.
25. Vogel RE, Wheeler SL, Renzo CC. Restoration of congenitally missing lateral incisors: a case report. *Implant Dent.* 1999; 8:390–395.
26. Kokich V. Single-tooth implants in young orthodontic patients. *Inform Orthod Kieferorthop.* 1994; 1:45–62.
27. Carlson G. Changes in contour of the maxillary alveolar process under immediate dentures. *Acta Odontol Scand.* 1967; 25:1–31.
28. Ostler MS, Kokich VG. Alveolar ridge changes in patients congenitally missing mandibular second premolar. *J Prosthet Dent.* 1994; 71:144–149.

TABLES [Return to TOC](#)

Table 1. Bone deficiency, standard deviation (SD), and significance during treatment at beginning of orthodontic treatment (T1); end of orthodontic treatment (T2); and implant insertion (T3)

Time	Age, y (mean ± SD)	Bone deficiency, mm ² (mean ± SD)	Significance to time T1 (<i>P</i> < .05)
T1	13.02 ± 1.49	0.26 ± 0.69	—
T2	15.55 ± 1.38	1.92 ± 1.54	.044
T3	18.67 ± 2.83	3.77 ± 3.07	.028

Table 2. Bone deficiency and standard deviation (SD) during treatment at beginning of orthodontic treatment (T1); end of orthodontic treatment (T2); and implant insertion (T3)

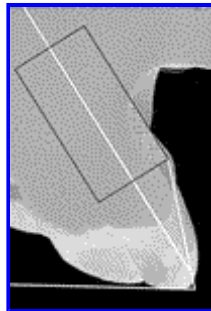
Time	Treatment group (no. of patients) ^a	Age, y (mean ± SD)	Bone deficiency, mm ² (mean ± SD)
T1	early (13)	11.67 ± 0.93	0.44 ± 0.97
	late (13)	14.91 ± 0.53	0.09 ± 0.21
T2	early (13)	14.57 ± 1.19	2.05 ± 1.72
	late (13)	16.48 ± 0.69	1.78 ± 1.54
T3	early (12)	19.23 ± 4.19	2.61 ± 1.57
	late (9)	18.64 ± 1.15	4.93 ± 3.93

^a Patients were categorized into early and late treatment groups according to time of orthodontic intervention.

Table 3. Inclination of the incisors, standard deviation (SD), and significance during treatment at beginning of orthodontic treatment (T1); end of orthodontic treatment (T2); and implant insertion (T3)

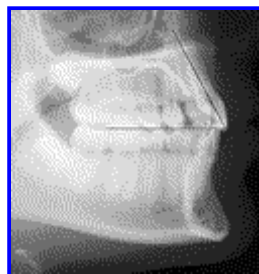Time	O1-NA, ° (mean ± SD)	O1-NA difference to standard, ° (mean ± SD)	Significance to time T1 (<i>P</i> < .05)
T1	22.11 ± 6.9	-0.5 ± 7.2	—
T2	31.56 ± 7.2	+7.5 ± 6.2	.005
T3	31.42 ± 5.5	+7.4 ± 6.1	.001

FIGURES [Return to TOC](#)




Click on thumbnail for full-sized image.

Figure 1. Cross section of the split cast. Transference of the occlusal plane and axis of the incisors from the cephalogram to the split cast. Adjustment of the implant axis to the axial inclination of the incisors. Projection of the implant surface (6 mm × 12 mm) onto the surface 1 mm below the gingival margin of the central incisor. Calculation of missing surface by the Leica Quin analySIS software




Click on thumbnail for full-sized image.

Figure 2. Analysis of the angle between occlusal plane and axis of the incisors in the cephalogram



Click on thumbnail for full-sized image.

Figure 3. Ridge deficiency at beginning of orthodontic treatment (T1), end of orthodontic treatment (T2), and implant insertion (T3) ($*P < .05$)



Click on thumbnail for full-sized image.

Figure 4. Inclination of the incisors at beginning of orthodontic treatment (T1), end of orthodontic treatment (T2), and implant insertion (T3) ($*P < .05$)

^aPostgraduate Student, University Hospital Carl Gustav Carus, Department of Orthodontics, Technical University of Dresden, Dresden, Germany

^bResident, University Hospital Carl Gustav Carus, Department of Orthodontics, Technical University of Dresden, Dresden, Germany

^cAssociate Professor, University Hospital Carl Gustav Carus, Department of Prosthodontics, Technical University of Dresden, Dresden, Germany

Professor and Department Chair, University Hospital Carl Gustav Carus, Department of Orthodontics, Technical University of Dresden, Dresden, Germany

Corresponding author: Prof Winfried Harzer, Professor and Department Chair, Department of Orthodontics, University Hospital Carl Gustav Carus, Fetscherstr 74, 01307 Dresden, Germany (E-mail: Winfried.Harzer@uniklinikum-dresden.de)