

[\[Print Version\]](#)  
[\[PubMed Citation\]](#) [\[Related Articles in PubMed\]](#)

#### TABLE OF CONTENTS

[\[INTRODUCTION\]](#) [\[MATERIALS AND...\]](#) [\[RESULTS\]](#) [\[DISCUSSION\]](#) [\[CONCLUSIONS\]](#) [\[REFERENCES\]](#) [\[TABLES\]](#) [\[FIGURES\]](#)

doi: 10.2319/042806-179  
*The Angle Orthodontist*: Vol. 77, No. 5, pp. 857-863.

## Treatment and Posttreatment Changes with Combined Headgear Therapy

Tuba Tortop,<sup>a</sup> Sema Yüksel<sup>a</sup>

### ABSTRACT

**Objective:** To determine the effects of combined headgear treatment in high-angle patients and to evaluate the differences 2 years after treatment.

**Materials and Methods:** The study material consisted of lateral cephalograms of 21 patients (13 girls and eight boys; mean age 10 years 3 months) with Class II dental relationship. Only extraoral combined traction that was applied to maxillary first molars was used in the treatment of all patients. The patients were instructed to wear the appliance 20 hours per day until the molar relationship was corrected. The treatment time was approximately 5 months. At the beginning (T0), at the end (T1), and approximately 2 years after (T2) combined headgear treatment, lateral cephalometric radiographs were obtained.

**Results:** SNA and ANB angles and convexity decreased significantly during treatment (T0-T1;  $P < .05$  and  $P < .01$ , respectively), and the net changes (T0-T2) in ANB angle and convexity were also found to be statistically significant ( $P < .01$ ). During treatment, significant distal movement was found in the upper first molar, and the second premolar and molar were also distalized significantly ( $P < .001$ ). At the end of 2 years, there was a significant mesial migration of the upper molars and the second premolar during the posttreatment period, but all of them were positioned more distally compared to the beginning of treatment ( $P < .001$ ). The decrease in molar relation was statistically significant during the T0-T1 and T0-T2 periods ( $P < .001$ ).

**KEY WORDS:** Class II, Combined headgear.

Accepted: September 2006. Submitted: April 2006

### INTRODUCTION [Return to TOC](#)

Numerous combinations of dental and skeletal relationships between the maxilla and mandible can cause Class II malocclusion.<sup>1,2</sup> In some instances, the resolution of Class II malocclusions requires distal movement of the maxillary posterior teeth. Extraoral force applied to the maxillary denture has been used for many years to correct anteroposterior relationships of the jaws and teeth.

In many well-documented experimental and clinical studies, the effect of extraoral traction on the craniofacial complex has been reported. The relation between the force of direction and the changes in the orientation of the palatal plane, the occlusal plane, and the mandibular plane has been discussed in several studies.<sup>3-8</sup> However, there are controversies regarding its action, and especially there is a debate about the effect of cervical headgear on the SNA angle, extrusion of the upper molar, inclination of the palatal plane, and variation of the mandibular plane angle. Combined use of extraoral high-pull traction and cervical traction to the maxilla has been a choice for the control of the magnitude, direction, and duration of force.<sup>9-11</sup>

To evaluate the success of orthodontic treatment, an analysis of posttreatment changes is essential. Several studies were designed to evaluate fully changes that occurred following the removal of force, but most of them dealt with long-term effects of cervical traction applied to patients with an optimum mandibular plane angle.<sup>12-16</sup> Schudy<sup>17</sup> has suggested that high-mandibular plane angle patients are especially prone to relapse. There are few studies on combined headgear therapy, and few of these are concerned with posttreatment changes. The purpose of this study was to determine the effects of combined headgear treatment in high-angle patients and to evaluate the changes 2 years after treatment.

### MATERIALS AND METHODS [Return to TOC](#)

The study material consisted of lateral cephalograms of 21 consecutively-treated patients (13 girls and eight boys) with Class II molar relationship. All cases had high-quality pretreatment, posttreatment, and 2 years posttreatment lateral cephalometric radiographs. The mean ANB was 5.2° (range 4 to 7) and the mean SN/GoGn was 40.5° (range 37.5 to 48) at the beginning of treatment. At the beginning of treatment, the patients' mean chronological age was 10 years 3 months (range 9 years to 11 years 10 months).

Only extraoral combined traction applied to the maxillary first molars was used in the treatment of all patients. All patients were treated by one of the authors. Force adjustment was made as 150 g per side for both the high-pull component and the cervical component. Force adjustments were made using a gauge. The inner bow was not expanded, and the outer bow was adjusted parallel to the occlusal plane. The patients were instructed to wear the appliance 20 hours per day until the molar relationship was corrected. Cooperation was evaluated by time schedules prepared by the patients and checked by the parents. Twelve girls and six boys had good cooperation, and one girl and two boys had moderate cooperation. The subjects were observed monthly. At every appointment, force levels and time schedules were checked. The treatment time was approximately 5 months (range 3 to 8 months).

Lateral cephalometric radiographs were taken at the beginning of treatment (T0) and after a Class I molar relationship was obtained (T1). After treatment, 16 cases were just observed without any treatment for approximately 2 years. Five cases were bonded for leveling purposes and deboned in 6 months, and these were also observed for 2 years.

Approximately 2 years after combined headgear treatment, lateral cephalometric radiographs of the cases were obtained to observe the changes that occurred during the posttreatment phase (T2). All radiographs were taken at the same laboratory with the patient oriented in a cephalostat.

All radiographs were traced, digitized, and evaluated with the JOE program (JOE Version 5.0; Rocky Mountain Orthodontics, Denver, Colo). Nine angular and eight linear measurements were determined (Figure 1). Tipping of the upper posterior teeth was measured relative to the ANS-PNS plane (Figure 2a).

To eliminate orthopedic effects and evaluate orthodontic movement of the upper posterior teeth and lower first molar, superimpositions were made. For maxillary superimpositions, cephalometric radiographs taken at T0, T1, and T2 were superimposed on the best fit of palatal structures. The ANS-PNS plane of the pretreatment radiograph was used as the horizontal reference plane. A perpendicular to the ANS-PNS plane at point T (the most superior point of the anterior wall of the sella turcica at the junction with the tuberculum sella) on the pretreatment radiograph was used as the vertical reference plane (V1; Figure 2b). For mandibular superimpositions, cephalometric radiographs taken at T0, T1, and T2 were superimposed on the best fit of the symphysis and lower contour of the mandible. The Go-Gn plane of the pretreatment radiograph was used as the horizontal reference plane, and the perpendicular to the Go-Gn plane at point T on the pretreatment radiograph was used as the vertical reference plane (V2; Figure 3). When the right and left tooth images were not coincident on the lateral cephalometric radiographs, the midpoints of the cusp images were traced. All measurements were read to the nearest 0.1 mm.

All cephalometric radiographs were retraced and redigitized and superimpositions and measurements repeated after 15 days. Method error coefficients were calculated and found within acceptable limits (range 0.94 to 0.99). The mean differences between the beginning and end of treatment (T0-T1), the end of treatment and the end of the posttreatment period (T1-T2), and the beginning of treatment and the end of the posttreatment period (T0-T2) were evaluated with the paired *t*-test.

## RESULTS [Return to TOC](#)

Treatment (T0-T1), posttreatment (T1-T2), and net changes (T0-T2) of the cephalometric measurements are given in Table 1. The SNA and ANB angles plus the angle of convexity decreased significantly during treatment (T0-T1;  $P < .05$  and  $P < .01$ , respectively). The net changes (T0-T2) in the ANB angle and convexity were also statistically significant ( $P < .01$ ).

A significant increase in CoA was observed during the T1-T2 and T0-T2 periods ( $P < .01$ ). CoGn and the maxillomandibular differential also increased significantly during T1-T2 and T0-T2 ( $P < .001$ ).

Facial depth and N-Me showed significant increases during treatment (T0-T1;  $P < .05$  and  $P < .01$ , respectively). Significant increases were observed in the net changes (T0-T2) of facial depth and maxillary height ( $P < .05$ ). S-Go and N-Me increased significantly during the T1-T2 and T0-T2 periods ( $P < .001$ ) but the S-Go/N-Me ratio showed a significant change only during the posttreatment period (T1-T2;  $P < .05$ ).

A decrease in the molar relation was found to be statistically significant during the T0-T1 and T0-T2 periods ( $P < .001$ ). The overbite decreased significantly during the posttreatment period (T1-T2;  $P < .05$ ).

Treatment (T0-T1), posttreatment (T1-T2), and net changes (T0-T2) measured on superimpositions are given in Table 2.

The upper first molar angle (U6DG) decreased significantly during treatment (T0-T1;  $P < .001$ ) and increased significantly during posttreatment (T1-T2;  $P < .01$ ). The upper second molar (U7DG) and premolar (U5DG) angles showed similar changes during treatment (T0-T1;  $P < .01$ ) and posttreatment (T1-T2;  $P < .05$ ).

Distal displacement of the upper second premolar cusp (U5CX) and upper second molar cusp (U7CX) during treatment (T0-T1) and the net changes (T0-T2) of these measurements were statistically significant ( $P < .001$ ). At the end of the posttreatment period (T2) the upper second premolar apex (U5AX) was in a more distal position than at the beginning of the treatment (T0;  $P < .05$ ).

A significant downward displacement of the upper second premolar cusp (U5CY) was found for all periods ( $P < .001$ ). The upper second premolar apex (U5AY) also showed a downward displacement for all periods (T0-T1, T1-T2, and T0-T2;  $P < .05$  and  $P < .001$ , respectively).

The upper first molar cusp (U6CX) moved significantly in a distal direction during treatment (T0-T1;  $P < .001$ ). During the posttreatment period (T1-T2) significant mesial displacement was observed ( $P < .01$ ), but evaluation of the net changes (T0-T2) showed a significant distal displacement of the upper first molar cusp ( $P < .001$ ). The downward displacements of the upper first and second molar cusps (U6CY, U7CY) and apexes (U6AY, U7AY) were statistically significant during the T1-T2 and T0-T2 periods ( $P < .001$ ).

A significant distal displacement of the upper third molar cusp (U8CX) was observed during all periods (T0-T1, T1-T2, and T0-T2;  $P < .05$ ,  $P < .05$ , and  $P < .01$ , respectively). The upper third molar cusp (U8CY) showed a downward displacement during treatment (T0-T1;  $P < .05$ ). During the T1-T2 and T0-T2 periods, downward displacements of the upper third molar cusp (U8CY) and apex (U8AY) were statistically significant ( $P < .001$  and  $P < .01$ , respectively).

## DISCUSSION [Return to TOC](#)

The purpose of this study was to examine the effects of combined headgear therapy in high-angle patients with Class II malocclusion, and to determine the stability of skeletal and dental changes 2 years after treatment.

During treatment (T0-T1) the SNA, ANB angles, and convexity decreased significantly and the changes were preserved after treatment (T1-T2). Though the net changes (T0-T2) in SNA showed no significant differences, the net changes in ANB, maxillomandibular differential, and angle of convexity were statistically significant.

Several studies have reported that after the use of cervical headgear, a posterior movement of the maxilla was achieved.<sup>7,8,18,19</sup> Long-term studies of cervical headgear treatment concluded that the SNA and ANB angles showed no significant difference between the headgear and control groups.<sup>20,21</sup>

In some studies it has been suggested that, after discontinuation of the forces, the maxilla seemed to catch up on the restricted growth.<sup>7,22</sup> In this study, an increase in CoA was not significant during treatment (T0-T1). However, the posttreatment (T1-T2) and net changes (T0-T2) showed a significant increase. Hubbard et al<sup>23</sup> showed increments in ANS-PNS and Ar-A during nonextraction cervical headgear treatment that were almost identical to the changes in the untreated Class I sample. These results might be considered as a minimization of the forward growth of the maxilla, as was done in previous studies.<sup>11,24,25</sup> The net changes (T0-T2) in ANB, the maxillomandibular differential, and the angle of convexity could be concluded to mean that the skeletal change achieved in the maxillomandibular relation was also preserved during the posttreatment period.

Either during (T0-T1) or after (T1-T2) treatment, SNGoGn, GnGoAr, and facial axis showed no significant changes. These results are parallel to the findings of studies that emphasized that no significant increase occurred in the inclination of the mandibular plane, even with the use of cervical headgear.<sup>12,21,23,26,27</sup> Badell<sup>10</sup> reported a mean increase of 0.8° in the mandibular plane angle during combined headgear therapy, but Ucem and Yüksesli<sup>11</sup> reported no significant change in this angle with the use of a headgear that had a force system similar to that which was applied in this study. Badell<sup>10</sup> reported a mean 2.4° decrease in the mandibular plane angle during the postheadgear period, unlike the nonsignificant changes in this study. This difference might be because of the pretreatment values of the mandibular plane angle.

Evaluation of the upper dental arch on superimpositions showed that, besides the upper first molar distal tipping (U6DG), the second molar and premolar (U5DG, U7DG) also showed significant distal tipping during combined headgear therapy (T0-T1). The tipping of the first molar is similar to the findings of previous combined headgear therapy studies.<sup>10,11,28</sup>

At the end of the combined headgear treatment (T1) the mean distal movement of the upper first molar cusp (U6CX) was approximately 3.2 mm. In several headgear studies, molar distalization was reported, but the amounts of distal movement differed.<sup>8,10,11,28,29</sup> No significant sagittal change was observed in the lower molar cusp (L6CX), so a decrease in molar relation was obtained by upper molar distalization. These findings are in agreement with those of other cervical headgear<sup>25,29,30</sup> and combined headgear<sup>10,11</sup> studies.

As was expected, the upper second molar, premolar, and even third molar cusps (U7CX, U5CX, and U8CX) showed significant distal movement during treatment (T0–T1). Taner et al<sup>29</sup> found that the upper second molar was moved distally a mean of 2.27 mm and reported a spontaneous distal movement of the premolar teeth with cervical headgear. Distal movement and distal tipping of the maxillary premolar and second molar were also among the significant findings with 3-D bimetric distalizing arch treatment.<sup>31</sup>

During the posttreatment period (T1–T2), a greater uprighting was observed in the first molar (U6DG). The second molar and premolar (U7DG, U5DG) showed slight mesial tipping during this period (T1–T2), and the net changes (T0–T2) of the molar and premolar angulations were not significant. Thus, it could be concluded that during the posttreatment period (T1–T2), the upper posterior teeth returned to their original angulation.

A significant mesial migration of the upper first molar (U6CX) was found during the posttreatment period (T1–T2). This finding is in accordance with findings of some other posttreatment studies relating to molar distalization.<sup>10,14,32</sup> However, in this study the amount of mesial movement was smaller than in the other studies. This mesial movement makes no difference in molar relationship because of the mandibular forward growth and the mesial migration of the lower first molar.

Through the posttreatment period (T1–T2) there were no significant changes in the upper second molar and premolar (U7CX, U5CX). The upper third molar (U8CX) showed a significant distal movement during the posttreatment period (T1–T2). Contrary to our findings, Ngantung et al<sup>32</sup> reported a 3.4 mm mesial movement of the upper second molar in a posttreatment evaluation study on distal molar movement using a distal jet appliance. This could be because of the anchorage loss in the intraoral molar distal movement systems. Also, the maintenance of the sagittal position of the upper second molar and premolar might be related to their eruption period. A distal tip position of the second molar might be the cause of distal movement of the upper third molar.

The net changes (T0–T2) showed that 2 years after treatment (T2), the upper second premolar and molars were positioned distally compared to the beginning of treatment (T0). These findings support Dewel's<sup>33</sup> statements that restoration and establishment of normal occlusal relations will give a better chance for normal development in the future.

## CONCLUSIONS [Return to TOC](#)

- During the treatment period, the premolars and molars moved and tipped distally.
- Two years after treatment, the molar relation was preserved, despite mesial migration during the posttreatment period
- Sagittal skeletal and dental changes obtained by combined headgear remained stable 2 years after removal of combined headgear forces, demonstrating that a combined headgear is a reliable method for the correction of the Class II molar relationship.

## REFERENCES [Return to TOC](#)

1. McNamara JA Jr. Components of Class II malocclusion in children 8–10 years of age. *Angle Orthod.* 1981; 51:177–202.
2. Moyers RE, Riolo ML, Guire KE, Wainwright RL, Bookstein FW. Differential diagnosis of Class II malocclusions: part 1—facial types associated with Class II malocclusions. *Am J Orthod.* 1980; 78:477–494.
3. Barton JJ. Highpull headgear versus cervical traction: a cephalometric comparison. *Am J Orthod.* 1972; 62:517–579.
4. Baumrind S, Molthen R, West EE, Miller DM. Mandibular plane changes during maxillary retraction. *Am J Orthod.* 1978; 74:32–40.
5. Brown P. A cephalometric evaluation of high-pull molar headgear and face-bow neck strap therapy. *Am J Orthod.* 1978; 74:621–632.
6. Burke M, Jacobson A. Vertical changes in high-angle Class II, division 1 patients treated with cervical or occipital pull headgear. *Am J Orthod Dentofacial Orthop.* 1992; 102:501–508.
7. Melsen B. Effects of cervical anchorage during and after treatment: an implant study. *Am J Orthod.* 1978; 73:526–540.
8. Wieslander L. The effect of force on craniofacial development. *Am J Orthod.* 1974; 65:531–538.
9. Armstrong MM. Controlling the magnitude, direction and duration of extraoral force. *Am J Orthod.* 1971; 59:217–243.
10. Badell MC. An evaluation of extraoral combined high-pull traction and cervical traction to the maxilla. *Am J Orthod.* 1976; 69:431–446.
11. Ucem TT, Yüksel S. Effects of different vectors of forces applied by combined headgear. *Am J Orthod Dentofacial Orthop.* 1998; 113:316–323.
12. Lima Filho RMA, Lima AL, de Oliveira Ruellas AC. Mandibular changes in skeletal Class II patients treated with Kloehn cervical headgear. *Am J Orthod Dentofacial Orthop.* 2003; 124:83–90.
13. Lima Filho RMA, Lima AL, de Oliveira Ruellas AC. Longitudinal study of anteroposterior and vertical maxillary changes in skeletal Class II patients treated with Kloehn cervical headgear. *Angle Orthod.* 2003; 73:187–193.
14. Melsen B, Dalstra M. Distal molar movement with Kloehn headgear: is it stable?. *Am J Orthod Dentofacial Orthop.* 2003; 123:374–378.
15. Mitani H, Brodie AG. Three plane analysis of tooth movement, growth and angular changes with cervical traction. *Angle Orthod.* 1970; 40:80–94.
16. Wieslander L, Buck DL. Physiologic recovery after cervical headgear traction therapy. *Am J Orthod.* 1974; 66:294–301.
17. Schudy FF. The rotation of the mandible resulting from growth: its implication on orthodontic treatment. *Angle Orthod.* 1965; 35:36–50.
18. Tulloch JFC, Phillips C, Koch G, Proffit WR. The effect of early intervention on skeletal pattern in Class II malocclusion: a randomized clinical trial. *Am J Orthod Dentofacial Orthop.* 1997; 111:391–400.
19. Mäntysaari R, Kantomaa T, Pirttiniemi P, Pykäläinen A. The effects of early headgear treatment on dental arches and craniofacial morphology: a report of a 2 year randomized study. *Eur J Orthod.* 2004; 26:59–64.

20. Keeling SD, Wheeler TT, King GJ, Garvan CW, Cohen DA, Cabassa S, McGorray SP, Taylor MG. Anteroposterior skeletal and dental changes after early Class II treatment with bionators and headgear. *Am J Orthod Dentofacial Orthop.* 1998; 113:40–50.

21. Pirttiniemi P, Kantomaa T, Mäntysaari R, Pykäläinen A, Krusinskiene V, Laitala T, Karikko J. The effects of early headgear treatment on dental arches and craniofacial morphology: an 8 year report of a randomized study. *Eur J Orthod.* 2005; 27:429–436.

22. Fotis V, Melsen B, Williams S. Posttreatment changes of skeletal morphology following treatment aimed at restriction of maxillary growth. *Am J Orthod.* 1985; 88:288–296.

23. Hubbard GW, Nanda RS, Currier GF. A cephalometric evaluation of nonextraction cervical headgear treatment in Class II malocclusions. *Angle Orthod.* 1994; 64:359–370.

24. Boecler PR, Riolo ML, Keeling SD, TenHave TR. Skeletal changes associated with extraoral appliance therapy: an evaluation of 200 consecutively treated cases. *Angle Orthod.* 1989; 59:263–270.

25. O'Reilly MT, Nanda SK, Close J. Cervical and oblique headgear: a comparison of treatment effects. *Am J Orthod Dentofacial Orthop.* 1993; 103:504–509.

26. Kim KR, Muhl ZF. Changes in mandibular growth direction during and after cervical headgear treatment. *Am J Orthod Dentofacial Orthop.* 2001; 119:522–30.

27. Elms TN, Buschang PH, Alexander RG. Long-term stability of Class II division 1, nonextraction cervical face-bow therapy: II. Cephalometric analysis. *Am J Orthod Dentofacial Orthop.* 1996; 109:386–392.

28. Baumrind S, Korn EL, Isaacson RJ, West EE, Molthen R. Quantitative analysis of the orthodontic and orthopedic effects of maxillary traction. *Am J Orthod.* 1983; 84:384–398.

29. Taner TU, Yukay F, Pehlivanoglu M, Cakirer B. A comparative analysis of maxillary tooth movement produced by cervical headgear and pend-x appliance. *Angle Orthod.* 2003; 73:686–691.

30. Mills CM, Holman RG, Graber TM. Heavy intermittent cervical traction in Class II treatment: a longitudinal cephalometric assessment. *Am J Orthod.* 1978; 74:361–379.

31. Ucem TT, Yüksel S, Okay C, Gülşen A. Effects of a 3D bimetric distalizing arch. *Eur J Orthod.* 2000; 22:293–298.

32. Ngantung V, Nanda RS, Bowman SJ. Posttreatment evaluation of the distal jet appliance. *Am J Orthod Dentofacial Orthop.* 2001; 120:178–185.

33. Dewel BF. Objectives of mixed dentition treatment in orthodontics. *Am J Orthod.* 1964; 50:504

TABLES [Return to TOC](#)

Table 1. Values of Cephalometric Measurements Pretreatment, Posttreatment, and 2 Years After Treatment<sup>a</sup>

	T0		T1		T2		T0–T1	T1–T2	T0–T2
	Mean	Sx	Mean	Sx	Mean	Sx			
1. SNA	78.0	0.7	77.4	0.6	77.2	0.7	*		
2. SNB	72.8	0.6	72.8	0.6	73.0	0.6			
3. ANB	5.2	0.3	4.6	0.3	4.2	0.4	**		**
4. CoA	82.6	0.8	83.1	0.9	85.3	1.1		**	**
5. CoGn	105.5	0.7	107.4	0.9	112.4	1.0	**	***	***
6. Maxillomandibular differential	23.0	0.8	24.3	0.9	27.1	1.0		***	***
7. Convexity	5.0	0.5	4.4	0.5	3.9	0.6	**		**
8. Facial depth	81.7	0.6	82.4	0.6	83.0	0.5	*		*
9. Facial axis	84.4	0.7	84.3	0.8	84.3	0.9			
10. Maxillary depth	86.5	0.7	86.5	0.6	86.6	0.7			
11. Maxillary height	61.4	0.7	61.4	0.7	62.3	0.7			*
12. SNGoGn	40.5	1.1	40.5	1.0	40.4	0.9			
13. GnGoAr	127.3	1.5	127.4	1.4	127.3	1.3			
14. S-Go	71.4	1.3	72.2	1.4	76.3	1.4		***	***
15. N-Me	117.7	1.2	119.2	1.3	124.4	1.4	**	***	***
16. S-Go/N-Me ratio	60.7	0.8	60.5	0.8	61.3	0.7		*	
17. Molar relation	0.4	0.4	–3.0	0.5	–2.9	0.5	***		***
18. Overjet	5.1	0.5	4.7	0.4	4.8	0.5			
19. Overbite	2.0	0.5	2.4	0.5	1.4	0.6		*	

<sup>a</sup> T0 indicates pretreatment; T1, posttreatment; and T2, 2 years after treatment.

<sup>b</sup> \*  $P < .05$ ; \*\*  $P < .01$ ; \*\*\*  $P < .001$ .

<sup>c</sup> Sx indicates standard of error of mean.

Table 2. Treatment, Posttreatment, and Net Changes Measured on Cephalometric Radiographs and on Superimpositions<sup>a</sup>

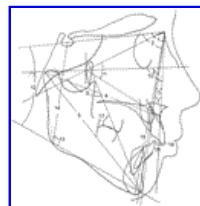	T0		T1		T2		T0-T1	T1-T2	T0-T2
	Mean	SD	Mean	SD	Mean	SD			
<b>Maxillary measurements</b>									
1. U5DG	81.3	1.2	78.6	1.0	81.3	1.2	**	*	
2. U6DG	76.7	0.9	69.6	1.3	74.4	1.2	***	**	
3. U7DG	62.6	1.9	53.3	1.3	57.5	1.5	**	*	
4. U8DG	49.2	2.7	49.3	2.8	50.2	2.8			
5. U5CX	38.1	1.1	36.1	1.2	36.3	1.2	***		***
6. U5AX	41.3	0.9	40.4	1.0	40.1	1.0			*
7. U5CY	19.9	1.3	21.7	1.1	26.3	0.7	***	***	***
8. U5AY	0.8	0.6	1.4	0.5	3.9	0.5	*	***	***
9. U6CX	32.1	1.2	28.3	1.1	29.7	1.0	***	**	***
10. U6AX	37.1	1.0	36.4	1.0	36.3	1.0			
11. U6CY	21.7	0.4	21.7	0.5	24.5	0.5		***	***
12. U6AY	0.0	0.4	0.5	0.4	2.3	0.4		***	***
13. U7CX	20.9	1.0	18.6	1.1	17.9	1.0	***		***
14. U7AX	24.9	1.9	25.3	1.9	25.0	1.7			
15. U7CY	7.3	0.7	7.8	0.7	14.3	0.9		***	***
16. U7AY	-3.5	0.4	-3.1	0.5	0.4	0.5		***	***
17. U8CX	16.7	1.0	16.1	1.0	15.4	1.0	*	*	**
18. U8AX	19.5	0.9	19.1	1.0	19.6	0.9			
19. U8CY	-4.6	0.5	-4.0	0.4	0.6	0.7	*	***	***
20. U8AY	-7.7	0.6	-7.4	0.5	-3.8	0.9		**	**
<b>Mandibular measurements</b>									
1. L6DG	83.4	1.0	83.6	0.9	81.5	1.2			
2. L6CX	60.2	0.8	60.1	0.8	61.4	0.9		***	**
3. L6AX	62.1	1.0	61.9	1.0	63.5	0.9		**	**
4. L6CY	29.1	0.6	29.4	0.6	30.8	0.6		***	***
5. L6AY	7.4	0.6	7.6	0.6	8.4	0.7		*	**

<sup>a</sup> T0 indicates pretreatment; T1, posttreatment; T2, 2 years after treatment; U5DG, upper second premolar angle; U6DG, upper first molar angle; U7DG, upper second molar angle; U8DG, upper third molar angle; U5CX, sagittal displacement of the upper second premolar cusp; U5AX sagittal displacement of the upper second premolar apex; U5CY vertical displacement of the upper second premolar cusp; U5AY vertical displacement of the upper second premolar apex; U6CX, sagittal displacement of the upper first molar cusp; U6AX sagittal displacement of the upper first molar apex; U6CY vertical displacement of the upper first molar cusp; U6AY vertical displacement of the upper first molar apex; U7CX, sagittal displacement of the upper second molar cusp; U7AX sagittal displacement of the upper second molar apex; U7CY vertical displacement of the upper second molar cusp; U7AY vertical displacement of the upper second molar apex; U8CX, sagittal displacement of the upper third molar cusp; U8AX sagittal displacement of the upper third molar apex; U8CY vertical displacement of the upper third molar cusp; U6AY vertical displacement of the upper third molar apex; L6DG, lower first molar angle; L6CX, sagittal displacement of the lower first molar cusp; L6AX sagittal displacement of the lower first molar apex; L6CY vertical displacement of the lower first molar cusp; L6AY vertical displacement of the lower first molar apex.

<sup>b</sup> \*  $P < .05$ ; \*\*  $P < .01$ ; \*\*\*  $P < .001$ .

<sup>c</sup> Sx indicates standard error of mean.

**FIGURES** [Return to TOC](#)



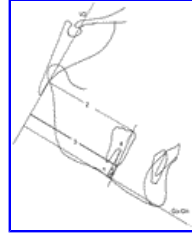
Click on thumbnail for full-sized image.

**Figure 1.** Angular and dimensional cephalometric measurements. 1 indicates SNA; 2, SNB; 3, ANB; 4, CoA; 5, Co-Gn; 6, maxillomandibular differential ( $[\text{Co-Gn}] - [\text{Co-A}]$ ); 7, convexity (Pg-N-A); 8, facial depth (N-Pg/FH); 9, facial axis (N-Ba/CC-Gn); 10, maxillary depth (NA/FH); 11, maxillary height (N-CF/CF-A); 12, SN/GoGn; 13, GnGoAr; 14, SGo; 15, NMe; 16, S-Go/N-Me ratio; 17, molar relation; 18, overjet; and 19, overbite



Click on thumbnail for full-sized image.

**Figure 2.** (a) Angular maxillary dental measurements. 1 indicates U5DG; 2, U6DG; 3, U7DG; and 4, U8DG. (b) Dimensional dental measurements on maxillary superimposition. 5 indicates U5CX; 6, U5AX; 7, U5CY; 8, U5AY; 9, U6CX; 10, U6AX; 11, U6CY; 12, U6AY; 13, U7CX; 14, U7AX; 15, U7CY; 16, U7AY; 17, U8CX; 18, U8AX; 19, U8CY; and 20, U8AY



Click on thumbnail for full-sized image.

**Figure 3.** Dimensional dental measurements on mandibular superimposition. 1 indicates L6DG; 2, L6CX; 3, L6AX; 4, L6CY; and 5, L6AY

<sup>a</sup> Professor, Department of Orthodontics, Gazi University, Ankara, Turkey

Corresponding author: Dr Tuba Tortop, Department of Orthodontics, Gazi University, 82.sok, Emek, Ankara 06510, Turkey (E-mail: [tucem@gazi.edu.tr](mailto:tucem@gazi.edu.tr))