

[\[Print Version\]](#)  
[\[PubMed Citation\]](#) [\[Related Articles in PubMed\]](#)

## TABLE OF CONTENTS

[\[INTRODUCTION\]](#) [\[MATERIALS AND...\]](#) [\[RESULTS\]](#) [\[DISCUSSION\]](#) [\[CONCLUSIONS\]](#) [\[REFERENCES\]](#) [\[TABLES\]](#) [\[FIGURES\]](#)

doi: 10.2319/071006-284.1  
*The Angle Orthodontist*: Vol. 77, No. 6, pp. 947-953.

# Mandibular Growth Changes and Cervical Vertebral Maturation

## A Cephalometric Implant Study

Yan Gu;<sup>a</sup> James A. McNamara, Jr<sup>b</sup>

### ABSTRACT

**Objective:** To evaluate mandibular dimensional changes and regional remodeling occurring during five intervals of circumpubertal growth.

**Materials and Methods:** This investigation evaluated a unique sample of subjects in whom tantalum implants were placed into the craniofacial complex during childhood. The sample was obtained from the Mathews and Ware implant study originally conducted at the University of California San Francisco in the 1970s, with longitudinal cephalometric records of 20 subjects (13 female, 7 male) available for evaluation. Cephalograms at six consecutive stages of cervical vertebral maturation (CS1 through CS6) were analyzed.

**Results:** Peak mandibular growth was noted during the interval from CS3 to CS4. Forward rotation of the mandible was due to greater mandibular growth posteriorly than anteriorly. Progressive closure of the condylar-ramus-occlusal (CRO) angle resulted in a forward and upward orientation of the ramus relative to the corpus of the mandible due to increased vertical growth of the condyle.

**Conclusions:** A peak in mandibular growth at puberty was substantiated. Mandibular remodeling and condylar rotation continue to occur after the growth spurt.

**KEY WORDS:** Cephalometrics, Metallic implants, Mandible, Growth, Remodeling, Cervical vertebral maturation method.

Accepted: November 2006. Submitted: July 2006

### INTRODUCTION [Return to TOC](#)

Serial headfilms have been used by many researchers to evaluate human mandibular growth, with the analysis typically based on regional superimposition of serial lateral cephalograms on stable anatomical structures. The sequential growth and remodeling of the mandible in children has been of interest due to its important role in orthodontic treatment.<sup>1-4</sup> An understanding of the normal growth processes enables us to differentiate the effects of orthodontic and orthopedic treatments from the changes occurring during normal growth and development.

The analysis of mandibular growth is complex because of extensive surface apposition and resorption and the difficulty in identifying stable anatomical landmarks within the mandible that can be used for the superimposition of serial headfilms. One of the obvious solutions to this problem is to establish stable, artificial reference points within the mandible. The classic studies of Björk and coworkers provided the first insights as to the pattern of craniofacial growth in humans through the analysis of serial cephalograms on metallic implants in the craniofacial complex.<sup>5-10</sup> Since that time, the use of metallic implants as reference points in longitudinal cephalometric investigations unfortunately has been exceedingly rare, with most studies conducted two or more decades ago.<sup>11-16</sup> Ødegaard produced two papers on the growth and development of the mandible, with special emphasis on mandibular rotation during growth.<sup>15,16</sup> Lavergne and Gasson<sup>14</sup> also published an investigation on mandibular growth rotation based on the Bergen material. Only a few clinical studies of orthodontic treatment have been conducted, including an early investigation of rapid maxillary expansion by Krebs.<sup>12,13</sup> Later, Breiden and coworkers evaluated the transverse changes produced by the FR-2 appliance of Fränkel also by way of metallic implants placed in the maxilla.<sup>11</sup>

Dr J. Rodney Mathews and colleagues at the University of California San Francisco were one of the few groups to conduct a longitudinal growth study similar to that of Björk and coworkers. From series of cephalograms taken annually, Mathews and Ware described the growth direction of the mandible.<sup>17</sup> Subsequently, Mathews and Payne published a study of changes in lower incisor position over time.<sup>18</sup> Baumrind and coworkers<sup>19-24</sup> also published a series of papers after further investigation of the films in the Mathews and Ware sample with the aim of describing maxillary and mandibular growth changes.

One of the themes emerging in orthodontics today that generally was not of as much interest three or four decades ago is the issue of treatment timing, with the maturational stage of the individual assuming increased importance in contemporary diagnosis and treatment planning. A variety of biologic indicators have been used over the years to evaluate skeletal maturity, including increases in body height,<sup>25</sup> maturation of the bones in the hand and wrist,<sup>26</sup> dental development and eruption,<sup>27</sup> menarche and voice changes,<sup>28</sup> as well as the maturation of the cervical vertebrae.<sup>29-32</sup> During the past several years, the relationship between the stages of cervical vertebral maturation (CVM) and mandibular growth has received increasing attention, with the CVM method shown to be effective and clinically reliable for the appraisal of mandibular skeletal maturation in growing children.<sup>29,30,33</sup>

Fortunately, the longitudinal cephalometric records of subjects in the Mathews and Ware implant study<sup>17</sup> again have been made available for evaluation. In the current study, the analysis of subjects in whom tantalum implants have been placed is combined with recent information on cervical vertebral maturation. Therefore, the primary purpose of this paper is to

evaluate the mandibular length changes from cephalometric superimpositions of metallic implants located within the mandible at six consecutive stages of cervical vertebral maturation (CS1 through CS6) and superimposed on metallic implants located within the mandible. Both changes in overall dimension and regional growth and remodeling of the mandible will be examined.

## MATERIALS AND METHODS [Return to TOC](#)

The sample consisted of the longitudinal cephalometric records of 20 of the original 36 subjects (13 female, 7 male) included in the Mathews and Ware<sup>17</sup> implant study. Eleven subjects were orthodontically untreated and nine subjects were without treatment in the mandible. Fifteen subjects showed a Class I molar relationship, and five subjects showed a Class II molar relationship. Cephalograms were available at each of the six consecutive stages of cervical vertebral maturation (CS1 through CS6; [Table 1](#)).<sup>29</sup> The average interval between cervical stages 1–5 ranged from 15 to 18 months; the interval between the last two stages (CS 5 and CS6) was 12 months.

### Cephalometric Analysis

Lateral cephalograms were hand traced by one investigator (YG), and then landmark identification, anatomical outlines, and tracing superimpositions were verified by another investigator (JMc). A customized digitization regimen and analysis was formulated with Dentofacial Planner software (Toronto, Ontario, Canada) for mandibular dimensional changes ([Figure 1](#)).

To evaluate mandibular remodeling, an occlusal reference line “X” was drawn along the functional occlusal plane (as established by the cusps of the canines, premolars, and first permanent molars) in the first headfilm; a perpendicular line “Y” was constructed through the pterygomaxillary fissure at its most superior point (Ptm) ([Figure 2](#)). This “template” provided a means of quantifying mandibular growth and remodeling (including identifying specific areas of regional deposition and resorption) relative to the position of the mandibular implants in subsequent serial headfilms, as has been described previously.<sup>34,35</sup> Not only could changes in overall mandibular morphology be determined over time, but also the precise locations at which bone deposition and resorption occurred could be identified between films.

The following mandibular regions were analyzed in each film ([Figure 2](#)):

- Superior condyilion: the most superior point on the condylar outline
- Condylion: the most posterosuperior point on the condylar outline
- Posterior condyilion: the most posterior point on the condylar outline
- Posterior border of the ramus: the point of intersection of template line “X” with the posterior ramal outline
- Posterior lower border: intersection of a perpendicular to the occlusal reference line “X” through a point on the inferior border of the mandible at the depth of the concavity of the antegonial notch
- Anterior lower border: intersection of a perpendicular to the occlusal reference line, drawn through the most mesial contact point of the mandibular first permanent molar to the lower border of the mandible
- Menton: the most inferior point on the symphyseal outline
- Pogonion: the most anterior point on the symphyseal outline

In addition, the condylar-ramus-occlusal (CRO) angle was determined by the intersection of the posterior border of the ramus with the horizontal template line “X”.

Skeletal maturation was assessed by the first author and then checked by two independent examiners experienced in the CVM method<sup>29</sup> (the second author and Dr Tiziano Baccetti). Agreement as to CVM staging was reached on each film.

### Statistical Analysis

Statistical analysis was carried out with SPSS v14.0 (SPSS Inc, Chicago, Ill). In that the films chosen were based on CVM stage, not chronological age, and because of the small number of available subjects for this unique sample, female and male subjects were pooled. Descriptive statistics were calculated for all variables at each stage and interval ([Tables 2](#) and [3](#)). One-way analysis of variance (MANOVA) was performed to compare cephalometric changes over five observation intervals (CS1–CS2, CS2–CS3, CS3–CS4, CS4–CS5, and CS5–CS6).

Sixty lateral cephalograms chosen at random were retraced and redigitized by the same examiner to determine the intraexaminer error resulting from landmark selection. Intraclass correlation coefficients were calculated to compare within-subjects variability to between-subjects variability. All correlation coefficients were greater than .95.

## RESULTS [Return to TOC](#)

### Overall Mandibular Dimensions

The greatest increase in mandibular length (Co-Gn) occurred during growth interval CS3 to CS4; the observed average increase was 4.1 mm ([Table 3](#)). During the interval CS5–CS6, a smaller amount of mandibular growth was noted; the observed average increase was 1.3 mm ([Table 3](#)). Ramus length (Co-Go) and corpus length (Go-Me) increased steadily from CS1 through CS6, both exhibiting the greatest change occurring during the growth interval CS3 to CS4 (2.1 mm and 2.8 mm, respectively). Mandibular growth changes from CS3 to CS4, CS1 to CS2, and CS5 to CS6 were statistically significant.

Measurements of upper and lower anterior facial height (Na-ANS and ANS-Me, respectively; [Figure 1](#)) increased similarly during the six stages of cervical vertebral maturation. Once again, the greatest increases occurred during CS3 to CS4 ([Table 3](#)). The most pronounced difference between incremental increases in posterior facial height (PFH) and lower anterior facial height (LAFH) was noted during the interval from CS4 to CS5, with a difference of 1.7 mm ([Table 3](#)). The gonial angle (Co-Go-Me; [Figure 1](#)) closed progressively from CS1 to CS6, with a reduction in average value of about  $-1.0^\circ$  occurring during three intervals ([Tables 2](#) and [3](#)). Mandibular rotation, measured as the angular change between the implant reference line “X” and the Frankfort horizontal in serial films, was observed from CS1 through CS6, with a decrease of approximately  $0.5^\circ$ – $1^\circ$  noted during each growth interval ([Table 3](#)).

### Mandibular Remodeling

The greatest amount of bone apposition at condyilion occurred during CS3–CS4, with an average increase of 4.2 mm ([Table 4](#)). During the last growth interval studied (CS5–CS6), the addition of bone at condyilion decreased to 2.2 mm, nearly half of that observed during CS3–CS4 ([Table 4](#)). Remodeling changes in the condyle from CS3 to CS4 and from CS5 to CS6 were statistically significant.

The most pronounced deposition at superior condyion was noted during the interval from CS4 to CS5, with an average value of 3.7 mm (Table 4). Deposition at posterior condyion remained relatively constant during the five intervals studied, with slightly more observed from CS2 to CS3; the average value was 1.7 mm (Table 4).

The absolute amount of bone apposition at the posterior border of the mandibular ramus also did not change remarkably over the five observation intervals, although apposition during the intervals from CS3 to CS4 and CS4 to CS5 was almost twice that observed during CS1 to CS2, with average values of 1.1 mm and 0.6 mm, respectively (Table 4). Gradual bone deposition at the anterior lower border of the mandibular corpus was noted from CS1 to CS6 with an average value of about 1.0 mm, whereas there was gradual bone resorption at the posterior lower border of corpus (Table 4; Figures 3 and 4).

No bone remodeling was noted at Pogonion from CS1 to CS6 when the distance from Pogonion to a reference line "Y" was measured. Minor bone apposition was recorded along the lower border of the symphysis at Menton, with less than 0.5 mm observed during each interval (Table 4, Figures 3 and 4).

The relationship between the ramus and the corpus of the mandible was determined by the condylar-ramus-occlusal (CRO) angle, which was formed by the posterior plane of ramus and the horizontal template line "X." The CRO angle decreased steadily from CS1 to CS6. The greatest decreases were found during the intervals from CS1 to CS2 and from CS4 to CS5; average decreases of  $-1.8^\circ$  occurred during both of these intervals (Table 4).

## DISCUSSION [Return to TOC](#)

The current study took the advantage of the unique Mathews and Ware implant sample and evaluated mandibular dimensional changes and regional remodeling, based on cephalograms available at six consecutive stages of cervical vertebral maturation (CS1 through CS6).

In the sample analyzed, the peak in mandibular growth occurred from CS3 to CS4, a finding that is in agreement with the work of Franchi and colleagues on untreated subjects.<sup>30</sup> The average increase in mandibular length from CS3 to CS4 was almost twice that measured from CS1 to CS2 and three times that measured from CS5 to CS6. It should be noted, however, that the average interval length from CS5 to CS6 was 12 months; the average duration of the other interval was 16 or 17 months (Table 3). Also, the largest closure of the gonial angle was observed at the peak interval of CS3 to CS4, in agreement with previous findings of a morphometric study of mandibular growth, that showed the greatest amount of anterior morphogenetic rotation of the mandible at the peak.<sup>33</sup>

Peak bone apposition at condyion occurred during the same interval in the present study. This observation seems to substantiate the findings of Björk<sup>5</sup> that increases in mandibular length occur primarily at the condyles. Moreover, a smaller amount of mandibular dimensional changes and bone remodeling at the condyle was noted from CS5 to CS6. With the exception of Co-Go, growth in all other measures during CS5–CS6 was approximately half or one-third of its peak increment. These results support the idea that the cervical vertebral maturation method is efficient in detecting the peak in mandibular growth.

Furthermore, the results of the present study also substantiate previous findings that no visible remodeling occurs at the anterior border of the symphysis (Pogonion) with only minor bone deposition along the lower border of the symphysis (Menton) during adolescence.<sup>5,6,17</sup> Bone apposition on the anterior portion of the lower border and resorption along the posterior portion of the lower border of the corpus contributed to the observed change in mandibular shape.

The progressive closure of the CRO angle observed in our study implied an increasingly forward and upward orientation of the ramus with respect to the corpus; a forward rotation of the mandible relative to the Frankfort Horizontal was noted. Interval increases in posterior facial height always were greater than simultaneous increases in lower anterior facial height. These results confirmed the findings of Björk<sup>6</sup> that growth in the posterior region of the mandible usually exceeds that in the anterior region, which contributes to the forward rotation of mandible in most subjects. Furthermore, the current findings substantiate Björk's<sup>8–10</sup> observations that vertical growth at the condyle is the primary contributor to increases in posterior facial height and that the mechanism of forward mandibular rotation is related closely to the concomitant vertical direction of condylar growth.

## CONCLUSIONS [Return to TOC](#)

- The peak increase in mandibular length, along with greatest bone apposition at condyion, was observed during the interval CS3–CS4.
- Forward mandibular rotation occurred, due to greater mandibular growth posteriorly than anteriorly.
- Progressive closure of the CRO angle demonstrated increasingly forward and upward orientation of the ramus with respect to corpus, and was attributed to the observed vertical condylar growth.
- Mandibular remodeling and condylar rotation continue over a relatively long period of time, even after the peak in mandibular growth had occurred.

## ACKNOWLEDGMENTS

The authors wish to thank Dr Tiziano Baccetti for having acted as an expert consultant in the evaluation of stages in cervical vertebral maturation and for his help with the statistical analyses. The lateral cephalograms from the Mathews and Ware collection were made available through the generosity of Dr Sheldon Baumrind. Funding for this project, in part, was through the Thomas M. and Doris Graber Endowed Professorship in the Department of Orthodontics and Pediatric Dentistry at the University of Michigan.

## REFERENCES [Return to TOC](#)

1. Bambha JK, Van Netta P. Longitudinal study of facial growth in relation to skeletal maturation during adolescence. *Am J Orthod.* 1963; 49:481–493.
2. Lewis AB, Roche AF, Wagner B. Growth of the mandible during pubescence. *Angle Orthod.* 1982; 52:325–341.
3. Maj G, Luzi C. Analysis of mandibular growth on 28 normal children followed from 9 to 13 years of age. *Trans Eur Orthod Soc.* 1962; 36:141–158.
4. Tracy WE, Savara BS. Norms of size and annual increments of five anatomical measures of the mandible in girls from 3 to 16 years of age. *Arch Oral Biol.* 1966; 11:587–598.
5. Björk A. The use of metallic implants in the study of facial growth in children: method and application. *Am J Phys Anthropol.* 1968; 29:243–254.
6. Björk A. Variations in the growth pattern of the human mandible: longitudinal radiographic study by the implant method. *J Dent Res.* 1963; 42:400–411.
7. Björk A. Cranial base development. *Am J Orthod.* 1955; 41:198–225.
8. Björk A. Prediction of mandibular growth rotation. *Am J Orthod.* 1969; 55:585–599.

9. Björk A, Skieller V. Normal and abnormal growth of the mandible. A synthesis of longitudinal cephalometric implant studies over a period of 25 years. *Eur J Orthod.* 1983; 5:1–46.
10. Björk A, Skieller V. Facial development and tooth eruption. An implant study at the age of puberty. *Am J Orthod.* 1972; 62:339–383.
11. Breiden CM, Pangrazio-Kulbersh V, Kulbersh R. Maxillary skeletal and dental change with Fränkel appliance therapy—an implant study. *Angle Orthod.* 1984; 54:232–266.
12. Krebs A. Midpalatal suture expansion studies by the implant method over a seven year period. *Trans Eur Orthod Soc.* 1964; 40:131–142.
13. Krebs A. Expansion of the midpalatal suture studies by means of metallic implants. *Trans Eur Orthod Soc.* 1958; 34:163–171.
14. Lavergne J, Gasson N. A metal implant study of mandibular rotation. *Angle Orthod.* 1976; 46:144–150.
15. Ødegaard J. Mandibular rotation studied with the aid of metal implant. *Am J Orthod.* 1970; 57:448–454.
16. Ødegaard J. Growth of the mandible studied with the aid of metal implant. *Am J Orthod.* 1970; 57:145–157.
17. Mathews JR, Ware WH. Longitudinal mandibular growth in children with tantalum implants. *Am J Orthod.* 1978; 74:633–655.
18. Mathews JR, Payne GS. Quantitative computerized analysis of lower incisor changes: a longitudinal implant study in man. *Angle Orthod.* 1980; 50:218–229.
19. Baumrind S, Ben-Bassat Y, Korn EL, Bravo LA, Curry S. Mandibular remodeling measured on cephalograms: 2. A comparison of information from implant and anatomic best-fit superimpositions. *Am J Orthod Dentofacial Orthop.* 1992; 102:227–238.
20. Baumrind S, Ben-Bassat Y, Korn EL, Bravo LA, Curry S. Mandibular remodeling measured on cephalograms. 1. Osseous changes relative to superimposition on metallic implants. *Am J Orthod Dentofacial Orthop.* 1992; 102:134–142.
21. Baumrind S, Korn EL. Postnatal width changes in the internal structures of the human mandible: a longitudinal three-dimensional cephalometric study using implants. *Eur J Orthod.* 1992; 14:417–426.
22. Baumrind S, Korn EL, Ben-Bassat Y, West EE. Quantitation of maxillary remodeling. 2. Masking of remodeling effects when an “anatomical” method of superimposition is used in the absence of metallic implants. *Am J Orthod Dentofacial Orthop.* 1987; 91:463–474.
23. Baumrind S, Korn EL, Ben-Bassat Y, West EE. Quantitation of maxillary remodeling. 1. A description of osseous changes relative to superimposition on metallic implants. *Am J Orthod Dentofacial Orthop.* 1987; 91:29–41.
24. Korn EL, Baumrind S. Transverse development of the human jaws between the ages of 8.5 and 15.5 years, studied longitudinally with use of implants. *J Dent Res.* 1990; 69:1298–1306.
25. Hunter CJ. The correlation of facial growth with body height and skeletal maturation at adolescence. *Angle Orthod.* 1966; 36:44–54.
26. Greulich WW, Pyle SI. *Radiographic Atlas of Skeletal Development of the Hand and Wrist.* Stanford: Stanford University Press; 1959.
27. Hellman M. The process of dentition and its effects on occlusion. *Dent Cosmos.* 1923; 65:1329–1344.
28. Hägg U, Taranger J. Menarche and voice changes as indicators of the pubertal growth spurt. *Acta Odontol Scand.* 1980; 38:179–186.
29. Baccetti T, Franchi L, McNamara JA Jr. The cervical vertebral maturation method for the identification of optimal treatment timing. *Semin Orthod.* 2005; 11:119–129.
30. Franchi L, Baccetti T, McNamara JA Jr. Mandibular growth as related to cervical vertebral maturation and body height. *Am J Orthod Dentofacial Orthop.* 2000; 118:335–340.
31. O'Reilly MT, Yanniello G. Mandibular growth changes and maturation of cervical vertebrae: a longitudinal cephalometric study. *Angle Orthod.* 1988; 58:179–184.
32. Lamparski DG. *Skeletal Age Assessment Utilizing Cervical Vertebrae.* [master thesis]. Department of Orthodontics. Pittsburgh: The University of Pittsburgh; 1972.
33. Franchi L, Baccetti T, McNamara JA Jr. Thin-plate spline analysis of mandibular growth. *Angle Orthod.* 2001; 71:83–92.
34. McNamara JA Jr, Graber LW. Mandibular growth in the rhesus monkey (*Macaca mulatta*). *Am J Phys Anthropol.* 1975; 42:15–24.
35. McNamara JA Jr, Bryan FA. Long-term mandibular adaptations to protrusive function in the rhesus monkey (*Macaca mulatta*). *Am J Orthod Dentofacial Orthop.* 1987; 92:98–108.

**TABLES** [Return to TOC](#)

**Table 1.** Summary of Sample in Each Cervical Vertebral Maturation Stage

	CS1	CS2	CS3	CS4	CS5	CS6
Mean age, years	9.0 ± 1.1	10.3 ± 1.0	11.7 ± 0.9	13.0 ± 0.9	14.6 ± 1.1	15.6 ± 1.0
Female	13	13	13	13	13	12
Male	7	7	7	6	7	7
Total	20	20	20	19	20	19

**Table 2.** Descriptive Statistics for Mandibular Dimensional Measurements at the Six Stages of Cervical Vertebral Maturation (mm)

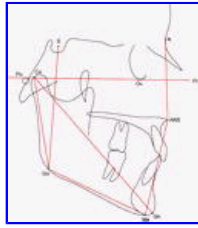	CS1		CS2		CS3		CS4		CS5		CS6	
	9.0 ± 1.1 Years		10.3 ± 1.0 Years		11.7 ± 0.9 Years		13.0 ± 0.9 Years		14.6 ± 1.1 Years		15.6 ± 1.0 Years	
	Mean	SD	Mean	SD	Mean	SD	Mean	SD	Mean	SD	Mean	SD
<b>Mandibular measurements</b>												
Mandibular length: Co-Gn	104.7	5.2	106.9	5.5	109.9	5.5	113.9	4.9	117.1	5.7	118.3	5.6
Ramal length: Co-Go	51.6	3.8	53.0	4.7	54.9	3.9	56.9	4.1	59.6	5.5	61.0	5.8
Corpus length: Go-Me	60.3	3.8	62.3	4.1	64.5	4.4	67.2	4.0	68.2	3.7	69.5	4.6
Go angle	129.9	3.1	128.9	3.6	128.6	4.1	127.6	3.2	126.9	3.7	126.8	4.4
<b>Vertical measurements</b>												
UFH: Na-ANS	48.1	2.3	49.5	2.4	50.7	2.3	52.9	2.2	54.7	2.1	55.3	2.0
LAFH: ANS-Me	62.3	4.4	63.6	4.6	65.3	4.7	67.0	5.1	68.3	5.7	69.4	6.2
PFH: S-Go	48.3	3.3	49.9	4.2	51.7	4.2	54.1	4.4	56.6	4.9	57.3	5.2
<b>Overall measurements</b>												
Mandibular rotation, degrees	27.1	5.3	26.0	5.9	24.9	6.4	23.6	6.7	23.0	6.8	22.8	7.0

**Table 3.** Mandibular Dimensional Changes in Five Intervals of Cervical Vertebral Maturation Stages

	CS1-CS2 (15 m)		CS2-CS3 (16 m)		CS3-CS4 (17 m)		CS4-CS5 (18 m)		CS5-CS6 (12 m)	
	Mean	SD	Mean	SD	Mean	SD	Mean	SD	Mean	SD
<b>Mandibular measurements</b>										
Mandibular length Co-Gn	2.2	1.3	3.0	1.2	4.1	2.5	2.5	2.0	1.3	1.4
Ramal length: Co-Go	1.3	2.2	1.9	2.2	2.1	1.5	2.2	3.0	1.4	2.3
Corpus length: Go-Me	2.1	2.5	2.1	2.1	2.7	2.4	1.3	2.2	1.3	2.0
<b>Vertical measurements</b>										
UFH: Na-ANS	1.4	1.6	1.2	1.3	2.3	1.7	1.6	1.7	0.5	1.6
LAFH: ANS-Me	1.3	1.8	1.6	1.6	1.9	1.9	0.6	2.1	1.0	2.1
PFH: S-Go	1.5	1.5	1.8	1.4	2.5	1.9	2.3	2.5	0.7	1.6
<b>Overall measurements</b>										
Mandibular rotation, degrees	1.1	1.7	1.1	1.5	1.2	1.8	0.8	1.8	0.5	1.3

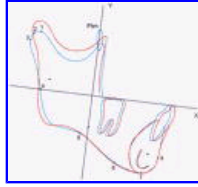
**Table 4.** Remodeling Changes of the Mandible in Five Intervals of Cervical Vertebral Maturation Stages

	CS1-CS2 (15 months)		CS2-CS3 (16 months)		CS3-CS4 (17 months)		CS4-CS5 (18 months)		CS5-CS6 (12 months)	
	Mean	SD	Mean	SD	Mean	SD	Mean	SD	Mean	SD
<b>Condylar region</b>										
Condylion	3.2	1.5	3.3	1.8	4.2	1.5	3.6	2.4	2.2	1.3
Superior condylion	2.5	1.3	3.4	2.2	3.2	1.5	3.7	2.9	1.5	1.5
Posterior condylion	1.3	1.4	1.7	1.4	1.3	1.2	1.1	1.2	0.8	0.8
<b>Mandibular ramus</b>										
Posterior border	0.6	0.7	0.7	0.9	1.1	0.9	1.1	1.2	0.9	0.6
<b>Mandibular corpus</b>										
Anterior lower border	0.4	0.7	0.9	0.7	0.8	1.1	0.6	1.1	0.3	0.7
Posterior lower border	-0.9	0.6	-0.8	0.9	-0.7	0.8	-0.3	0.7	-0.4	0.8
<b>Symphysis</b>										
Pogonion	0.0	0.7	0.0	0.4	0.0	0.4	0.1	0.4	0.0	0.5
Menton	0.0	0.5	0.5	0.6	0.3	0.7	0.1	0.6	0.2	0.6
<b>Ramus-corporis relationship</b>										
CRO angle, degrees	-1.8	1.8	-1.2	1.6	-1.3	1.4	-1.8	2.2	-0.6	1.7



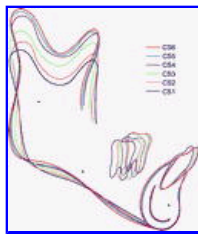
Click on thumbnail for full-sized image.

**Figure 1.** Measurements of mandibular dimensions



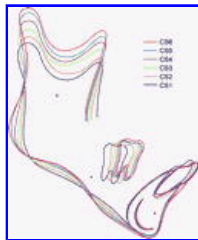Click on thumbnail for full-sized image.

**Figure 2.** Reference lines and reference points for mandibular remodeling analysis. 1. Superior Condylion; 2. Condylion; 3. Posterior Condylion; 4. Posterior Border of Ramus; 5. Posterior Lower Border; 6. Anterior Lower Border; 7. Menton; 8. Pogonion



Click on thumbnail for full-sized image.

**Figure 3.** Composite tracings of the six stages of cervical vertebral maturation. Superimposition is on the tantalum implants. Note that the largest increment of condylar growth occurred between stages CS3 and CS4. Note also the forward and upward movement of the molar and the primarily forward movement of the incisor



Click on thumbnail for full-sized image.

**Figure 4.** Composite tracings of another subject in the series in whom the difference in condylar growth increment was not as pronounced. In [Figures 3](#) and 4, deposition along the anterior lower border of the corpus and resorption posteriorly in the antegonial region can be observed

<sup>a</sup> Associate Professor, Department of Orthodontics, School of Stomatology, Peking University, Beijing, China

<sup>b</sup> Thomas M. and Doris Graber Endowed Professor of Dentistry, Department of Orthodontics and Pediatric Dentistry, School of Dentistry; Professor of Cell and Developmental Biology, School of Medicine; and Research Professor, Center for Human Growth and Development, The University of Michigan, Ann Arbor, Mich. Private practice of orthodontics, Ann Arbor, Mich

Corresponding author: Dr James A. McNamara, Department of Orthodontics and Pediatric Dentistry, The University of Michigan, 1011 North University Avenue, Ann Arbor, MI 48109-1078 (E-mail: [mcnamara@umich.edu](mailto:mcnamara@umich.edu))