

[\[Print Version\]](#)
[\[PubMed Citation\]](#) [\[Related Articles in PubMed\]](#)

TABLE OF CONTENTS

[\[INTRODUCTION\]](#) [\[MATERIALS AND...\]](#) [\[RESULTS\]](#) [\[DISCUSSION\]](#) [\[CONCLUSION\]](#) [\[REFERENCES\]](#) [\[TABLES\]](#) [\[FIGURES\]](#)

doi: 10.2319/081406-332

The Angle Orthodontist: Vol. 77, No. 6, pp. 1046–1053.

Upper Airway Dimensions in Class II Malocclusion

Effects of Headgear Treatment

Mirja Kirjavainen;^a Turkka Kirjavainen^b

ABSTRACT

Objective: To study the effects of cervical headgear treatment of Class II division 1 malocclusion on upper airway structures in children.

Materials and Methods: Forty children aged 9.1 (7.2–11.5) years with Class II division 1 malocclusion were treated using a cervical headgear as the only treatment appliance. The headgear consisted of a long outer bow bent 15° upward and a large inner bow expanded 10 mm larger than the intermolar distance. Lateral cephalograms were taken before and after the treatment. Upper airway structures were estimated from the cephalograms. The results were compared to cross-sectional data of 80 age-matched controls with a Class I molar relationship.

Results: A Class I molar relationship was achieved in all treated children. The mean treatment time was 1.6 (0.3–3.1) years. The Class II malocclusion was accompanied by a similar or wider nasopharyngeal space than in the controls but narrower oro- and hypopharyngeal spaces. The retropalatal area was widened by the treatment ($P < .05$), whereas the rest of the oropharynx and hypopharynx remained narrower than in the controls. Before the treatment, the mandibular plane was in a more horizontal position than in the controls, but during the treatment, it rotated to a position similar to that of the controls.

Conclusion: Class II division 1 malocclusion is associated with a narrower upper airway structure even without retrognathia. Headgear treatment is associated with an increase in the retropalatal airway space.

KEY WORDS: Cephalometry, Headgear, Orthodontic, Malocclusion, Angle Class II, Upper airway.

Accepted: November 2006. Submitted: August 2006

INTRODUCTION [Return to TOC](#)

A cervical headgear with an expanded inner bow may be used alone to treat Class II division 1 malocclusion.^{1–3} This form of treatment is associated with the widening of maxilla together with upward and forward rotation of the mandible. These effects would be expected to be accompanied by an increase in upper airway space and should be favorable for breathing. Consistent with this, maxillary expansion has been shown to decrease the presence of upper airway obstruction during sleep in young adults with mild or moderate obstructive sleep apnea.⁴ However, there is one preliminary report that the use of headgear treatment could predispose a patient to upper airway obstruction during sleep.⁵

The purpose of this study was to examine the upper airway structures in children with Class II malocclusion to determine the effects of headgear treatment on upper airway dimensions.

MATERIALS AND METHODS [Return to TOC](#)

Patients

Upper airway structures were studied in 40 consecutively referred healthy school children (20 boys and 20 girls) who were referred for treatment because of a Class II division 1 malocclusion. The inclusion criteria were (1) Class II malocclusion with an overjet of more than 2 mm, (2) a protrusive maxilla indicated in a cephalometric analysis by the A-point's being in front of the nasion-pogonion line, (3) the availability of pretreatment and posttreatment plaster models and lateral and posteroanterior cephalograms, (4) between the age of 7 and 12 years at the date of referral, (5) good general health, and (6) good or at least moderate cooperation. The mean age of the children at the beginning of treatment was 9.1 ± 1.0 (range, 7.2–11.5) years and at the end of the treatment 10.7 ± 1.1 (range, 8.6–13.0) years.

The results were compared to the control cephalograms of 80 children (aged 6–14 years) with a Class I molar relationship. Ten controls, five girls and five boys, were blindly selected for each 8-year group from the cross-sectional normal population of 538 Finnish schoolchildren (282 boys and 256 girls). The normal population data were collected between 1965 and 1968,⁶ but the cephalograms were reanalyzed for the purposes of this study. There were no data available concerning adenoids and tonsils in this population.

The study protocol was approved by the Ethics Review Committee of the Hospital for Children and Adolescents, Helsinki University Hospital.

The first author treated the children with Class II malocclusion with an orthopedic cervical headgear without any other appliances during the study periods in the Health Center of

Forssa. A Kloehn-type cervical headgear with a large inner bow and long outer bow was used. The treatment methodology has been described previously in detail.¹⁻³ The inner bow of the headgear was expanded 10 mm larger than the distance between the maxillary first molar tubes and made parallel to the occlusal plane. To prevent distal tipping of the first molar crowns and extrusion of the first molars over the amount of the normal eruption, a long rigid outer bow bent 15° upward was used. The cervical traction force was 500 g per side. The expansion of the inner bow and the amount of force used were adjusted at 6- to 8-week intervals. The subjects were asked to wear the headgear 12 to 14 hours a day, in the evenings and at nights, and to keep a daily diary of their headgear wear. Cooperation was estimated according to the diary notes and signs of use, including the tearing of the elastic band and neck strap. The posttreatment cephalograms were taken when a Class I molar relationship was achieved.

Cephalometric Landmarks and Reference Planes

To analyze the effects of the cervical headgear therapy on upper airway dimensions, lateral cephalograms were taken before and after the treatment using a cephalostat (Cranex DC2, Tuusula, Finland). The linear measurements and angles were calculated using special purpose software. The used landmarks are defined in [Table 1](#) and presented in [Figure 1](#). Lines parallel to the Frankfort horizontal plane (Po-O) were used in the determination of counterpart landmarks for ve, p, ph, and eb on the posterior pharyngeal wall. The linear measures were corrected for magnification of the cephalograms.

Statistical Methods

For the definition of normal mean values, a fourth-order polynomial equation was fitted to the control group data using nonlinear curve fitting by GraphPad Prism 4.0 (GraphPad Software Inc, San Diego, Calif; [Figure 2](#)). This calculated fitted mean was used to estimate the normal mean value for each particular age and to compare with the study group. The comparisons between the groups were performed using a paired *t*-test. Statistical analyses were calculated using SPSS 12.0.1 (SPSS Inc, Chicago, Ill). Paired *t*-tests were also used to compare the pretreatment and posttreatment measurements. Correlations between variables were calculated by linear regression analyses, and *P* < .05 was considered statistically significant. The values are presented in the form of mean ± standard deviation.

Method Error

Serial pretreatment and posttreatment measurements were taken in five randomly selected children to assess measurement repeatability. The method error was estimated using the Dahlberg formula⁷:

$$ME = \sqrt{\frac{\sum d^2}{2n}},$$

and the results are presented in [Table 2](#). The presence of systematic error was estimated by Forsberg's method.⁸ The significance tests of the mean differences (\bar{d}) were calculated according to the formula

$$t = \frac{\bar{d}}{\sqrt{\frac{\sum d^2}{n \cdot (n - 1)}}}.$$

The measurement was considered to be free of systematic error if the *t* value was within the limits $-2.07 < t < 2.07$. All of the measurements were free of systematic error.

RESULTS [Return to TOC](#)

The target of the treatment was achieved in all children, and all Class II division 1 malocclusions were converted to a Class I molar relationship. The mean treatment time was 1.6 ± 1.5 (0.3–3.1) years. Thirty-three children had good cooperation, and 7 had moderate cooperation. Phase 2 treatment was needed in 18 of 40 treated children, most often because of remaining overjet or overbite.

The effects of treatment on facial skeletal widths has been published previously.³ Numeric values of the measurements in the control group are presented in [Table 2](#), and the treatment results are presented in [Table 3](#). Adenoids were removed in 14 children prior to the headgear therapy. There were no significant differences in the results between the children with and without adenoidectomy except in the parameters ad1-PNS and ad2-PNS distances, both of which were longer in the children who had undergone adenoidectomy (*P* = .02). The SNA angle also decreased less in the children whose adenoids had been removed (*P* = .004).

Nasopharynx

The subjects in the treatment group had a similar or wider nasopharynx than the controls, and this was not affected by the treatment. The distance S-PNS was 2.0 ± 2.7 mm longer (*P* < .0001) pretreatment and 1.9 ± 3.0 mm longer (*P* = .0002) posttreatment ([Table 3](#); [Figure 2](#)). Also, ad2-PNS was longer than in the controls. However, this difference was observed only in those patients whose adenoids were removed. The ad1-PNS distance was similar to the controls both pretreatment and posttreatment.

Oro- and Hypopharynx

The children with Class II malocclusion had a narrower oro- and hypopharynx (AA-PNS ns; ve-pve 1.8 ± 2.2 mm, *P* < .0001; p-pp 1.8 ± 2.4 mm, *P* < .0001; pas 1.7 ± 3.2 mm, *P* = .0004; ph-pph 1.9 ± 2.8 mm, *P* = .0002; eb-peb 3.1 ± 2.7 mm, *P* < .0001) than the controls before the treatment ([Table 3](#); [Figure 2](#)). The retropalatal area was widened by the treatment, whereas the rest of the oropharynx and hypopharynx remained narrower than in the controls. In the retropalatal area, ve-pve was increased 0.6 ± 1.7 mm/y (*P* = .03) more, and p-pp was increased 0.6 ± 1.7 mm/y (*P* = .03) more than the observed annual change in the cross-sectional control population.

The length (PNS-p) and width (sp1-sp2) of the soft palate remained similar to the controls throughout the treatment period. The angle between the palatal plane and the tip of the soft palate (ANS-PNS-p) was decreased by the treatment (*P* < .0001) from 3.6° ± 5.9° wider (*P* = .0004) to 3.9° ± 5.8° narrower (*P* = .0002) than observed in the controls. However, the change in this angle did not correlate to the observed space gain in the retropalatal area (ve-pve, p-pp).

Maxilla, Mandible, Tongue, and Hyoid Bone Position

The SNA angle was 1.9° ± 2.9° wider in the treatment group than in the controls (*P* = .0003) before the treatment but was decreased 1.0° ± 0.7° per year by the treatment, whereas in the controls, the angle was widened 0.3° ± 0.4° per year (*P* < .0001). At the end of the treatment, the angles between the groups did not differ from each other (*P* = .21). The length of the hard palate (ANS-PNS) was increased 0.6 ± 1.0 mm per year more than the observed annual change in the control group (*P* = .001), and it became 1.7 ± 3.3 mm longer than in the controls at the end of the treatment (*P* = .002).

The SNB angle was similar to that of the controls throughout the treatment period and was unaffected by the treatment. The ANB angle was 1.1 ± 1.8 mm wider than in the controls at the beginning of the treatment (*P* = .0002) but was reduced 1.0° ± 0.8° per year more than the observed annual change in the control group (*P* < .0001), to become 0.9 ± 1.9 mm narrower than in the controls (*P* = .005) at the end of the treatment. The mandibular plane angle (NS-MP) lay 2.7° ± 5.2° more horizontal than in the controls (*P* = .002) at the beginning and 1.8° ± 5.4° at end of the treatment. The treatment did not significantly affect the mandibular plane angle. The length of the mandible (Co-Gn) was increased 1.9 ± 3.5 mm per year

more than the annual change in the control group ($P = .001$) to become 4.3 ± 7.1 mm longer ($P = .0004$) than in the controls pretreatment. The distance of the chin from the spine (sum of measures C3ai-HPT and HPT-Rgn) was 8.4 ± 12.9 mm shorter in the treatment group than in the controls pretreatment ($P < .0001$) and 5.3 ± 14.2 mm shorter posttreatment ($P = .03$). The C3ai-HPT-Rgn distance grew 1.4 ± 3.0 mm per year more than the annual change in the control group ($P = .03$).

The facial height (N-Me) and lower facial height (ANS-Me) were similar to the controls at the beginning of the study, but N-Me grew 1.5 ± 0.9 mm per year more than the annual change in the control group to become 3.9 ± 4.9 mm longer than in the controls ($P < .0001$). ANS-Me remained similar to that of the controls throughout the treatment period. The ratio ANS-Me : N-Me was decreased accordingly during the treatment period to become smaller than in the controls at the end of the treatment ($P < .0001$).

The length of the tongue (tt-eb) was similar to the controls and was unaffected by the treatment. Tongue height (th) was 1.8 ± 2.6 mm longer pretreatment and 3.1 ± 3.2 mm longer posttreatment in treated children compared to the controls ($P = .0001$), and the growth exceeded 0.7 ± 1.7 mm per year the annual increase observed in the control group ($P = .01$).

The distance between the hyoid bone and mandible (H-H') was 2.1 ± 4.5 mm shorter pretreatment ($P = .008$) and 4.1 ± 4.1 mm posttreatment ($P < .0001$) in the treated children than in the controls. The distance became 0.4 ± 2.2 mm per year shorter during the treatment, while in the control group, the distance increased 0.7 ± 0.9 mm per year ($P = .01$).

DISCUSSION [Return to TOC](#)

The important feature of the headgear used was a 10-mm expanded inner bow. With this treatment, all of the children were treated to a Class I first molar relationship. The children with Class II malocclusion had a wider or similar nasopharynx than the controls but narrower oro- and hypopharyngeal spaces. The retropalatal area was widened by the treatment, whereas the rest of the oropharynx and hypopharynx remained narrower than in the controls.


The effects of the headgear treatment on the upper airway space seem to be limited to the nose, nasopharynx, and retropalatal area. It has been previously shown in these same children with Class II malocclusion that the treatment increased their nasal width more than in the controls.³ This observed increase in the lateronasal width together with the observed increase in the retropalatal airway space should decrease nasal resistance and enhance nasal breathing,⁹⁻¹³ although the effect may not necessarily be clinically significant.¹⁴ Increased nasal breathing should have favorable effects on dentofacial development.¹⁵⁻¹⁷ The horizontal position of the mandible (NS-MP) and high position of the tongue support the idea that the treated children were nose breathers prior to the treatment.

Although the principal idea of headgear treatment is to restrict forward growth of the maxilla,¹⁸ the treatment did not restrict growth of the palatal plane (ANS-PNS). The palatal plane length grew even more than the observed annual change in the control group. We suggest that the restriction of the maxillary growth caused by the treatment is limited to the maxillary alveolar process. This growth discrepancy may influence the forward growth and appearance of the nose.

The angle between the palatal plane and the tip of the soft palate was decreased during treatment. However, this decrease did not correlate with the change in dimensions of the retropalatal airway space. We suggest that at least some of the decrease in this angle is due to the anterior downward rotation of the palatal plane² instead of a change in position of the uvula.

The hyoid bone was in a higher position in the children with Class II malocclusion than in the controls. This suggests that most of the studied subjects were habitual tongue thrusters.¹⁹ Seventeen of 40 children with Class II malocclusion were observed to thrust the tongue during swallowing at clinical controls.

Limitations of the Study

The control population consisted of a cross-sectional analysis of 538 school children studied in the late 1960s. Eighty controls with a Class I molar relationship were blindly selected from this normal population. To enable the direct comparison between the two studied groups and to minimize the effect of normal variability within the control group, the normal growth pattern of each parameter was estimated by fitting a fourth-order polynomial equation to the control group data (Figure 2 ). This calculated fitted mean was used to estimate the normal mean value for each particular age and used in comparisons with the study group. A more precise estimate of normal growth would have been valuable, but this would have required a substantially larger and newer control population or a longitudinally followed control group.

CONCLUSION [Return to TOC](#)

- A Class I molar relationship may be achieved by using only the cervical headgear in the treatment of Class II malocclusion.
- Class II malocclusion is related to a narrower oro- and hypopharyngeal space than in controls with a Class I first molar relationship.
- Cervical headgear treatment increases retropalatal airway space but does not significantly affect the rest of the oropharynx or hypopharynx in children with Class II malocclusion without retrognathia.

REFERENCES [Return to TOC](#)

1. Kirjavainen M, Kirjavainen T, Haavikko K. Changes in dental arch dimensions by use of an orthopedic cervical headgear in Class II correction. *Am J Orthod Dentofacial Orthop.* 1997; 111:59-66.
2. Kirjavainen M, Kirjavainen T, Hurmerinta K, Haavikko K. Orthopedic cervical headgear with an expanded inner bow in Class II correction. *Angle Orthod.* 2000; 70:317-325.
3. Kirjavainen M, Kirjavainen T. Maxillary expansion in Class II correction with orthopedic cervical headgear: a posteroanterior cephalometric study. *Angle Orthod.* 2003; 73:281-285.
4. Cistulli PA, Palmisano RG, Poole MD. Treatment of obstructive sleep apnea syndrome by rapid maxillary expansion. *Sleep.* 1998; 21:831-835.
5. Pirila-Parkkinen K, Pirtiniemi P, Nieminen P, Lopponen H, Tolonen U, Uotila R, Huggare J. Cervical headgear therapy as a factor in obstructive sleep apnea syndrome. *Pediatr Dent.* 1999; 21:39-45.
6. Haavikko K. The formation and the alveolar and clinical eruption of the permanent teeth: an orthopantomographic study. *Proc Finn Dent Soc.* 1970; 66(3):103-170.
7. Dahlberg G. *Statistical Methods for Medical and Biological Students.* New York, NY: Interscience; 1940.
8. Forsberg CM. *Growth Changes in the Adult Face: A Longitudinal Roentgen Cephalometric Investigation on Men and Women in Early Adulthood.* [PhD thesis]. Stockholm, Sweden: Karolinska Institutet; 1976.
9. Hershey HG, Stewart BL, Warren DW. Changes in nasal airway resistance associated with rapid maxillary expansion. *Am J Orthod.* 1976; 69:274-284.

10. Timms DJ. The effect of rapid maxillary expansion on nasal airway resistance. *Br J Orthod*. 1986; 13:221–228.
11. Hartgerink DV, Vig PS, Abbott DW. The effect of rapid maxillary expansion on nasal airway resistance. *Am J Orthod Dentofacial Orthop*. 1987; 92:381–389.
12. Timms DJ. Rapid maxillary expansion in the treatment of nasal obstruction and respiratory disease. *Ear Nose Throat J*. 1987; 66:242–247.
13. White BC, Woodside DG, Cole P. The effect of rapid maxillary expansion on nasal airway resistance. *J Otolaryngol*. 1989; 18:137–143.
14. Warren DW, Hershey HG, Turvey TA, Hinton VA, Hairfield WM. The nasal airway following maxillary expansion. *Am J Orthod Dentofacial Orthop*. 1987; 91:111–116.
15. Linder-Aronson S. Effects of adenoidectomy on dentition and nasopharynx. *Trans Eur Orthod Soc*. 1972:177–186.
16. Linder-Aronson S, Woodside DG, Lundstrom A. Mandibular growth direction following adenoidectomy. *Am J Orthod*. 1986; 89:273–284.
17. Woodside DG, Linder-Aronson S, Lundstrom A, McWilliam J. Mandibular and maxillary growth after changed mode of breathing. *Am J Orthod Dentofacial Orthop*. 1991; 100:1–18.
18. Bench RW, Gugino CF, Hilgers JJ. Bioprogressive therapy. Part 5. *J Clin Orthod*. 1978; 12:48–69.
19. Ricketts RM. *Provocations and Perceptions in Cranio-facial Orthopedics: Dental Science and Facial Art*. San Diego, CA: Rocky Mountain Orthodontics; 1989:603–606.

TABLES [Return to TOC](#)

Table 1. Cephalometric Landmarks, Angles, and Reference Planes

Measure	Definition
Nasopharynx	
S-PNS	The distance of sella (S) to posterior nasal spine (PNS)
ad1-PNS	The distance of ad1 to posterior nasal spine (PNS). Ad1 is the intersection point of posterior pharyngeal wall and the line from posterior nasal spine (PNS) to basion (Ba)
ad2-PNS	The distance of ad2 to posterior nasal spine (PNS). Ad2 is the intersection point of posterior pharyngeal wall and the line from the midpoint of the line from sella (S) to basion (Ba) to posterior nasal spine (PNS)
Oropharynx	
AA-PNS	The distance of the most anterior point of atlas vertebra (AA) to posterior nasal spine (PNS)
ve-pve	The distance of the closest point of soft palate to the posterior pharyngeal wall (velum palatinum, ve) to the horizontal counterpoint on the posterior pharyngeal wall (pve)
p-pp	The distance of the tip of soft palate (p) to horizontal counterpoint on posterior pharyngeal wall (pp)
Pas	The distance of the intersection points on anterior and posterior pharyngeal wall of the line from supramentale (B) to gonion (Go)
ph-pph	The distance of horizontal counterpoints on anterior and posterior pharyngeal wall in oropharynx at its narrowest area
Soft palate	
ANS-PNS-p	The angle anterior nasal spine (ANS) to posterior nasal spine (PNS) to palate point (p)
PNS-p	The distance of posterior nasal spine (PNS) to tip of soft palate (p)
sp1-sp2	The thickest cross section of the soft palate
Hypopharynx	
eb-peb	The distance from vallecula of epiglottis (eb) to horizontal counterpoint on the posterior pharyngeal wall (peb)
Maxilla	
SNA	The angle sella (S) to nasion (N) to subspinale (A)
ANS-PNS	The length of the palatal plane from anterior nasal spine (ANS) to posterior nasal spine (PNS)
Mandible	
SNB	The angle sella (S) to nasion (N) to supramentale (B)
ANB	The angle subspinale (A) to nasion (N) to supramentale (B)
NS-MP	The angle nasion (N) to sella (S) to mandibular plane (MP). Mandibular plane is the line from mandibular base point (MBP) to menton (Me)
Co-Gn	Mandibular length. The length from the most posterior and superior point on the condylar head (Co) to the most anterior and inferior point on the mandibular symphysis (Gn)
C3ai-HPT-Rgn	Sum of two distances: (1) the perpendicular distance between the most anterior and inferior point on the corpus of the third cervical vertebra (C3ai) and HPT. HPT is the vertical line from the most anterior and superior point of hyoid bone perpendicular to nasion (N) to sella (S) line with 7° upward correction. (2) The distance from most dorsal point of mandibular symphysis (retrognation, Rgn) perpendicular to HPT
Facial heights	
N-Me	The distance from nasion (N) to menton (Me)
ANS-Me	The distance from anterior nasal spine (ANS) to menton (Me)
Tongue	

Length (tt-eb)	Tongue length. The distance from anterior point of tip of tongue (tt) to the base of epiglottis (eb)
Height (th)	Tongue height. The perpendicular distance of superior point of tongue (th) below posterior nasal spine (PNS) to line from the tongue tip (tt) to the intersection point of tongue and mandibular border (tg)
Hyoid bone	
H-H'	The distance from the most anterior and superior point of hyoid bone (H) perpendicular to mandibular plane (MP)
H-C3ai	Hyoidale (H). The perpendicular distance from the most anterior and superior point of hyoid bone to perpendicular line from C3ai to HPT

Table 2. Measurements of the 80 Control Children^a

	Age, y															
	6–7		7–8		8–9		9–10		10–11		11–12		12–13		13–14	
	\bar{x}	SD	\bar{x}	SD	\bar{x}	SD	\bar{x}	SD	\bar{x}	SD	\bar{x}	SD	\bar{x}	SD	\bar{x}	SD
Nasopharynx																
S-PNS, mm	38.4	2.6	39.8	2.6	40.3	3.0	41.3	1.8	42.0	2.5	43.0	1.8	43.0	1.9	44.1	2.3
ad1-PNS, mm	18.9	5.2	21.3	1.9	20.1	3.7	19.0	5.5	21.1	5.6	19.5	4.3	20.7	5.0	23.2	5.1
ad2-PNS, mm	13.5	3.1	14.2	2.1	14.8	1.2	14.7	3.7	14.8	3.0	15.3	3.4	15.0	3.0	16.9	2.7
Oropharynx																
AA-PNS, mm	30.6	2.5	33.5	3.5	32.3	4.7	31.7	2.7	32.0	2.7	31.9	4.1	31.0	3.1	33.9	3.7
ve-pve, mm	9.2	2.2	10.6	2.9	9.4	2.4	9.8	1.7	9.4	2.6	10.6	4.4	9.1	2.2	11.0	1.9
p-pp, mm	11.9	2.0	13.0	3.2	11.5	3.1	11.1	1.6	10.9	2.8	12.1	4.4	10.9	2.3	13.0	1.7
pas, mm	12.0	3.2	13.5	4.7	12.8	3.5	13.0	2.3	12.3	2.6	13.3	4.9	13.1	3.3	12.9	3.1
ph-pph, mm	10.3	3.0	13.1	5.0	11.3	4.4	10.2	3.0	9.7	2.8	10.7	5.0	10.1	3.2	12.0	3.9
Soft palate																
ANS-PNS-p, °	134.1	8.5	136.6	4.6	133.9	7.4	135.7	4.7	136.4	5.1	137.1	5.0	132.9	7.7	134.1	7.8
PNS-p, mm	25.9	2.4	26.8	2.3	27.9	1.8	28.2	3.0	28.5	1.2	28.3	2.8	28.7	1.6	30.9	3.4
sp1-sp2, mm	7.2	0.7	8.0	0.6	7.3	1.5	7.2	1.0	7.6	1.2	7.7	0.8	8.2	1.1	8.3	0.9
Hypopharynx																
eb-peb, mm	13.5	1.6	16.6	4.0	14.8	2.7	15.4	2.7	14.2	2.5	17.7	6.7	14.8	3.8	19.0	5.1
Maxilla																
SNA, °	81.4	1.7	82.1	3.0	79.2	3.9	80.6	2.0	81.6	3.4	81.3	3.0	81.7	3.3	80.5	3.6
ANS-PNS, mm	44.8	2.0	46.0	2.1	47.6	2.8	45.9	2.3	46.2	2.8	46.6	3.2	47.3	2.3	50.7	3.2
Mandible																
SNB, °	76.4	1.4	77.8	3.3	76.6	4.3	77.7	2.6	77.8	2.9	78.7	2.7	79.9	2.9	78.1	4.8
ANB, °	5.0	1.5	4.3	1.4	2.9	2.2	2.9	1.7	3.8	2.2	2.8	2.0	2.0	1.8	2.5	2.1
NS-MP, °	36.4	2.5	32.9	4.7	35.9	4.9	34.9	5.1	35.6	4.9	34.8	3.9	30.6	4.5	31.0	5.8
Co-Gn	90.0	3.3	95.2	2.9	97.6	6.6	99.3	4.7	100.1	3.6	101.3	4.3	103.4	3.1	108.3	5.7
C3ai-HPT-Rgn, mm	57.2	5.8	65.4	8.5	65.0	6.8	64.1	8.1	62.5	4.2	67.5	6.5	66.2	8.5	72.8	11.0
Facial heights																
N-Me, mm	93.9	3.6	95.4	2.6	100.5	4.3	99.8	4.8	102.3	4.3	103.4	5.3	101.8	5.1	108.5	4.3
ANS-Me, mm	54.4	2.2	55.0	2.1	57.8	2.8	57.5	3.7	59.1	3.4	58.7	3.2	57.1	3.7	62.2	3.0
Tongue																
Length (tt-eb), mm	58.4	4.7	62.4	5.7	64.9	4.4	65.9	5.6	65.5	4.2	67.3	2.5	70.3	3.8	71.8	5.8
Height (th), mm	17.4	1.5	17.5	2.3	18.9	3.1	18.0	2.7	19.5	3.0	19.1	3.3	18.3	3.7	21.6	4.0
Hyoid bone																
H-H', mm	9.2	2.5	8.7	2.6	11.3	4.5	14.3	2.7	13.5	6.2	14.0	4.2	13.3	4.8	12.8	3.7
H-C3ai vertical line, mm	-1.9	3.2	-4.3	2.9	-2.7	3.4	0.8	2.9	0.4	4.8	-0.1	3.5	2.1	4.6	-1.4	3.6

^a Each age group includes data from five girls and five boys.

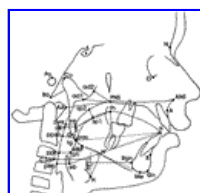Table 3. Pretreatment and Posttreatment Values and Changes and Method Errors^a

	Pretreatment		Posttreatment		Change/y	SD	ME
	\bar{x}	SD	\bar{x}	SD			
Nasopharynx							
S-PNS, mm	43.0 ^{θ****}	2.9	44.4 ^{θ****}	3.2	0.6	0.4	0.3
ad1-PNS, mm	21.1	4.3	21.1	4.3	0.0	2.0	0.5
ad2-PNS, mm	16.2 ^{θ*}	3.5	17.3 ^{θ**}	4.4	0.6 ^{θ*}	1.5	0.7
Oropharynx							
AA-PNS, mm	32.2	3.5	31.0 ^{↓*}	2.6	-0.6	1.4	0.6
ve-pve, mm	8.1 ^{↓****}	2.2	9.1	2.4	0.4 ^{θ*}	1.3	0.5
p-pp, mm	10.1 ^{↓****}	2.4	10.6	2.6	0.2 ^{θ*}	1.6	0.3
pas, mm	11.0 ^{↓****}	3.1	11.1 ^{↓**}	3.2	0.0	1.8	0.5
ph-pph, mm	9.7 ^{↓****}	2.6	9.9	3.7	0.1	2.1	0.3
Soft palate							
ANS-PNS-p, °	139.3 ^{θ****}	5.9	131.6 ^{↓****}	5.9	-3.6 ^{↓****}	2.5	2.4
PNS-p, mm	28.1	3.0	28.4	2.6	0.1	1.3	0.8
sp1-sp2, mm	7.7	1.1	7.7	1.1	0.0	0.8	0.4
Hypopharynx							
eb-peb, mm	12.3 ^{↓****}	2.7	13.1 ^{↓****}	3.2	0.2	2.0	0.4
Maxilla							
SNA, °	82.7 ^{θ****}	3.0	80.8	3.4	-1.0 ^{↓****}	0.7	0.3
ANS-PNS, mm	47.2	2.8	48.5 ^{θ**}	3.5	0.6 ^{θ**}	1.0	0.6
Mandible							
SNB, °	78.1	2.9	78.8	3.2	0.3	0.8	0.3
ANB, °	4.6 ^{θ****}	1.8	2.0 ^{↓**}	1.8	-1.3 ^{↓****}	0.8	0.2
NS-MP, °	31.7 ^{↓**}	5.2	31.3 ^{↓*}	5.5	-0.2	0.9	0.5
Co-Gn	99.3	5.3	105.7 ^{θ****}	6.2	2.9 ^{θ****}	1.4	0.3
C3ai-HPT-Rgn, mm	59.3 ^{↓****}	5.5	62.2 ^{↓*}	6.6	1.4 ^{θ*}	3.2	0.2
Facial heights							
N-Me, mm	99.8	4.8	105.4 ^{θ****}	5.1	2.5 ^{θ****}	0.5	0.4
ANS-Me, mm	57.7	3.7	59.0	4.2	0.6	0.7	0.3
Tongue							
Length (tt-eb), mm	64.6	5.2	67.0	4.2	0.9	1.9	0.4
Height (th), mm	20.1 ^{θ****}	2.7	22.2 ^{θ****}	3.3	1.0 ^{θ*}	1.7	1.2
Hyoid bone							
H-H', mm	10.3 ^{↓**}	3.9	9.9 ^{↓****}	3.9	-0.4 ^{↓*}	2.2	0.3
H-C3ai vertical line, mm	-0.4	5.3	-1.0	6.4	-0.6 ^{↓*}	2.6	0.2

^θ Superscript at the end of a number indicates if the value is longer (θ) or shorter (↓) than in the controls and whether it differs from the controls. ME indicates method error.


* $P < .05$; ** $P < .01$; *** $P < .001$; **** $P < .0001$.

FIGURES [Return to TOC](#)



Click on thumbnail for full-sized image.

Figure 1. Landmarks used. For definitions, see [Table 1](#)



[Click on thumbnail for full-sized image.](#)

Figure 2. Pretreatment (solid) and posttreatment (open) upper airway widths plotted against normal mean with 95% prediction interval

^a Practitioner, Department of Pedodontics and Orthodontics, University of Helsinki, Helsinki, Finland

^b Practitioner, Department of Pediatrics, Hospital for Children and Adolescents, Helsinki, Finland

Corresponding author: Dr Mirja Kirjavainen, Venhontie 7, Tammela 31300, Finland (E-mail: mirja.kirjavainen@fimnet.fi)