

[\[Print Version\]](#)
[\[PubMed Citation\]](#) [\[Related Articles in PubMed\]](#)

TABLE OF CONTENTS

[\[INTRODUCTION\]](#) [\[MATERIALS AND...\]](#) [\[RESULTS\]](#) [\[DISCUSSION\]](#) [\[CONCLUSION\]](#) [\[REFERENCES\]](#) [\[TABLES\]](#) [\[FIGURES\]](#)

doi: 10.2319/052106-207
The Angle Orthodontist: Vol. 77, No. 6, pp. 1062-1066.

Malposition of Unerupted Mandibular Second Premolar in Children with Cleft Lip and Palate

Miri Shalish;^a Leslie A. Will;^b Stephen Shustermann^c

ABSTRACT

Objective: To determine whether distoangular malposition of the unerupted mandibular second premolar (MnP2) is more frequent in children with unilateral clefts of the lip and palate.

Materials and Methods: This retrospective study examined panoramic radiographs from 45 patients with unilateral clefts of the lip and/or palate who had no previous orthodontics. A control sample consisted of age- and sex-matched patients. The distal angle formed between the long axis of MnP2 and the tangent to the inferior border was measured. The mean, standard deviation, and range were calculated for the angles measured in the cleft and the control groups. The significance of the differences between the means was evaluated by the paired *t*-test. The angles of the cleft and noncleft sides were also measured and compared.

Results: The mean inclination of the MnP2 on the cleft side was 73.6°, compared with 84.6° in the control group. This difference was highly significant statistically (*P* < .0001). The difference in angles from the cleft and noncleft sides was 0.7°, not statistically significant. A significant association was found between clefting and distoangular malposition of the developing MnP2, suggesting a shared genetic etiology. This association is independent of the clefting side, ruling out possible local mechanical effects.


Conclusion: Clinicians should be aware of the potential for anomalous development of MnP2 in children with clefts.

KEY WORDS: Malposition, Dental anomalies, Cleft, Mandibular second premolar, *MSX1*, Genetic etiology.

Accepted: August 2006. Submitted: May 2006

INTRODUCTION [Return to TOC](#)

Exaggerated distoangular malposition of the unerupted mandibular second premolar (MnP2) has been found to be associated with agenesis of its antimere.¹ This finding relates the MnP2 malposition to a group of tooth developmental abnormalities of possible common genetic origin, including agenesis (hypodontia), peg-shaped maxillary lateral incisors, palatally displaced canines, and transpositions of various teeth.²⁻¹⁰

Accumulated evidence on associations among this group go well beyond coincidence, suggesting them as part of a broader genetically related pattern of dental anomalies. Several of these anomalies have been found more frequently in patients with clefting.¹¹⁻¹³ Recent studies have linked both familial posterior tooth agenesis and orofacial clefting to mutations of the homeobox gene, *MSX1*.^{14,15} If both the MnP2 anomaly and clefting are indeed related to tooth agenesis, as part of a broader biological relation, they should also exhibit a direct association. [Figure 1](#)  places this hypothesis in a diagram among previously established associations.

Although a genetic basis of clefting is considered likely in many cases,¹⁶ it may also constitute a mechanical growth disturbance. For example, the lateral incisor in the region of the alveolar cleft is known to be sensitive to developmental disorders.¹⁷ However, when the clefting is unilateral the range of its mechanical effect is usually limited to that side. Nonetheless, teeth outside the cleft area are known to be affected as well with dental growth anomalies. For example, Shapira et al¹² observed high prevalence (18%) of missing premolars in cleft lip and cleft palate children.

This study was undertaken to test the hypothesis that MnP2 would show a significantly greater distal angulation in cleft lip and palate children than those in an age- and sex-matched control sample.

MATERIALS AND METHODS [Return to TOC](#)

Two samples, a cleft group and a noncleft control group, were selected retrospectively from pretreatment records of patients in Children's Hospital, Boston, Mass. The cleft sample consisted of 45 patients (21 girls and 24 boys). The criteria for inclusion in this sample were (1) unilateral cleft lip and/or palate; (2) no previous orthodontic treatment; and (3) development of MnP2 tooth bud in stages D to G of tooth formation, according to the classification of Koch et al.¹⁸ Unerupted stage D is defined as crown formation completed down to the cemento-enamel junction, unerupted stage E is with root length smaller than crown length, unerupted stage F is with root length equal to or larger than crown length, and unerupted stage G is with the walls of the root canal parallel and the root apex still partially open.

The mandibular deciduous second molars were present for all participants. Among the 21 girls, 14 showed left-side clefting and all showed clefting of both lip and palate; among the

24 boys, 18 showed left-side clefting, 22 had clefting of both lip and palate, and two had clefting of lip only. A control sample was provided consisting of age- (rounded to a half year) and sex-matched patients from the same orthodontic patient pool.

In both samples, panoramic radiographs were used to trace each MnP2 along with the neighboring mandibular first molar, the deciduous first molar, and a tangent to the inferior border of the mandibular body on the side of the second premolar. The long axis of the MnP2 was determined as the line connecting the uppermost point of the pulp with the point bisecting the distance between the mesial and the distal points of the apex. A protractor was then used to measure the distal angle formed between the long axis of the MnP2 and the line drawn tangent to the inferior border of the mandible. [Figure 2](#) shows a typical drawing with the assigned lines and the resulting angle. All tracings were made independently by one examiner with 0.003-inch frosted-acetate paper and a 0.5-mm pencil.

Descriptive statistics including the mean, standard deviation, and range were calculated for the unerupted MnP2 angles measured in the cleft and the noncleft groups. The significance of the differences between the compared means was evaluated by the Student's *t*-test for paired samples. The significance level was set at $P < .05$. Inpatient correlation was evaluated by the Pearson correlation test.

To quantify the error of the method, a second set of data was traced and measured 1 month later by the same examiner. Standard deviations calculated for two repeated measurements of two tracings of six different panoramic roentgenograms were used as intraexaminer error. This procedural error was found to be 1.0° , which is within reasonable limits in the context of this study.

RESULTS [Return to TOC](#)

[Table 1](#) shows the descriptive statistics of cleft-side MnP2 in the cleft group and the same side in the age- and sex-matched paired noncleft control group. The mean distal inclination of the MnP2 in the cleft side of the cleft sample was 73.6° , compared with a mean 84.6° obtained for the matched control group. The mean increase of 11.0° in the distoangular malposition of the developing MnP2 in cleft patients was highly significant statistically ($P < .0001$). Thus, our null hypothesis that the distal angulation of a developing MnP2 does not change significantly relative to the presence or absence of clefting lip and palate at the same side can be rejected.

To examine a local influence of the clefting on the distal inclination of the MnP2, we compared the cleft-side MnP2 in each patient of the cleft group with its antimere, that is, the MnP2 in the noncleft side. [Table 2](#) shows the descriptive statistics of the two sides of the same patient in the cleft group. The mean distal inclination of the MnP2 in the cleft side of the cleft sample was 73.6° , compared with a mean 74.3° obtained for the noncleft side. The difference, 0.7° , is small and insignificant statistically ($P = .72$). Moreover, the Pearson correlation test yielded a correlation coefficient of 0.303, which was found statistically significant ($P = .043$). This result clearly supports a nonlocal mechanism for MnP2 angulation in cleft patients. In other words, the distal angulation of a developing MnP2 in the noncleft side is not significantly different relative to the cleft side of the clefting lip and palate.

DISCUSSION [Return to TOC](#)

This study was designed to test a hypothesis that angular malposition of a developing MnP2 would be directly associated with clefting. The data suggest a significant connection between these two conditions. Moreover, this association is found independent of the clefting side, thereby ruling out possible local mechanical effects.

Clefting affects the maxilla. Hence, a direct mechanical effect in the mandible is unlikely and even less likely in the nonclefting side of the mandible. Furthermore, the local surroundings of the unerupted MnP2 seemed normal for all the teeth studied. The absence of a local mechanical disturbance suggests association through a common genetic disorder. Van den Boogaard et al¹⁵ have already associated clefting and agenesis through mutations of the homeobox gene, *MSX1*. The results of this work along with the results of Shalish et al¹ associate the MnP2 angulation anomaly with both clefting and agenesis, suggesting the MnP2 anomaly as a variable in a genetically related group of dental anomalies likely to be associated with *MSX1* mutations. It is likely for the MnP2 anomaly to appear in combination with any other of these interassociated anomalies, such as infraocclusion, mesially ectopic maxillary first molar, palatally displaced canine, tooth transposition, tooth rotation, tooth-size reduction, and peg-shaped maxillary lateral incisor.^{2-10,19-23}

An interesting side observation made in this study is the actual correlation of MnP2 angulation observed between the two sides in the cleft sample. It therefore suggests that in clefting patients, anomalous MnP2 angulation often affects both sides rather than just the clefting side, in further support of a systemic, nonlocal mechanism, such as genetics. This observation adds to the accumulated evidence showing that various dental developmental anomalies associated with clefting are not restricted to the clefting side.¹²

Although the statistical associations of MnP2 angulation anomaly with both agenesis of its antimere and with clefting are clearly significant, the mechanism by which a possible common genetic disturbance could cause both anomalies at the same time is not evident. However, several studies have shown that clefting is often accompanied with a delay in tooth formation not specific to the clefting side or the maxilla.²⁴⁻²⁶

Ranta²⁷ has clearly shown that a delay in tooth formation is associated with agenesis of second premolars in children with cleft palate. Independently, Wasserstein et al²⁸ have recently shown in a longitudinal study that the MnP2 angulation anomaly is associated with a delay in the MnP2 dental age. Hence, both agenesis and the angulation anomaly of MnP2 seem to be associated with a delay in tooth formation, a condition often observed in association with clefting. Therefore, it seems possible that the common mechanism is a delay in tooth formation.

Knowledge of the timing of tooth formation and the dental age are essential parameters in any orthodontic treatment plan involving the mixed dentition. A delay in the dental age, whether or not combined with other significant tooth developmental disturbance, should alert the clinician for the likelihood of anomalous development of the MnP2.

CONCLUSION [Return to TOC](#)

- Clinicians should be aware of the potential for anomalous development of MnP2 in children with clefts.

REFERENCES [Return to TOC](#)

1. Shalish M, Peck S, Wasserstein A, Peck L. Malposition of unerupted mandibular second premolar associated with agenesis of its antimere. *Am J Orthod Dentofacial Orthop.* 2001; 121:53-55.
2. Alvesalo L, Portin P. The inheritance pattern of missing, peg-shaped and strongly mesio-distally reduced upper lateral incisors. *Acta Odontol Scand.* 1969; 27:563-573.
3. Garn SM, Lewis AB. The gradient and the pattern of crown-size reduction in simple hypodontia. *Angle Orthod.* 1970; 40:51-58.
4. Peck S, Peck L, Kataja M. The palatally displaced canine as a dental anomaly of genetic origin. *Angle Orthod.* 1994; 64:249-256.
5. Peck S, Peck L, Kataja M. Prevalence of tooth agenesis and peg-shaped maxillary lateral incisor associated with palatally displaced canine (PDC) anomaly. *Am J Orthod Dentofacial Orthop.* 1996; 110:441-443.
6. Peck L, Peck S, Attia Y. Maxillary canine-first premolar transposition, associated dental anomalies and genetic basis. *Angle Orthod.* 1993; 63:99-109.

7. Peck S, Peck L, Kataja M. Mandibular lateral incisor-canine transposition, concomitant dental anomalies and genetic control. *Angle Orthod.* 1998; 68:455–466.
8. Symons AL, Stritzel F, Stamation J. Anomalies associated with hypodontia of the permanent lateral incisor and second premolar. *J Clin Pediatr Dent.* 1993; 17:109–111.
9. Zilberman Y, Cohen B, Becker A. Familial trends in palatal canines, anomalous lateral incisors, and related phenomena. *Eur J Orthod.* 1990; 12:135–139.
10. Pirinen S, Arte S, Apajalahti S. Palatal displacement of canine is genetic and related to congenital absence of teeth. *J Dent Res.* 1996; 75:1742–1746.
11. Pirinen S. Genetic craniofacial aberrations. *Acta Odontol Scand.* 1998; 56:356–359.
12. Shapira Y, Lubit E, Kufninec MM. Congenitally missing second premolars in cleft lip and cleft palate children. *Am J Orthod Dentofacial Orthop.* 1999; 115:396–400.
13. Slayton RL, Williams L, Murray JC, Wheeler JJ, Lidral AC, Nishimura CJ. Genetic association studies of cleft lip and/ or palate with hypodontia outside the cleft region. *Cleft Palate Craniofac J.* 2003; 40:274–279.
14. Vastardis H, Karimbux N, Guthua SW, Seidman JG, Seidman CE. A human MSX1 homeodomain missense mutation causes selective tooth agenesis. *Nat Genet.* 1996; 13:417–421.
15. Van den Boogaard MJ, Dorland M, Beemer FA, van Amstel HK. MSX1 mutation is associated with orofacial clefting and tooth agenesis in humans. *Nat Genet.* 2000; 24:342–343.
16. Cobourne MT. The complex genetics of cleft lip and plate. *Eur J Orthod.* 2004; 26:7–16.
17. Ribeiro LL, Das Neves TL, Costa B, Gomide RM. Dental anomalies of the permanent lateral incisors and prevalence of hypodontia outside the cleft area in complete unilateral cleft lip and palate. *Cleft Palate Craniofac J.* 2003; 40:172–175.
18. Koch G, Modeer T, Poulsen S, Rasmussen P. *Pedodontics: A Clinical Approach.* Copenhagen, Denmark: Munksgaard; 1991:60.
19. Bjerklin K, Kuroi J, Valentin J. Ectopic eruption of maxillary first permanent molars and association with other tooth and developmental disturbances. *Eur J Orthod.* 1992; 14:369–375.
20. Kuroi J. Infraocclusion of primary molars: an epidemiological and familial study. *Community Dent Oral Epidemiol.* 1982; 9:94–102.
21. Hu JR, Nakasima A, Takahama Y. Familial similarity in dental arch form and tooth position. *J Craniofac Genet Dev Biol.* 1992; 12:33–40.
22. Baccetti T. A controlled study of associated dental anomalies. *Angle Orthod.* 1998; 68:267–274.
23. Baccetti T. Tooth rotation associated with aplasia of nonadjacent teeth. *Angle Orthod.* 1998; 68:471–474.
24. Ranta R. A review of tooth formation in children with cleft lip/palate. *Am J Orthod Dentofacial Orthop.* 1986; 90:11–18.
25. Harris EF, Hullings JG. Delayed dental development in children with isolated cleft lip and palate. *Arch Oral Biol.* 1990; 35:469–473.
26. Mitsea AG, Spyropoulos MN. Premolar development in Greek children with cleft lip and palate. *Quintessence Int.* 2001; 32:639–646.
27. Ranta R. Hypodontia and delayed development of the second premolars in cleft palate children. *Eur J Orthod.* 1983; 5:145–148.
28. Wasserstein A, Brezniak N, Shalish M, Heller M, Rakocz M. Angular changes and their rates in concurrence to developmental stages of the mandibular second premolar. *Angle Orthod.* 2004; 74:332–336.

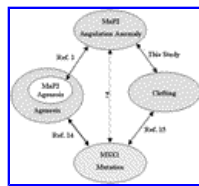
TABLES [Return to TOC](#)

Table 1. Descriptive Statistics of Cleft Sample vs. Noncleft Control Sample—Comparison of Distoangular Malposition of the Unerupted Mandibular Second Premolar Between the Cleft Side in the Cleft and Noncleft Samples

Group	n	Range, °	Mean, °	Standard Deviation, °	t-test Value	P Value
Cleft sample						
Cleft side	45	46.0–90.0	73.6	11.1	–5.81	<.0001
Noncleft control sample						
Same side	45	63.0–98.0	84.6	6.6		

Table 2. Descriptive Statistics of Two Sides within the Cleft Sample—Comparison of Distoangular Malposition of the Unerupted Mandibular Second Premolar Between the Cleft Side and the Noncleft Side

Group	n	Range, °	Mean, °	Standard Deviation, °	t-test Value	Correlation
Cleft side	45	46.0–90.0	73.6	11.1	–0.356	0.303
Noncleft side	45	53.0–95.0	74.3	10.1		
P value					.72	.043



[Click on thumbnail for full-sized image.](#)

Figure 1. Diagrammatic representation of syllogistic relations between the hypothesis of this study and published biological associations



[Click on thumbnail for full-sized image.](#)

Figure 2. The distal angle (θ) between the long axis of the mandibular second premolar and the tangent to the lower border of the mandible defined on a typical drawing of the relevant part of an orthopantomogram

^aAssistant Professor, Harvard School of Dental Medicine, Developmental Biology (Orthodontics), Boston, Mass

^bAssociate Professor, Harvard School of Dental Medicine, Developmental Biology (Orthodontics), Boston, Mass

^cAssociate Professor, Harvard School of Dental Medicine, Developmental Biology (Pediatric Dentistry), Boston, Mass

Corresponding author: Dr Miri Shalish, Harvard School of Dental Medicine, Developmental Biology (Orthodontics), 188 Longwood Avenue, Boston, MA 02115 (E-mail: mshalish@hsdm.harvard.edu)