

[\[Print Version\]](#)

[\[PubMed Citation\]](#) [\[Related Articles in PubMed\]](#)

TABLE OF CONTENTS

[\[INTRODUCTION\]](#) [\[CASE REPORT\]](#) [\[DISCUSSION\]](#) [\[CONCLUSIONS\]](#) [\[REFERENCES\]](#) [\[TABLES\]](#) [\[FIGURES\]](#)

doi: 10.2319/112106-476.1

The Angle Orthodontist: Vol. 77, No. 6, pp. 1109–1118.

Treatment of Class II Protrusion with Severe Crowding Using Indirect Miniscrew Anchorage

Nak-Chun Choi;^a Young-Chel Park;^b Han-Ah Lee;^a Kee-Joon Lee^c

ABSTRACT

This report describes the nonsurgical treatment of a patient with skeletal Class II protrusion and severe crowding. A 20-year-old woman presented with the chief complaint of lip protrusion and crowding. To correct the Class II relationship, severe crowding, and lip protrusion, distal movement of the maxillary first molars using indirect miniscrew anchorage and nickel-titanium coil springs, along with extraction of the first premolars and maxillary second molars, was planned. After the distal molar movement phase was complete, the maxillary first molars had moved 8.0 mm to the distal, and the first premolars, which were splinted to the miniscrews, had moved 0.5 mm to the mesial. The results show that the distal molar movement mechanics were efficient and stable. After treatment, all of the patient's chief complaints were relieved and an esthetic facial profile was obtained.

KEY WORDS: Distal molar movement, Anchorage, Miniscrew, Class II correction, Noncompliance treatment.

Accepted: December 2006. Submitted: November 2006

INTRODUCTION [Return to TOC](#)

Treatment of skeletal Class II in nongrowing individuals involves either surgical correction of the jaw abnormality or orthodontic camouflage, which usually requires extraction of the premolars or distal movement of the maxillary molars. Despite the good treatment results that are possible via orthognathic surgery, this option is generally declined because of its associated risks and costs.^{1,2}



A variety of treatment modalities have been suggested for the distal movement of maxillary molars. Extraoral appliances such as a headgear have been used successfully. However, such modalities are heavily dependent on patient compliance, and some patients are averse to wearing a headgear for social and esthetic reasons.^{3,4} To avoid the need for patient compliance, several intraoral distal molar movement devices, such as the pendulum,^{5,6} distal jet,^{7,8} Jones jig,^{9,10} repelling magnets,^{11,12} and nickel-titanium (NiTi) coil springs,^{12,13} have been proposed. Conventional intraoral distal molar movement has relied mainly on a Nance button and the use of anterior teeth to reinforce anchorage. Although these methods often achieve acceptable results, anchorage loss is unavoidable and the mechanics are often difficult to control precisely. These problems can be overcome using temporary anchorage devices such as endosseous implants, miniplates, onplants, or miniscrews. With the help of these absolute anchorage systems, various successful methods of distal molar movement have been reported.^{14–20} However, most of them have limitations, such as complicated surgical implantation, the need for



additional laboratory procedures, difficult manipulation, and/or patient discomfort.

Of the various temporary anchorage devices, miniscrews have several advantages. They are relatively easy to place, inflict less trauma on the oral tissues, are stable under the optimal force exerted, and can bear force immediately after placement. Moreover, miniscrews are relatively inexpensive and have few limitations regarding implantation sites. This case report describes the treatment of a skeletal Class II adult with severe crowding using indirect miniscrew anchorage and NiTi coil springs.

CASE REPORT [Return to TOC](#)

Diagnosis


A 20-year-old woman presented with the chief complaints of lip protrusion and crowding. Her prior medical and dental history revealed no significant systemic problems, with no significant temporomandibular joint disorders. The initial clinical findings showed a convex facial profile associated with a retrognathic mandible, protrusive lips, and mentalis muscle strain ([Figure 1](#) ). The patient had a large overjet (6.0 mm) and a significant amount of crowding in both arches (maxilla 20.0 mm; mandible 11.0 mm). From the lateral view, a bilateral full-cusp Class II molar and canine relationship was apparent. Her maxillary dental midline deviated 1.0 mm to the right, and the mandibular dental midline deviated 2.0 mm to the right relative to the facial midline ([Figure 2](#) .


Cephalometric analysis indicated a skeletal Class II (ANB angle 9.1, Wits appraisal 1.5), a hyperdivergent profile with a steep mandibular plane angle (57.0), large Björk sum angle (417.0), and uprighted maxillary and mandibular incisors (U1 to SN 93.3, IMPA 87.3) ([Figure 3](#) , [Table 1](#) ). Based on this information, the patient was diagnosed with skeletal Class II protrusion with severe crowding.

Treatment Alternatives

Orthognathic surgery was suggested as the preferred treatment option. With this treatment option, premolar extractions are first performed to relieve the severe crowding. Two-jaw surgery with impaction of the maxilla and advancement of the mandible would be needed to address the Class II relationship, the hyperdivergent profile, the large overjet, and the lip protrusion. However, the surgical option was declined by the patient because of the surgical risks and high cost.


In terms of the orthodontic camouflage treatment alternative, the extraction of maxillary and mandibular first molars was considered as a second option, since the mandibular first molars had been treated endodontically. However, extraction of only the maxillary first molars would provide insufficient space to relieve the severe crowding and the large overjet in the maxillary arch, even with maximum miniscrew anchorage. In the mandible, the crowding could be relieved with extraction of the first molars, but eruption of the third molars would be unpredictable because of the limited posterior space, even if the second molars had moved mesially. For these reasons and in terms of overall benefit, extraction of all first molars was rejected as a treatment possibility.

The third option was distal maxillary molar movement using miniscrews. Both distal movement of the maxillary molars and extraction of premolars would be necessary, because all of the problems could not be solved by premolar extractions alone. Prior to distal molar movement, the space available was inspected by clinical and radiographic examination ([Figure 3](#) ). Because of the lack of posterior space for distal molar movement and because both the size and shape of the maxillary third molars appeared to be acceptable, extraction of the maxillary second molars was recommended for sufficient distal molar movement.


An occlusogram was drawn to ensure precise treatment planning. In the maxilla, 8.0 mm of distal molar movement on both sides was planned to achieve a Class I molar relationship. An additional 8.0 mm of space would be gained by extraction of the first premolars. As a result, the anterior retraction of 5.5 mm and the maxillary midline correction of 1.0 mm to the left side could be accomplished using these spaces. In the mandible, 2.5 mm of space in the right quadrant and 4.5 mm in the left quadrant would remain after extraction of the first premolars and relief of crowding. Therefore, anterior retraction of 2.5 mm and a mandibular midline correction of 2.0 mm to the left side were planned ([Figure 4](#) .




Treatment Progress

To ensure efficient distal maxillary molar movement and prevent undesirable side effects, miniscrews (7.0 mm length × 1.8 mm diameter; Orlus, Ortholution, Seoul, Korea) were placed in the maxillary alveolar buccal bone between the second premolar and first molar on both sides. In the mandible, one miniscrew per side was placed between the second premolar and the first molar for maximum anchorage.

After primary stability was confirmed, the miniscrews in the maxilla were splinted to the first premolars with a 0.018 × 0.025-inch stainless steel wire, ensuring indirect anchorage for distal molar movement. To apply the distal force, NiTi open-coil springs, guided by a 0.018 × 0.025-inch stainless steel wire, were used between the maxillary first premolar and the first molar on both sides with a magnitude of 200 to 250 g. During distal molar movement, additional crimpable hooks were attached loosely, and continuous distal force was applied with an elastomeric chain ([Figure 5](#) .




After 5 months, the maxillary first molars had moved approximately 4.0 mm distally, resulting in an end-to-end Class II molar


relationship. In the mandible, in which the first premolars had been extracted, leveling and alignment were in progress ([Figure 6A](#) ).




After 8 months, distal maxillary molar movement of 8.0 mm was completed, and a Class I molar relation had been established on both sides ([Figure 6B](#) ). The maxillary first premolars were then extracted and the maxillary anterior teeth were retracted after leveling and alignment ([Figure 6C](#) ). The existing miniscrews between the second premolar and the first molar were removed to avoid interference with distal premolar movement. During leveling and retraction, new miniscrews were implanted distal to the maxillary first molar; these were used as anchorage for anterior retraction and to maintain the new distal positions of the molars ([Figure 6D](#) ).

After 20 months, the treatment was complete, and the miniscrews were removed easily by the orthodontist without anesthesia. Lingual fixed retainers were bonded to both arches, and an additional removable circumferential retainer was placed on the maxillary arch to prevent relapse of the large amount of maxillary teeth movement and to secure the positions of the maxillary third molars. The patient was instructed to wear it only at night.

Treatment Results

A Class I molar relationship and a normal overjet/ overbite were achieved, and the maxillary and mandibular midlines were corrected ([Figure 7](#) ). The protrusion of the upper and lower lips was corrected, and the strain of the mentalis muscle on lip closure was relieved. As a result, a harmonious facial profile was achieved ([Figure 8](#) ). The final panoramic radiograph confirmed that the maxillary third molars on both sides had erupted successfully and were well aligned ([Figure 9](#) ).



On the cephalometric superimposition, the maxillary molar had moved to the distal by 7.5 mm. However, because the force was applied at the crown level, distal tipping (7.7 degrees) occurred during the active phase of distal molar movement. During the second phase of treatment, the angulation of the first molars was controlled with mesial tipping of 5.3 degrees, with a final angulation of 2.4 degrees distal relative to the initial position ([Table 2](#) ).

The maxillary and mandibular anterior teeth were retracted 5.0 mm and 2.0 mm, respectively, as initially planned. This improved the upper and lower lip positions by placing them 1.0 mm and 1.3 mm in front of the esthetic line, respectively. Distal molar movement tends to increase the vertical relationship and worsen the skeletal Class II and hyperdivergent profile. However, the patient's vertical relationships were maintained because an intrusive force was applied to the maxillary molars during and after distal molar movement ([Figure 10](#) ; [Table 1](#) ). The patient was satisfied with the tooth alignment and facial profile. Acceptable occlusion and normal overjet/overbite had been maintained after 1 year of retention ([Figure 11](#) ).

DISCUSSION [Return to TOC](#)

This case was characterized by Class II skeletal and dental patterns together with severe crowding. Therefore, maximum distal movement of the maxillary molars and extraction of the premolars were indicated. Consequently, sufficient distal molar movement was achieved without anchorage loss using indirect miniscrew anchorage and a NiTi coil spring. The first premolars, which were splinted to the buccal miniscrews, acted as absolute anchorage devices for the distal force, preventing mesial movement of the anterior teeth and completing the anterior retraction stage more rapidly and efficiently. Control of molar angulation was essential during the second phase of treatment. Root axis control was possible after the distal molar movement with little loss of anchorage, since the molars were tied to the newly implanted miniscrews. The vertical facial relationship was maintained because of the vertical control of the molars, which was easily controlled by the miniscrews.

Previous studies of distal molar movement using NiTi coil springs and a Nance button reported the following results. Gulati et al²¹ reported 2.75 mm of distal molar movement with 1.10 mm of mesial premolar movement; Keles²² reported 4.92 mm of distal molar movement with 1.31 mm of mesial premolar movement; Mavropoulos et al²³ reported 1.90 mm of distal molar movement with 2.08 mm of mesial premolar movement; Bondemark and Thorneus²⁴ reported 1.70 mm of distal molar movement with 1.90 mm of incisor flaring; and Öztürk et al²⁵ reported 5.44 mm on the right and 3.75 mm on the left of distal molar movement, with 3.06 mm (right) and 2.56 mm (left) of mesial premolar movement. These results represent anchorage loss ranging from 26.6% to 111.8% relative to the molar movement (premolar or incisor mesial movement/molar distal movement ×100).

The rate of anchorage loss was evaluated by measuring the amount of movement and axis change on cephalograms obtained immediately after completing distal molar movement and debonding. During the 8 months of distal molar movement, the maxillary first molar moved to the distal by 8.0 mm and tipped 7.7 degrees distally. The maxillary first premolar moved to the mesial by 0.5 mm and tipped 0.9 degrees mesially. The maxillary incisors did not show any change. After treatment, the maxillary first molar had relapsed slightly to the mesial by 0.5 mm and tipped 5.3 degrees. Accordingly, the anchorage loss rate was 6.25%, which shows that the indirect anchorage with miniscrews was stable for distal molar movement ([Figure 12](#) ; [Table 2](#) ).

Although distal molar movement using miniscrews is a very effective and simple treatment modality, it is not a universally applicable method. First, the status of the second molars and the posterior space should be considered. In adolescent patients who are still growing, the maxillary posterior area, including the maxillary tuberosity, continues to grow as the maxillary molars move distally.²⁶ In addition, distal

movement of the maxillary molars in adults has several limitations, such as the second molar space and limited posterior space.²⁷ Extraction of the third molars should be considered prior to distal molar movement after carefully inspecting the status of the second and third molars as well as the maxillary tuberosity. As shown in this case, extraction of the second molars instead of the third molars may be an alternative, depending on the respective situation. However, second molar extraction should be considered only after prudent inspection of the third molars. Successful eruption of the third molars after extraction of the second molars requires (1) confirmation of normal size and shape by radiographic examination; (2) favorable inclination of the third molars, with a 15- to 30-degree angle to the long axis of the first molar; and (3) performance of second molar extraction before Nolla developmental stage 8 (two thirds of root formed).²⁸⁻³⁰

Second, the stability of the miniscrews must be monitored carefully during distal molar movement. If an undesired shift of the premolars that are splinted to the miniscrews takes place, the clinician must determine whether this shift is caused by mobility of the miniscrews or breakage of the splint bonding. The success rates of miniscrews have been reported to range from 83% to 93%.^{31,32} We investigated the failure rates of miniscrews that had been placed in our department between 2001 and 2005. Success was defined as a lack of mobility after application of force for 1 year. In 2001, the failure rate was 30.7%, but the failure rate decreased annually and was only 7.8% in 2005. This improvement in miniscrew stability can be attributed to improved surgical techniques as well as the advanced design of the miniscrews by trial and error. According to Liou et al,³³ miniscrews are not always stationary, although the average amount of tipping (0.4 mm) is not clinically remarkable. This finding was confirmed with the 0.5-mm mesial movement of the premolars in the present case. If a loss of anchorage above such limits is found, careful evaluation will be needed to determine the reason and its solution.

Third, the three-dimensional position of the molars should be controlled precisely in regard to arch form integrity, angulation, and vertical relationships. For example, in the case of segmental force application, an in-and-out position (first order) of the molars and arch form integrity are difficult to maintain, making careful monitoring very important. In terms of the second order, the angulation of molars must be controlled carefully because the line of force application through the center of resistance of the posterior segment can determine angulation of the molars during distal molar movement. If molars are tipped to the distal after molar movement, angulation control is required by root movement without relapse during the second phase of treatment. The vertical position during distal molar movement is controlled by the application of an intrusive force using miniscrews, preventing an increase in vertical facial height.

Finally, the periodontal condition should be considered carefully. Distal molar movement may cause inflammation and gingival enlargement in posterior regions. Therefore, a thorough examination of the periodontal condition should be completed before orthodontic treatment, and periodic periodontal management and radiographs are necessary during treatment. However, it is most important to remember that distal molar movement should not exceed anatomic and biologic limits.

CONCLUSIONS [Return to TOC](#)

The advantages of miniscrew anchorage and NiTi coil springs over conventional mechanics include:

- Treatment is simple and comfortable for both the patient and orthodontist.
- There is no need for additional laboratory work.
- There is no loss of anchorage, so the entire treatment time can be shortened.
- Treatment is esthetic because there is no need for bracketing of the anterior teeth during the distal molar movement phase.
- The amount of movement on each side is controllable, making it possible to apply an asymmetric force.

REFERENCES [Return to TOC](#)

1. Tucker MR. Orthognathic surgery versus orthodontic camouflage in the treatment of mandibular deficiency. *J Oral Maxillofac Surg.* 1995; 53:572–578.
2. Tulloch JF, Lenz BE, Phillips C. Surgical versus orthodontic correction for Class II patients: age and severity in treatment planning and treatment outcome. *Semin Orthod.* 1999; 5:231–240.
3. Egolf RJ, Begole EA, Upshaw HS. Factors associated with orthodontic patient compliance with intraoral elastic and headgear wear. *Am J Orthod.* 1990; 97:336–348.
4. Agar U, Doruk C, Bicakci AA, Bukusoglu N. The role of psycho-social factors in headgear compliance. *Eur J Orthod.* 2005; 27:263–267.
5. Hilgers JJ. The pendulum appliance for Class II non-compliance therapy. *J Clin Orthod.* 1992; 26:706–714.
6. Byloff FK, Darendeliler MA. Distal molar movement using the pendulum appliance. Part 1. Clinical and radiological evaluation. *Angle*

7. Carano A, Testa M. The distal jet for upper molar distalization. *J Clin Orthod.* 1996; 30:374–380.

8. Ngantung V, Nanda RS, Bowman SJ. Posttreatment evaluation of the distal jet appliance. *Am J Orthod Dentofacial Orthop.* 2001; 120:178–185.

9. Jones RD, White JM. Rapid Class II molar correction with an open-coil jig. *J Clin Orthod.* 1992; 26:661–664.

10. Brickman CD, Sinha PK, Nanda RS. Evaluation of the Jones jig appliance for distal molar movement. *Am J Orthod Dentofacial Orthop.* 2000; 118:526–534.

11. Gianelly AA, Vaitas AS, Thomas WM. The use of magnets to move molars distally. *Am J Orthod Dentofacial Orthop.* 1989; 96:161–167.

12. Bondemark L, Kurol J, Bernhold M. Repelling magnets versus superelastic nickel-titanium coils in simultaneous distal movement of maxillary first and second molars. *Angle Orthod.* 1994; 64:189–198.

13. Gianelly AA, Bednar J, Dietz VS. Japanese Ni-Ti coils used to move molars distally. *Am J Orthod Dentofacial Orthop.* 1991; 99:564–546.

14. Kyung SH, Hong SG, Park YC. Distalization of maxillary molars with a midpalatal miniscrew. *J Clin Orthod.* 2003; 37:22–26.

15. Keles A, Erverdi N, Sezen S. Bodily distalization of molars with absolute anchorage. *Angle Orthod.* 2003; 73:471–482.

16. Gelgor IE, Buyukyilmaz T, Karaman AI, Dolanmaz D, Kalayci A. Intraosseous screw-supported upper molar distalization. *Angle Orthod.* 2004 Dec; 74:838–850.

17. Park HS, Lee SK, Kwon OW. Group distal movement of teeth using microscrew implant anchorage. *Angle Orthod.* 2005 Jul; 75:602–609.

18. Kinzinger G, Wehrbein H, Byloff FK, Yildizhan F, Diedrich P. Innovative anchorage alternatives for distalization—an overview. *J Orofac Orthop.* 2005; 66:397–413.

19. Sugawara J, Kanzaki R, Takahashi I, Nagasaka H, Nanda R. Distal movement of maxillary molars in nongrowing patients with the skeletal anchorage system. *Am J Orthod Dentofacial Orthop.* 2006; 129:723–733.

20. Kircelli BH, Pektas ZO, Kircelli C. Maxillary molar distalization with a bone-anchored pendulum appliance. *Angle Orthod.* 2006 Jul; 76:650–659.

21. Gulati S, Kharbanda OP, Parkash H. Dental and skeletal changes after intraoral molar distalization with sectional jig assembly. *Am J Orthod Dentofacial Orthop.* 1998; 114:319–327.

22. Keles A. Maxillary unilateral molar distalization with sliding mechanics: a preliminary investigation. *Eur J Orthod.* 2001; 23:507–515.

23. Mavropoulos A, Karamouzou A, Kiliaridis S, Papadopoulos MA. Efficiency of noncompliance simultaneous first and second upper molar distalization: a three-dimensional tooth movement analysis. *Angle Orthod.* 2005; 75:532–539.

24. Bondemark L, Thorneus J. Anchorage provided during intra-arch distal molar movement: a comparison between the Nance appliance and a fixed frontal bite plane. *Angle Orthod.* 2005; 75:437–443.

25. Öztürk Y, Firatli S, Almac L. An evaluation of intraoral molar distalization with nickel-titanium coil springs. *Quintessence Int.* 2005; 36:731–735.

26. Ricketts RM. Perspectives in the clinical application of cephalometrics. The first fifty years. *Angle Orthod.* 1981; 51:115–150.

27. Jedlickova O. Diagnostic method for assessment of possible distalization of the first upper molar. *Prakt Zahn Lek.* 1990; 38:8245–249.

28. Bishara SE, Burkey PS. Second molar extractions: a review. *Am J Orthod.* 1986; 89:415–424.

29. Lehman R. A consideration of the advantages of second molar extractions in orthodontics. *Eur J Orthod.* 1979; 1:119–124.

30. De-la-Rosa-Gay C, Valmaseda-Castellon E, Gay-Escoda C. Spontaneous third-molar eruption after second-molar extraction in orthodontic patients. *Am J Orthod Dentofacial Orthop.* 2006; 129:337–344.

31. Miyawaki S, Koyama I, Inoue M, Mishima K, Sugahara T, Takano-Yamamoto T. Factors associated with the stability of titanium screws

placed in the posterior region for orthodontic anchorage. *Am J Orthod Dentofacial Orthop.* 2003; 124:373–378.

32. Park HS. Clinical study on success rate of microscrew implants for orthodontic anchorage. *Kor J Orthod.* 2003; 33:151–156.

33. Liou EJ, Pai BC, Lin JC. Do miniscrews remain stationary under orthodontic forces?. *Am J Orthod Dentofacial Orthop.* 2004; 126:42–47.

TABLES [Return to TOC](#)

Table 1. Comparison of Cephalometric Measurements Before and After Treatment

Measurement ^a	Pretreatment	Posttreatment
SNA (°)	79.5	77.5
SNB (°)	70.4	69.5
ANB (°)	9.1	8.0
Wits appraisal (mm)	1.5	0.9
Mandibular body length (mm)	66.3	66.2
SN-GoMe (°)	57.0	56.5
Björk sum (°)	417.0	416.1
U1 to facial plane (mm)	22.1	16.7
L1 to facial plane (mm)	14.5	12.1
Point A to N perp (mm)	4.3	3.8
Pog to N perp (mm)	−16.1	−16.6
U1 to SN (°)	93.3	92.0
IMPA (°)	87.3	85.7
Upper lip to Ricketts E-line (mm)	5.2	1.0
Lower lip to Ricketts E-line (mm)	6.1	1.3

^a A indicates point A; B, point B; Go, gonion; IMPA, incisor-mandibular plane angle; L1, mandibular incisor; Me, menton; N, nasion; Pog, pogonion; S, sella; U1, maxillary incisor.

Table 2. Position and Axis Changes of Maxillary First Molars, First Premolars, and Central Incisors During Treatment

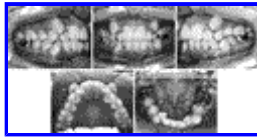
Measurement ^a	Pretreatment	After Distal	
		Movement	Posttreatment
U6 to PTV (mm)	15.6	7.6	8.1
U6 to SN (°)	67.2	59.5	64.8
U4 to PTV (mm)	32.3	32.8	—
U4 to SN (°)	84.1	85.0	—
U1 to PTV (mm)	48.8	48.9	43.8
U1 to SN (°)	93.3	93.4	92.0

^a N indicates nasion; PTV, Pterygoid Vertical Line; S, sella; U1, maxillary central incisor; U4, maxillary first premolar; U6, maxillary first molar.



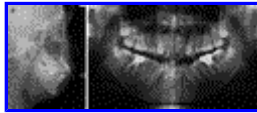
[Click on thumbnail for full-sized image.](#)

Figure 1. Pretreatment facial photographs



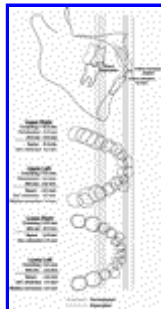
[Click on thumbnail for full-sized image.](#)

Figure 2. Pretreatment intraoral photographs



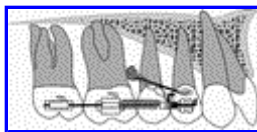
[Click on thumbnail for full-sized image.](#)

Figure 3. Pretreatment radiographs



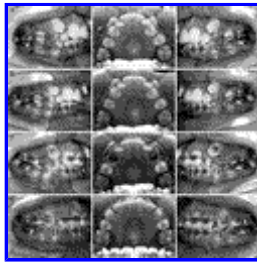
[Click on thumbnail for full-sized image.](#)

Figure 4. Treatment planning procedure by occlusogram



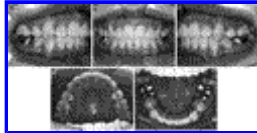
[Click on thumbnail for full-sized image.](#)

Figure 5. Distal molar movement mechanics. Miniscrews were splinted to the first premolars with 0.018- × 0.025-inch stainless steel wire, and NiTi open-coil springs were used to apply the distal forces. Additional crimpable hooks were loosely attached and a continuous force was applied with an elastomeric chain



[Click on thumbnail for full-sized image.](#)

Figure 6. Treatment progress. (A) After 5 months, the maxillary first molars had moved distally approximately 4.0 mm, achieving an end-to-end Class II molar relation. (B) After 8 months, maxillary distal molar movement of 8.0 mm was completed and a Class I molar relationship on both sides was accomplished. (C) The maxillary first premolars were then extracted, and the leveling and alignment were in progress. (D) The maxillary anterior teeth were retracted



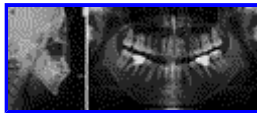
[Click on thumbnail for full-sized image.](#)

Figure 7. Posttreatment intraoral photographs



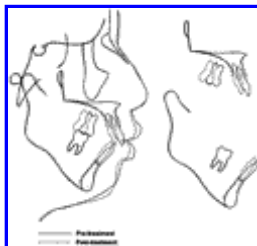[Click on thumbnail for full-sized image.](#)

Figure 8. Posttreatment facial photographs



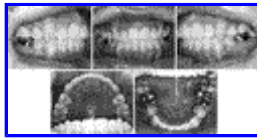
[Click on thumbnail for full-sized image.](#)

Figure 9. Posttreatment radiographs



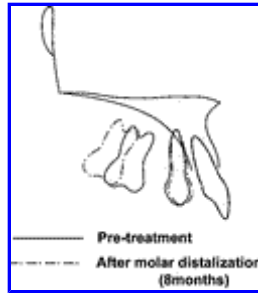
[Click on thumbnail for full-sized image.](#)

Figure 10. Cephalometric superimposition



Click on thumbnail for full-sized image.

Figure 11. One-year retention intraoral photographs



Click on thumbnail for full-sized image.

Figure 12. Maxillary cephalometric superimposition for evaluation of anchorage loss rate

^a Resident, Department of Orthodontics, College of Dentistry, Yonsei University, Seoul, South Korea

^b Professor, Department of Orthodontics, College of Dentistry, Yonsei University, Seoul, South Korea

^c Assistant Professor, Department of Orthodontics, College of Dentistry, Yonsei University, Seoul, South Korea

Corresponding author: Dr Young-Chel Park, Department of Orthodontics, College of Dentistry, Yonsei University, 134 Shinchon-dong, Seodaemun-gu, Seoul, 120-752, South Korea (E-mail: ypark@yumc.yonsei.ac.kr)