

[\[Print Version\]](#)

[\[PubMed Citation\]](#) [\[Related Articles in PubMed\]](#)

TABLE OF CONTENTS

[\[INTRODUCTION\]](#) [\[CASE HISTORY\]](#) [\[TREATMENT RESULTS...\]](#) [\[REFERENCES\]](#) [\[TABLES\]](#) [\[FIGURES\]](#)

The Angle Orthodontist: Vol. 76, No. 2, pp. 341–348.

Mandibular Distraction Osteogenesis and Maxillary Osteotomy in a Class II division 1 Patient with Chronic Juvenile Arthritis

Steven Lewis Singer;^a Peter Julian Southall;^b Ian Rosenberg;^c David Gillett;^d Mark Walters^e

ABSTRACT

A patient with juvenile chronic arthritis presented with a malocclusion characterized by mandibular hypoplasia, symphyseal deficiency, and an increased mandibular occlusal plane angle. Correction of the mandibular defect required both the horizontal advancement of the mandible and a counterclockwise rotation of the proximal segment to reduce the mandibular occlusal plane angle. This was achieved by a combination of distraction osteogenesis to horizontally advance the mandible (14 mm), followed by manipulation of the postdistraction regenerate to reduce the mandibular occlusal plane and increase the symphyseal projection. The counterclockwise rotation of the mandibular body resulted in the creation of a posterior open bite. After a three-month period to allow consolidation of the mandibular distraction osteogenesis, secondary maxillary surgery at the Le Fort 1 level was performed to reestablish maxillary occlusal contact at the new mandibular occlusal plane. A genioplasty was also performed to improve chin projection.

KEY WORDS: Juvenile chronic arthritis, Mandibular distraction osteogenesis, Postdistraction regenerate.

Accepted: April 2005. Submitted: January 2005

INTRODUCTION [Return to TOC](#)

When juvenile chronic arthritis (JCA) involves the condylar cartilage, it can adversely affect the growth and development of the mandible.¹⁻⁷ The earlier the onset and the greater the severity of the pathology, the more abnormal the subsequent mandibular development.^{1,6} A decrease in muscle of mastication activity also has been suggested as a contributor to the mandibular form.^{1,4}

Skeletally, this manifests as a reduction in both ramus height and corpus body length.⁷ The mandible develops a posterior growth rotation, an increase in mandibular plane angle, and lower facial height and antgonial notching.^{2,5,7} This growth pattern produces a Class II division 1 malocclusion characterized by a hypoplastic and retrusive mandible with an anterior open-bite tendency.^{1,4-6} The maxilla is often horizontally well placed even in the presence of severe disruption of mandibular growth.⁷ Vertically, however, there tends to be a lack of posterior maxillary development secondary to the reduced ramus height. Clinically, this manifests as a steep occlusal plane that can adversely affect dental esthetics and mandibular function.^{2,5,8} Dentally, the lower incisors generally overerupt and procline in compensation for the underlying Class II skeletal pattern.^{2,3,5,7}

When the resultant malocclusion is severe, a combination of orthodontics and orthognathic surgery is required to attain both an acceptable occlusion and an improvement in facial esthetics. Bimaxillary surgery is necessary if the occlusal plane angle has to be reduced. One of the limitations to achieving these goals is the ability to sufficiently advance as well as to rotate the mandibular body in a counterclockwise direction in the presence of associated soft tissue hypoplasia, a feature common in these patients.



Distraction osteogenesis can increase bone volume by gradual traction of a fracture callus formed between osteotomized bony segments.⁹⁻¹¹ The application of this technique to the treatment of a severe dentofacial deformity that is characterized by significant hard and soft tissue deficiency has become an established technique in craniofacial surgery over the last decade. It is particularly useful for treating cases of severe bony hypoplasia where the surgical movement required to correct the malocclusion is outside the range predictably achievable with routine orthognathic surgery techniques.⁹⁻¹¹




One of the criticisms of distraction osteogenesis, however, is that accurate positioning of the proximal segment can be difficult to achieve either because of an inaccurate displacement vector or because of an unpredictable soft tissue influence on the immature regenerate.^{12,13} It has been shown in an animal model¹⁴ and in clinical case reports that postdistraction regenerate can be molded by external forces.¹⁵⁻¹⁷ It also has been suggested that a more accurate positioning of a proximal segment could be achieved by manipulating the distraction regenerate.^{15,16}

In this case history, we report the successful combination of distraction to horizontally advance a severely hypoplastic mandible in a patient with JCA, followed by manipulation of the regenerate to achieve accurate positioning of the mandibular body. A maxillary osteotomy was subsequently performed to reestablish maxillary occlusal contact at the new mandibular occlusal plane.

CASE HISTORY [Return to TOC](#)

An 18-year-old Caucasian female patient was referred to the Cranio Maxillo Facial unit of Princess Margaret Hospital for assessment of occlusion in 1998. There was a medical history of JCA. At the time of presentation, the disease process was inactive. The patient expressed a concern about facial esthetics particularly in relation to a lack of chin prominence.

Clinical examination revealed facial features consistent with JCA involvement in the temporomandibular joints with a divergent facial profile, a hypoplastic mandible with associated soft tissue deficiency and a deficient chin ([Figure 1](#) ). Intraoral examination revealed an overjet of six mm and a reduced overbite ([Figure 1](#) ). The upper and lower incisors were crowded and proclined. The molar relationship was one-fourth unit Class II on both sides. The upper first and lower second permanent premolars had previously been extracted as part of a previous unsuccessful course of fixed appliance orthodontic intervention before referral.

Radiographic investigation revealed a severe skeletal Class II pattern due to mandibular hypoplasia ([Table 1](#) ). Ramus height and corpus length were reduced, and the mandibular symphysis was deficient ([Figure 2](#) ). The mandibular plane angle (SN-Mand 64°) was increased, and antgonial notching was evident. The occlusal plane was increased (SN-OP 34°). The maxilla was retrusive (SNA 74°), however, the upper lip was clinically well balanced ([Figure 1](#) ). The lower incisors were proclined in compensation for the retrusive mandible (Mand-1 96°). The morphology of the temporomandibular joints was examined by a computerized tomography (CT) investigation, which revealed the absence of a glenoid fossa and a flattening of the articular eminence. The condyles translated over the eminence on opening. There was a history of pain and discomfort over the masseter muscles. Maximum opening was 32 mm.

Treatment plan

Because the patient's principal complaint was related to her facial esthetics, treatment options were directed to address the underlying mandibular deficiency. The severity of the skeletal Class II pattern meant that jaw surgery was required to achieve these goals. Because of the previous history of lower second bicuspid extraction, the option of mandibular extractions for maximum incisor retraction before mandibular advancement alone was not available. Counterclockwise rotation of the mandibular body was required to reduce the occlusal plane angle and increase the symphyisial projection. Secondary maxillary surgery was required to reestablish occlusal contact to the new occlusal plane and eliminate the posterior open bite produced by the counterclockwise rotation of the mandibular body.



The aims of treatment were to:


- improve the esthetics of the lower face;
- reduce the overjet and maintain a positive overbite;
- reduce the steep occlusal plane;
- increase the chin prominence.




The following treatment was planned to achieve these goals.

1. Bilateral distraction osteogenesis of the mandible to increase the corpus body length;
2. On completion of distraction, anterior intermaxillary elastic traction to mold the distraction regenerate to produce a counterclockwise rotation of the proximal mandibular segment to reduce the occlusal plane angle and increase the symphyseal projection. An inclined maxillary splint was to be placed to control movement. The splint would also be necessary to support the mandible during the consolidation phase because of the creation of a posterior open bite after rotation of the mandibular body;
3. After a three-month period to allow consolidation of the distraction regenerate, a Le Fort I maxillary osteotomy would be performed to reestablish maxillary occlusal contact to the new mandibular occlusal plane;
4. A genioplasty would be carried out to increase symphyseal projection.

Treatment progress

Fixed appliances (0.022 × 0.028 inch preadjusted edgewise) were placed in November 1999 to align the dentition, level the occlusal plane, and coordinate the archform in preparation for surgery. A bilateral osteotomy was performed at the angle of mandible and at the level of the ascending ramus via an intraoral approach. An intraoral distractor (RK 20 mm Medicon Instrumente, Tuttlingen, Germany) was placed spanning the osteotomy cuts. The distractor device was orientated to produce an oblique displacement of the mandibular body. After a period of three days, distraction was started by activating the distractor mechanism one turn twice per day (0.8 mm). Distraction was continued until the maximum activation of the appliance had been achieved. This produced a 14 mm increase in horizontal mandibular projection at B point ([Table 1](#) ). A Class III incisal relationship was produced, and a positive overbite was maintained during this period ([Figure 3](#) ).



Once activation was stopped, the screws holding the distractor were removed from the proximal segment under general anesthesia. A maxillary splint was attached using eyelet wires. On insertion, the splint contacted the mandibular second molars sloping up toward the maxillary incisors. Full-time intermaxillary elastic traction (one-fourth inch 6 oz) was applied between the maxillary and mandibular anterior teeth to produce a counterclockwise rotation of the body of the mandible by molding the uncalcified distraction regenerate ([Figure 4](#) ). Elastic traction was stopped once the mandibular teeth occluded into the maxillary splint.


On removal of the fixed splint, a posterior open bite had been produced by the counterclockwise rotation of the mandibular body ([Figure 5](#) ). An upper removable appliance that contacted all the mandibular teeth was inserted to support the mandible while the regenerate calcified. A Le Fort maxillary osteotomy was carried out in August 2000 to reestablish occlusal contact between the maxillary and mandibular dentition ([Figure 6](#) ). A genioplasty was also performed to increase chin prominence, and the mandibular distractor was removed. Postsurgical orthodontics was carried out to finalize the occlusion ([Figure 7](#) ). Appliances were removed in June 2001, and a maxillary Hawley and mandibular Dohner retainer was inserted to maintain dental alignment. After treatment, maximum opening remained at 32 mm. There was no pain or discomfort from the temporomandibular joint (TMJ) or related musculature.

TREATMENT RESULTS AND DISCUSSION [Return to TOC](#)

The skeletal deformity produced by the JCA had resulted in a hypoplastic mandible characterized by a short ramus, a reduced mandibular body length, and a deficient symphysis. The mandibular occlusal plane was increased. These features were characteristic of her medical condition.¹⁻⁷ Although the overjet was only six mm, lower incisal dentoalveolar compensation was masking a severe mandibular retrusion (ANB 12°).

Distraction osteogenesis was chosen as the method for surgical correction of the mandibular defect because of its ability to predictably lengthen bone, where there is both significant hard and soft tissue hypoplasia.⁹⁻¹¹

Because of the requirement to both lengthen the mandible and reduce the mandibular occlusal plane angle, it was necessary for the distraction process to produce a horizontal and rotational movement of the mandibular body. The horizontal component of mandibular movement was achieved using an internal distractor, which lengthened the mandible 14 mm as measured by horizontal change in B point ([Figure 6](#) ). This illustrates the ability of distraction osteogenesis to produce significant bony displacement even in the presence of bony and soft tissue hypoplasia ([Figure 7](#) ).^{16,18}

The distractors were placed obliquely to maximize the forward displacement of the mandibular body while reducing the tendency to bite opening, which would have occurred if they had been placed with a horizontal orientation.¹⁸ It was interesting to note that despite the distractor having an activation of 20 mm, the mandible was only displaced 14 mm at B point ([Table 1](#) ). This was due to the displacement vector having a vertical as well as a horizontal component. Also, there may have been a degree of flexing between the bony segments across the osteotomy site during distraction that could have produced a posterior displacement of the ramus as well as anterior movement of the mandibular body. The lack of a normal temporomandibular anatomy may have also contributed to a potential lack of distal segment stability. The difference between the actual surgical displacement relative to the range of activation of a distractor device can influence the facial change attained. In view of this, it would be advantageous to use a distractor that can be activated further than the

planned surgical move so that extra bony movement is possible if clinically required.

The history of premolar extractions before referral to Princess Margaret hospital prevented presurgical orthodontic decompensation and thus limited the amount of mandibular body advancement achievable at surgery. The ideal presurgical extraction pattern would have been the removal of the upper second and lower first bicuspids. The latter would have created space for both the relief of crowding and the uprighting of the lower incisors before surgery. This would have enabled a greater surgical advancement of the mandible than that attained in this clinical history.

The reduction in the mandibular occlusal plane and the increase in symphyseal projection was achieved by the controlled manipulation of the postdistraction regenerate. An angled maxillary occlusal splint was placed to act as an occlusal guide so as to direct the amount of mandibular body rotation during manipulation (Figure 5). The mandibular occlusal plane was reduced from 34° to 23° (Figure 6). This change supports animal experimentation¹⁴ and clinical case histories^{15–18} that have demonstrated the ability to manipulate the immediate postdistraction regenerate by the application of external force.

The alternative use of an external multidirectional distractor would have allowed the application of both horizontal and vertical mandibular displacement vectors, but there are two potentially significant problems with this approach. First, extraoral distractors are fixated by pins that penetrate the skin. This can produce unsightly external scarring during the distraction process that can detract from the esthetics of the treatment result. Second, compared with routine orthognathic surgery, one of the criticisms of distraction osteogenesis is that unless the distractor is accurately placed, incorrect displacement vectors will produce a less than satisfactory occlusal end result.^{15,16} This is especially likely to arise when dealing with a patient who has a severe dentofacial deformity because there is often reduced surgical access, abnormal hard tissue form, and significant hard tissue hypoplasia. Also, such a distractor may not be able to produce the rotational movements required.

The horizontal mandibular advancement and the rotational change in the mandible were stable one year after surgery (Table 1). Gradual stretching of hypoplastic soft tissue during distraction has been suggested to be important in such postoperative stability.¹⁸ Also, the location of the mandibular osteotomy at the angle of the mandible avoided any increase in ramus height and therefore prevented stretching of the pterygomasseteric sling and would have contributed to postsurgical stability.¹⁹ As the body of the mandible rotated, the projection of the mandibular symphysis increased. Despite this, the severity of the symphyseal deficiency necessitated a genioplasty to further increase the chin prominence and to improve chin projection. Pogonion was advanced 23 mm by this combination. At one year, B point was stable, but pogonion had moved distally two mm suggesting localized remodeling (Table 1).

The reduction in the mandibular occlusal plane made maxillary surgery necessary to reestablish occlusal contact. Although the cephalometric value of SNA was reduced, the upper lip was well balanced (Figure 1). It was therefore decided to maintain the relative horizontal position of the maxilla limiting surgical change to a counterclockwise rotation of the maxilla. As this occurred, the maxillary incisors proclined and reestablished a positive overjet.

This case history illustrates the ability to carry out controlled multivectoral change using distraction osteogenesis. The ability to manipulate the immediate postdistraction mandibular regenerate provides the clinician a method of controlling the final position of a distracted mandibular body and, in this case, was an alternative to the use of an external multivectoral distractor.

REFERENCES [Return to TOC](#)

1. Larheim TA, Haanaes HR. Micrognathia, temporomandibular joint changes and dental occlusion in juvenile rheumatoid arthritis of adolescents and adults. *Scand J Dent Res*. 1981; 89:329–338. [[PubMed Citation](#)]
2. Ronning O, Barnes SAR, Pearson MH, Pledger DM. Juvenile chronic arthritis: a cephalometric analysis of the facial skeleton. *Eur J Orthod*. 1994; 16:53–62. [[PubMed Citation](#)]
3. Kjellberg H, Killiaridis S, Thilander B. Dentofacial growth in orthodontically treated and untreated children with juvenile chronic arthritis (JCA). A comparison with Angle Class II division 1 subjects. *Eur J Orthod*. 1995; 17:357–373. [[PubMed Citation](#)]
4. Kjellberg H, Fasth A, Killiaridis S, Wenneberg B, Thilander B. Craniofacial structure in children with juvenile chronic arthritis (JCA) compared with healthy children with ideal or postnormal occlusion. *Am J Orthod Dentofacial Orthop*. 1995; 107:67–78. [[PubMed Citation](#)]
5. Kjellberg H. Craniofacial growth in juvenile chronic arthritis. *Acta Odontol Scand*. 1998; 56:360–365. [[PubMed Citation](#)]
6. Svensson B, Adell R, Kopp S. Temporomandibular disorders in juvenile chronic arthritis patients. *Swed Dent J*. 2000; 24:83–92. [[PubMed Citation](#)]
7. Stabrun AE. Impaired mandibular growth and micrognathic development in children with juvenile rheumatoid arthritis. A longitudinal study of lateral cephalographs. *Eur J Orthod*. 1991; 13:423–434. [[PubMed Citation](#)]

8. Wolford LM, Chemello PD, Hillard PD. Occlusal plane alteration in orthognathic surgery-Part I: effects on function and aesthetics. *Am J Orthod Dentofacial Orthop.* 1994; 106:434–440. [[PubMed Citation](#)]
9. Cope JB, Samchukov ML. Mineralization dynamics of regenerate bone during mandibular osteodistraction. *J Oral Maxillofac Surg.* 2001; 30:234–242.
10. McCarthy JC, Schreiber J, Karp N, Thorne CH, Grayson BH. Lengthening of the human mandible by gradual distraction. *Plast Reconstr Surg.* 1992; 89:1–8. [[PubMed Citation](#)]
11. Hopper RA, Altug AT, Grayson BH, Barillas I, Sato Y, Cutting CB, McCarthy JG. Cephalometric analysis of the consolidation phase following bilateral pediatric mandibular distraction. *Cleft Palate Craniofac J.* 2003; 40:233–240.
12. Van Sickels JE. Distraction osteogenesis versus orthognathic surgery. *Am J Orthod Dentofacial Orthop.* 2000; 118:482–484. [[PubMed Citation](#)]
13. Gosain AK., Plastic Surgery Educational Foundation DATA Committee. Distraction osteogenesis of the craniofacial skeleton safety and efficacy report. *Plast Reconstr Surg.* 2001; 17:278–280.
14. Luchs JS, Stelnicki EJ, Rowe NM, Najjher NS, Grayson BH, McCarthy JG. Molding of the regenerate in mandibular distraction: part 1: laboratory study. *J Craniofac Surg.* 2002; 13:205–210. [[PubMed Citation](#)]
15. Kunz C, Hammer B, Prein J. Manipulation of callus after linear distraction: a “lifeboat” or an alternative to multivectoral distraction osteogenesis of the mandible?. *Plast Reconstr Surg.* 2000; 105:674–679. [[PubMed Citation](#)]
16. McCarthy JG, Hopper RA, Hollier LH, Peltomaki T, Katzen T, Grayson BH. Molding of the regenerate in mandibular distraction: clinical experience. *Plast Reconstr Surg.* 2003; 112:1239–1246. [[PubMed Citation](#)]
17. Fritz MA, Sidman JD. Distraction osteogenesis of the mandible. *Curr Opin Otolaryngol Head Neck Surg.* 2004; 12:513–518. [[PubMed Citation](#)]
18. Grayson BH, Santiago PE. Treatment planning and biomechanics of distraction osteogenesis from an orthodontic perspective. *Semin Orthod.* 1999; 5:9–24. [[PubMed Citation](#)]
19. McNamara JA Jr, Carlson DS, Yellich GM, Hendricksen RP. *Musculoskeletal Adaptation Following Orthognathic Surgery.* Monograph #8, Craniofacial Growth Series. Ann Arbor, Michigan: University of Michigan; 1978:91–132.

TABLES [Return to TOC](#)

TABLE 1. Lateral cephalometric measurements

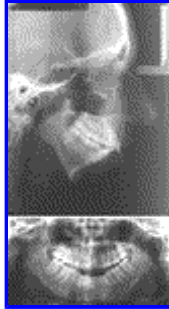	T1*	T2	T3
SNA	74	74	75
SNB	63	72	73
ANB	11	2	2
Maxillary plane (SN-MxP)	13	9	9
Occlusal plane (SN-OP)	34	23	22
Mandibular plane (SN Mand)	64	60	61
YA	—	0	1
YB	—	14	15
Y Pg	—	23	21
Upper incisor to SN	100	107	110
Lower incisor to mandibular plane	96	83	81

*T1 indicates before surgery; T2, Post Le Fort 1 surgery; T3, 1 yr after surgery; YA, Horizontal change in A point from T1; YB, Horizontal change in B point from T1; Y Pg, Horizontal change in pogonion from T1.




[Click on thumbnail for full-sized image.](#)

FIGURE 1. (a) Pretreatment frontal facial view. (b) Pretreatment lateral facial view. (c) Pretreatment anterior intraoral view. (d) Pretreatment right lateral intraoral view. (e) Pretreatment left lateral intraoral view



[Click on thumbnail for full-sized image.](#)

FIGURE 2. (a) Pretreatment lateral cephalometric radiograph. Note retrusive mandible with antigenial notching. (b) Pretreatment orthopantomogram. Note hypoplastic ramus condyle region



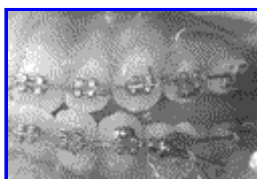[Click on thumbnail for full-sized image.](#)

FIGURE 3. (a) Lateral cephalometric radiograph at the end of distraction. (b) Progress orthopantomogram. Note developing regenerate in distraction region



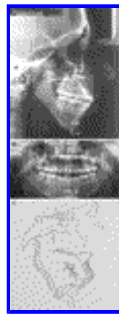[Click on thumbnail for full-sized image.](#)

FIGURE 4. (a) Intraoral view of splint and elastic traction. Note progressive reduction in height of splint from molar to incisal region. (b) Progress lateral cephalometric radiograph after anticlockwise rotation of mandibular body



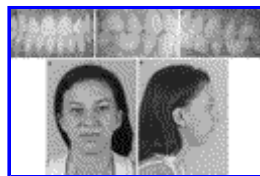[Click on thumbnail for full-sized image.](#)

FIGURE 5. View of posterior open bite after splint removal



Click on thumbnail for full-sized image.

FIGURE 6. (a) Posttreatment lateral cephalometric radiograph. (b) Posttreatment OPG. Note development of new bone in distraction area. (c) Superimposition of pretreatment (solid line) and posttreatment (broken line) lateral cephalometric tracing on SN at Sella. (d) Superimposition of pretreatment (solid line) and posttreatment (broken line) mandibular tracing on SN at Sella



Click on thumbnail for full-sized image.

FIGURE 7. (a) Posttreatment anterior intraoral view. (b) Posttreatment right lateral intraoral view. (c) Posttreatment left intraoral view. (d) Posttreatment anterior facial view. (e) Posttreatment lateral facial view

^aOrthodontist, Princess Margaret Hospital, Dental Department, Thomas St, Perth, Western Australia

^bOrthodontist, Princess Margaret Hospital, Dental Department, Thomas St, Perth, Western Australia

^cOral Surgeon, Princess Margaret Hospital, Dental Department, Thomas St, Perth, Western Australia

^dPlastic Surgeon, Princess Margaret Hospital, Dental Department, Thomas St, Perth, Western Australia

^eSenior Research Scientist, Princess Margaret Hospital, Plastic and Reconstructive Surgery Department, Thomas St, Perth, Western Australia

Corresponding author: Steven Lewis Singer, Princess Margaret Hospital, Dental, Thomas St, Perth, Western Australia 6008, Australia (E-mail: ssin9420@bigpond.net.au)