

[\[Print Version\]](#)  
[\[PubMed Citation\]](#) [\[Related Articles in PubMed\]](#)

## TABLE OF CONTENTS

[\[INTRODUCTION\]](#) [\[MATERIALS AND...\]](#) [\[RESULTS\]](#) [\[DISCUSSION\]](#) [\[CONCLUSIONS\]](#) [\[REFERENCES\]](#) [\[TABLES\]](#) [\[FIGURES\]](#)

*The Angle Orthodontist*: Vol. 76, No. 3, pp. 360-368.

# Skeletal and Dental Effects of a Mini Maxillary Protraction Appliance

Zahir Altug;<sup>a</sup> Aysegul Dalkiran Arslan<sup>b</sup>

## ABSTRACT

The aim of this study was to evaluate the skeletal and dentoalveolar changes achieved by a modified protractor in growing skeletal and dental Class III patients and to compare these changes with normal growth in a Class I untreated control group. The study group consisted of 25 patients (11 girls, 14 boys; mean age 11.74 ± 1.81 years). The control group was composed of 20 patients (15 girls, five boys; mean age 11.89 ± 1.08 years). The Class III patients were treated with a bonded acrylic cap splint type expander and a modified maxillary protractor until a positive overjet was achieved. The mean observation period was 0.65 years. Changes in study and control groups and differences between the groups were analyzed statistically. The results showed that protraction appliance produced a significant positive improvement in maxillo-mandibular relations. The forward movement of the maxilla was significant in treated Class III patients, but a slight difference was present between the two groups regarding maxillary rotation. The effective length of the maxilla was significantly increased in the Class III patients. The mandible was positioned backward, and posterior rotation of the mandible was significant in the treatment group. There was a significant increase in lower anterior facial height of treated Class III patients. The dentoalveolar measurements showed that the maxillary incisors proclined and the mandibular incisors significantly retroclined in the Class III group. A modified maxillary protractor treatment is effective for correcting skeletal Class III malocclusion.

**KEY WORDS:** Class III treatment, Modified protractor, Maxillary retrognathism.

Accepted: April 2005. Submitted: March 2005

## INTRODUCTION [Return to TOC](#)

The characteristics of Class III malocclusions include a large or protrusive mandible, deficient or retrusive maxilla, protrusive mandibular dentition, retrusive maxillary dentition, and combinations of these.<sup>1-4</sup> Although skeletal Class III malocclusions with mandibular prognathism have limited treatment procedures and sometimes surgery is unavoidable, treatment of maxillary retrusion can generally show favorable results with only orthopedic procedures.<sup>5,6</sup>

The use of reverse headgear in the treatment of Class III malocclusion was described more than 100 years ago.<sup>7</sup> It has been demonstrated that a reverse headgear can be an effective method in the treatment of Class III malocclusion with a retrusive maxilla. Clinical studies have reported that forward movement of the maxilla and clockwise rotation of the mandible are typical skeletal effects of this appliance.<sup>8-10</sup> Animal studies have shown that forward movement and anterior displacement of the maxilla are due to remodeling of the circummaxillary sutures, especially zygomaticomaxillary, zygomaticofrontal, frontomaxillary, zygomaticotemporal, and transverse palatine sutures.<sup>11,12</sup> Ngan et al<sup>13</sup> reported good results in dentoskeletal structures and soft tissue with a protraction headgear and maxillary expansion. Others have also concluded that protraction therapy is useful in Class III malocclusions with maxillary retrognathism and produces favorable results in dentoalveolar, skeletal, and profile changes.<sup>14,15</sup>

Optimal timing is important with maxillary protraction because the goal in early treatment is to provide a more favorable environment for normal growth and to improve the psychosocial development of the child.<sup>16,17</sup> The orthopedic approaches in prepubertal and pubertal stages shortens the total treatment time and, if mandibular growth can be controlled after the treatment, an adequate anterior occlusion can be maintained.<sup>17-22</sup> However, Sung and Baik<sup>23</sup> reported that, comparison of the measurements of the treatment effect according to age showed no statistically significant difference. Kapust et al<sup>24</sup> divided patients into three groups: 4-7, 7-10, and 10-14 years and found minimal statistical difference in the three age groups. Merwin et al<sup>25</sup> used a reverse headgear before eight years and after eight years and found similar results as measured by overjet elimination.

Rapid maxillary expansion is commonly used in the treatment of patients with Class III malocclusion because of its action in disturbing the maxillary sutural system to enhance the protraction effect of the face mask.<sup>26,27</sup> According to Proffit and Fields,<sup>28</sup> maxillary expansion must be applied to mobilize the maxillary sutures before maxillary protraction. Some other studies also confirm the effects of maxillary expansion in the Class III treatment.<sup>17,21,29-32</sup>

The purpose of this study was to evaluate the effects of a modified protractor and rapid palatal expansion on dentoalveolar and skeletal structures in Class III patients and to compare these changes with a Class I control group.

## MATERIALS AND METHODS [Return to TOC](#)

In this study, 25 children (11 girls, 14 boys: mean pretreatment age 11.74 years, range 1.81 years) with skeletal and dental Class III malocclusions were treated with maxillary expansion and a modified maxillary protractor in the Department of Orthodontics, University of Ankara, Ankara, Turkey. This study was approved by the Ethical Committee of the University of Ankara in 2004.

The treatment group was selected according to these criteria: (1) noncleft, nonsyndromic white patients with skeletal and dental Class III malocclusion and negative overjet; (2)

vertically normal growth pattern; (3) minimum or moderate crowding in both dental arches; (4) in late mixed or early permanent dentition; (5) no previous orthodontic treatment.

The control group consisted of 20 children (15 girls, five boys; mean age 11.89 years, range 1.08 years) with Class I malocclusions. Bone age was assessed using hand-wrist radiographs according to the Greulich and Pyle atlas. [Table 1](#) shows the chronological and skeletal age distribution of the subjects in the treatment and control groups.

Lateral cephalometric headfilms at the beginning and the end of the treatment were obtained for each patient in both the treatment and the control groups. Pretreatment (T1) cephalometric radiographs ( $\bar{X}$  = 11.74 years) and on immediate postprotraction cephalometric radiographs are taken from all patients (T2) ( $\bar{X}$  = 12.39 years). The average treatment time was 0.65 years with a range of 0.30 years. All radiographs were traced by one researcher (Dr. Arslan) and double digitized on PORDIOS computer program (Purpose on Request Digitizer Input Output System, Institute of Orthodontic Computer Science, Aarhus, Denmark).

The T-W line was used as the x-axis. A vertical line passing through T and perpendicular to the x-axis served as the y-axis ([Figure 1](#)). The changes in 24 landmarks from T1 to T2 were evaluated relative to the x-y coordinate system and were measured according to the differences in landmark position.

A modified maxillary protraction appliance was used to treat the patients ([Figure 2](#)). The appliance consisted of the following.

1. Maxillary expander: a full coverage acrylic cap splint type expansion appliance that covered all the maxillary dentition was constructed ([Figure 3a](#)). Hooks were embedded in both the premolar and the molar region on the buccal sides of the expander. The maxillary expansion appliance was activated everyday (0.20 mm) even in the absence of a posterior crossbite. Activation generally lasted three weeks.
2. Mandibular plate: a mandibular plate covering the posterior mandibular dental arch was constructed ([Figure 3b](#)).
3. Chincap: hooks were attached on the lateral sides of the acrylic chincap to apply cervical forces.
4. Lower face bow (1.2 mm in diameter): it attached the acrylic chincap to the mandibular plate. A horizontal bar was used to apply protraction elastics two to three cm in front of the lips ([Figure 3c,d](#)).

With this appliance, the chin and the lower dental arch were used as an anchorage unit.

The patients were treated with a combination of mini maxillary protractor and rapid maxillary expansion appliance until positive overjet was achieved. Elastics were attached between maxillary hooks to the horizontal bar of the mandibular plate ([Figure 3c,d](#)). A protraction force of 300–400 g per side with an anteroinferior force vector of 20–30 degrees to the occlusal plane was applied. Patients were instructed to use the mini maxillary protractor at least 18 hours a day. In the treatment group, all subjects were overcorrected to a Class I or Class II dental arch relationship with a minimum two-mm overjet. The treatment progress of a patient is shown in [Figures 4 through 6](#).

### Statistical method

To evaluate the changes occurred during treatment/ control groups, paired *t*-test was performed. The levels of significance used were  $P < .05$ ,  $P < .01$ ,  $P < .001$ .

### Method error

The identification of landmark and digitizing procedures were repeated for randomly selected 30 cephalograms by Dr. Arslan at least one month after the first measurement. Repeatability coefficients were above 0.90 for all variables, confirming the reliability of the measurements.

## RESULTS [Return to TOC](#)

Changes in cephalometric measurements in patients treated with protraction headgear before treatment (T1) and 0.65 years after treatment (T2) are shown in [Table 2](#). Comparison of mean values of two groups is shown in [Table 4](#).

### Skeletal changes

Evaluation of cephalometric findings showed that increases in SNA, ANB, Co-A were statistically significant ( $P < .001$ ) ([Table 2](#)). The skeletal changes in both the maxilla and the mandible indicated a significant improvement in the intermaxillary sagittal relationship (ANB,  $P < .001$ ). In the treatment group, maxilla moved forward 1.73 mm ( $P < .001$ ), and mandibular sagittal growth was  $-2.98$  mm. In the control group, mandibular growth was 0.90 mm, and maxillary growth was 0.75 mm ([Table 3](#)). Lower face height showed a significant increase in study group ( $P < .001$ ), and palatal plane angle rotated upward 0.76 degrees. Regarding mandibular skeletal measurements, mandibular length (Co-Gn) increased 3.02 mm in the control group and 1.48 mm in the treatment group ( $P < .01$ ).

### Dentoalveolar changes

In the treatment group, overjet improved, increasing by an average of 7.27 mm ([Table 2](#)) and overbite decreased (0.91 mm). The maxillary incisors were tipped labially 1.26 mm ( $4.74^\circ$ ), and the mandibular incisors tipped lingually 1.31 mm ( $-4.70^\circ$ ). The decrease in overbite was found to be statistically significant in treatment group ( $P < .05$ ). The horizontal changes of maxillary central incisors were from 3.67 to 4.94 mm in the protraction group, which were greater than those of the untreated control group (3.89 to 4.01).

## DISCUSSION [Return to TOC](#)

This study demonstrated a significant response to maxillary protraction/expansion therapy, which affected many areas of the dentofacial complex. Skeletal changes were primarily a result of anterior movement of the maxilla and posterior rotation of the mandible. Ngan et al<sup>33</sup> showed a two-mm forward movement of point A after six months of protraction, which might have been related to the 4.2-mm forward movement of the maxillary incisor. Most other studies reported one to three mm of maxillary protraction.<sup>30,34,35</sup> In this study, the increase in SNA ( $P < .001$ ) and A-VR ( $P < .01$ ) measurements showed significant forward movement of the maxilla at the end of the treatment ([Table 2](#)).

Because of the unavailability of comparable Class III untreated subjects, most of the studies used Class I untreated samples as control group.<sup>9,22,36</sup> In this study, because of ethical reasons we did not use a Class III control group. A full coverage acrylic cap splint type expansion appliance was used in this study to prevent the occlusal interferences and to maximize the skeletal effects of maxillary protraction. According to Haas,<sup>29</sup> rapid palatal expansion produces a slight forward movement of point A and a slight downward and forward movement of the maxilla. McNamara<sup>26</sup> and Turley<sup>27</sup> reported that rapid maxillary expansion may also disrupt the maxillary sutural system and enhance the protraction effect of the face mask.

Significant changes in mandibular position also contributed to the Class III correction in this study. Downward and backward movement of the mandible was consistent with Ngan's findings related to maxillary protraction and face mask. Because the chin is the anchorage region in our protraction device, a force was applied directly to the mandible, and the mandible was displaced downward and backward during treatment, with an increase of mandibular plane angle. Because the only extraoral anchorage was the chin, most of the resisted force was directed to the mandible. These treatment effects have been described with reverse-pull headgears and chincups.<sup>35,37,38</sup>

Contrary to the findings of Bacetti et al,<sup>39</sup> a slight increase in Co-Gn was found in the treatment group. The counterclockwise rotation of the palatal plane noted by the previous authors<sup>24,39</sup> was not found in our study group. Contrary to the findings of reports that showed anterior rotation with protraction devices,<sup>24,39</sup> the palatal plane slightly rotated upwards in this study. Westwood et al<sup>40</sup> also showed no increase in the palatal plane angle.

Overjet was improved with maxillary incisor proclination and mandibular incisor retroclination. Maxillary incisor proclination may be due to the mesial dental movement of the upper dental arch by the effects of protraction elastics.

## CONCLUSIONS [Return to TOC](#)

- A modified maxillary protractor treatment was an effective treatment for correcting skeletal Class III malocclusion.
- Treatment induced a significant response of the craniofacial skeleton in terms of forward movement of the maxilla and backward movement of the mandible.
- Using a modified maxillary protraction appliance, the upper incisors were protruded, lower incisors were retruded, and a positive overjet was achieved in a very short period.
- Mandibular growth was redirected or displaced toward a more vertical pattern, with a slight opening of the mandibular plane angle.

## ACKNOWLEDGMENTS

We thank Professor Fikret Gürbüz (Ankara University, Department of Biostatistics and Genetics) who managed the statistical analysis of this study.

## REFERENCES [Return to TOC](#)

1. Campbell PM. The dilemma of Class III treatment. *Angle Orthod.* 1983; 53:175–191. [[PubMed Citation](#)]
2. Ellis EE, McNamara JA Jr. Components of adult Class III malocclusion. *Am J Oral Maxillofac Surg.* 1984; 42:295–305.
3. Guyer EC, Ellis EE, McNamara JA Jr, Behrents RG. Components of Class III malocclusion in juveniles and adolescents. *Angle Orthod.* 1986; 56:7–30. [[PubMed Citation](#)]
4. McNamara JA Jr, Brudon WL. *Orthodontic and Orthopedic Treatment in the Mixed Dentition.* Ann Arbor, Mich: Needham Press; 1993; 117–129; 283–295.
5. Sakamoto T. Effective timing for application of orthopedic force in skeletal Class III malocclusions. *Am J Orthod.* 1981; 85:341–350.
6. Delaire J. Maxillary development revisited: relevance to the orthopaedic treatment of Class III malocclusions. *Eur J Orthod.* 1997; 19:289–311. [[PubMed Citation](#)]
7. Potpeschnigg H. Eine Zahnrichtmaschine. *Deutsche Vierteljahres-Z Zahnheilk.* 1875; 15:34–36.
8. Irie M, Nakamura S. Orthopedic approach to severe skeletal Class III malocclusion. *Am J Orthod.* 1975; 67:377–392. [[PubMed Citation](#)]
9. Ishii H, Morita S, Takeuchi Y, Nakamura S. Treatment effect of combined maxillary protraction and chin cap appliance in severe skeletal Class III cases. *Am J Orthod Dentofacial Orthop.* 1987; 92:304–312. [[PubMed Citation](#)]
10. Gallagher RW, Miranda F, Buschang PH. Maxillary protraction: treatment and posttreatment effects. *Am J Orthod Dentofacial Orthop.* 1998; 113:612–619. [[PubMed Citation](#)]
11. Kambara T. Dentofacial changes produced by extraoral forward force in the *Macaca irus*. *Am J Orthod.* 1977; 71:249–276. [[PubMed Citation](#)]
12. Nanda R. Protraction of maxilla in rhesus monkeys by controlled extraoral forces. *Am J Orthod.* 1978; 74:121–131. [[PubMed Citation](#)]
13. Ngan P, Hägg U, Yiu C, Merwin D, Wei SHY. Soft tissue and dentoskeletal profile changes associated with maxillary expansion and protraction headgear treatment. *Am J Orthod Dentofacial Orthop.* 1996; 109:38–49. [[PubMed Citation](#)]
14. Macdonald KE, Kapust AJ, Turley PK. Cephalometric changes after the correction of Class III malocclusion with maxillary expansion/facemask therapy. *Am J Orthod Dentofacial Orthop.* 1999; 116:13–24. [[PubMed Citation](#)]
15. Nartallo-Turley PE, Turley PK. Cephalometric effects of combined palatal expansion and facemask therapy on Class III malocclusion. *Angle Orthod.* 1998; 68:217–224. [[PubMed Citation](#)]
16. Joondeph DR. Early orthodontic treatment. *Am J Orthod Dentofacial Orthop.* 1993; 104:99–200.
17. Campbell PM. The dilemma of Class III treatment. Early or late?. *Angle Orthod.* 1983; 53:175–191. [[PubMed Citation](#)]
18. Graber LW. Chin cup therapy for mandibular prognathism. *Am J Orthod.* 1977; 72:23–41. [[PubMed Citation](#)]
19. Ritucci R, Nanda R. The effect of chin cup therapy on the growth and development of the cranial base and midface. *Am J Orthod Dentofacial Orthop.* 1986; 90:475–483. [[PubMed Citation](#)]
20. Sugawara J, Asano T, Endo N, Mitani H. Long-term effects of chin cap therapy in skeletal profile in mandibular prognathism. *Am J Orthod Dentofacial Orthop.* 1990; 98:127–133. [[PubMed Citation](#)]
21. Cozzani G. Extraoral traction and Class III treatment. *Am J Orthod.* 1981; 80:638–650. [[PubMed Citation](#)]
22. Takada K, Petdachai S, Sakuda M. Changes in dentofacial morphology in skeletal Class III children treated by a modified maxillary protraction headgear and a chin cup: a longitudinal cephalometric appraisal. *Eur J Orthod.* 1993; 15:211–221. [[PubMed Citation](#)]
23. Sung SJ, Baik HS. Assessment of skeletal and dental changes by maxillary protraction. *Am J Orthod Dentofacial Orthop.* 1998; 114:492–502. [[PubMed Citation](#)]
24. Kapust AJ, Sinclair PM, Turley PK. Cephalometric effects of face mask/expansion therapy in class III children: a comparison of three age groups. *Am J Orthod Dentofacial Orthop.* 1998; 113:204–212. [[PubMed Citation](#)]
25. Merwin D, Ngan P, Hägg U, Yiu C, Wei SH. Timing for effective application of anteriorly directed orthopedic force to the maxilla. *Am J Orthod Dentofacial Orthop.* 1997; 112:292–

26. McNamara JA Jr. An orthopedic approach to the treatment of Class III malocclusion in young patients. *J Clin Orthod.* 1987; 21:598–608. [\[PubMed Citation\]](#)
27. Turley PK. Orthopedic correction of Class III malocclusion with palatal expansion and custom protraction headgear. *J Clin Orthod.* 1988; 23:314–325.
28. Proffit WR, Fields HW Jr. *Contemporary Orthodontics.* St Louis, Mo: CV Mosby; 1993.
29. Haas AJ. Palatal expansion: just the beginning of dentofacial orthopedics. *Am J Orthod.* 1970; 57:219–255. [\[PubMed Citation\]](#)
30. Nanda R. Biomechanical and clinical considerations of a modified protraction headgear. *Am J Orthod.* 1980; 78:125–139. [\[PubMed Citation\]](#)
31. Timms DJ. *Rapid Maxillary Expansion.* Chicago, Ill: Quintessence Publishing Co; 1981.
32. Spolyar JL. The design, fabrication and use of full-coverage bonded rapid maxillary expansion appliance. *Am J Orthod.* 1984; 86:136–145. [\[PubMed Citation\]](#)
33. Ngan P, Wei SH, Hägg U, Yiu C, Merwin D, Stickel B. Effect of protraction headgear on Class III malocclusion. *Quintessence Int.* 1992; 23:3197–207. [\[PubMed Citation\]](#)
34. Mermigos J, Full CA, Andreasen G. Protraction of the maxillofacial complex. *Am J Orthod Dentofacial Orthop.* 1990; 98:47–55. [\[PubMed Citation\]](#)
35. Wendell PD, Nanda R, Sakamoto T, Nakamura S. The effects of chin cup therapy on the mandible: a longitudinal study. *Am J Orthod.* 1985; 87:265–274. [\[PubMed Citation\]](#)
36. Wisth PJ, Tritrapunt A, Rygh P, Boe OE. The effect of maxillary protraction on front occlusion and facial morphology. *Acta Odontol Scand.* 1987; 45:227–237. [\[PubMed Citation\]](#)
37. Mitani H, Sakamoto T. Chin cup forces to a growing mandible. Long term clinical reports. *Angle Orthod.* 1984; 54:93–122. [\[PubMed Citation\]](#)
38. Sakamoto T, Iwase I, Uka A, Nakamura SA. A roentgenocephalometric study of skeletal changes during and after chin cup treatment. *Am J Orthod.* 1984; 85:341–350. [\[PubMed Citation\]](#)
39. Bacetti T, McGill JS, Franchi L, McNamara JA Jr, Tollaro I. Skeletal effects of early treatment of Class III malocclusion with maxillary expansion and face-mask therapy. *Am J Orthod Dentofacial Orthop.* 1998; 113:333–343. [\[PubMed Citation\]](#)
40. Westwood PV, McNamara JA Jr, Bacetti T, Franchi L, Sarver DM. Long-term effects of Class III treatment with rapid maxillary expansion and facemask therapy followed by fixed appliances. *Am J Orthod Dentofacial Orthop.* 2003; 123:306–320. [\[PubMed Citation\]](#)

---

**TABLES** [Return to TOC](#)

**TABLE 1.** Age Distribution of the Treatment and Control Group

	Treatment group (n = 25)		Control group (n = 20)	
	$\bar{x} \pm S_{\bar{x}}$		$\bar{x} \pm S_{\bar{x}}$	
Chronological age	11.74	1.81	11.89	1.08
Skeletal age	11.59	2.10	12.07	1.69
Duration of treatment/control	0.65	0.30	1.09	0.09

**TABLE 2.** Changes in Cephalometric Measurements Treated With a Modified Maxillary Protractor: Before Treatment (T1) and Posttreatment (T2)

Measurement	Before Treatment		Posttreatment		Difference		P Value
	mean ± standard error of mean (SEM)	standard error of mean (SEM)	mean ± standard error of mean (SEM)	standard error of mean (SEM)	D ± SD		
SNA	78.45	3.43	79.90	4.09	1.45	1.34	***
SNB	81.77	3.78	80.09	3.74	-1.68	1.18	***
ANB	-3.32	2.14	-0.18	2.09	3.13	1.61	***
SN/GoGn	32.56	4.39	34.84	4.43	2.28	1.74	***
SN/OP	19.89	4.19	17.14	5.27	-2.75	3.32	***
SN/PP	9.73	2.98	8.97	2.50	-0.76	1.51	*
A-VR	50.67	7.58	52.41	7.88	1.73	1.48	***
A-HR	59.26	4.69	60.02	5.07	0.76	1.42	*
B-VR	47.50	12.50	44.50	11.74	-2.98	2.54	***
B-HR	97.19	7.07	100.38	7.19	3.19	3.12	***
PNS-VR	8.46	6.03	8.24	6.35	-0.22	1.51	NS <sup>a</sup>
PNS-HR	45.88	2.85	46.95	2.96	1.07	0.94	***
ANS-VR	57.15	7.70	58.76	7.78	1.60	1.83	***
ANS-HR	55.46	4.80	56.18	5.18	0.72	1.62	*
ANS-Me	63.06	7.04	67.20	7.08	4.14	2.18	***
Co-A	82.55	4.36	85.42	4.87	2.86	2.30	***
Co-Gn	114.56	6.34	116.04	7.00	1.48	2.31	**
U1/L1	136.87	9.63	133.71	8.58	-3.17	5.64	**
U1/NA	24.75	6.91	29.49	6.94	4.74	5.45	***
L1/NB	21.69	6.37	16.99	7.21	-4.70	3.82	***
Overjet	-4.03	2.08	3.24	1.96	7.27	2.16	***
Overbite	2.83	2.72	1.92	2.01	-0.91	1.96	*
U1i-NA	3.67	1.87	4.94	2.05	1.26	1.63	***
L1i-NB	3.27	2.13	1.95	2.67	-1.31	1.24	***

<sup>a</sup> NS indicates not significant.

\*  $P < .05$ .

\*\*  $P < .01$ .

\*\*\*  $P < .001$ .

**TABLE 3.** Changes in Cephalometric Measurements in Control Group: Before Control (T1) and After Control (T2)

Measurement	Before Control		After Control		Difference		P Value
	mean ± standard error of mean (SEM)	mean ± standard error of mean (SEM)	mean ± standard error of mean (SEM)	mean ± standard error of mean (SEM)	D ± SD		
SNA	79.57	3.70	80.01	3.70	0.45	1.28	NS <sup>a</sup>
SNB	77.80	3.77	78.43	4.03	0.63	1.33	*
ANB	1.77	1.52	1.58	1.63	-0.19	0.71	NS
SN/GoGn	33.74	4.77	32.72	4.77	-1.01	2.00	*
SN/OP	19.56	3.73	18.66	3.35	-0.89	2.12	NS
SN/PP	10.60	2.65	10.40	3.36	-0.21	1.56	NS
A-VR	53.20	6.49	53.95	6.55	0.75	0.94	**
A-HR	60.22	5.26	61.40	5.45	1.18	1.70	**
B-VR	43.24	10.90	44.14	11.42	0.90	1.81	*
B-HR	97.08	7.21	99.98	7.54	2.90	2.40	***
PNS-VR	8.45	5.03	8.43	5.37	-0.02	1.14	NS
PNS-HR	46.06	4.01	47.09	3.93	1.03	0.79	***
ANS-VR	59.02	6.23	60.28	6.21	1.26	0.83	***
ANS-HR	55.48	4.93	56.78	5.08	1.29	1.72	**
ANS-Me	64.02	5.36	66.03	5.70	2.00	1.47	***
Co-A	88.23	3.79	89.47	4.50	1.25	2.04	*
Co-Gn	113.16	6.71	116.18	7.37	3.02	1.77	***
U1/L1	127.87	8.33	129.43	8.48	1.56	3.72	NS
U1/NA	23.72	4.42	22.97	3.97	-0.75	3.09	NS
L1/NB	26.63	6.20	26.01	6.07	-0.62	2.26	NS
Overjet	2.10	0.69	2.01	0.84	-0.09	0.81	NS
Overbite	2.86	1.02	2.63	1.17	-0.23	1.13	NS
U1i-NA	3.89	1.30	4.01	1.38	0.12	0.92	NS
L1i-NB	4.38	2.05	4.44	2.24	0.66	0.53	NS

<sup>a</sup> NS indicates not significant.

\*  $P < .05$ .

\*\*  $P < .01$ .

\*\*\*  $P < .001$ .

**TABLE 4.** Means, Standard Deviations, and Results of the t-test Between Posttreatment Changes in the Experimental Group (n = 25) and in the Control Group (n = 20)

Measurement	Experimental		Control		P
	Mean ± SD	Mean ± SD	Mean ± SD	Mean ± SD	
SNA	1.45	1.35	0.45	1.28	**
SNB	-1.68	1.18	0.63	1.33	***
ANB	3.13	1.61	-0.19	0.70	***
SN/GoGn	2.28	1.74	-1.01	2.00	***
SN/OP	-2.75	3.32	-0.89	2.13	*
SN/PP	-0.76	1.51	-0.21	1.56	NS <sup>a</sup>
A-VR	1.73	1.48	0.75	0.95	**
A-HR	0.76	1.42	1.18	1.71	NS
B-VR	-2.98	2.54	0.90	1.81	***
B-HR	3.19	3.13	2.90	2.38	NS
PNS-VR	-0.22	1.52	-0.02	1.14	NS
PNS-HR	1.07	0.94	1.03	0.79	NS
ANS-VR	1.60	1.83	1.26	0.84	NS
ANS-HR	0.72	1.62	1.29	1.72	NS
N-Me	4.08	2.29	2.97	2.51	NS
Co-A	2.86	2.30	1.25	2.04	*
Co-Gn	1.48	2.31	3.02	1.77	*
U1/L1	-3.17	5.64	1.57	3.72	**
U1/NA	4.74	5.45	-0.75	3.09	***
L1/NB	-4.70	3.82	-0.62	2.26	***
Overjet	7.27	2.16	-0.09	0.81	***
Overbite	-0.91	1.96	-0.23	1.13	NS
U1i-NA	1.26	1.63	0.12	0.92	**
L1i-NB	-1.31	1.24	0.07	0.53	***

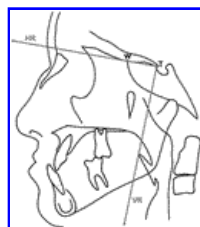<sup>a</sup> NS indicates not significant.

\*  $P < .05$ .

\*\*  $P < .01$ .

\*\*\*  $P < .001$ .

#### FIGURES [Return to TOC](#)



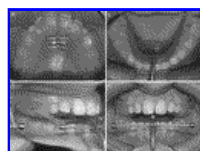
[Click on thumbnail for full-sized image.](#)

**FIGURE 1.** Reference planes used in the study. (T) The most superior point of the anterior wall of sella turcica at the junction with tuberculum sellae. (W) The point where the middle cranial fossa is intersected by the sphenoid bone



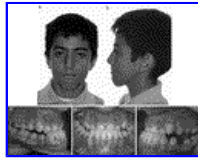
[Click on thumbnail for full-sized image.](#)

**FIGURE 2.** (a-c) Extraoral views of mini maxillary protractor used in the study



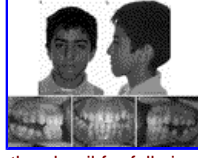[Click on thumbnail for full-sized image.](#)

**FIGURE 3.** (a-d) Intraoral views of mini maxillary protractor used in the study



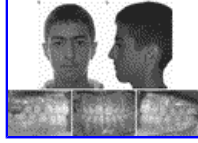
Click on thumbnail for full-sized image.

**FIGURE 4.** (a–e) Pretreatment photographs of a case treated by mini maxillary protractor used in the study



Click on thumbnail for full-sized image.

**FIGURE 5.** (a–e) Photographs of the case after protraction



Click on thumbnail for full-sized image.

**FIGURE 6.** (a–e) Photographs of the case after edgewise therapy

<sup>a</sup>Professor, Department of Orthodontics, Ankara University, Ankara, Turkey

<sup>b</sup>Research Assistant, Department of Orthodontics, Ankara University, Ankara, Turkey

Corresponding author: Dr. Aysegul Dalkiran Arslan, Ankara Universitesi, Dis Hekimligi Fakultesi Ortodonti Anabilim Dalı, 06500, Besevler, Ankara, Turkey (E-mail: [ayseguldalkiran@hotmail.com](mailto:ayseguldalkiran@hotmail.com))