

[\[Print Version\]](#)  
[\[PubMed Citation\]](#) [\[Related Articles in PubMed\]](#)

## TABLE OF CONTENTS

[\[INTRODUCTION\]](#) [\[MATERIALS AMD...\]](#) [\[RESULTS\]](#) [\[DISCUSSION\]](#) [\[CONCLUSIONS\]](#) [\[REFERENCES\]](#) [\[TABLES\]](#) [\[FIGURES\]](#)

*The Angle Orthodontist*: Vol. 76, No. 3, pp. 388–393.

# Validity of Panoramic Radiographs for Measuring Mandibular Asymmetry

Panagiotis Kambylafkas;<sup>a</sup> Edward Murdock;<sup>b</sup> Edward Gilda;<sup>c</sup> Ross H. Tallents;<sup>d</sup> Stephanos Kyrkanides<sup>e</sup>

## ABSTRACT

The objective of this study is to evaluate the accuracy of panoramic radiographs for diagnosing vertical asymmetry of the posterior mandible. The first part of the study used a model to evaluate the reproducibility of this particular panoramic machine. The tube traverse did not significantly affect the linear measurements, but the side of the machine where the structure was located produced an average of 2.1% variation in the total height of the mandible. In the second part of the study, the left-right (%) differences were measured on the panoramics and the laminographs of five skulls with lead markers. These differences were compared with the percent difference measured directly on the skull and with each other and suggested that the laminograph could be used as the "gold standard" for measuring posterior vertical mandibular asymmetry. The third part of the study evaluated a patient sample (N = 42). The correlation coefficient between the two types of films was determined to be 0.92 for total height and 0.39 for condyle height. Using the 6% cutoff reported in the literature, the sensitivity of the panoramics to diagnose asymmetry for the total height was determined to be 0.62 and the specificity 1.0. This study suggests that the panoramic radiograph can be used to evaluate vertical posterior mandibular asymmetry, but there will be some underdiagnosis.

**KEY WORDS:** Mandibular asymmetry, Panoramic, Laminograph, TMJ.

Accepted: May 2005. Submitted: February 2005

## INTRODUCTION [Return to TOC](#)

Internal derangements of the temporomandibular joint (TMJ) and degenerative joint disease (DJD) have been suggested to contribute to altered skeletal morphology. A shortening of the ramus, steep mandibular plane angle, and cranial base involvement have all been reported to be associated with disk displacement, DJD, and rheumatoid arthritis.<sup>1-3</sup> Vertical asymmetries may be observed in the mandible as well as the cranial base.<sup>4-6</sup> Many studies have reported a relationship between mandibular asymmetry and internal derangement.<sup>6-11</sup>

Various radiological modalities have been evaluated for imaging of the TMJ and skeletal structures. Panoramic radiography has been suggested for measurement of side-to-side height differences.<sup>12-15</sup> If joints are differentially affected, an asymmetry may develop. A few studies have used measurements of condylar and total height to define side-to-side differences.<sup>16,17</sup>

Panoramic radiography is relatively accessible and provides a bilateral view of the mandible, and vertical measurements can be

constructed.<sup>18</sup> The question is whether panoramic radiographs can be used to describe side-to-side differences in condyle and ramus height. Support for this has come from a series of reports on the panoramic technique.<sup>17,19,20</sup> These reports suggested that panoramic radiographs yield acceptable results, are noninvasive, have a favorable cost-benefit relationship, and expose subjects to relatively low doses of radiation. The shortcomings include distortion and magnification of the mandibular ramus and the condyle. The lateral margin of the glenoid fossa and the root of the zygomatic arch may mask the condyle.


Measurements on panoramic radiographs have been called into question because of considerable methodological errors.<sup>21</sup> The panoramic image is affected by both magnification errors and displacement, leading to distortion.<sup>22</sup> The technique is quite sensitive to positioning errors because of a relatively narrow image layer, particularly in the anterior region.<sup>23,24</sup> Images of structures within the sharply depicted plane are free of distortion. Structures outside this plane will appear distorted in the image because of the difference between the velocity of the film and the velocity of the projection of the object on the film. Ramstad et al<sup>25</sup> felt that quantitative measurements on panoramic radiographs should be abandoned.


Still, others feel that standardized positioning of the head and the use of a bite block reduce most of these distortions.<sup>17,20</sup> Horizontal measurements have been shown to be particularly unreliable because of the nonlinear variation in the magnification at different object depths, whereas vertical measurements are relatively reliable.<sup>22,26</sup> Therefore, most authors suggest that the reproducibility of vertical and angular measurements is acceptable provided the patient's head is positioned properly in the equipment.<sup>24,27</sup> Kjellberg et al<sup>28</sup> used panoramic radiography to evaluate condylar destruction on both sides in a juvenile chronic arthritis and postnormal patients (Class II division 2). They developed a reliable method to measure and quantify condyle lesions.

The purpose of this study was (1) to evaluate the accuracy of our panoramic machine for detecting differences between right and left sides on a Plexiglas model of the mandible (phantom), (2) to evaluate the ability of panoramic and laminagraphic radiographs in detecting the asymmetry on a sample of dry skulls where direct measurement could be made, and (3) using the laminagraphs as "gold standard" to evaluate asymmetries on a temporomandibular disorder (TMD) patient sample and, using the 6% cutoff reported in the literature, to test the sensitivity and specificity of the panoramic in detecting asymmetry.

## MATERIALS AND METHODS [Return to TOC](#)

### Part 1: Plexiglas phantom


A phantom was constructed of 8-mm thick Plexiglas and was used to simulate selected anatomical features in one-half of the human mandible using average measurements obtained from a sample of adult skulls. Various anatomic structures were marked with 1-mm-diameter stainless steel ball bearings. The model suitably positioned was capable of representing a right or left side of the mandible. The phantom was set up in the panoramic machine using a custom positioner that was representative of an average mandibular position ([Figure 1](#) ) .

Two series of films were taken using the Orthopantomograph OP100 (Instrumentation Corp. Imaging Division, Tuusula, Finland). One series used the phantom as the right half of the mandible and the other series as the left half of the mandible ([Figure 2](#) ) . Five trials were performed on different days and two exposures for the right and left positions with the tube traveling from left to right and then with the tube traveling from right to left.

Measurements of the condyle height and the total ramal height on the phantom were compared with the measurements on the radiographs. These data were analyzed with a two-tailed *t*-test.

### Part 2: Skulls

Craniometrical assessment was carried out on five skulls that were subjectively observed as demonstrating asymmetry. Measurements of the condyle and ramus areas on the different size and shape skulls were performed using a caliper. Lead markers were attached to the skulls on anatomic points representing: (1) Cd (the highest point of the condyle), (2) Go (anthropometric gonion), and (3) Sg (the deepest point of the sigmoid notch) to assure easy identification of these points on the radiographs. The skulls were placed in both the panoramic machine (using a custom-made positioner) and laminagraphic (Quint Sectograph) (linear) tomogram machine (using the ear rods). They were positioned using the guidelines for patients specified by the manufacturers. The films were exposed using machine settings determined by the investigators to obtain good quality radiographs of the dry skulls.

Measurements of the total and the condylar height were performed directly on the skulls and the radiographs ([Figure 3](#) ) . Asymmetry between right (R) and left (L) vertical measurements was then calculated with the formula:

$$\% \text{ difference} = (R - L)/(R + L)/2 \times 100\%$$

for each radiograph.

These data were subjected to statistical analysis using a multiple regression.

This determined the validity of the panoramic radiograph for performing linear measurements and detecting asymmetries on different sizes and shapes of skulls. It also evaluated the laminagraphs as the potential gold standard in the patient study.

### Part 3: Patient sample

This part of the study compared panoramic radiographs with full-profile laminagraphs in 42 TMD patients.

The panoramic radiograph and full-profile laminagraphs were traced and digitized (Houston Instruments Hi Pad Digitizer, England). The center cut laminagraph was selected for measurement. The following lines and points were identified ([Figure 3](#)): (1) a line tangent to the most prominent points of the inferior border mandible, (2) a tangent along the posterior margin of the ascending ramus, and (3) a line perpendicular to the posterior margin tangent extending to the most superior outline of the condyle. Total ramal and condylar heights were identified in similar manner on the laminagraphs and the panoramic radiographs as shown in the [Figure 3](#). The mean, standard deviation, and percent difference for (1) total height and (2) condylar height were calculated to evaluate side-to-side differences.

Determination of operator error in interpretation, tracing, and measurement of the patient radiographs was performed by evaluating the differences in measurements on five tracings of five radiographs of each type (panoramic and laminagraph). These were then subjected to a multiple regression analysis to determine an "intraclass correlation estimate." The intraclass correlation analysis revealed values of  $R$  to be 0.94 and 0.95 for the measurement of the total ramal height on the panoramics and the laminagraphs, respectively. The intraclass correlation for the condyle height measurement was very low (0.52 for the panoramic and 0.52 for the laminagraph).

## RESULTS [Return to TOC](#)

### Part 1: Plexiglas phantom

The traverse of the machine was tested using the phantom. Two series of films were performed, one using the phantom as the right half and one as the left half of the mandible. When the model was positioned on the left side, the mean condylar height measurement and the mean total height measurement was measured for the L-R and the R-L traverse. Paired  $t$ -test (two-tailed) suggested that these differences were not significant ( $P > .05$ ). The same was found when the model was positioned in the right side as the paired  $t$ -test (two-tailed) for analysis. These differences were not significant ( $P > .05$ ).

However, when the R-L and L-R traverses were pooled together and the means of the condylar and the total height for the right side vs the left were subjected to the paired  $t$ -test (two-tailed) for statistical analysis, the differences were significant ( $P < .05$ ). The clinically significant difference for total height was found to be a 2.1% difference between the two sides.

### Part 2: Skulls

The multiple regression analysis for the five skulls demonstrated high correlation between the measurements on the skulls and the radiographs, which was always more than 0.95 ([Table 1](#)). The regression for the comparison of the actual measurements on the skulls with those on the laminagraphs was 0.99 and supported the use of the laminagraphs as the gold standard in the patient study.

### Part 3: Patient sample

The asymmetry measured on the panoramic radiograph and that measured on the laminagraphs taken from the patients had a correlation of 0.92 for total height and 0.39 for condyle height ([Table 2](#)). The mean disagreement (the mean of the difference percent of measured asymmetry) between the panoramic and the laminagraph for the total height asymmetry was 2.23% and for condyle height was 11.9%. There was never more than 6% disagreement for total height between the panoramic radiograph and laminagraphic measurements.

Using the laminagraph as the gold standard and a 6% cutoff<sup>17</sup> as an indication of potential asymmetry, a 2 × 2 table was constructed ([Table 3](#)) to evaluate the sensitivity and specificity of the two tests. The sensitivity and specificity of the diagnostic tests were 0.62 and 1.0, respectively. Therefore, a panoramic radiograph will not overestimate the asymmetry in this patient population if we use 6% as our cutoff for true asymmetry. There were no false-positive examinations with the panoramic radiograph.

## DISCUSSION [Return to TOC](#)

The purpose of this study was to evaluate the potential of panoramic radiographs to determine vertical asymmetry between the right and left side in the mandible. Measurements of the total height on the phantom were compared with the measurements on the radiographs. The consistency of the measurements for those structures was determined comparing the different tube traverses and the phantom placed on the left vs the right side. This produced good reproducibility for the panoramic machine for repeated positioning and exposures with different

tube travel. The tube travel appeared to be negligible on this machine. However, the side that the phantom was positioned was not negligible. There was a 1.45-mm difference between right and left side for total height, which was calculated to be a 2.1% difference between the two sides. Thus, it appears that there is an average inherent error in the machine of 2.1% for total height.

The skull specimens allowed a direct measure of the object being radiographed. The most accurate method to measure the skulls is to use lead markers because they can easily be identified on the radiographs. The panoramic and the laminograph were both good, but the laminograph was better when compared with the actual specimen (skull), and the correlation coefficient was equal ( $R = 0.99$ ) for total height and condylar height. The validity of the laminographs as the gold standard was investigated. The results of the skull portion support the laminograph as the radiographic gold standard because we cannot compare the panoramic with the actual subject in live patients.

Measurements from the panoramic films were compared with the laminographic films for the worst-case scenario for potential error in the measurements. The inherent error in the machine and operator error must be considered. Both intra- and interoperator error may be present in positioning and exposing the radiographs, as well as intraoperator error in the tracing and the measurements.

In the patient part of the study, there was a very low correlation between panoramic and laminograph radiographs for the condyle height asymmetry ( $R = 0.39$ ), suggesting that the panoramic radiograph should be questioned for this measurement. This is probably because of the small dimension of the measurement and operator error in tracing and identification of landmarks. This agrees with the findings of Turp et al,<sup>29</sup> who evaluated condyle height and found the correlation to be very low when using Bezuur's 6% cutoff for asymmetry. The total height measurement was more encouraging with  $R = 0.92$ . This supports the use of the panoramic radiograph for evaluation of total ramal height asymmetry.<sup>20</sup>

In the patient sample, the mean disagreement between the panoramics and the laminographs for total height was 2.23% and compares well with the first part of the study that found the inherent machine error of 2.1%. However, it cannot be deduced that these two numbers represent the same error. The maximum disagreement for the total ramal height was 5.38%, similar to the 6% cutoff that Habets et al<sup>20</sup> calculated as reasonable for the panoramic radiograph.

In investigating morphologic effects of temporomandibular dysfunction, Habets et al<sup>17,20</sup> and Bezuur et al<sup>19</sup> found that vertical differences between the left and right sides were less than 6% if positions were altered less than 10 mm from their original centered position (using an experimental model resembling a human mandible). They concluded that observed condylar asymmetry within a 6% difference might, therefore, be because of technical failures. They also reported that a significant difference between controls and patients treated for craniomandibular disorders was found in condylar height symmetry. We decided from previous observations in this study that the use of a 6% cutoff proposed by Bezuur et al<sup>19</sup> was acceptable for comparing right with left differences.

The panoramic radiograph was found to have a sensitivity of 0.62 (high false negative) in detecting asymmetry in patients after the 6% cutoff factor and using the laminographs as the gold standard. This would indicate that when using 6% as a cutoff for asymmetry, the panoramic radiograph would underdiagnose asymmetry compared with the laminographic radiograph. The specificity of the panoramic radiograph was 1.0 (no false positive). This meant that none of the panoramic radiographs indicated greater than 6% asymmetry if the laminograph radiographs indicated less than 6% asymmetry. Therefore, when using the panoramic radiograph to detect mandibular total ramal height differences, one can confidently state that there is a true asymmetry if indicated on the panoramic using the 6% cutoff. If one accepts the laminograph radiographs as the gold standard, the panoramic radiograph is reasonable for detecting asymmetries of total ramal height.

## CONCLUSIONS [Return to TOC](#)

- Condylar height was unreliable when determining asymmetry from the panoramic radiograph.
- Total ramal height could be used in determining asymmetry from the panoramic radiograph, but it must be realized that it would generally underdiagnose asymmetry.
- Some patients with a less than 6% difference between the left and right sides might not be diagnosed with panoramic radiograph.

## REFERENCES [Return to TOC](#)

1. Gidarakou IK, Tallents RH, Stein S, Kyrkanides S, Moss ME. Comparison of skeletal and dental morphology in asymptomatic volunteers and symptomatic patients with unilateral displacement with reduction. *Angle Orthod.* 2004; 74:212–219. [[PubMed Citation](#)]
2. Gidarakou IK, Tallents RH, Stein S, Kyrkanides S, Moss ME. Comparison of skeletal and dental morphology in asymptomatic volunteers and symptomatic patients with unilateral displacement without reduction. *Angle Orthod.* 2003; 73:121–127. [[PubMed Citation](#)]

3. Gidarakou IK, Tallents RH, Stein S, Kyrkanides S, Moss ME. Comparison of skeletal and dental morphology in asymptomatic volunteers and symptomatic patients with bilateral degenerative joint disease. *Angle Orthod.* 2003; 73:71–78. [[PubMed Citation](#)]
4. Bezuur JN, Habets LL, Hansson TL. The recognition of craniomandibular disorders; condylar symmetry in relation to myogenous and arthrogenous origin of pain. *J Oral Rehabil.* 1989; 16:257–260. [[PubMed Citation](#)]
5. Qadan S, Macher DJ, Tallents RH, Kyrkanides S, Moss ME. The effect of surgically induced anterior disc displacement of the temporomandibular joint on the midface and cranial base. *Clin Orthod Res.* 1999; 2:124–132. [[PubMed Citation](#)]
6. Hatala MP, Macher DJ, Tallents RH, Spoon M, Subtelny JD, Kyrkanides S. Effect of a surgically created disk displacement on mandibular symmetry in the growing rabbit. *Oral Surg Oral Med Oral Pathol Oral Radiol Endod.* 1996; 82:625–633. [[PubMed Citation](#)]
7. Tallents RH, Guay JA, Katzberg RW, Murphy W, Proskin H. Angular and linear comparisons with unilateral mandibular asymmetry. *J Craniomandib Disord.* 1991; 5:135–142. [[PubMed Citation](#)]
8. Schellhas KP, Piper MA, Omlie MR. Facial skeleton remodeling due to temporomandibular joint degeneration: an imaging study of 100 patients. *Am J Neuroradiol.* 1990; 11:541–551. [[PubMed Citation](#)]
9. Schellhas KP. Unstable occlusion and temporomandibular joint disease. *J Clin Orthod.* 1989; 23:332–337. [[PubMed Citation](#)]
10. Schellhas KP, Keck RJ. Disorders of skeletal occlusion and temporomandibular joint disease. *Northwest Dent.* 1989; 68:35–39, 42.
11. Trpkova B, Major P, Nebbe B, Prasad N. Craniofacial asymmetry and temporomandibular joint internal derangement in female adolescents: A posteroanterior cephalometric study. *Angle Orthod.* 2000; 70:81–88. [[PubMed Citation](#)]
12. Larheim TA. Comparison between three radiographic techniques for examination of the temporomandibular joints in juvenile rheumatoid arthritis. *Acta Radiol Diagn (Stockholm).* 1981;22:195–201.
13. Larheim TA, Hoyeraal HM, Stabrun AE, Haanaes HR. The temporomandibular joint in juvenile rheumatoid arthritis. Radiographic changes related to clinical and laboratory parameters in 100 children. *Scand J Rheumatol.* 1982; 11:5–12. [[PubMed Citation](#)]
14. Ronning O, Valiaho ML. Involvement of the facial skeleton in juvenile rheumatoid arthritis. *Ann Radiol (Paris).* 1975;18: 347–353.
15. Ronning O, Valiaho ML. Progress of mandibular condyle lesions in juvenile rheumatoid arthritis. *Proc Finn Dent Soc.* 1981; 77:151–157.
16. Athanasiou AE, Melsen B, Mavreas D, Kimmel FP. Stomatognathic function of patients who seek orthognathic surgery to correct dentofacial deformities. *Int J Adult Orthod Orthognath Surg.* 1989; 4:239–254. [[PubMed Citation](#)]
17. Habets LL, Bezuur JN, Naeiji M, Hansson TL. The Orthopantomogram, an aid in diagnosis of temporomandibular joint problems. II. The vertical symmetry. *J Oral Rehabil.* 1988; 15:465–471. [[PubMed Citation](#)]
18. Wabeke KB, Spruijt RJ, Habets LL. Spatial and morphologic aspects of temporomandibular joints with sounds. *J Oral Rehabil.* 1995; 22:21–27. [[PubMed Citation](#)]
19. Bezuur JN, Habets LL, Hansson TL. The recognition of craniomandibular disorders; condylar symmetry in relation to myogenous and arthrogenous origin of pain. *J Oral Rehabil.* 1989; 16:257–260. [[PubMed Citation](#)]
20. Habets LL, Bezuur JN, van Ooij CP, Hansson TL. The orthopantomogram, an aid in diagnosis of temporomandibular joint problems. I. The factor of vertical magnification. *J Oral Rehabil.* 1987; 14:475–480. [[PubMed Citation](#)]
21. Larheim TA, Johannessen S, Tveito L. Abnormalities of the temporomandibular joint in adults with rheumatic disease. A comparison of panoramic, transcranial and transpharyngeal radiography with tomography. *Dentomaxillofac Radiol.* 1988; 17:109–113. [[PubMed Citation](#)]
22. Tronje G, Welander U, McDavid WD, Morris CR. Image distortion in rotational panoramic radiography. IV. Object morphology; outer contours. *Acta Radiol Diagn (Stockholm).* 1981;22:689–696.
23. Welander U. A mathematical model of narrow beam rotation methods. *Acta Radiol Diagn (Stockholm).* 1974;15:305– 317.
24. Larheim TA, Svanaes DB. Reproducibility of rotational panoramic radiography: mandibular linear dimensions and angles. *Am J Orthod Dentofacial Orthop.* 1986; 90:45–51. [[PubMed Citation](#)]
25. Ramstad T, Hensten-Pettersen O, Mohn E, Ibrahim SI. A methodological study of errors in vertical measurements of edentulous ridge height on orthopantomographic radiograms. *J Oral Rehabil.* 1978; 5:403–412. [[PubMed Citation](#)]
26. Ericsson S, Lundberg M. Alterations in the temporomandibular joint at various stages of rheumatoid arthritis. *Acta Rheumatol Scand.*



27. Larheim TA, Svanaes DB, Johannessen S. Reproducibility of radiographs with the Orthopantomograph 5: Tooth length assessment. *Oral Surg Oral Med Oral Pathol.* 1984; 58:736–741. [[PubMed Citation](#)]

28. Kjellberg H, Ekestubbe A, Kiliaridis S, Thilander B. Condylar height on panoramic radiographs. A methodologic study with a clinical application. *Acta Odontol Scand.* 1994; 52:43–50. [[PubMed Citation](#)]

29. Turp JC, Vach W, Strub JR, Harbich K, Alt KW. The recognition of mandibular asymmetries in the panoramic tomogram. An example of the need for judging the value of a diagnostic procedure. *Schweiz Monatsschr Zahnmed.* 1995; 105:755–759. [[PubMed Citation](#)]

**TABLES** [Return to TOC](#)

**TABLE 1.** Multiple Regression Analysis Comparing Actual vs Ra diographic Measurements on the Phantom. All the Correlation Estimates Were Significant ( $P < .05$ )

		<i>R</i>
Panorex—actual	Total height	0.95
	Condylar height	0.95
Laminagraph—actual	Total height	0.99
	Condylar height	0.99
Panoramic—laminagraph	Total height	0.95
	Condylar height	0.97


**TABLE 2.** Multiple Regression Analysis Comparing Panorex With Laminagraphic Measurements in the Patient Sample

	Laminagraph Difference (Yes)	Laminagraph Difference (No)
Panoramic difference (Yes)	8	0
Panoramic difference (No)	5	29

**TABLE 3.** In the Patient Sample: Using the Laminagraph as the Gold Standard and the 6% Cutoff the Sensitivity and Specificity of the Two Diagnostic Tests Were 0.62 and 1.0, Respectively

Panorex vs Laminagraph	Total Height	Condylar Height
<i>R</i>	0.92	0.39

**FIGURES** [Return to TOC](#)



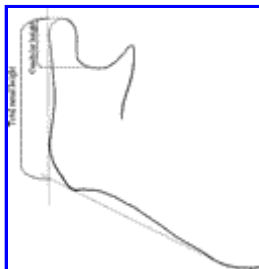
Click on thumbnail for full-sized image.

**FIGURE 1.** The phantom was set up in the panoramic machine using a custom positioner that was representative of an average mandibular position in the machine



Click on thumbnail for full-sized image.

**FIGURE 2.** Two films taken on the panoramic machine, one using the phantom as the right and the other as the left half of the mandible



Click on thumbnail for full-sized image.

**FIGURE 3.** The panoramic and laminographic films were traced, and the lines shown were used to measure the condylar and the total ramal height

<sup>a</sup>Resident, Department of Dentistry, Division of Orthodontics, University of Rochester School of Medicine and Dentistry, Rochester, NY

<sup>b</sup>Resident, Department of Dentistry, Division of Orthodontics, University of Rochester School of Medicine and Dentistry, Rochester, NY

<sup>c</sup>Professor Emeritus, Division of Orthodontics and TMD, Department of Dentistry, University of Rochester School of Medicine and Dentistry, Rochester, NY

<sup>d</sup>Professor, Department of Dentistry, Division of Orthodontics and Prosthodontics, Program Director Temporomandibular Joint Disorders, University of Rochester School of Medicine and Dentistry, Rochester, NY

<sup>e</sup>Associate Professor, Departments of Dentistry and Neurobiology and Chairman of Division of Orthodontics and TMJD, Craniofacial Research Core Coordinator, University of Rochester School of Medicine and Dentistry, Rochester, NY

Corresponding author: Dr. Ross Tallents, Eastman Dental Center, Orthodontics and TMJD, 625 Elmwood Avenue, Eastman Dental Center, Rochester, NY 14620 (E-mail: [ross\\_tallents@urmc.rochester.edu](mailto:ross_tallents@urmc.rochester.edu))