

[\[Print Version\]](#)

[\[PubMed Citation\]](#) [\[Related Articles in PubMed\]](#)

## TABLE OF CONTENTS

[\[INTRODUCTION\]](#) [\[CASE REPORT\]](#) [\[DISCUSSION\]](#) [\[CONCLUSIONS\]](#) [\[REFERENCES\]](#) [\[FIGURES\]](#)

*The Angle Orthodontist: Vol. 76, No. 3, pp. 510-518.*

# Severe Crowding and a Dilacerated Maxillary Central Incisor in an Adolescent

Eiji Tanaka;<sup>a</sup> Takuro Hasegawa;<sup>b</sup> Koichi Hanaoka;<sup>c</sup> Kiyoshi Yoneno;<sup>c</sup> Eka Matsumoto;<sup>b</sup> Diego Dalla-Bona;<sup>b</sup> Eizo Yamano;<sup>b</sup> Yohei Suekawa;<sup>b</sup> Mineo Watanabe;<sup>d</sup> Kazuo Tanne<sup>e</sup>

## ABSTRACT

This study reports the treatment of an adolescent patient with dilacerated maxillary incisor. She complained of severe crowding with a high-positioned left upper canine. Her left central incisor had been impacted and moved to proper position at the age of eight years, resulting in a severe root dilaceration. To avoid any progression of root dilacerations and resorption in the maxillary incisor, maxillary lateral expansion and molar distalization plus multibracket appliance were selected as the best nonextraction treatment plan. The maxillary expansion and molar distalization should provide adequate space for the correction of the severe crowding, and treatment with a multibracket appliance was initiated. After a 17-month treatment with a multibracket appliance, an acceptable occlusion was achieved with a Class I molar relationship. An acceptable occlusion was maintained without recurrence of the crowding and impairment of the dilacerated root in the maxillary incisor during three years of retention. It is emphasized that careful planning is required to avoid any progression of the root dilaceration and resorption through orthodontic treatment. A shortening of the period of applying orthodontic force on the dilacerated incisor and avoidance of tooth extraction will minimize the risk factors.

**KEY WORDS:** Tooth impaction, Dilacerated root, Orthodontic treatment.

Accepted: June 2005. Submitted: April 2005

## INTRODUCTION [Return to TOC](#)




Tooth impaction is present in 1% to 2% of orthodontic patients,<sup>1</sup> and the maxillary canine impacts most frequently.<sup>2</sup> According to the review by Bishara,<sup>3</sup> the causes of tooth impaction are divided into generalized and localized factors. The most common causes are localized and include lack of space for eruption, prolonged retention or early loss of the deciduous tooth, abnormal position of the tooth bud, the presence of alveolar cleft, ankylosis, cystic or neoplastic formation, alveolar or dental trauma, and dilaceration of the root.<sup>3</sup> Although impaction of the permanent maxillary incisor occurs less frequently than that of the maxillary canine,<sup>4</sup> impacted incisors have many serious problems in terms of esthetic and occlusal aspects in the early mixed dentition.



Several reports have indicated that an impacted tooth can be brought to proper alignment in the dental arch.<sup>5-8</sup> The success rate of an impacted dilacerated tooth depends on the degree of dilaceration, stage of root formation and position of the tooth.<sup>6</sup> Successful treatment



of an impacted maxillary incisor with severe dilacerations is quite rare. In addition, orthodontists often hesitate to align an impacted incisor with a severely dilacerated root because there are chances of failure due to ankylosis, external root resorption, and root exposure after orthodontic tooth movement.<sup>6</sup>


The purpose of this study is to present the treatment of a patient with severe crowding, a dilacerated maxillary incisor and to monitor the dilacerated root radiographically through the orthodontic treatment.

## CASE REPORT [Return to TOC](#)

The patient was an 11-years one-month-old female who had a bimaxillary protrusion and severe crowding with a Class II molar relationship ([Figure 1](#) ). She complained of severe crowding of the anterior teeth with a high-positioned left upper canine. Her facial profile was convex with lip protrusion, and no facial asymmetry was observed ([Figure 1](#) ). Overjet and overbite were 3.4 and 2.6 mm, respectively. The maxillary dentition exhibited a narrow and asymmetric dental arch and the mandibular dentition exhibited a narrow, V-shaped dental arch. Her only periodontal problem was a localized gingivitis on the left maxillary incisors ([Figure 1](#) ).

Although there was no apparent history of facial and dental trauma, the left maxillary central incisor had been impacted horizontally and traction of the impacted central incisor was conducted at the age of eight years ([Figure 2A](#) ). After surgical exposure with an apically positioned flap, an attachment was bonded to the lingual surface of the impacted tooth, and a week after surgical exposure, orthodontic traction was initiated. An additional auxiliary spring was soldered to the base arch, and an elastic chain with a traction force of 60 g or less was applied between the attachment and the auxiliary spring. The impacted incisor was properly positioned in six months. At this point, the periapical radiograph showed a severe dilacerated root in the central incisor ([Figure 2B](#) ).



From the model analysis, basal and coronal arch widths of the upper and lower dentitions were below the normal range of Japanese females. The maxillary midline was shifted to the left by 3.4 mm, whereas the mandibular midline was almost coincident to the facial one. An arch length discrepancy of -8.1 and -1.6 mm was present in the upper and lower arches, respectively. Panoramic and periapical radiographs revealed a severe dilacerated root in the left maxillary central incisor. The right maxillary central and left maxillary lateral incisors also showed mild root dilacerations ([Figures 3](#)  and [4A](#) ). The tooth mobility of the left maxillary central incisor was not severe, but the crown easily deviated within one mm in labiolingual direction.

Analysis of the lateral cephalometric radiograph revealed a normal skeletal pattern according to Japanese standards<sup>9</sup> ([Figure 5](#) ). However, the maxillary and mandibular incisors were tipped more facially than the Japanese standards.


From these findings, this case was diagnosed as a severe crowding with dilacerated maxillary incisors. Because of the severity of the root dilaceration, careful planning was required. A shortening of the period of applying orthodontic force on the dilacerated incisors and avoidance of tooth extraction were indicated. The treatment plan developed for this case was as follows.

1. Maxillary lateral expansion by use of a quad helix to gain adequate space for tooth alignment.
2. Distal movement of the maxillary first molars by use of a cervical headgear to obtain Class I molar relationships.
3. After making adequate space, multibracket appliances were placed on both dentitions for tooth alignment.
4. Retention by use of lingual-bonded retainers on both dentitions and a wrap around-type retainer on the upper arch.

### Treatment progress

A quad helix was applied to the upper arch for lateral expansion. Four months after initiating the lateral expansion, cervical headgear was placed on the upper arch, and distal movement of the maxillary first molars was initiated. By activating the quad helix and headgear, adequate space for tooth alignment was obtained, and the molar relationships were changed to Class I on both sides ([Figure 6A](#) ). The periapical radiograph showed no change of the dilacerated root of the left maxillary central incisor during initial treatment ([Figure 4B](#) ).

When the patient was 12 years and one month old, a 0.018 × 0.025-inch slot standard wire appliance was placed on both the upper and lower dentitions except for the maxillary incisors. The initial leveling was performed with a 0.016-inch Ni-Ti wire. After the leveling, a plain stiff 0.016 × 0.022-inch wire was placed on the lower arch. Simultaneously, a segmental 0.016 × 0.022-inch stainless steel arch wire was applied in the upper molar regions. On the upper arch, the premolars and canines were retracted with labial elastics. The quad helix on the upper arch was replaced with a transpalatal arch.

Fifteen months after initiating orthodontic treatment with conventional fixed appliance, the scattered spaces were gathered about the anterior region and the maxillary midline, which had been shifted to the left by 3.4 mm at the initial stage, almost matched the facial one without the aid of orthodontic force application ([Figure 6B](#) ).

At this point, brackets were placed on the maxillary incisors. The leveling on the upper anterior teeth was conducted with a 0.016-inch Ni-Ti wire (Figure 6C). An orthodontic force was applied to the maxillary incisors for only two months to avoid any progression of root resorption that might be induced by orthodontic force. After 29 months of orthodontic treatment, an acceptable and stable occlusion was achieved and the multibracket appliances were removed. Immediately after appliance removal, a wrap around-type retainer was placed on the upper dentition, and lingually bonded retainers were placed on both upper and lower dentitions.

## Treatment results

Facial photographs showed that overall facial balance was improved (Figure 7). The lip protrusion was slightly improved. An acceptable occlusion was achieved, and the overjet and overbite were improved to 2.2 and 1.9 mm, respectively (Figure 7). The molar relationships were changed to Class I on both sides. From the model analysis, basal and coronal arch widths of both arches were within the normal range. The local gingivitis on the left maxillary incisors disappeared. With respect to the tooth mobility of the left maxillary central incisor, the degree of mobility did not change compared with that at the initial stage.

Panoramic and periapical radiographs showed no or little progression of the root dilaceration and resorption on the maxillary incisors (Figures 4C and 8). This implied that no damage or little damage occurred at the roots because of orthodontic force application. Cephalometric analysis indicated a normal growth of the maxilla and mandible during orthodontic treatment (Figure 5). The labiolingual inclination of the maxillary central incisors was within the normal range although the lower central incisors were still inclined labially beyond the normal range of Japanese standards.

Three years after retention, an acceptable occlusion was maintained without recurrence of the anterior crowding, indicating a long-term stability of the occlusion (Figure 9). A periapical radiograph revealed no change of the root dilaceration on the left maxillary central incisor (Figure 4D), resulting in long-term stability of this tooth.

## DISCUSSION [Return to TOC](#)

The major treatment procedure for an impacted tooth is orthodontic traction after proper crown exposure surgery. There are actually some failures of the traction because of ankylosis and external root resorption. Furthermore, even successful cases probably end with an irregular root formation or an unesthetic gingival margin of the incisor (or both) after orthodontic treatment.

In our clinic, we determine whether an impacted tooth can be successfully aligned in proper position on the basis of the position and direction of the impacted tooth, the amount of root formation, and the degree of root dilacerations. Furthermore, an impacted tooth is likely to have a dilacerated root, which becomes worse with time.<sup>7</sup> Therefore, when treating patients with tooth impaction, it is of great importance to diagnose and plan when and how the impacted tooth is moved to its proper position, resulting in elimination of the possibility of progressive root dilacerations.

Although the cause of root dilaceration is still not clear, studies have documented several possible causative agents and events.<sup>5,6,10,11</sup> Smith and Winter<sup>11</sup> found that traumatic injury of the deciduous incisors can lead to dilacerations of the permanent incisors. Kolokithas and Kawakasis<sup>10</sup> showed that trauma to the deciduous incisor causes a change in the axial inclination of the unerupted tooth.

However, the present case had no apparent history concerning dental and alveolar trauma. Therefore, the possible causes inducing a dilacerated root in the present case may be an ectopic development and abnormal position of the tooth bud. Stewart<sup>12</sup> studied 41 cases of dilacerations and reported that only 22% of the patients had a history of trauma and also proposed that root dilacerations were more likely caused by ectopic development of the tooth germ.

The fact is that orthodontic tooth movement directly causes an irreversible resorption of the root. The most severely resorbed teeth because of orthodontic tooth movement are the maxillary lateral incisors, followed by the maxillary central incisors.<sup>13</sup> Furthermore, dilacerated teeth have the most resorption, followed by bottle-shaped and pointed teeth.<sup>13,14</sup> Kjaer<sup>15</sup> also found a high incidence of dysmorphic roots in patients with severe root resorption. From these findings, maxillary central incisors with a severely dilacerated root as shown in this study are likely to have significant root resorption from orthodontic forces.

With respect to the treatment factors causing root resorption, Sameshima and Sinclair<sup>16</sup> indicated that maxillary central incisors had significantly more resorption than nonextraction cases in first premolar extraction cases. Furthermore, they found a significant correlation between the duration of treatment and the amount of apical root resorption for maxillary central incisors and suggested that the reason for extended treatment may itself shed some light on this association.

In this study, therefore, maxillary lateral expansion and molar distalization were performed to gain adequate space for tooth alignment. As the result, the present case could be treated as a nonextraction case. Considering the large discrepancies in both arches, premolar or incisor extraction may be considered a treatment alternative, but we could not decide to treat this patient as an extraction case because of the risk of impairment of dilacerated roots. Furthermore, after making adequate space for improvement of anterior crowding, we placed brackets on the maxillary incisors and applied orthodontic force to the maxillary incisors only for two months. Such careful treatment

planning resulted in no progression of the root dilaceration and resorption on the maxillary incisors throughout the treatment period because of the decreased period with complete maxillary fixed appliances in place.

## CONCLUSIONS [Return to TOC](#)

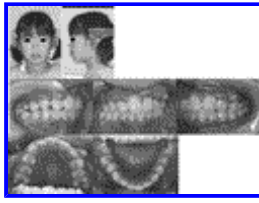
A crowded case with a severely dilacerated incisor is among the most complicated problems encountered. Therefore, careful planning is required to avoid any progression of root dilaceration and resorption. This requires a shortening of the period of applying orthodontic force on the dilacerated incisor and avoidance of tooth extraction.

## REFERENCES [Return to TOC](#)

1. Johnston W. Treatment of palatally impacted canine teeth. *Am J Orthod.* 1969; 56:589–596. [[PubMed Citation](#)]
2. McDonald F, Yap WL. The surgical exposure and application of direct traction of unerupted teeth. *Am J Orthod.* 1986; 89:331–340. [[PubMed Citation](#)]
3. Bishara SE. Impacted maxillary canines: a review. *Am J Orthod Dentofacial Orthop.* 1992; 101:159–171. [[PubMed Citation](#)]
4. Kamat SS, Kumar GS, Raghunath V, Rekha KP. Permanent maxillary central incisor impaction: report of two cases. *Quintessence Int.* 2003; 34:50–52. [[PubMed Citation](#)]
5. Wasserstein A, Tzur B, Brezniak N. Incomplete canine transposition and maxillary central incisor impaction: a case report. *Am J Orthod Dentofacial Orthop.* 1997; 111:635–639. [[PubMed Citation](#)]
6. Y-TJ Lin. Treatment of an impacted dilacerated maxillary central incisor. *Am J Orthod Dentofacial Orthop.* 1999; 115:406–409. [[PubMed Citation](#)]
7. Tanaka E, Watanabe M, Nagaoka K, Yamaguchi K, Tanne K. Orthodontic traction of an impacted maxillary central incisor. *J Clin Orthod.* 2001; 35:375–378. [[PubMed Citation](#)]
8. Uematsu S, Uematsu T, Furusawa K, Deguchi T, Kurihara S. Orthodontic treatment of an impacted dilacerated maxillary central incisor combined with surgical exposure and apicoectomy. *Angle Orthod.* 2004; 74:132–136. [[PubMed Citation](#)]
9. Wada K, Otani S, Sakuda M. Morphometric analysis in maxillary protrusion [in Japanese]. In: Yamauchi K, Sakuda M. eds. *Maxillary Protrusion*. Tokyo, Japan: Ishiyaku; 1989:95– 130.
10. Kolokithas G, Kawakasis D. Orthodontic movement of dilacerated maxillary central incisor. *Am J Orthod.* 1979; 76:310–315. [[PubMed Citation](#)]
11. Smith DMH, Winter GB. Root dilaceration of maxillary incisors. *Br Dent J.* 1981; 150:125–127. [[PubMed Citation](#)]
12. Stewart DJ. Dilacerate unerupted maxillary central incisors. *Br Dent J.* 1978; 145:229–233. [[PubMed Citation](#)]
13. Sameshima GT, Sinclair PM. Predicting and preventing root resorption: part I. Diagnostic factors. *Am J Orthod Dentofacial Orthop.* 2001; 119:505–510. [[PubMed Citation](#)]
14. Mirabella AD, Årtun J. Risk factors for apical root resorption of maxillary anterior teeth in adult orthodontic patients. *Am J Orthod Dentofacial Orthop.* 1995; 108:48–55. [[PubMed Citation](#)]
15. Kjaer I. Morphological characteristics of dentitions developing excessive root resorption during orthodontic treatment. *Eur J Orthod.* 1995; 16:25–34.
16. Sameshima GT, Sinclair PM. Predicting and preventing root resorption: part II. Treatment factors. *Am J Orthod Dentofacial Orthop.* 2001; 119:511–515. [[PubMed Citation](#)]

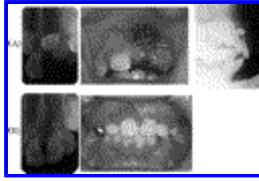
---

## FIGURES [Return to TOC](#)



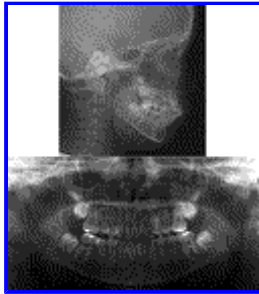
[Click on thumbnail for full-sized image.](#)

**FIGURE 1.** Facial and intraoral photographs before treatment (11 years one month old).



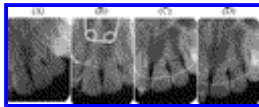
[Click on thumbnail for full-sized image.](#)

**FIGURE 2.** Periapical and occlusal radiographs before tooth traction and intraoral photograph at surgical procedure.




[Click on thumbnail for full-sized image.](#)

**FIGURE 3.** Cephalometric and panoramic radiographs before treatment (11 years one month old).



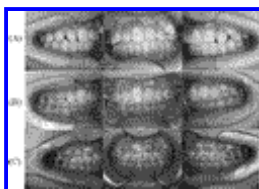
[Click on thumbnail for full-sized image.](#)

**FIGURE 4.** Periapical radiographs of maxillary incisors through orthodontic treatment.(A) Before treatment. (B) After lateral expansion. (C) Immediately after treatment. (D) Three year after retention



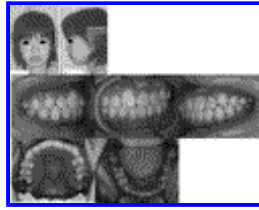
[Click on thumbnail for full-sized image.](#)

**FIGURE 5.** Superimposition of cephalometric tracings before (solid line) and after (dotted line) treatment.



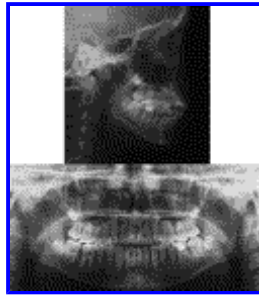
[Click on thumbnail for full-sized image.](#)

**FIGURE 6.** Intraoral photographs during treatment. (A) After maxillary lateral expansion and molar distalization. (B) Fifteen months after initiating orthodontic treatment with conventional fixed appliance. (C) Onset of leveling on the maxillary anterior teeth.



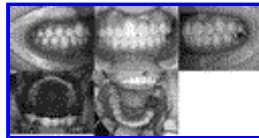[Click on thumbnail for full-sized image.](#)

**FIGURE 7.** Facial and intraoral photographs after treatment (13 years six months old).



[Click on thumbnail for full-sized image.](#)

**FIGURE 8.** Cephalometric and panoramic radiographs after treatment (13 years six months old).



[Click on thumbnail for full-sized image.](#)

**FIGURE 9.** Intraoral photographs three years after retention (16 years six months old)

<sup>a</sup>Associate Professor, Department of Orthodontics and Craniofacial Developmental Biology, Hiroshima University Graduate School of Biomedical Sciences, Hiroshima, Japan

<sup>b</sup>Graduate PhD Student, Department of Orthodontics and Craniofacial Developmental Biology, Hiroshima University Graduate School of Biomedical Sciences, Hiroshima, Japan

<sup>c</sup>Resident, Department of Orthodontics and Craniofacial Developmental Biology, Hiroshima University Graduate School of Biomedical Sciences, Hiroshima, Japan

<sup>d</sup>Assistant Professor, Department of Orthodontics and Craniofacial Developmental Biology, Hiroshima University Graduate School of Biomedical Sciences, Hiroshima, Japan

<sup>e</sup>Professor and Department Chair, Department of Orthodontics and Craniofacial Developmental Biology, Hiroshima University Graduate School of Biomedical Sciences, Hiroshima, Japan

Corresponding author: Dr. Eiji Tanaka, Department of Orthodontics and Craniofacial Developmental Biology, Hiroshima University Graduate School of Biomedical Sciences, 1-2-3 Kasumi, Minami-ku, Hiroshima 734-8553, Japan (E-mail: [etanaka@hiroshima-u.ac.jp](mailto:etanaka@hiroshima-u.ac.jp))

