

[\[Print Version\]](#)
[\[PubMed Citation\]](#) [\[Related Articles in PubMed\]](#)

TABLE OF CONTENTS

[\[INTRODUCTION\]](#) [\[MATERIALS AND...\]](#) [\[RESULTS\]](#) [\[DISCUSSION\]](#) [\[CONCLUSIONS\]](#) [\[REFERENCES\]](#) [\[TABLES\]](#) [\[FIGURES\]](#)

The Angle Orthodontist: Vol. 75, No. 5, pp. 730-735.

The Relation between the Point of Force Application and Flaring of the Anterior Segment

E. van Steenberghe;^a C. J. Burstone;^b B. Prah-Andersen;^c I. H. A. Aartman^d

ABSTRACT

The purpose of this study was to determine whether application of an intrusive force by an intrusion arch at the distal wings of the lateral incisor brackets causes a change in the axial inclination of the anterior segment. Intrusion of the maxillary anterior segment caused a statistically significant mean increase in axial inclination of the anterior segment. Correlations were investigated and found not statistically significant. The correlation between the (1) distance from the point of force application to the center of resistance at the start of intrusion and the change in axial inclination, (2) distance from the point of force application to the center of resistance at the start of intrusion and the change in distance from the incisal edge to the distal side of the first molar, (3) distance from the point of intrusive force application to the center of resistance at the start of intrusion and the change in this distance between start and end of intrusion, and (4) distance from the point of intrusive force application to the center of resistance at the start of intrusion and the change in axial inclination.

KEY WORDS: Biomechanics, Incisor intrusion.

Accepted: December 2004. Submitted: November 2004

INTRODUCTION [Return to TOC](#)

This study focused on correction of deep overbite by intrusion of maxillary central and lateral incisors and evaluated various options to decrease side effects and to increase efficiency with minimal dependence on patient compliance. Previous studies have focused on intrusion.³⁻⁵

One investigation was performed to compare different methods of deep overbite correction.⁴ Other reports on intrusion were based on in vitro or laboratory studies^{1,6,7} and animal studies.⁸⁻¹⁰ Because intrusion is often a necessary part of orthodontic treatment, a randomized clinical trial focusing on all aspects related to intrusion is needed as a scientific basis for clinical study and to increase treatment efficiency. This part of the study evaluated the influence of the location of the point of force application on the axial inclination of the maxillary anterior segment.

The location of the point of force application in relation to the center of resistance of the anterior segment can alter the axial inclination of that segment. A more anterior location of the point of force application causes a more uprighting of the anterior teeth.^{1,2,6,7,11} Studies on dry skulls have determined that the center of resistance for a segment of four maxillary incisors with a normal axial inclination lies apical of a point between the distal side of the lateral incisor.² Therefore, if an intrusion arch is attached at that point, the anterior segment, the incisors will move bodily in an apical direction. When the axial inclination of the incisors is different, so is the location of the center of resistance. More flared incisors should have a more distal point of force application through the center of resistance than retroclined incisors.⁷

The purpose of this study was to determine whether, in patients with a normal axial inclination (within 2 SD) of the anterior segment, application of an intrusive force at the distal wings of the lateral incisor brackets causes a change in axial inclination of that segment while it is being intruded. In this study, the following null hypotheses were tested.

Application of an intrusive force by tying the intrusion arch at the distal wings of the lateral incisor brackets onto the anterior segment causes no change in axial inclination of that segment while it is being intruded.

There is no correlation between the distance from the point of force application to the center of resistance of the maxillary anterior segment at the start of intrusion and the change in axial inclination of the anterior segment.

There is no correlation between the distance from the point of force application to the center of resistance of the maxillary anterior segment at the start of intrusion and the change in distance from the incisal edge to the distal side of the first molar.

There is no correlation between the distance from the point of force application to the center of resistance of the maxillary anterior segment at the start of intrusion and at the end of intrusion.

There is no correlation between the distance from the point of force application to the center of resistance of the maxillary anterior segment at the start of intrusion and the change in this distance between the start and end of intrusion.

There is no correlation between the amount of intrusion and the change in axial inclination of the anterior segment.

MATERIALS AND METHODS [Return to TOC](#)

Sample

Orthodontic patients needing maxillary central and lateral incisor intrusion of at least two mm were recruited for this study from all patients referred to the principal investigator's practice. Treatment was performed by D. van't Hof-Grootenboer.





Patients included in the sample had at least maxillary first molars, first and second premolars, canines, and all maxillary incisors present and fully erupted and were between nine and 14 years of age. Patients with extruded maxillary incisors were excluded as well as patients with periodontal disease. Patients with crowding to the extent that they needed extractions to perform alignment were also excluded. No other form of orthodontic treatment was allowed. All patients willing to participate in this study were included in the sample if they met the above-mentioned requirements. During a four-year period, 40 patients were recruited.

Records

A lateral cephalometric radiograph, one set of impressions with a wax bite in centric occlusion, and intraoral photographs were taken of each patient at the start of intrusion and when intrusion of the four maxillary incisors was completed (Department of Orthodontics, University Hospital, Committee of the University Hospital, Amsterdam, The Netherlands). The lateral cephalograms were taken with the aid of a cephalostat by the principal investigator. The patient's head position in the cephalostat was documented by a nasal rest, so that pre- and postintrusion cephalograms were taken with the patient's head in the same position. To distinguish the patient's right and left side, a ligature wire was tied around the right canine bracket in situ on the cephalogram. Impressions were poured in plaster and trimmed in centric occlusion.

Measurements


Lateral cephalograms were traced on a computer screen and on acetate paper.¹² From each set of lateral cephalograms, a maxillary superimposition (structural) was made.¹³ The tracings were digitized and analysed with a computer program (Quick Ceph Systems, San Diego, Calif). The following measurements were performed.


1. Vertical movement of the center of resistance of the maxillary central incisor (indicating the amount of intrusion) axial means perpendicular to the palatal plane (Figure 1 , measurement 1). The center of resistance of the anterior segment because of its easier and therefore more reliable and reproducible location. Because of the rigidity of the anterior segment, the displacement of the center of resistance of the anterior segment.
2. Axial inclination of the anterior segment in the sagittal plane, which was determined by measuring the angle between the central incisor and the palatal plane (Figure 1 , measurement 2).
3. Distance from the point of intrusive force application to the center of resistance of the central incisor. The greater this distance, the greater the chance of incisor flaring (Figure 2 , measurement 1).
4. Distance from the incisal edge to the distal side of the maxillary first molar (Figure 3 , measurement 1). This measurement in the sagittal plane indicates the amount of flaring of the maxillary incisor in combination with the amount of intrusion.

To make the measurement error as small as possible, the digital image was enlarged to the extent that the crosshair symbol used for landmark identification was much smaller than the enlarged landmark itself. The digital images of these tracings and of the cephalograms directly, and trace both. To make the superimpositions more reliable, it was decided to make structural superimpositions on maxillary skeletal structures, which has a clear advantage over the computer superimposition because the complete outlines of the skeletal structures are used and not just a few digitized points. This method was checked independently by reanalyzing the start and end of intrusion. Differences between both measurements varied from 0.01° for the angular measurement between the central incisor and the palatal plane and 0.01 mm between the distance from the auxiliary tube to the point of intrusive force application and the distance from the incisal edge to the maxillary first molar. None of the differences were statistically significant.

Treatment protocol


Patients were recruited after an explanation of the treatment plan by the orthodontist. First, bands and brackets were placed and segments aligned. Alignment was performed on segments, the anterior segment extended from canine to first molar.


When the wire segments were rigid and passive, one lateral cephalogram, five intraoral photographs (one frontal, two buccal, and two occlusal photographs), and one set of impressions with a wax bite in centric occlusion were taken. When the segments were passive, they were left in place for five weeks after insertion before records were taken and intrusion was started. At the same visit the intrusion arch was placed (Figure 4 )


Visits were scheduled every five weeks. During each visit, the intrusive force was measured, recorded, and, when necessary, adjusted to the proper level. When the incisors were intruded to the proper level, the intrusion arch was removed, the impressions, and wax bite were taken (Figure 5 )


To test the null hypotheses (see Introduction), Pearson's product moment correlation coefficients (r ; two-tailed) were calculated.^{15,16}


RESULTS [Return to TOC](#)


Table 1  demonstrates that the maxillary central incisor flared a mean of 8.74°, which was statistically significant ($P < .001$). Null hypothesis one was therefore rejected.

There was no statistically significant correlation between the distance from the point of force application to the center of resistance of the incisor at the moment when the intrusion was started and the change in axial inclination of the incisor (Table 2 )


The correlation between the distance from the point of force application to the center of resistance of the maxillary anterior segment at the start of intrusion and the change in distance from the incisal edge to the first molar was statistically significant (Table 2 )

The correlation between the distance from the point of force application to the center of resistance at the start and at the end of intrusion was not statistically significant (Table 2 )

The correlation between the distance from the point of force application to the center of resistance of the central incisor at the start of intrusion and the change in this distance between start and end of intrusion was not statistically significant (Table 2 )

There was no statistically significant correlation between the amount of intrusion and the change in axial inclination of the central incisor (Table 2 )

DISCUSSION [Return to TOC](#)

According to the studies on dry skulls, the center of resistance for a segment of four maxillary incisors with a normal axial inclination lies apical of a point between the distal side of the canine⁶ and the distal side of the lateral incisor. The most distal point of force application is at the distal side of the lateral incisor bracket, which is approximately three mm anterior to the distal side of the lateral incisor. This study evaluated the clinical application. The mean axial inclination of the central incisor increased a statistically significant 8.74° (Table 1 )

On the basis of this finding, it would be logical to assume that the larger the distance from the point of force application to the center of resistance at the start of intrusion, the larger would be the change in axial inclination of the incisor. An increase in axial inclination would increase the distance between the point of force application and the center of resistance.^{1,2}

The second hypothesis described the correlations between the distance from the point of force application to the center of resistance of the maxillary incisor and the change in axial inclination. The third hypothesis described the correlations between the distance from the point of force application to the center of resistance of the maxillary incisor and the distance from incisal edge to first molar. In case the incisor was flared, this distance would increase. The fourth hypothesis described the correlations between the distance from the point of force application to the center of resistance of the maxillary incisor and the distance from the point of force application to the center of resistance at the end of intrusion. The fifth hypothesis described the correlations between the distance from the point of force application to the center of resistance of the maxillary incisor and the change in distance from the point of force application to the center of resistance between start and end of intrusion.

In this study, none of the correlations, as tested for the second through the fifth hypothesis, were statistically significant. The most likely explanation for finding no statistically significant differences within the sample of intrusion was normal. The differences in distance between the point of force application and the center of resistance were therefore small within the sample and caused no statistically significant differences in axial inclination.

Each patient included in this study needed a minimum of two mm intrusion of the maxillary anterior segment. This was determined from the initial records. The decision to stop intruding the maxillary incisors was made when the overbite decreases.^{1,2,4} The amount of intrusion in this study is defined by the vertical movement in cranial direction of the center of resistance of the maxillary central incisor. On the basis of the assumption that the amount of intrusion can be related to a decrease in vertical movement of the center of resistance, the correlation between the amount of incisor intrusion and the change in incisor axial inclination was measured and found not statistically significant.

In a clinical situation where maxillary incisor intrusion is desired and the incisor axial inclination can be increased, incisor intrusion can be performed with a one-piece intrusion arch with the point of force application at the distal side of the lateral incisor bracket. If an increase in axial inclination is not desired, the clinician should change the point of force application in the distal direction.

CONCLUSIONS [Return to TOC](#)

- Intrusion of the maxillary anterior segment by application of the intrusive force at the distal side of the lateral incisor bracket caused a statistically significant mean increase in axial inclination of the central incisor.
- There was no statistically significant correlation between the distance from the point of intrusive force application to the center of resistance at the start of intrusion and the change in axial inclination of the incisor.
- No statistically significant correlation was found between the distance from the point of intrusive force application to the center of resistance at the start of intrusion and the change in distance from the incisal edge to the first molar.
- There was no statistically significant correlation between the distance from the point of intrusive force application to the center of resistance at the start of intrusion and at the end of intrusion.
- No statistically significant correlation between the distance from the point of intrusive force application to the center of resistance at the start of intrusion and the change in this distance between start and end of intrusion.
- There was no statistically significant correlation between the amount of intrusion and the change in axial inclination.

REFERENCES [Return to TOC](#)

1. Burstone CJ. Deep overbite correction by intrusion. *Am J Orthod.* 1977; 72:1-22. [[PubMed Citation](#)]

2. Burstone CJ. Biomechanics of deep overbite correction. *Semin Orthod.* 2001; 7:126–33.

3. van Steenberghe E, Burstone CJ, Prah-Andersen B, Aartman IHA. The role of a high pull headgear in counteracting side effects from intrusion of the maxillary anterior segment. *Angle Orthod.* 2004; 74:480–486. [PubMed Citation]

4. Weiland FJ, Bantleon HP, Droschl H. Evaluation of continuous arch and segmented arch leveling techniques in adult patients—a clinical study. *Am J Orthod Dentofacial Orthop.* 1996; 110:6647–652. [PubMed Citation]

5. Melsen B, Agenbæk N, Markenstam G. Intrusion of incisors in adult patients with marginal bone loss. *Am J Orthod Dentofacial Orthop.* 1989; 96:3232–241. [PubMed Citation]

6. Vanden Bulcke M, Sachdeva R, Burstone CJ. The center of resistance of anterior teeth during intrusion using the laser reflection technique and holographic interferometry. *Am J Orthod.* 1986; 90:3211–219.

7. Dermaut LR, Vanden Bulcke MM. Evaluation of intrusive mechanics of the type “segmented arch” on a macerated human skull using the laser reflection technique and holographic interferometry. *Am J Orthod Dentofacial Orthop.* 1987; 91:321–327. [PubMed Citation]

8. Dellinger EL. A histological and cephalometric investigation of premolar intrusion in the macaca speciosa monkey. *Am J Orthod.* 1967; 53:325–355. [PubMed Citation]

9. Steigman S, Michaeli Y. Experimental intrusion of rat incisors with continuous loads of varying magnitude. *Am J Orthod.* 1981; 80:4429–436. [PubMed Citation]

10. Woods MG. The mechanics of lower incisor intrusion: experiments in nongrowing baboons. *Am J Orthod Dentofacial Orthop.* 1988; 93:3186–195. [PubMed Citation]

11. Burstone CJ, Pryputniewicz RJ. Holographic determination of centers of rotation produced by orthodontic forces. *Am J Orthod.* 1980; 77:396 [PubMed Citation]

12. Baumrind S, Frantz R. The reliability of headfilm measurements: 1 landmark identification. *Am J Orthod.* 1971; 60:111–127. [PubMed Citation]

13. Baumrind S. The reliability of headfilm measurements: 2 linear and angular measurements. *Am J Orthod.* 1971; 60:506–517.

14. Baumrind S, Miller D, Molthen R. The reliability of headfilm measurements: 3 tracing superimpositions. *Am J Orthod.* 1976; 70:6617–644. [PubMed Citation]

15. Faber R, Burstone CJ, Solonche DJ. System of computerized treatment planning. *Am J Orthod.* 1978; 73:136–46. [PubMed Citation]

16. Altman DG. *Practical Statistics for Medical Research.* London: Chapman & Hall; 1991:278–286.

17. Pocock SJ. *Clinical Trials, a Practical Approach.* Chichester, UK: Wiley & Sons; 1984:73–76.

TABLES [Return to TOC](#)

TABLE 1. Change in Axial Inclination of the Maxillary Central Incisor

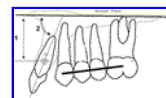
	Mean	SD
Incisor angulation at start (°)	71.03	6.09
Incisor angulation at end (°)	62.30	7.05
Incisor angulation change (°)	8.74	3.71

TABLE 2. Pearson's Product Moment Correlation Coefficients (*r*) With the Significance in Parentheses (two-tailed)^a

	D pF-Cr	D Mx1-PP	D Mx1-Mx6
pF-Cr	0.16 (0.31)	0.11 (0.49)	-0.15 (0.37)
Mx1-PP		0.03 (0.88)	
D Cr-PP		-0.20 (0.21)	

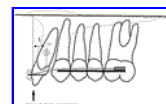
^a pF-Cr indicates distance from the point of force application to the center of resistance of maxillary central incisor; D pF-Cr, change in distance from the point of force application to the center of resistance of maxillary central incisor; Mx1-PP, angle between the central incisor and the palatal plane; D Mx1-PP, change in angle between the central incisor and the palatal plane; Cr-PP, distance from the center of resistance of the central incisor to the palatal plane; D Cr-PP, change in distance from the center of resistance of the central incisor to the palatal plane; Mx1-Mx6, distance from incisal edge to the distal side of the first molar; and D Mx1-Mx6, change in distance from incisal edge to the distal side of the first molar.

FIGURES [Return to TOC](#)



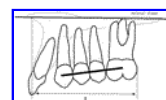
Click on thumbnail for full-sized image.

FIGURE 1. Incisor intrusion and axial inclination



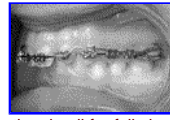
Click on thumbnail for full-sized image.

FIGURE 2. Distance between the point of force application to the center of resistance



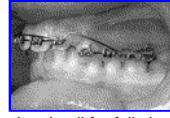Click on thumbnail for full-sized image.

FIGURE 3. Distance from incisal edge to first molar



Click on thumbnail for full-sized image.

FIGURE 4. Patient at the start of intrusion



Click on thumbnail for full-sized image.

FIGURE 5. Patient at the end of intrusion

^aPrivate Practice, Apeldoorn, The Netherlands

^bProfessor Emeritus, Department of Orthodontics, University of Connecticut Health Center, Farmington, Conn

^cProfessor and Chairperson, Orthodontic Department, Academic Centre for Dentistry, Amsterdam, The Netherlands

^dAssistant Professor, Methodologist, Department of Orthodontics and Social Dentistry, Section Social Dentistry and Dental Health Education, Academic Centre for Dentistry, Amsterdam

Corresponding author: E. van Steenberg, DDS, MDS, Orthodontiepraktijk Van Steenberg, Hofdwaarsstraat 1 c, 7311 KK Apeldoorn, The Netherlands (E-mail: ecbt@vansteenbergen.nl)