

[\[Print Version\]](#)
[\[PubMed Citation\]](#) [\[Related Articles in PubMed\]](#)

TABLE OF CONTENTS

[\[INTRODUCTION\]](#) [\[RAPID MOLAR...\]](#) [\[CLINICAL APPLICATION\]](#) [\[GROWING PATIENTS\]](#) [\[ADULT PATIENTS\]](#) [\[CONCLUSIONS\]](#) [\[REFERENCES\]](#) [\[TABLES\]](#) [\[FIGURES\]](#)

The Angle Orthodontist: Vol. 75, No. 5, pp. 736-746.

Treatment of Skeletal Open Bite with a Device for Rapid Molar Intrusion:

A Preliminary Report

Aldo Carano;^a Giuseppe Siciliani;^b S. Jay Bowman^c

ABSTRACT

An open bite is one of the most difficult malocclusions the clinician has to deal with. In recent years, interest has increased regarding mechanics that reduce dependency upon patient compliance for success. Some patient vertical control is desirable. The rapid molar intruder (RMI) appliance consists of two elastic modules that are secured to orthodontic bands on the upper and lower first molars. Vertical forces from these modules typically produce months. The RMI modules may be used in the mixed dentition or incorporated in full-fixed mechanics in the permanent dentition. To avoid buccal flaring of the molars, these modules should be attached to a transpalatal arch provided to stimulate interest in further investigation of the properties of this appliance.

KEY WORDS: Open bite, Rapid molar intrusion, Mechanics.

Accepted: August 2004. Submitted: June 2004

INTRODUCTION [Return to TOC](#)


An open bite is one of the most difficult malocclusions the clinician has to deal with. Several etiologies have been offered for the development of open bites.¹⁻³ In general, the dominant morphological features may include a backward (especially in the posterior segments), or hypereruption of posterior teeth (or all). In patients with long faces the length of the face often tends to elongate further with orthodontic treatment because there is less anchorage available than

The posterior maxilla is the primary area where vertical control should be directed^{4,5} because stable results are often seen with surgical superior repositioning of the posterior maxilla.⁶ In addition, if the molars are intruded, the same improved profile effects evidenced with the use of functional appliances. Schudy⁴ described the important role of excessive vertical growth in the development of sagittal discrepancies. Subsequently, mechanics have been described (headgears) and also to advance the mandible with functional appliances.^{7,8} Although patients treated with this combined approach have shown some impressive results, these methods require a very high level of unpredictable patient

More recently, repelling magnets have also been proposed for the correction of vertical skeletal problems.^{9,10} Three-dimensional control is difficult when using repelling magnets because the devices may deviate from centered control deviation and this can result in the development of a crossbite.¹¹ In addition, removable splint appliances leave the orthodontist totally dependent on patient compliance,¹² whereas bonded functional appliances present hygiene and patient compliance issue affects the successful application of a vertical chin cap.¹³

Consequently, there is a need to provide some modicum of posterior vertical control or molar intrusion that can be achieved independent of patient cooperation. The use of implants or screws as anchorage for molar intrusion may present and potential morbidity are of concern. Therefore, it is the objective of this communication to describe a new method of obtaining vertical control by molar intrusion without dependence upon patient compliance or a surgical procedure



RAPID MOLAR INTRUSION APPLIANCE DESIGN [Return to TOC](#)

The rapid molar intruder (RMI) appliance¹⁴ is composed of elastic modules that are attached to orthodontic bands luted to the maxillary and mandibular first molars. The terminal ends of each module are secured with L-shaped, arch tubes (eg, headgear) welded on orthodontic bands ([Figure 1](#) ). There are two different end-caps on each elastic module. The straight end-cap is attached to the maxillary tube and the angulated one is connected to the mandibular



When the patient occludes, the elastic modules are flexed to produce an intrusive force of 600-900 g to the molars on each side. As this force is applied at the buccal surface, a moment is produced that would produce adverse buccal transpalatal and a mandibular lingual arch should always support these modules. In addition, this appliance can be applied in either the mixed dentition or in conjunction with full fixed brackets in the permanent dentition.

CLINICAL APPLICATION [Return to TOC](#)

Chairside installation of the force modules can be challenging because visibility and access is limited at the back of the mouth. Therefore, it may be easier to attach the modules to the transpalatal arch and mandibular lingual arch. Subsequently, the entire system can be inserted as one unit. If an anterior open bite is present, a tongue crib or habit appliance may be incorporated into the design of the transpalatal arch. For patients who also exhibit a maxillary transpalatal arch modules can also be applied to a maxillary expansion device.

Construction of the intrusion appliance is accomplished by first placing one of the L-shaped ball pins into the hole of the angulated end of the elastic force module ([Figure 1](#) ). The pin is inserted through the convex side of the metal cap is then inserted into the mesial opening of the mandibular buccal tube, carrying the concave side of the metal cap to the buccal tube. The annealed portion of the ball pin that extends out beyond the buccal tube is bent gingivally. The contact only the apical margin of the orthodontic band, so as to avoid any gingival impingement ([Figure 1](#) ). In this arrangement, the pin and module are free to rotate occlusally, as the patient opens his or her mouth, providing a re

Next, another ball pin is placed through the hole in the flat end of the force module. This pin is then inserted into the mesial of the buccal tube on the maxillary first molar band. The ball end of the pin at the mesial of the tube is also




If the patient demonstrates a Class II or Class III tendency, the modules may be mounted differently. For example, if a Class II malocclusion is present, the maxillary end of the force module could be attached to the distal of the buccal tube much similar to the Jasper Jumper auxiliary from which the force modules were derived ([Figure 1B](#) ). When a Class III relationship is present, the mandibular end of the force module can be attached to the distal of the buccal tube on the maxilla ([Figure 1C](#) ).

GROWING PATIENTS [Return to TOC](#)

The RMI appliance would seem to be most applicable for "growing" patients who are exhibiting excessive vertical growth or anterior open bites. The RMI appliance appears to produce more intrusion of the maxillary molars compared to addition, this device diminishes vertical maxillary development and assists in closing the vertical dimension of the lower third of the face.

After the appliance is delivered, the patient is seen at four-week intervals. During intrusion of the permanent molars, deciduous molars may hypererupt and prevent bite closure. In these instances, serial extraction of the deciduous molars reduction because of the speed of the permanent molar intrusion. In cases where the second molars erupt before or during molar intrusion, they should be included in the intrusive mechanics by a sectional full-size rectangular wire or arch is included in the RMI appliance, it may remain after completion of intrusion to maintain arch length if extractions of the mandibular deciduous molars were performed. After five to seven months, the modules of the RMI are removed and

Case example 1

A 12-year-old female presented with chief complaints of a lack of contact between the upper and lower incisors and difficulty in closing her lips together ([Figure 2A-D](#) ). The patient exhibited a Class I transitional dentition malocclusion with posterior contraction ([Figure 2E](#) ). Cephalometric analysis revealed an obtuse mandibular plane angle, excessive vertical development of the maxilla and lower third of the face ([Table 1](#) .

Maxillary palatal expansion and interference with the tongue thrust habit was achieved using a palatal arch with a tongue crib. A mandibular lingual arch was simultaneously constructed and RMI modules were placed bilaterally.

After four months, the anterior open bite was reduced to zero mm (Figure 3A-C). The changes in the cephalometric measurements reveal moderate intrusion of the first molars and anterior rotation of the occlusal plane changed its orientation following the mandibular plane in its counterclockwise rotation. Because of the counter rotation of the occlusal plane, the Wits appraisal showed a decrease (Table 1). During this first and were included into the intrusive mechanics with a sectional full-size rectangular wire. The RMI was maintained for two more months for retention (Figure 4A-C), while bonded preadjusted brackets were placed on the remaining used in this case at any time during treatment.

The total treatment required 26 months followed by a maxillary Hawley and bonded mandibular lingual retainer (note that the data of the first cephalometric radiograph does not correspond with the beginning of treatment but in fact some lip incompetence despite the closure of the anterior open bite that was stable 21 months after the removal of the RMI appliance (26 months from the initial photos) (Figure 5A-E).

From the cephalometric data resulting from the control at 21 months after removal of the RMI (T3), it is evident that there was a certain amount of relapse of the skeletal correction achieved during molar intrusion (Figure 6A-D) upon a return to an excessive vertical pattern is a subject of future investigation and cannot be answered by the observation of a single case.

ADULT PATIENTS [Return to TOC](#)

The treatment with the RMI also may be indicated for some adult dental and skeletal open bites. Although adults exhibiting a "long face syndrome" often may be better treated with a surgical approach, the RMI gives an alternative treated better with RMI are skeletal open bites with Class I and Class II patterns, whereas open bite with a Class III malocclusion are less indicated.

For adult treatment, additional anchorage for the RMI appliance is recommended with transpalatal and lingual arches with bands on the first and second molars. In addition, an extension from the transpalatal and lingual arches from first to second molar bands could be added.

In severe skeletal open bites, the extractions of the maxillary second molars are often required (if the maxillary third molars are well formed and positioned for eruption). Otherwise, when present, erupted third molars are typically re-

Because treatment for adults will take longer, the modules of the RMI may need to be replaced because they tend to deform permanently with time, resulting in a decay of their force level. To facilitate the replacement RMI modules lingual arch and subsequently recement the reconstructed appliance. After some confidence using the appliance has been achieved, the placement and removal of the RMI modules can be directly done in the patient's mouth.

Case example 2

A 22-year-old female presented with the chief complaint of a lack of contact between the anterior teeth and a poor esthetic appearance of her smile (Figure 7A-C). The patient demonstrated a severe Class II malocclusion with Cephalometric analysis revealed an obtuse mandibular plane angle and excessive vertical development of the maxilla (Table 2).

Maxillary expansion was accomplished using a spring jet appliance.¹⁷ Initial leveling and alignment was achieved with a preadjusted appliance and a mandibular lingual arch. After four months, RMI modules were placed bilaterally

Molar intrusion and concurrent counterclockwise rotation of the mandible was achieved in about five months (Figure 8B). No use of vertical elastics was applied to this case at any time of treatment, and only a limited use of Class II malocclusion. Treatment was completed in a total of 19 months (Figure 9A-C). The occlusion and skeletal results have remained stable 21 months after the removal of the appliance for intrusion (eight months after the end of treatment eight months after the end of treatment) (Figure 10A-D).

CONCLUSIONS [Return to TOC](#)

The rapid molar intrusion appliance consists of elastic modules attached to the buccal auxiliary tubes of orthodontic bands on the four maxillary and mandibular first molars. As patients occlude, these modules are flexed and produce intrusion and some corresponding closure of anterior open bites are typically produced in 4–6 months without the use of vertical elastics. Adverse buccal tipping of the molars is counteracted by a maxillary transpalatal arch mechanism can be incorporated into typical orthodontic mechanics. However, these intrusive forces are applied independently from the constraints of patient cooperation required with other devices such as headgears, elastics, or bite

The initial clinical experiences with the RMI device are promising and although a more structured research project is needed to document the long-term effects. The long-term results in these two cases suggest that the RMI intrudes molars without the use of vertical elastics.

In 19 consecutively treated cases using these mechanics, no signs or symptoms of temporomandibular disorder were reported either during or after intrusion of the molars.

The RMI seems to limit normal eruption of the molars during growth and to induce a change of the cant of the mandibular plane resulting from anterior rotation. In the adult, it appears to close the bite by molar intrusion and anterior rotation of the mandible thus far.

REFERENCES [Return to TOC](#)

- Schendel SA, Carlotti AE Jr. Variations of total vertical maxillary excess. *J Oral Maxillofac Surg.* 1985; 43:590–596. [\[PubMed Citation\]](#)
- Subtelney JD, Sakuda M. Open-bite: diagnosis and treatment. *Am J Orthod.* 1964; 50:337–358.
- Schendel SA, Eisenfeld J, Bell WH, Epker BN, Mischelevich DJ. The long face syndrome: vertical maxillary excess. *Am J Orthod.* 1976; 70:398–408. [\[PubMed Citation\]](#)
- Schudy FF. The rotation of the mandible resulting from growth: its implications in orthodontic treatment. *Angle Orthod.* 1965; 35:36–50. [\[PubMed Citation\]](#)
- Creekmore TD. Inhibition or stimulation of the vertical growth of the facial complex, its significance to treatment. *Angle Orthod.* 1967; 37:285–297. [\[PubMed Citation\]](#)
- Bell WH, Proffit WR, White RP. *Surgical Correction of Dentofacial Deformities.* Philadelphia, Pa: WB Saunders Co; 1980.
- Owen AH. Modified function regulator for vertical maxillary excess. *J Clin Orthod.* 1985; 19:733–749. [\[PubMed Citation\]](#)
- Pfeiffer JP, Grobety D. Simultaneous use of cervical appliances and activator: an orthopedic approach to fixed appliance therapy. *Am J Orthod.* 1972; 61:353–373. [\[PubMed Citation\]](#)
- Woods MG, Nanda RS. Intrusion of posterior teeth with magnets: an experiment in growing baboons. *Angle Orthod.* 1988; 58:136–150. [\[PubMed Citation\]](#)
- Kiliaridis S, Egermark I, Thilander B. Anterior open bite treatment with magnets. *Eur J Orthod.* 1990; 12:447–457. [\[PubMed Citation\]](#)
- Darendeliler M, Yuksel S. Open-bite correction with the magnetic activator device IV. *J Clin Orthod.* 1995; 29:569–576. [\[PubMed Citation\]](#)
- Armbruster P, Sheridan JJ, Nguyen P. An Essix intrusion appliance. *J Clin Orthod.* 2003; 37:412–416. [\[PubMed Citation\]](#)
- Iscan HN, Dincer M, Gultan A, Meral O, Taner-Sarisoy L. Effects of vertical chin-cap therapy on the mandibular morphology in open-bite patients. *Eur J Orthod.* 2002; 24:407–416. [\[PubMed Citation\]](#)
- Sugawara J, Baik UB, Umemori M, Takahashi I, Nagasaka H, Kawamura H, Mitani H. Treatment and posttreatment dentoalveolar changes following intrusion of mandibular molars with application of a skeletal anchorage (SAS) for intrusion. *J Clin Orthod.* 2002; 122:593–600. [\[PubMed Citation\]](#)
- Sherwood KH, Burch JG, Thompson WJ. Closing anterior open bites by intruding molars with titanium miniplate. *Am J Orthod Dentofacial Orthop.* 2002; 122:506–511. [\[PubMed Citation\]](#)
- Carano A, Machata B. Non-compliance orthodontics: rapid molar intrusion. *J Clin Orthod.* 2002; 36:137–142. [\[PubMed Citation\]](#)
- Carano A, Testa M. The Spring Jet for slow maxillary expansion. *J Clin Orthod.* 1999; 9:527–531.

TABLES [Return to TOC](#)

Table 1. Some of the Cephalometric Measurements of the Growing Patient Before the Intrusion with the Rapid Molar Intrusion (RMI) (T1), Soon After the Removal of the RMI (T2) and 21 Months After the Removal of the RMI (T3)

Federica R (F 12.4y)	December 5, 2001 T1	September 3, 2002 T2	June 4, 2004 T3
Skeletal Measurements			
SNA	76.8	76.9	79.1
SNB	74.1	74.5	75.2
ANB	2.7	2.4	3.9
SN ANS-PNS	-1.8	-1.8	-1.8
S-N-Pg (angle)	73.1	75.7	76.0
Go-Gn	72.5	72.6	72.4
Ar-Gn	43.2	43.6	43.4
S-N Go-Gn	43.5	39.6	41.3
Ar-Go-Gn (angle)	138.4	136.6	137.0
Ar-Go-N (angle)	57.6	57.8	58.1
N-Go-Gn	81.8	79.7	78.9
Asse Y S-N	74.5	71.1	73.5
ANS-PNS Go-Gn	40.5	36.4	39.2
ANS-Me (mm)	71.2	68.6	72.9
N-Me (mm)	117.6	113.4	117.3
S-Go (mm)	71.2	70.9	72.0
Dental measurements			
SN Occl plane	19.2	21.8	19.9
Occl plane Go-Gn	24.4	17.4	21.6
U1 L1	112.1	118.2	117.3
U1 SN	112.7	86.4	97.7
L1 GoGn	90.8	88.7	93.5
APg-L1	2.0	1.6	3.8
Wits appraisal	-1.7	-3.2	0.4
Open bite	-4.6	2.1	2.5
Max 1-palatal plane	31.4	33.3	32.9
Max 6-palatal plane	16.8	14.6	17.4
Max 7-palatal plane	13.3	12.1	14.9
Mand 1-mandible	34.7	35.3	41.3
Mand 1molar-mandible	22.2	20.1	24.1
Mand 2molar-mandible	19.1	19.2	22.3

Table 2. Some of the Cephalometric Measurements of the Adult Patient Before the Intrusion with the Rapid Molar Intrusion (RMI) Device (T1), Soon After the Removal of the RMI (T2), and 21 Months After the Removal of the RMI (T3).

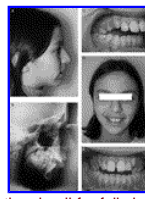Concetta G (F 23.1y)	August 5, 2001 T1	May 18, 2002 T2	February 20, 2004 T3
Skeletal measurements			
SNA	75.5	75.6	75.9
SNB	68.2	69.6	69.4
ANB	7.3	6.0	6.5
SN ANS-PNS	9.3	9.0	10.4
S-N-Pg (angle)	68.8	70.0	71.3
Go-Gn	74.3	74.8	74.5
Ar-Gn	51.1	51.7	52.9
S-N Go-Gn	46.4	43.0	42.3
Ar-Go-Gn (angle)	129.1	125.9	125.5
Ar-Go-N (angle)	47.1	47.8	47.4
N-Go-Gn	82.0	78.2	78.5
Asse Y S-N	80.2	78.1	77.2
ANS-PNS Go-Gn	34.9	32.2	31.9
ANS-Me (mm)	85.5	82.5	81.6
N-Me (mm)	140.7	138.4	137.7
S-Go (mm)	82.1	81.2	81.0
Dental measurements			
SN Occl plane	22.6	24.5	24.5
Occl plane Go-Gn	18.3	16.9	17.7
U1 L1	130.4	124.7	130.1
U1 SN	91.6	92.1	91.9
L1 GoGn	90.8	98.8	97.4
APg-L1	0.2	1.6	1.6
Wits appraisal	6.5	5.0	4.0
Open bite	-1.9	1.3	1.2
Max 1-palatal plane	36.3	37.8	36.4
Max 6-palatal plane	23.6	22.3	22.4
Max 7-palatal plane	19.8	17.4	17.6
Mand 1-GoGn	43.7	42.6	42.6
Mand 6-GoGn	32.6	31.1	31.3
Mand 7-GoGn	29.9	28.7	28.6

FIGURES [Return to TOC](#)



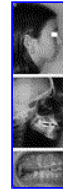
[Click on thumbnail for full-sized image.](#)

FIGURE 1. The rapid molar intrusion (RMI) appliance consists of two elastic modules. (A) The terminal ends of the modules are secured at the upper and lower molar tubes with L-shaped pins. (B) RMI oriented to produce force to assist with a Class III malocclusion



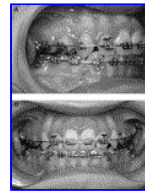
Click on thumbnail for full-sized image.

FIGURE 2. Twelve-year-old female with "long face" appearance and lip incompetency (A–B) exhibited a Class I mixed dentition malocclusion with 3.6-mm open bite and some posterior constriction (C–E). Cephalometric analysis revealed (PNS-Go-Gn 40.5°)



Click on thumbnail for full-sized image.

FIGURE 3. After five months of molar intrusion with the RMI (A–C) the effects of molar intrusion and resultant counterclockwise rotation of the mandible are evident



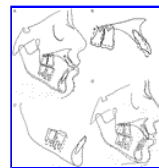Click on thumbnail for full-sized image.

FIGURE 4. Intraoral photographs during retention of intruded molars (A–B)



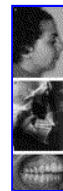
Click on thumbnail for full-sized image.

FIGURE 5. Facial and intraoral photos after treatment (A–E)



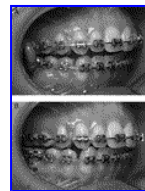
Click on thumbnail for full-sized image.

FIGURE 6. Superimposition demonstrating molar intrusion and favorable mandibular autorotation during use of the rapid molar intrusion (A– C). After removal of the intruder, some relapse occurred in the skeletal features whereas (D)



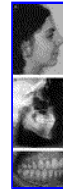
Click on thumbnail for full-sized image.

FIGURE 7. Twenty-two-year-old female exhibited a Class II malocclusion with 3-mm open bite and posterior crossbite (A–C)



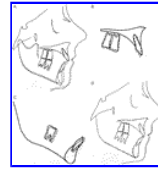Click on thumbnail for full-sized image.

FIGURE 8. (A) The patient with the appliance. (B) After five months of molar intrusion



Click on thumbnail for full-sized image.

FIGURE 9. Final correction of the Class II malocclusion was achieved using Class II intermaxillary elastics but no anterior vertical elastics (A–C)



Click on thumbnail for full-sized image.

FIGURE 10. Superimposition demonstrating molar intrusion and favorable mandibular autorotation during use of the rapid molar intrusion (A– C). Twenty-one months after removal of the intruder, the skeletal and dental changes were

^aAdjunct Professor, Department of Orthodontics, University of Ferrara, Ferrara, Italy; Adjunct Professor, Department of Orthodontics, St Louis University, St Louis, Mo

^bChairman, Department of Orthodontics, University of Ferrara, Ferrara, Italy

^cAdjunct Associate Professor, Department of Orthodontics, St Louis University, St Louis, Mo

Corresponding author: Aldo Carano, Dr Odont, MS, Spec Orthod, Lungomare 15, 74100 Taranto, Italy (E-mail: a.carano@libero.it)

Aldo Carano holds a financial interest in the Rapid Molar Intruder (RMI) appliance described in this article.