

[\[Print Version\]](#)  
[\[PubMed Citation\]](#) [\[Related Articles in PubMed\]](#)

#### TABLE OF CONTENTS

[\[INTRODUCTION\]](#) [\[MATERIALS AND...\]](#) [\[RESULTS\]](#) [\[DISCUSSION\]](#) [\[CONCLUSIONS\]](#) [\[REFERENCES\]](#) [\[TABLES\]](#) [\[FIGURES\]](#)

*The Angle Orthodontist*: Vol. 75, No. 5, pp. 761-767.

## Apical Root Resorption of Maxillary First Molars after Intrusion with Zygomatic Skeletal Anchorage

Arzu Ari-Demirkaya;<sup>a</sup> Mazin Al Masry;<sup>b</sup> Nejat Erverdi<sup>c</sup>

### ABSTRACT

The aim of this study was to evaluate radiographically the apical root resorption of maxillary first molars after their intrusion was done using zygomatic miniplates as skeletal anchorage in open-bite cases. The study group consisted of 16 patients who had received special titanium miniplates in their zygomatic bones for use as anchorage to apply orthodontic intrusive forces to the maxillary posterior region. The control group consisted of 16 patients, who were matched for age, sex, and dental status. All patients had undergone fixed orthodontic treatment without intrusion mechanics for molars. Tooth lengths were measured on pretreatment, and posttreatment panoramic radiographs of all patients and mesiobuccal and distobuccal roots were measured on-screen using a software program. The difference between the pre- and posttreatment tooth lengths was defined as apical root resorption. Comparison of the differences in root resorption of the two groups using the Student's *t*-test showed a statistically significant difference ( $P = .004$ ) only for mesial roots on the right side. But because the mean difference in apical root resorption was only 0.5 mm, it was concluded that the apical root resorption of maxillary first molars with zygomatic skeletal anchorage was not clinically significant.

**KEY WORDS:** Apical root resorption, Intrusion, Maxillary molars, Zygomatic skeletal anchorage.

Accepted: August 2004. Submitted: June 2004

### INTRODUCTION [Return to TOC](#)

The treatment of patients with an anterior open bite has proven to be one of the most challenging aspects of orthodontics. Molar intrusion is normally required when a skeletal open bite is corrected without orthognathic surgery. However, extraoral anchorage, or a vertical-pull chin cap, or the active vertical corrector with magnets, require a high level of patient cooperation to effectively control intrusion of the molars.

Beck and Harris<sup>1</sup> discussed the likely relationship between biomechanics of bite closure and resorption of molar roots. In the Begg technique, the first molars in both arches had tip-back bends placed mesial to the molar tube, similar to the technique often used with a reverse curve of Spee in the upper archwire to assist with leveling, and many techniques use a high pull headgear to the upper molars, which show a high incidence of orthodontically induced inflammatory root resorption. However, investigators have not reported any difference in root resorption at low and high force levels (50 to 200 g).<sup>2</sup>

To obtain a rigid anchorage, dental implants and bone screws have been reported as orthodontic and orthopedic anchors. Zygomatic bone anchorage is one of the preferred methods for this purpose and this subject has been studied extensively.

Root resorption associated with orthodontic treatment has been recognized as a clinical problem since the 1920s.<sup>3</sup> According to the literature, the possible predisposing factors affecting root resorption are numerous.<sup>3,9-28</sup>

In the past, little attention has been paid to root resorption occurring in the posterior part of the dentition. In a radiographic study carried out by Hendrix et al,<sup>19</sup> posterior apical root resorption in orthodontic patients has been investigated using OPTGs (OPTGs), but limitations of OPTGs have been reported. The reliability of tooth length assessments using OPTGs and observations on distortion effects have been studied mathematically and experimentally on panoramic radiography. Vertical measurements, provided the patient is correctly positioned in the machine during the exposure.<sup>29</sup> In view of the fact that deviation of the apical part of the root may result in root resorption,<sup>16</sup> another shortcoming of OPTGs may be an abnormal shape on periapical films were rated normal on panoramic films.<sup>30</sup>

Several radiographic studies about type of tooth movement in the anterior teeth and its possible link to root resorption have been carried out.<sup>21,23,25,26</sup> Also, intrusion of anterior teeth with low forces (25 g) has been investigated.<sup>25</sup> The amount of root shortening observed, and treatment time was the most significant factor for occurrence of root shortening. Nevertheless, comparison of radiographic studies is difficult because of the large differences in methods and techniques used.

The aim of this study was to evaluate radiographically the apical root resorption of maxillary first molars after their intrusion was done using zygomatic miniplates as skeletal anchorage in open-bite cases.

### MATERIALS AND METHODS [Return to TOC](#)

#### Subjects

This study was performed on records of patients who were treated orthodontically in the Department of Orthodontics, Dental Faculty of Marmara University, between 2000 and 2004. Selection of cases was based on the presence of an anterior open bite, a description of the course of the orthodontic treatment, availability of clear before and after treatment OPTGs taken with the same orthopantomograph machine, and good oral hygiene.

For the study group (group 1), 16 consecutively treated open-bite cases (13 females and three males) were selected, who had received special titanium miniplates in their zygomatic bones to use as anchorage to apply orthodontic intrusive forces to the maxillary posterior region. The control group (group 2) consisted of 16 patients, who were matched for age, sex, and dental status. All patients had undergone fixed orthodontic treatment without intrusion mechanics for molars. The mean age in group 1 was 19.25 years (range 14-26 years). The mean age in group 2 was 19.43 years (range 14-25 years).

The intrusion of the upper posterior segments including the first molars was accomplished using closed Ni-Ti coil springs from the intraoral extensions of the zygomatic miniplates to extensions on the cap-splints (Figures 1 and 2). The intrusion was completed consisted of a standard 0.018 × 0.025-inch slot Edgewise technique with the maxillary molars tied passively to the zygomatic miniplates. The control group (group 2) consisted of 16 patients, who were matched regarding age, sex, and dental status. All patients had undergone standard 0.018 × 0.025-inch slot Edgewise treatment without intrusion mechanics for molars. The mean age in group 1 was 19.25 years (range 14-26 years). The mean age in group 2 was 19.43 years (range 14-25 years).

#### Methods

The OPTGs were taken with an orthopantomograph (Siemens, Bensheim, Germany) in a standardized manner, according to the instructions of the manufacturer (Figure 3). The AutoCAD R14 software (AutoDesk Co, San Rafael, CA) was used to measure the OPTGs automatically. A scanner (HP PSC 2210, HP, Kuala Lumpur, Malaysia) was used to scan the pretreatment and posttreatment OPTGs and transfer the size and magnification of OPTGs to the computer. They were corrected for magnification and standardized and calibration for image distortion. The magnification degree of the scanner was 1:1. For each tooth, the most occlusal point of the cusp and the most apical point of the root were determined (Figure 4a). The coordinates of the OPTGs in the AutoCAD software. The accuracy of the digitizer was 0.2 mm.

From these coordinates, tooth length for left and right permanent first molars in the maxilla was calculated automatically (Figure 4b). Mesiobuccal and distobuccal roots were measured and calculated separately as mesial and distal roots because of difficulty faced in locating root apices. Root resorption was calculated for each root by subtracting posttreatment tooth length from pretreatment tooth length.

#### Method error

The error of the method was measured to evaluate the reliability of the operator in locating the identification points. Sixteen OPTGs of a total 64 were randomly selected. The root lengths on those OPTGs were remeasured using the same method. Statistical evaluation of the method error was done by calculating Pearson's correlations between initial and repeated measurements of the root lengths and the paired samples *t*-test.

#### Statistical analysis

The null hypothesis established stated that there would be no difference in the amount of root resorption between the study and the control groups.

One-tail and two-tail Student's *t*-tests were used to compare pretreatment tooth lengths of the two groups and also to compare the differences in root resorption. The SPSS for Windows (SPSS Inc, Chicago, Ill) was used to analyze the data.

significant.

## RESULTS [Return to TOC](#)

### Method error

The repeated measurements were highly correlated, and this correlation was statistically significant ([Table 1](#)). The paired sample *t*-test revealed that differences between two measurements were not statistically significant ([Table 2](#)).

### Results of the main study

A comparison of groups 1 and 2 showed no statistically significant difference in root lengths at the beginning of treatment ([Table 2](#)).

The mean root resorption after intrusion for group 1, the mean root resorption after treatment for group 2, as well as the results of the comparison of the differences in root resorption of the two groups are summarized in [Table 3](#). The mean root resorption in group 1 was 2.49 mm among the roots in group 1. On the other hand, apical root resorption in group 2 ranged from zero to 1.60 mm, with 12 roots showing no resorption at all. There was a statistically significant difference between groups for root resorption ([Table 3](#)). On the basis of these results, the null hypothesis had to be rejected.

## DISCUSSION [Return to TOC](#)

According to the literature, there is no safe tooth movement with regard to OIIRR. Because intrusion is probably the most detrimental to the roots involved,<sup>25,26</sup> it was tempting to evaluate whether the intrusion of maxillary first molars could be one of the risk factors for apical root resorption.

There are controversial reports regarding sex differences in OIIRR. Kjar<sup>15</sup> found that females were slightly more affected than males, whereas Linge and Linge<sup>27</sup> reported no sex differences. Because of the retrospective character of the study, the quantity of OIIRR was not given because the majority of the patients were female.

The main source of error inherent in the method was landmark identification and the measurement procedure. From the insignificantly small method error, it can be concluded that the software program used in this study has the root apex more discernible, minimizing the possible errors during these procedures.

Most studies on anterior apical root resorption rely on standardized long-cone periapical radiographs of maxillary anterior teeth. However, Sharpe et al<sup>28</sup> observed on periapical radiographs that molars have the second highest incidence of root resorption.

Hendrix et al<sup>19</sup> studied the root resorption of posterior teeth in orthodontic patients using OPTGs. In this study, OPTGs were used to evaluate root resorption of maxillary first molars because they were part of the standard set of root apex points on the palatal root of the first maxillary molar proved to be very difficult and unreliable, and therefore the measurements of these roots were excluded. But it can be concluded that although panoramic radiography has its limitations, it can be sufficiently reliable for vertical measurements<sup>29</sup> on mesial and distal roots of posterior teeth, provided head posture during exposure is standardized.

Some investigators have suggested that resorption increases with increasing length of active treatment and, therefore, severe resorption is more likely in patients with long treatment times.<sup>23,25,28</sup> Levander and Malmgren<sup>12</sup> found that after six to nine months of treatment, whereas at the end of 19 months active treatment, root resorption increased to 56%. It has also been reported previously that some resorption occurs in almost every orthodontic patient.<sup>10,11</sup> The findings of this study were not designed to investigate the relationship between the amount of root resorption and the duration of active treatment, but the mean duration of active treatment was about 20 months in both groups. This relatively long treatment time applied to the maxillary molars, appears to have caused 81% of the roots evaluated to show some resorption on careful examination of panoramic radiographs. In the intrusion group, all the roots evaluated showed resorption to some extent, whereas the amount calculated larger than the largest resorption in the control group.

Because the mean difference in root length between the groups before treatment was insignificant, the groups were considered similar and comparable in that regard. The maximum mean difference between groups was 0.58 mm. Dermaut and De Munck<sup>26</sup> and less than the one mm of resorption found after orthodontic therapy by Linge and Linge<sup>27</sup> in studies done on anterior teeth.

Mild to moderate shortening of the roots as a consequence of orthodontic treatment, with loss of up to one-quarter of the root length, was said to have no clinical significance.<sup>18</sup> Severe resorption, defined as loss of more than one-quarter of the root length and potentially significant; however, in these patients, it is difficult to demonstrate major adverse clinical effects. For support of the tooth, three mm of apical root loss is equivalent to one mm of crestal bone loss, which implies that the overall periodontal support.<sup>18</sup>

Fortunately, resorption related to treatment almost never continues once the active phase of treatment has ended. Nevertheless, avoiding severe resorption should be a goal of orthodontic treatment. However, on the basis of the findings of this study, root resorption than periapical films for 743 teeth surveyed and that the use of panoramic films to measure pre- and posttreatment root resorption may overestimate the amount of root loss by 20% or more,<sup>30</sup> the largest amount of root loss is likely to have clinical implications.

Although high force levels are said to play a role in OIIRR,<sup>3,27</sup> the relationship between biomechanics of bite closure and apical resorption of molar roots may be more important than force levels. The high incidence of posttreatment root resorption is because of the large moment on the teeth rather than the net force of the mechanics.<sup>1,2</sup> In this study, the mean intrusion force level was about 150 g, applied with a closed Ni-Ti coil spring to achieve low continuous intrusive force. However, on the mesial roots, together with the larger amount of OIIRR of the left mesial roots, suggests that perhaps an unintentional counterclockwise moment was created during intrusion. Because, at least for some of the patients, the coil spring was applied to the buccal surface of the cap splint, this counterclockwise moment may be because of the force application anterior to the center of resistance of the posterior segments, which should be located closer to the second molar than the first molar.

The result of our study showed statistical significance of root resorption of upper right mesial roots. Because the amount of resorption was small and the resorption on the other roots statistically insignificant, it can be concluded that the intrusion aided by zygomatic skeletal anchorage is clinically insignificant.

The amount of intrusive tooth movement was not measured in this study. Further investigation with a bigger sample size and further investigation into the association between the degree of intrusion of the posterior teeth and the amount of root resorption is needed.

## CONCLUSIONS [Return to TOC](#)

Within the limitations of this study, apical root resorption of maxillary first molars after intrusion was done using zygomatic miniplates as skeletal anchorage was not clinically significantly different from apical root resorption associated with orthodontic mechanics.

## REFERENCES [Return to TOC](#)

1. Beck BW, Harris EF. Apical root resorption in orthodontically treated subjects: analysis of edgewise and light wire mechanics. *Am J Orthod Dentofacial Orthop.* 1994; 105:350–361. [[PubMed Citation](#)]
2. McNab S, Battistutta D, Taverne A, Symons AL. External apical root resorption following orthodontic treatment. *Angle Orthod.* 2000; 70:227–232. [[PubMed Citation](#)]
3. Owman-Moll P, Kuro J, Lundgren D. Effects of doubled orthodontic force magnitude on tooth movement and root resorption. An inter-individual study. *Eur J Orthod.* 1996; 18:141–150. [[PubMed Citation](#)]
4. Umemori M, Sugawara J, Mitani H, Nagasaka H, Kawamura H. Skeletal anchorage system for open-bite correction. *Am J Orthod Dentofacial Orthop.* 1999; 115:166–174. [[PubMed Citation](#)]
5. Southard TE, Buckley MJ, Spivey JD, Krizan KE, Casco JS. Intrusion anchorage potential of teeth versus rigid endosseous implants: a clinical and radiographic evaluation. *Am J Orthod Dentofacial Orthop.* 1995; 107:115–120. [[PubMed Citation](#)]
6. Erverdi N, Keles A, Nanda R. The use of skeletal anchorage in open bite treatment: a cephalometric evaluation. *Angle Orthod.* 2004; 74:381–390. [[PubMed Citation](#)]
7. Erverdi N, Keles A. Anchorage for closing open bites. *Am J Orthod Dentofacial Orthop.* 2003; 123:14A–15A.
8. Kaley J, Phillips C. Factors related to root resorption in edgewise practice. *Angle Orthod.* 1991; 61:125–132. [[PubMed Citation](#)]
9. Goldie RS, King GJ. Root resorption and tooth movement in orthodontically treated, calcium-deficient, and lactating rats. *Am J Orthod Dentofacial Orthop.* 1984; 85:424–430.
10. Brezniak N, Wasserstein A. Root resorption. Part 1—literature reviews. *Am J Orthod Dentofacial Orthop.* 1993; 103:162–66. [[PubMed Citation](#)]
11. Harris EF, Kineret SE, Tolley EA. A heritable component for external apical root resorption in patients treated orthodontically. *Am J Orthod Dentofacial Orthop.* 1997; 111:301–309. [[PubMed Citation](#)]
12. Levander E, Malmgren O. Long term follow-up of maxillary incisors with severe apical root resorption. *Eur J Orthod.* 2000; 22:85–92. [[PubMed Citation](#)]
13. Al-Qawasmí RA, Hartsfield JK Jr, Everett ET, Flury L, Liu L, Frouud TM, Macri JV, Roberts WE. Genetic predisposition to external apical root resorption. *Am J Orthod Dentofacial Orthop.* 2003; 123:242–252. [[PubMed Citation](#)]
14. Owman-Moll P, Kuro J, Lundgren D. Continuous versus interrupted continuous orthodontic force related to early tooth movement and root resorption. *Angle Orthod.* 1995; 65:395–401. [[PubMed Citation](#)]
15. Kjar I. Morphological characteristics of dentitions developing excessive root resorption during orthodontic treatment. *Eur J Orthod.* 1995; 16:25–34.

16. Sameshima GT, Sinclair PM. Predicting and preventing root resorption: part I. Diagnostic factors. *Am J Orthod Dentofacial Orthop.* 2001; 119:505–510. [[PubMed Citation](#)]
17. Malmgren O, Goldson L, Hill C, Orwin A, Petrini L, Lundberg M. Root resorption after orthodontic treatment of traumatized teeth. *Am J Orthod Dentofacial Orthop.* 1982; 82:487–491.
18. Remington DN, Joondeph DR, Årtun J, Riedel RA. Long-term evaluation of root resorption occurring during orthodontic treatment. *Am J Orthod Dentofacial Orthop.* 1989; 96:43–46. [[PubMed Citation](#)]
19. Hendrix I, Carels C, Kuipers-Jagtman AM, Van 'T Hof M. A radiographic study of posterior apical root resorption in orthodontic patients. *Am J Orthod Dentofacial Orthop.* 1994; 105:345–349. [[PubMed Citation](#)]
20. Harris EF, Baker WC. Loss of root length and crestal bone height before and during treatment in adolescent and adult orthodontic patients. *Am J Orthod Dentofacial Orthop.* 1990; 98:463–469. [[PubMed Citation](#)]
21. Costopoulos G, Nanda R. An evaluation of root resorption incident to orthodontic intrusion. *Am J Orthod Dentofacial Orthop.* 1996; 109:543–548. [[PubMed Citation](#)]
22. Mirabella AD, Årtun J. Prevalence and severity of apical root resorption of maxillary anterior teeth in adult orthodontic patients. *Eur J Orthod.* 1995; 17:93–99. [[PubMed Citation](#)]
23. Linge BO, Linge L. Apical root resorption in upper anterior teeth. *Eur J Orthod.* 1983; 5:173–183. [[PubMed Citation](#)]
24. Baumrind S, Korn EL, Boyd RL. Apical root resorption in orthodontically treated adults. *Am J Orthod Dentofacial Orthop.* 1996; 110:311–320. [[PubMed Citation](#)]
25. McFadden WM, Engström C, Engström H, Anholm JM. A study of the relationship between incisor intrusion and root shortening. *Am J Orthod Dentofacial Orthop.* 1989; 96:390–396. [[PubMed Citation](#)]
26. Dermaut LR, De Munck A. Apical root resorption of upper incisors caused by intrusive tooth movement: a radiographic study. *Am J Orthod Dentofacial Orthop.* 1986; 90:321–326. [[PubMed Citation](#)]
27. Linge L, Linge BO. Patient characteristics and treatment variables associated with apical root resorption during orthodontic treatment. *Am J Orthod Dentofacial Orthop.* 1991; 99:135–43. [[PubMed Citation](#)]
28. Sharpe W, Reed B, Subtelny JD, Polson A. Orthodontic relapse, apical root resorption and crestal alveolar bone levels. *Am J Orthod Dentofacial Orthop.* 1987; 91:3252–258. [[PubMed Citation](#)]
29. Larheim TA, Svanaes DB. Reproducibility of rotational panoramic radiography: mandibular linear dimensions and angles. *Am J Orthod Dentofacial Orthop.* 1986; 90:45–51. [[PubMed Citation](#)]
30. Sameshima GT, Asgarifar KO. Assessment of root resorption and root shape: periapical vs panoramic films. *Angle Orthod.* 2001; 71:185–189. [[PubMed Citation](#)]

TABLES [Return to TOC](#)

TABLE 1. Method Error<sup>a</sup>

	n	Mean Difference (mm)	SD (mm)	r	P(r)	t	P(t)
Right mesial root	16	-0.061	0.225	0.995	.000	-1.087	.294
Right distal root	16	-0.069	0.185	0.995	.000	-1.493	.156
Left mesial root	16	-0.140	0.396	0.985	.000	-1.419	.176
Left distal root	16	0.023	0.269	0.993	.000	0.353	.729

<sup>a</sup> P(r) is the significance of the correlation, P(t) is the significance of the t-test.

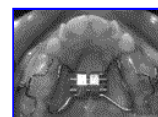
TABLE 2. Root Lengths at the Beginning of Treatment (t-Test)

	Group	n	Mean (mm)	SD (mm)	Mean Difference (mm)	t	P
Right mesial roots	1	16	22.671	2.064	0.590	0.890	.381
	2	16	22.081	1.662			
Right distal roots	1	16	21.845	1.996	-0.083	-0.124	.902
	2	16	21.928	1.814			
Left mesial roots	1	15	22.317	1.878	-0.035	-0.048	.962
	2	16	22.353	2.226			
Left distal roots	1	15	21.657	2.165	-0.230	-0.280	.781
	2	16	21.887	2.405			

TABLE 3. Differences in Root Resorption After Treatment (t-Test)


	Group	n	Mean (mm)	SD (mm)	Mean Difference (mm)	t	P
Resorption of right mesial roots	1	16	1.003	0.606	0.581	3.197	.004
	2	16	0.421	0.402			
Resorption of right distal roots	1	16	0.717	0.663	0.242	1.224	.232
	2	16	0.475	0.432			
Resorption of left mesial roots	1	15	0.840	0.713	0.418	1.981	.060
	2	16	0.421	0.414			
Resorption of left distal roots	1	15	0.786	0.465	0.311	1.898	.068
	2	16	0.474	0.447			

FIGURES [Return to TOC](#)



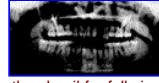Click on thumbnail for full-sized image.

FIGURE 1. Appliance used for intrusion of posterior segments. Note wire extensions to attach coil springs



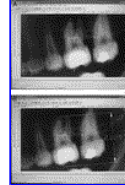Click on thumbnail for full-sized image.

**FIGURE 2.** (A) Before treatment. (B) Beginning of intrusion, appliance cemented. (C) End of intrusion. (D) After removal of appliance



Click on thumbnail for full-sized image.

**FIGURE 3.** OPTG taken after intrusion of posterior segments. Note zygomatic miniplates still in place



Click on thumbnail for full-sized image.

**FIGURE 4.** (A) On-screen identification of the most occlusal point of the cusp and most apical point of the root. (B) Computer-generated measurement of the distance between two identification points (root length)

<sup>a</sup>Assistant Professor, Department of Orthodontics, Faculty of Dentistry, Marmara University, Istanbul, Turkey

<sup>b</sup>Research Assistant, Department of Orthodontics, Faculty of Dentistry, Marmara University, Istanbul, Turkey

<sup>c</sup>Professor and Head, Department of Orthodontics, Faculty of Dentistry, Marmara University, Istanbul, Turkey

Corresponding author: Arzu Ari-Demirkaya, PhD, Department of Orthodontics, Faculty of Dentistry, Marmara University, Buyukciftlik Sok 6 Nisantasi, Istanbul 34365, Turkey (E-mail: [arzucan@...](mailto:arzucan@...))