

[\[Print Version\]](#)
[\[PubMed Citation\]](#) [\[Related Articles in PubMed\]](#)

TABLE OF CONTENTS

[\[INTRODUCTION\]](#) [\[MATERIALS AND...\]](#) [\[RESULTS\]](#) [\[DISCUSSION\]](#) [\[CONCLUSIONS\]](#) [\[REFERENCES\]](#) [\[FIGURES\]](#)

The Angle Orthodontist: Vol. 75, No. 5, pp. 797-804.

Neutralizing Effects of an Anti-Vascular Endothelial Growth Factor Antibody on Tooth Movement

Shinya Kohno;^a Masato Kaku;^b Toshitsugu Kawata;^b Tadashi Fujita;^b Keisuke Tsutsui;^a Junji Ohtani;^c Kaoru Tenjo;^c Yuiko Tohma;^c Masahide Motokawa;^c Mao Shigekawa;^c Hiroaki

ABSTRACT

Our recent studies demonstrated that local administration of recombinant human vascular endothelial growth factor (rhVEGF) during experimental tooth movement enhanced the number of osteoclasts and the rate of tooth movement. In the present study, we examined the effect of anti-VEGF polyclonal antibody on osteoclastic differentiation, the amount of tooth movement, and the degree of tooth relapse in 30-day-old mice. First, these mice were subjected to experimental tooth movement with an orthodontic appliance, with tooth movement for three days. In the next study, daily injections of 10- μ g antibody were administered for 18 days during the experimental tooth movement. The amount of tooth movement was measured. In the third study, we administered daily injection of 10- μ g antibody and measured tooth relapse after the experimental tooth movement for 45 days. The osteoclasts number in 10- and 50- μ g antibody two-time injected groups was significantly lower than the controls ($P < .05$). The number of osteoclasts was decreased more substantially by daily injection of 10- μ g antibody, showing more significant differences from the controls ($P < .01$). The amount of tooth movement was significantly less than that in the controls on days 15 and 18 ($P < .05$). Furthermore, the amount of relapse in the experimental group was significantly less than that in the controls on days 9 and 11 after removal of the appliance. Treatment of anti-VEGF polyclonal antibody markedly reduced the osteoclasts number and inhibited the amount of tooth movement and relapse of moved teeth.

KEY WORDS: VEGF, Anti-VEGF polyclonal antibody, Osteoclast, Bone remodeling, Experimental tooth movement.

Accepted: December 2004. Submitted: October 2004

INTRODUCTION [Return to TOC](#)

In clinical orthodontics, undesirable outcomes such as a movement of anchor teeth during tooth movement and relapse of well-aligned teeth to their original positions after treatment sometimes occur. If these phenomena could be avoided, treatment with long-term stability could be achieved and maintained.

Osteoclastic bone resorption is a well-understood cause of these undesirable tooth movements. Previous studies demonstrated that injection of bisphosphonate, a potent blocker of bone resorption, during or after experimental tooth movement and retention by inhibiting the appearance of osteoclasts and subsequent bone resorption.¹⁻³

Vascular endothelial growth factor (VEGF) is an important and essential mediator of angiogenesis.⁴ Previous studies^{5,6} demonstrate that recombinant human (rh)VEGF induces many osteoclasts in osteopetrotic (*op/op*) mice, resulting from mutation of the macrophage colony-stimulating factor gene.⁷⁻¹²

Furthermore, our latest study reports that VEGF is detected clearly within periodontal tissues during experimental tooth movement and that local administration of rhVEGF with the application of mechanical orthodontic force increases the extent of tooth movement.^{13,14} Therefore, we hypothesize that osteoclastic bone resorption during tooth movement may be inhibited by neutralizing the bioactivity of endogenous VEGF. In a previous study, we demonstrated that osteoclasts in *op/op* mice disappeared after intraperitoneal injection of an anti-VEGF⁵ polyclonal antibody, which neutralized the bioactivity of VEGF. We anticipate that an anti-VEGF polyclonal antibody may eliminate the effect of VEGF on anchor teeth and relapse of moved teeth.



The purpose of this study was to investigate the effect of an anti-VEGF polyclonal antibody on osteoclast differentiation, the extent of tooth movement, and the degree of tooth relapse.

MATERIALS AND METHODS [Return to TOC](#)

Experimental animals and histological examination

Thirty-day-old C57BL/6J mice weighing approximately 15 g were obtained from Jackson Laboratory (Bar Harbor, Me) and used in this experiment. All animals were treated under ethical regulations for animal experiments at the University Faculty of Dentistry.

Forty mice were divided into five groups of eight each. The first group, serving as the control, received nonimmune rabbit serum injections, with experimental tooth movement. Three groups underwent two injections of VEGF (LAB VISION, Fremont, Calif) immediately after the initiation of experimental tooth movement and six hours before the end of the experiment. The latest study showed that cyclic tensile forces significantly increased VEGF production by fibroblasts at 12 hours, suggesting that the VEGF protein was produced over a short time period by mechanical stimulation of the PDL.¹⁵ Therefore, we injected the anti-VEGF polyclonal antibody immediately after initiation of experimental tooth movement. The fifth group received VEGF polyclonal antibody six hours before the end of experiment was to inhibit osteoclast differentiation induced by endogenous VEGF. The fifth group received an injection of the anti-VEGF polyclonal antibody (10 μ g).

An experimental appliance with a helical loop was made from 0.008-inch stainless steel round wire (3M Unitek, Monrovia, Calif). The appliance was bonded onto the lateral surfaces of the upper incisors ([Figure 1](#) ). Antibody injections were made subcutaneously in the labial gingival groove of the incisors ([Figure 1](#) ). Experimental tooth movement was continued for three days as described previously.¹³ The anti-VEGF polyclonal antibody was administered using a hyperimmunization protocol.

The mice were sacrificed under general anesthesia with sodium pentobarbital, fixed in 4% paraformaldehyde, and rinsed with distilled water. The specimens were then decalcified in 14% ethylenediaminetetraacetic acid (EDTA) solution. The premaxillary bones, including the upper incisors, were cut into 7- μ m-thick transverse sections along the long axis of root. These sections were stained for tartrate-resistant acid phosphatase (TRAP) activity and counterstained with hematoxylin to identify TRAP-positive multinucleated cells.¹⁶

The number of osteoclasts that appeared in the PDL space on the pressure side of the incisors was counted on five sections at 35- μ m intervals for each specimen.

Anchorage effects of the anti-VEGF polyclonal antibody injection on tooth movement

Ten 30-day-old C57BL/6J mice were divided into two groups. In the first group, serving as the control ($n = 8$), nonimmune rabbit serum was injected immediately after the beginning of experimental tooth movement. The second group received an injection of the anti-VEGF polyclonal antibody (10 μ g) into the buccal gingival groove around the incisors. Experimental tooth movement was continued for 18 days in both groups. The distances between the upper incisors, were measured every three days on the dorsoventral cephalograms. A rat-and-mouse cephalometric X-ray apparatus (Asahi Roentgen Ind Co, Kyoto, Japan) was used at 20-25 kV and 6 mA with Ultra-speed film (Eastman Kodak Co, Rochester, NY). We then measured the width of the midpalatal suture every three days on the frontal sections and subtracted it from the distance of tooth movement, as reported previously.¹³ At the end of the experiment, the number of osteoclasts was counted in both groups ($n = 8$), as described above.

Retentive effects of the anti-VEGF polyclonal antibody injection on tooth relapse

Twelve 30-day-old C57BL/6J mice were divided into two groups. All mice underwent experimental tooth movement for 45 days. In the first group, serving as the control ($n = 8$), nonimmune rabbit serum was injected daily during the experimental tooth movement.



second group underwent a daily injection of the anti-VEGF polyclonal antibody (10 µg) after removal of the appliance. The amount of tooth relapse was measured on days 1, 3, 5, 7, 9, 11, 13, 15, 17, and 19 after removal of the appliance. The animals were sacrificed 5 and 11 days after removing the experimental appliance, and the number of osteoclasts was counted on the mesial side of the PDL space.

Statistical treatment



To examine differences in the number of osteoclasts and the amount of tooth movement among multiple groups, we performed analysis of variance and multiple comparison tests (Fisher's) using a Statview® (Abacus

RESULTS [Return to TOC](#)


Changes in the number of osteoclasts resulting from the injection of the anti-VEGF polyclonal antibody with tooth movement

The number of osteoclasts in the 10- and 50-µg anti-VEGF polyclonal antibody two-time injection groups (immediately after the initiation of experimental tooth movement and 6 hours before the end of the experiment) group ($P < .05$) ([Figure 2](#) ). The number of osteoclasts in the 10-µg anti-VEGF polyclonal antibody daily injection group was significantly different from the control ($P < .01$) and the 1.0-µg antibody two-time injection group of osteoclasts were found between the control and 1.0-µg antibody two-time injection groups and between the 10- and 50-µg antibody two-time injection groups ([Figure 2](#) ).



The number of osteoclasts on days 9 and 18 after initiating the experiment and time-course changes in the amount of tooth movement


There were no significant differences in body weights between the control and experimental groups (10-µg anti-VEGF polyclonal antibody daily injection group) ([Figure 3](#) ). [Figure 4](#)  shows the number of osteoclasts and the number of osteoclasts induced on the pressure side of the PDL space in the control group was approximately 7 and 8 on days 9 and 18, respectively.

On the other hand, approximately two osteoclasts were found in the experimental group (10-µg anti-VEGF polyclonal antibody daily injection group) on these days. Significant differences in the number of osteoclasts were found between the control and experimental groups on days 9 and 18. Some osteoclasts and resorption lacunae were detected on the pressure side in the PDL space in the control group, whereas few resorption lacunae were detected in the experimental group (10-µg anti-VEGF polyclonal antibody daily injection group).

[Figure 6](#)  shows time-course changes in the amount of tooth movement measured every three days. The amount of tooth movement continued to increase through the experimental period in the control group. On the other hand, the amount of tooth movement in the experimental group (10-µg anti-VEGF polyclonal antibody daily injection group) increased gradually and the rate of increase was less than in the control group. On day 18, the amount of tooth movement was approximately 1.5 mm in the control group and 0.8 mm in the experimental group (10-µg anti-VEGF polyclonal antibody daily injection group), respectively. A significant difference was found between these two groups on days 15 and 18.

The number of osteoclasts on days 5 and 11 after removing the experimental appliance and time-course changes in the amount of tooth relapse

[Figure 7](#)  shows the number of osteoclasts on days 5 and 11 after removal of the appliance. On an average, 8 and 7 osteoclasts were induced on the mesial side of the PDL space in the control group on days 5 and 11, respectively. Some resorption lacunae were also detected on the mesial side in the control group. On the other hand, osteoclasts were rarely detected in the experimental group (a daily injection of 10-µg anti-VEGF polyclonal antibody after removal of the appliance) ([Figure 8](#) ).

[Figure 9](#)  shows time-course changes in relapse in the experimental and control groups. Within one day, the experimental and control groups showed a prominent relapse. The amount of relapse in the control group was approximately 70% in the control group on day 11 after removing the appliance. On the other hand, the experimental group (a daily injection of 10-µg anti-VEGF polyclonal antibody after removal of the appliance) showed a relapse of approximately 30% on day 11. A significant difference was found between the control and experimental groups on day 11. Administration of the anti-VEGF polyclonal antibody significantly reduced relapse after tooth movement.

DISCUSSION [Return to TOC](#)

In a previous study, VEGF was identified as an osteoclast differentiation factor and the VEGF receptor, *fms*-like tyrosine kinase (Flt-1), was shown to be expressed on osteoclasts.⁵ Furthermore, our latest study showed that mechanical stimuli accelerated tooth movement. We also showed that VEGF was expressed on the surface of osteoblasts in the PDL space during experimental tooth movement.¹⁴

From these findings, we assume that endogenous VEGF participates in osteoclast differentiation and bone resorption essential for tooth movement. Therefore, we hypothesize that the rate of tooth movement and relapse is related to the bioactivity of the endogenous VEGF that appears in the PDL space.

In this study, after application of an orthodontic force, animals received varying doses of the anti-VEGF polyclonal antibody. The number of osteoclasts was significantly reduced in the 10- and 50-µg anti-VEGF polyclonal antibody injection groups compared with the control group ($P < .05$). Moreover, the number of osteoclasts was significantly reduced in the anti-VEGF polyclonal antibody (10 µg) daily injection group than in the control ($P < .01$) and 1.0-µg anti-VEGF polyclonal antibody injection group of the anti-VEGF polyclonal antibody (10 µg) inhibits the number of osteoclasts induced by experimental tooth movement more effectively.

On days 15 and 18, the extent of tooth movement was significantly reduced in the anti-VEGF polyclonal antibody injection group than in the control group. Moreover, the amount of tooth relapse was significantly smaller on days 9 and 11 after removing the appliance. Therefore, we considered that daily treatment with the anti-VEGF polyclonal antibody suppressed the extent of tooth movement and posttreatment relapse. The anti-VEGF polyclonal antibody effectively neutralized the biological activity of rhVEGF.¹² In this study, we believed that the anti-VEGF polyclonal antibody effectively neutralized the endogenous VEGF generated in the PDL space during tooth movement. From these findings, we believe that, if applied to orthodontic patients, less complex orthodontic anchorage system and less extensive retention would be required to obtain the desired outcome.

However, in clinical orthodontics, mechanical retention is essential for stabilizing periodontal tissues after orthodontic treatment. A tensed and deformed PDL is particularly associated with the relapse of moved teeth. Therefore, we consider that the anti-VEGF polyclonal antibody together with mechanical retention after removal of orthodontic appliances.

A previous study showed that an anti-VEGF monoclonal antibody suppressed tumor growth by inhibiting VEGF-induced angiogenesis.^{18–20} Current clinical trials of an anti-VEGF monoclonal antibody therapy are already underway in Europe.

In the phase I study conducted to investigate the side effects of the anti-VEGF monoclonal antibody in cancer patients, critical side effects were not reported, although headache, fever, nausea, and vomiting at the level of the study. There were no significant differences in the body weights between the control and the anti-VEGF polyclonal antibody injection groups through the experimental period. Furthermore, inflammation reactions and tissue damage were not observed at the injection sites. Thus, it was suggested that injection of the anti-VEGF polyclonal antibody did not cause systemic side effects in the mice. However, future studies should be conducted to see whether this pharmacologic adjunctive approach is applicable to orthodontic patients.

CONCLUSIONS [Return to TOC](#)

- Treatment with the anti-VEGF polyclonal antibody significantly reduced the number of osteoclasts and inhibited the extent of tooth movement and relapse of the moved tooth.
- These results suggest that injection of an anti-VEGF polyclonal antibody may be useful in maintaining anchorage and retaining dental alignment after orthodontic tooth movement.
- Future studies should be done to see whether this pharmacologic adjunctive approach is appropriate and applicable to orthodontic patients.

REFERENCES [Return to TOC](#)

1. Igarashi K, Mitani H, Adachi H, Shinoda H. Anchorage and retentive effects of a bisphosphonate (AHBuBP) on tooth movements in rats. *Am J Orthod Dentofacial Orthop.* 1994; 106:279–289. [[PubMed Citation](#)]
2. Adachi H, Igarashi K, Mitani H, Shinoda H. Effects of topical administration of a bisphosphonate (risedronate) on orthodontic tooth movements in rats. *J Dent Res.* 1994; 73:1478–1486. [[PubMed Citation](#)]
3. Lee K, Sugiyama H, Imoto S, Tanne K. Effects of bisphosphonate on the remodeling of rat sagittal suture after rapid expansion. *Angle Orthod.* 2001; 71:265–273. [[PubMed Citation](#)]
4. Leung DW, Cachianes G, Kuang WJ, Goeddel DV, Ferrara N. Vascular endothelial growth factor is a secreted angiogenic mitogen. *Science.* 1989; 246:1306–1309.
5. Niida S, Kaku M, Amano H, Yoshida H, Kataoka H, Nishikawa S. Vascular endothelial growth factor can substitute for macrophage colony-stimulating factor in the support of osteoclastic bone resorption. *J Exp Med.* 2000; 192:107–114.
6. Kaku M, Niida S, Kawata T, Maeda N, Tanne K. Dose- and time-dependent changes in osteoclast induction after a single injection of vascular endothelial growth factor in osteopetrotic mice. *Biomed Res.* 2000; 21:67–71.
7. Marks SC Jr, Lane PW. Osteopetrosis, a new recessive skeletal mutation on chromosome 12 of the mouse. *J Hered.* 1976; 67:1–18.
8. Marks SC Jr. Morphological evidence of reduced bone resorption in osteopetrotic (op) mice. *Am J Anat.* 1982; 163:157–167. [[PubMed Citation](#)]

10. Felix R, Cecchini MG, Hofstetter W, Eloff PR, Stutzer A, Freisch H. Impairment of macrophage colony-stimulating factor production and lack of resident bone marrow macrophages in the osteopetrotic *op/op* mouse. [Citation](#)

11. Felix R, Cecchini MG, Freisch H. Macrophage colony-stimulating factor restores in vivo bone resorption in the *op/op* osteopetrotic mouse. *Endocrinology*. 1990; 127:2592–2594. [\[PubMed Citation\]](#)

12. Yoshida H, Hayashi S, Kunisada T, Ogawa H, Nishikawa S, Okamura H. The murine mutation osteopetrosis is in the coding region of the macrophage colony stimulating factor gene. *Nature*. 1990; 345:442–444. [\[PubMed Citation\]](#)

13. Kaku M, Kohno S, Kawata T, Fujita T, Tokimasa C, Tsutsui K, Tanne K. Effects of vascular endothelial growth factor on osteoclast induction during tooth movement in mice. *J Dent Res*. 2001; 80:1880–1883. [\[PubMed Citation\]](#)

14. Kohno S, Kaku M, Tsutsui K. et al. Expression of vascular endothelial growth factor and the effects on bone remodeling during experimental tooth movement. *J Dent Res*. 2003; 82:177–182. [\[PubMed Citation\]](#)

15. Yoshino H, Morita I, Murota SI, Ishikawa I. Mechanical stress induces production of angiogenic regulators in cultured human gingival and periodontal ligament fibroblasts. *J Periodontal Res*. 2003; 38:405–410. [\[PubMed Citation\]](#)

16. Hammarström LE, Hanker JS, Toverud SU. Cellular differences in acid phosphatase isoenzymes in bone and teeth. *Clin Orthop*. 1971; 78:151–167.

17. Olson TA, Mohanraj D, Ramakrishnan S. *In Vivo* neutralization of vascular endothelial growth factor (VEGF)/vascular permeability factor (VPF) inhibits ovarian carcinoma-associated ascites formation and tumor growth in mice. *Cancer Res*. 1999; 59:1035–1040. [\[PubMed Citation\]](#)

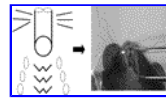
18. Kim KJ, Li B, Houck K, Winer J, Ferrara N. The vascular endothelial growth factor proteins: identification of biologically relevant regions by neutralizing monoclonal antibodies. *Growth Factors*. 1992; 7:53–64. [\[PubMed Citation\]](#)

19. Kim KJ, Li B, Winer J, Armanini M, Gillett N, Phillips HS, Ferrara N. Inhibition of vascular endothelial growth factor-induced angiogenesis suppresses tumor growth in vivo. *Nature*. 1993; 362:841–844. [\[PubMed Citation\]](#)

20. Kondo S, Asano M, Suzuki H. Significance of vascular endothelial growth factor/vascular permeability factor for solid tumor growth, and its inhibition by the antibody. *Biochem Biophys Res Commun*. 1993; 194:1234–1238. [\[PubMed Citation\]](#)


21. Takahashi Y, Mai M. Significance of angiogenesis and clinical application of anti-angiogenesis. *Nippon Geka Gakkai Zasshi*. 2001; 102:381–384.

FIGURES [Return to TOC](#)



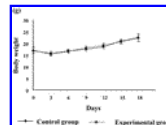
Click on thumbnail for full-sized image.

FIGURE 1. Occlusal view of experimental appliance with a helical loop (0.008 inch) for artificial tooth movement. Arrow indicates the injection site




Click on thumbnail for full-sized image.

FIGURE 2. The number of osteoclasts resulted from the injection of anti-vascular endothelial growth factor polyclonal antibody with tooth movement. The experimental tooth movement was continued for three days. **P* < .05, n = 8



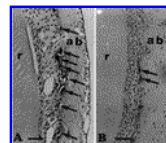
Click on thumbnail for full-sized image.

FIGURE 3. Changes in body weight for the control and the experimental group (10-µg anti-vascular endothelial growth factor polyclonal antibody daily injection group)



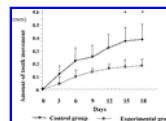
Click on thumbnail for full-sized image.

FIGURE 4. The number of osteoclasts nine and 18 days after the beginning of experimental tooth movement with or without anti-vascular endothelial growth factor polyclonal antibody injection. **P* < .05, n = 8




Click on thumbnail for full-sized image.

FIGURE 5. Histological sections (seven-µm thickness) of the periodontium around the incisors stained for tartrate-resistant acid phosphatase. Some osteoclasts and resorption lacunae were detected in the control (A) and experimental group (10-µg anti-vascular endothelial growth factor polyclonal antibody daily injection group) (B). Arrows indicate osteoclasts. r, root; ab, alveolar bone. Bar = 40 µm



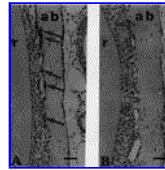
Click on thumbnail for full-sized image.

FIGURE 6. Time-course changes in the amount of tooth movement induced by experimental tooth movement with or without anti-vascular endothelial growth factor polyclonal antibody. **P* < .05, n = 8



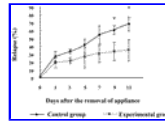
Click on thumbnail for full-sized image.

FIGURE 7. The number of osteoclasts 5 and 11 days after the removal of the experimental appliance. * $P < .05$, $n = 8$



Click on thumbnail for full-sized image.

FIGURE 8. Histological sections (7- μ m thickness) on the mesial side of the incisors 11 days after the removal of the experimental appliance stained for tartrate-resistant acid phosphatase. Alveolar bone resorption by hand, osteoclasts and resorption lacunae were hardly detected in the experimental group (a daily injection of 10- μ g anti-vascular endothelial growth factor polyclonal antibody after removal of the appliance). Arrows indicate



Click on thumbnail for full-sized image.

FIGURE 9. Time-course changes in the ratio of relapse after the removal of experimental appliance. Relapse (%) was expressed by $B/A \times 100$ (where A, distance moved by the appliance of force for 45 days and B, relapse distance after 10 days after removal of the appliance). $n = 8$

^aClinical Associate, Orthodontic Clinic, Hiroshima University Dental Hospital, Hiroshima, Japan

^bResearch Assistant, Department of Orthodontics and Craniofacial Developmental Biology, Hiroshima University Graduate School of Biomedical Sciences, Hiroshima, Japan

^cGraduate Student, Department of Orthodontics and Craniofacial Developmental Biology, Hiroshima University Graduate School of Biomedical Sciences, Hiroshima, Japan

^dProfessor and Chair, Department of Orthodontics and Craniofacial Developmental Biology, Hiroshima University Graduate School of Biomedical Sciences, Hiroshima, Japan

Corresponding author: Shinya Kohno, DDS, PhD, Department of Orthodontics and Craniofacial Developmental Biology, Hiroshima University Graduate School of Biomedical Sciences, 1-2-3 Kasumi, Minami-ku, Hiroshima, Japan