

[\[Print Version\]](#)
[\[PubMed Citation\]](#) [\[Related Articles in PubMed\]](#)

TABLE OF CONTENTS

[\[INTRODUCTION\]](#) [\[MATERIALS AND...\]](#) [\[RESULTS\]](#) [\[DISCUSSION\]](#) [\[CONCLUSIONS\]](#) [\[REFERENCES\]](#) [\[FIGURES\]](#)

The Angle Orthodontist: Vol. 75, No. 1, pp. 23-27.

Efficiency of Three Mandibular Anchorage Forms in Herbst Treatment: A Cephalometric Investigation

Dominique Weschler, DDS, Dr Med Dent,^a Hans Pancherz, DDS, Odont Dr, FCDSHK (Hon)^b

ABSTRACT

The aim of this study was to analyze the efficiency of the mandibular banded and cast splint anchorage forms used in Herbst treatment. The records of 16 Class II:1 subjects treated with mandibular banded premolar anchorage (group A), 19 Class II:1 subjects treated with mandibular banded premolar-molar anchorage (group B), 34 Class II:1 subjects (group C), and 18 Class II:2 subjects treated with mandibular cast splint anchorage (group D) were screened. The subjects in all four groups were treated for an average period of 0.6 years. Lateral head films were analyzed on four occasions ie, before treatment, after treatment, two years after, and four years after treatment. Mandibular anchorage loss during treatment was measured by the amount of anterior movement and proclination of the lower incisors as well as the anterior movement of the lower molars. During the treatment period a pronounced ($P < .001$) anchorage loss was found for all anchorage forms ie, incisor anterior movement/proclination as well as anterior movement of the lower molars. When comparing the cast splint anchorage in the Class II:1 and Class II: 2 cases, no difference was found with respect to the amount of mandibular anchorage loss of the incisors. After Herbst treatment, relapsing tooth movements were found in all three anchorage forms. It can be concluded that none of the three mandibular anchorage forms used in Herbst treatment could prevent an anchorage loss. Against all expectations, the cast splint anchorage was not better than the two banded anchorage forms.

KEY WORDS: Banded anchorage, Cast splint anchorage, Anchorage loss.




Accepted: January 2004. Submitted: November 2003

INTRODUCTION [Return to TOC](#)

The Herbst appliance is a fixed functional appliance used for the treatment of Class II malocclusions.¹ The appliance has skeletal and dentoalveolar effects.²⁻⁵ The Class II correction is accomplished by an increase in sagittal mandibular growth and by posterior maxillary tooth movements and anterior mandibular tooth movements. The dental effects are basically a result of anchorage loss.⁶ The mandible anchorage loss leads to an unwanted proclination of the incisors most of the time.

In an earlier study, Pancherz and Hansen⁶ compared five different anchorage systems of the banded type of the Herbst appliance. The results revealed that none of the anchorage systems could prevent anterior movement/proclination of the mandibular incisors.

To improve mandibular anchorage, a new anchorage system, the so-called cast splint anchorage has been used since 1995 at the Orthodontic Department, University of Giessen. The efficiency of this anchorage form has, however, to date not been examined.

Therefore, the aim of this Herbst study was to compare two of the original mandibular banded anchorage systems, the premolar anchorage ([Figure 1](#) ) and the premolar-molar anchorage ([Figure 2](#) ) with the mandibular cast splint anchorage ([Figure 3](#) ), with respect of their ability to prevent mandibular anterior tooth (incisors, molars) movements.

MATERIALS AND METHODS [Return to TOC](#)

Subjects

Four different Herbst sample groups were analyzed ie, group A: 16 Class II:1 subjects with a mandibular banded premolar anchorage (mean age of 12.2 years, range 10.8 to 13.6 years), group B: 19 Class II:1 subjects with a mandibular banded premolar-molar anchorage (mean age of 13.2 years, range 12.2 to 16.5 years), group C: 34 Class II: 1 subjects (mean age of 14.4 years, range 10.3 to 17.4 years except for one subject who was 34 years old), and group D: 18 Class II:2 subjects with a mandibular cast splint anchorage (mean age of 14.0 years, range 11.0 to 17.7 years). The average length of treatment was 0.6 years.

The severity of the malocclusion in the Class II:1 subjects was determined by the overjet and the molar relationship. The overjet was in group A: mean 8.4 mm (5.5–13.5 mm), in group B: mean 8.5 mm (7.0–12.0 mm), and in group C: mean 8.1 mm (5.5–12.0 mm). A distal molar relationship of three-quarters to one cusp width was present in all subjects, and no group differences were found.

The patients in group A and B were treated at the Orthodontic Department, Faculty of Odontology in Malmö, Sweden, and the patients in groups B and C were treated at the Orthodontic Department of the University of Giessen, Germany.

Only about half of the cases treated with the banded Herbst appliance were retained after treatment, and the other half was not retained at all. The subjects treated with a cast splint anchorage had a subsequent multibracket appliance treatment phase for about another year. Thereafter, retention was performed for one to two years with either a positioner or an activator in combination with a mandibular canine to canine retainer.

Cephalometric analysis


Lateral head films in habitual occlusion were analyzed on four occasions:

- T1: before Herbst treatment,
- T2: after Herbst treatment (treatment time 5–9 months),
- T3: approximately two years after Herbst treatment,
- T4: approximately four years after Herbst treatment.

Cephalometric changes were assessed during the following periods:

- T1–T2: treatment period (0.6 years, on average),
- T2–T3: first posttreatment period (two years, on average),
- T3–T4: second posttreatment period (two years, on average),
- T2–T4: total posttreatment period (four years, on average),
- T1–T4, total observation period (4.6 years, on average).

Method

Lateral head films from all subjects were analyzed twice, and the mean value was used as the final measuring value. The occlusal line (OL) and the occlusal line perpendicular (OLP) through pogonion from the T1 film were used as a reference grid for sagittal linear registrations ([Figure 4](#) ). The grid was transferred from the T1 film to the other films in a series (T2, T3, and T4) after superimposition of the head films using the anterior and inferior mandibular bone contours for orientation.

The analyses comprised the following variables ([Figure 4](#)):

i-OLP (D): position of the mandibular central incisor (mm),

IL/ML (D): inclination of the mandibular central incisor (°),

m-OLP (D): position of the mandibular permanent first molar (mm).

The registrations from the roentgenograms were made with the help of tracings on which the reference points were marked. Where double projections gave rise to two points, the midpoint was used. No correction was made for linear enlargement. The measuring points and reference lines used are shown in [Figure 4](#).

Statistical methods

The arithmetic mean (mean) and standard deviation (SD) were calculated for each variable. To assess the statistical significance of the changes that occurred in the four anchorage groups during the different examination periods, *t*-tests for paired samples were used. To compare the different anchorage groups, *t*-tests for independent samples were used. The following significance levels were considered: $P < .001$ (***), $P < .01$ (**), $P < .05$ (*), and $P > .05$ (ns: not significant).

Method errors

The combined method error (ME) was calculated, including the location of cephalometric landmarks, superimposition of the radiographs, and measurement of the changes of the different landmarks. The following formula was used in the ME calculations:

$$ME = \sqrt{\frac{\sum d^2}{2n}}$$

where d is the difference of double measurements and n the number of subjects.

RESULTS [Return to TOC](#)

Treatment changes (T1–T2)

The lower incisors moved anteriorly and proclined in all cases (group A: mean = 2.0 mm, SD = 1.0 mm/mean = 5.5°, SD = 3.5°; group B: mean = 2.2 mm, SD = 0.8 mm/ mean = 6.9°, SD = 2.7°; group C: mean = 3.6 mm, SD = 1.5 mm/mean = 9.3°, SD = 4.8°; and group D: mean = 3.5 mm, SD = 1.0 mm/mean = 9.7°, SD = 4.2°). These tooth movements were more extensive in subjects with the cast splint anchorage than in subjects with the two banded anchorage forms ($.01 > P < .001$). When comparing the cast splint anchorage in the Class II:1 and Class II:2 malocclusions, no group differences were found for lower incisor movements ([Figures 5–7](#)).

The lower first molars also moved anteriorly more extensively in Class II:1 subjects with the cast splint anchorage than in subjects with the banded anchorage forms ($0.05 > P < 0.01$). When comparing the cast splint anchorage in the Class II:1 and Class II:2 malocclusions, no group difference was found for lower first molar movements.


First posttreatment period (T2–T3)

Recovery in incisor and molar position changes were seen in all Class II:1 cases. For the mandibular incisors a statistically significant difference existed between the banded premolar anchorage and the cast splint anchorage, and the lower incisors moved more posteriorly in subjects with the cast splint anchorage (1.3 mm; $P < .05$). No differences were found when comparing Class II:1 and Class II:2 malocclusions with the cast splint anchorage ([Figures 5–7](#)).

The lower first molars recovered in subjects of group B (mean = 0.7 mm, SD = 1.3 mm; ns) and group C (mean = 0.8 mm, SD = 1.6 mm; $P < .01$). In the cases with the banded premolar anchorage (group A), a continuous anterior movement of the lower molars was noted (mean = 0.9 mm, SD = 1.4 mm; $P < .05$). When comparing the cast splint appliance in the Class II:1 and Class II:2 malocclusions, the lower first molars moved more posteriorly in Class II:2 subjects (1.0 mm; $P < .05$).


Second posttreatment period (T3–T4)

In the Class II:1 malocclusions, lower incisor position in all three anchorage forms was almost stable. In the Class II:2 subjects, the

lower incisors moved more posteriorly (1.3 mm; $P < .001$) than in the Class II:1 subjects with a cast splint anchorage ([Figures 5–7](#) ) .


The lower first molars moved more anteriorly (0.7 mm; $P < .05$) in Class II:1 cases with the banded premolar anchorage than in cases with the cast splint anchorage. When comparing the cast splint appliance in the Class II:1 and Class II:2 malocclusions, the lower first molars moved anteriorly in Class II:1 subjects (mean = 0.2 mm, SD = 0.8 mm; $P < .01$) and posteriorly in Class II:2 subjects (mean = 0.8 mm, SD = 0.7 mm; ns). The group differences were significant (1.0 mm; $P < .001$).

Total posttreatment period (T2–T4)

The lower incisors moved more posteriorly in Class II:1 subjects with the cast splint anchorage (0.9 mm; $P < .05$) than in subjects with the banded premolar anchorage. When comparing the cast splint anchorage in the Class II:1 and Class II:2 malocclusions, the lower incisors moved more posteriorly in the Class II:2 cases (1.1 mm; $P < .05$) ([Figures 5–7](#) ) .

The lower first molars moved anteriorly in Class II:1 subjects with the banded premolar anchorage (mean = 1.4 mm, SD = 1.9 mm; $P < .01$) and posteriorly in Class II: 1 subjects with the cast splint anchorage (mean = 0.6 mm, SD = 1.9 mm; ns). The group difference was significant (2.0 mm; $P < .01$). When comparing the cast splint anchorage in the Class II:1 and Class II:2 malocclusions, the lower first molars were moved more posteriorly in the Class II:2 cases (1.4 mm; $P < .05$).

Total observation period (T1–T4)

The lower incisors retroclined insignificantly in the Class II:1 cases with the banded premolar anchorage (mean = 0.8°, SD = 3.6°; ns) and proclined significantly in the cast splint anchorage group (mean = 4.4°, SD = 6.0°; $P < .001$). The group differences were significant (5.2°; $P < .01$). When comparing the cast splint anchorage in the Class II:1 and Class II:2 subjects, no group differences could be found ([Figures 5–7](#) ) .

With regard to the lower first molars in the Class II:1 subjects, no statistically significant differences could be found between the three anchorage forms. When comparing the cast splint anchorage in the Class II:1 and Class II:2 malocclusions, the lower first molars moved anteriorly in the Class II:1 cases (mean = 1.8 mm, SD = 1.7 mm; $P < .001$) and posteriorly in the Class II:2 cases (mean = 0.1 mm, SD = 1.1 mm; ns). The group differences were significant (1.9 mm; $P < .001$).

DISCUSSION [Return to TOC](#)

As mentioned in the “Introduction” section, the measured changes in mandibular tooth movements during Herbst treatment were basically the results of an anchorage loss due to the anterior directed force exerted to the lower teeth by the telescope mechanism.^{[6–9](#)} A proclination of the lower incisors is generally not desired in Class II:1 subjects but often desired in Class II:2 subjects because this improves the incisal support, which is important for the stability of the vertical overbite correction in those cases.^{[4,10,11](#)}

Surprisingly, the new cast splint anchorage system was not superior to the original banded anchorage systems. On the contrary, during treatment, the incisor anchorage loss was largest in the cast splint anchorage group. A possible explanation is that the lower incisors were furnished with a labial archwire for tooth alignment, which caused an additional protrusion and proclination of these teeth.^{[6](#)}

It could be expected that the strains on the lower front teeth by the Herbst telescope mechanism would increase in relation to subject age and malocclusion severity, thus resulting in a larger anchorage loss. With respect to the age, this could be true because the subjects treated with the cast splint anchorage Herbst were on average somewhat older (age 14.4 years) than those treated with the banded premolar (age 12.2 years) and premolar-molar (age 13.2 years) anchorage Herbst. This would also be in agreement with an earlier Herbst study^{[12](#)} in which it was shown that incisor proclination (anchorage loss) was larger in patients treated in the postpubertal than in the prepubertal growth period. On the other hand, with respect to the severity of the malocclusion, no relationship seemed to exist between anchorage loss and the amount of pretreatment overjet and Class II molar relationship. These measures were comparable in the different anchorage groups of the Class II:1 subjects.

It is a fact that teeth that have been orthodontically moved tend to return to their former positions.^{[13–16](#)} In all anchorage forms, relapsing tooth movements after Herbst treatment were noted. The relapse in incisor position was more pronounced in the Class II:2 than in the Class II:1 malocclusions. This could be explained by a higher lip pressure (mentalis hyperactivity) to the front teeth in the Class II:2 group.^{[1,17–22](#)}

Nevertheless, in comparison with before treatment, four years after treatment the lower incisors still had a slight protruded and proclined position in all anchorage forms. This was certainly a result of further treatment or retention.

The relapse in molar position was more pronounced in the Class II:2 than in the Class II:1 malocclusions. Comparable with the mandibular incisors, this could be a consequence of the mentalis hyperactivity seen in the Class II: 2 cases. In subjects treated with the premolar anchorage, the anterior molar tooth movements occurred continuously during and after treatment.^{[6](#)} However, this is difficult to

explain because the premolar anchorage was the only one that the molars were not attached to the appliance. This could probably contribute to a continuous physiologic anterior movement of the molars.

The subjects treated with the cast splint anchorage had a subsequent multibracket treatment phase for about another year. Thereafter, retention was performed for one to two years with either a positioner or an activator in combination with a mandibular canine to canine retainer. Because 50% of the cases treated with the banded Herbst appliance were not retained at all, this could explain the larger relapse in incisor inclination seen in these subjects when compared with the cast splint Class II:1 subjects.

CONCLUSIONS [Return to TOC](#)

Mandibular anchorage loss in Herbst treatment is a reality with which the orthodontist has to live. Furthermore, against all expectations, the cast splint anchorage was not superior to the two banded anchorage forms.

REFERENCES [Return to TOC](#)

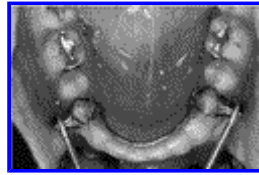1. Fletcher GGT. The retroclined upper incisors. *Br J Orthod.* 1975; 2:207–216. [[PubMed Citation](#)]
2. Pancherz H. Vertical dentofacial changes during Herbst appliance treatment. *Swed Dental J. Suppl.* 1982; 15:189–196. [[PubMed Citation](#)]
3. Paulsen HU. Morphological changes of the TMJ condyles in 100 patients treated with the Herbst appliance in the period of puberty to adult-hood: a long term radiographic study. *Eur J Orthod.* 1997; 19:657–668. [[PubMed Citation](#)]
4. Simons ME, Joondeph DR. Change in overbite: a ten-year post-retention study. *Am J Orthod.* 1973; 64:349–367. [[PubMed Citation](#)]
5. Wieslander L. Intensive treatment of severe Class II malocclusion with a headgear-Herbst appliance in the early mixed dentition. *Am J Orthod.* 1984; 86:1–13. [[PubMed Citation](#)]
6. Pancherz H, Hansen K. Mandibular anchorage in Herbst treatment. *Eur J Orthod.* 1988; 10:149–164. [[PubMed Citation](#)]
7. Pancherz H. Treatment of class II malocclusion by jumping the bite with the Herbst appliance. A cephalometric investigation. *Am J Orthod.* 1979; 76:423–442. [[PubMed Citation](#)]
8. Pancherz H. The mechanism of Class II correction in Herbst appliance treatment. *Am J Orthod.* 1982; 82:104–113. [[PubMed Citation](#)]
9. Pancherz H, Hansen K. Occlusal changes during and after Herbst treatment: a cephalometric investigation. *Eur J Orthod.* 1986; 8:215–228. [[PubMed Citation](#)]
10. Lagerström L. Tiefbißkorrektur in Angle Klasse II,2 Okklusionsanomalien. In: *Kieferorthopädie, Konzepte und Perspektiven*. München: ZMS-Verlag; 1980:129–136.
11. Pancherz H, Obijou C. Herbst appliance treatment of Class II, division 2 malocclusions. *Am J Orthod Dentofacial Orthop.* 1997; 112:287–291. [[PubMed Citation](#)]
12. Pancherz H, Hägg U. Dentofacial orthopedics in relation to somatic maturation. An analysis of 70 consecutive cases treated with the Herbst appliance. *Am J Orthod.* 1985; 88:273–287. [[PubMed Citation](#)]
13. Hansen K, Koutsonas T, Pancherz H. Long-term effects of Herbst treatment on the incisor segment: a cephalometric and biometric investigation. *Orthod Dentofacial Orthop.* 1997; 112:92–103. [[PubMed Citation](#)]
14. Litowitz RA. Study of movements of certain teeth during and following orthodontic treatment. *Angle Orthod.* 1948; 18:113–132.
15. Mills JRE. The long-term results of the proclination of lower incisors. *Br Dent J.* 1966; 120:355–363. [[PubMed Citation](#)]
16. Mills JRE. The stability of lower labial segment. *Trans Br Soc Orthod.* 1967; 54:11–24.
17. Fuhrmann R. *Kieferorthopädische Behandlung der Klasse II:2 Malokklusion. Nachuntersuchung von 17 Patienten unter besonderer Berücksichtigung der Unterlippenhöhe und der Bisshebung* [medical dissertation]. Homburg, Saar, Germany; 1989.
18. Luffingham JK. The lower lip and the maxillary central incisors. *Eur J Orthod.* 1982; 4:263–268. [[PubMed Citation](#)]
19. Mills JRE. The problem of overbite in Class II, division 2 malocclusion. *Br J Ortod.* 1973; 1:34–48.

20. Nicol WA. The lower lip and the upper incisor teeth in Angle's Class II, division 2 malocclusion. *Dent Pract.* 1963; 14:179–182.

21. Posen AL. The influence of maximum perioral and tongue force on the incisor teeth. *Angle Orthod.* 1972; 42:285–309. [[PubMed Citation](#)]

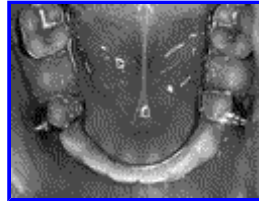22. Schweitzer M, Pancherz H. The incisor-lip relationship in Herbst/ multibracket appliance treatment of Class II, division 2 malocclusions. *Angle Orthod.* 2001; 71:358–363. [[PubMed Citation](#)]

FIGURES [Return to TOC](#)



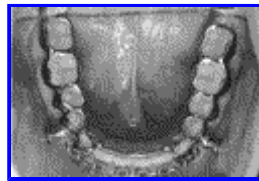Click on thumbnail for full-sized image.

FIGURE 1. Banded premolar anchorage



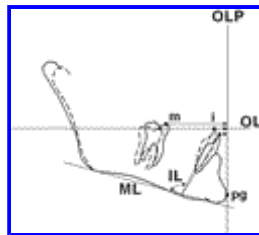
Click on thumbnail for full-sized image.

FIGURE 2. Banded premolar-molar anchorage




Click on thumbnail for full-sized image.

FIGURE 3. Cast splint anchorage




Click on thumbnail for full-sized image.

FIGURE 4. Measures of mandibular incisor and molar changes. The reference grid (occlusal line [OL] and the occlusal line perpendicular [OLP]) is shown




Click on thumbnail for full-sized image.

FIGURE 5. Average changes (mm) of the incisor movements. P II: 1 = premolar anchorage in 16 Class II:1 subjects; PM II:1 = premolar-molar anchorage in 19 Class II:1 subjects; S II:1 = cast splint anchorage in 34 Class II:1 subjects; S II:2 = cast splint anchorage in 18 Class II:2 subjects



Click on thumbnail for full-sized image.

FIGURE 6. Average changes (degrees) of the incisor inclination. P II:1 = premolar anchorage in 16 Class II:1 subjects; PM II:1 = premolar-molar anchorage in 19 Class II:1 subjects; S II:1 = cast splint anchorage in 34 Class II:1 subjects; S II:2 = cast splint anchorage in 18 Class II:2 subjects



Click on thumbnail for full-sized image.

FIGURE 7. Average changes (mm) of the molar movements. P II:1 = premolar anchorage in 16 Class II:1 subjects; PM II:1 = premolar-molar anchorage in 19 Class II:1 subjects; S II:1 = cast splint anchorage in 34 Class II:1 subjects; S II:2 = cast splint anchorage in 18 Class II:2 subjects

^aAssistant Professor, Department of Orthodontics, University of Giessen, Giessen, Germany

^bProfessor and Head, Department of Orthodontics, University of Giessen, Giessen, Germany

Corresponding author: Dominique Weschler, DDS, Dr Med Dent, Department of Orthodontics, University of Giessen, Schlangenzahl 14, Giessen, Hessen 35392, Germany (E-mail: dominique.weschler@dentist.med.uni-giessen.de)