

[\[Print Version\]](#)

[\[PubMed Citation\]](#) [\[Related Articles in PubMed\]](#)

## TABLE OF CONTENTS

[\[INTRODUCTION\]](#) [\[MATERIALS AND...\]](#) [\[RESULTS\]](#) [\[DISCUSSION\]](#) [\[CONCLUSIONS\]](#) [\[REFERENCES\]](#) [\[TABLES\]](#) [\[FIGURES\]](#)

*The Angle Orthodontist*: Vol. 75, No. 1, pp. 28-34.

# Early Predictive Variables for Upper Canine Impaction as Derived from Posteroanterior Cephalograms

Sergio Sambataro, DDS, MS;<sup>a</sup> Tiziano Baccetti, DDS, PhD;<sup>b</sup> Lorenzo Franchi, DDS, PhD;<sup>c</sup> Filippo Antonini, DDS<sup>d</sup>

## ABSTRACT

The aim of this study was to identify a model of cephalometric variables for early diagnosis of the displacement of upper permanent canine and early prognosis of upper canine impaction. Posteroanterior (PA) cephalograms of 43 subjects (22 males and 21 females) with different types of malocclusions in the mixed dentition were analyzed at the time of first observation (mean age 8 years and 5 ± 9 months). All subjects were reevaluated at the mean age of 14.3 years. At this time the sample was divided into 2 groups according to the presence of canine impaction: nonimpacted canine group (31 subjects) and impacted canine group (12 subjects). Stepwise variable selection on the measurements at the time of first observation identified 2 predictive variables on PA cephalograms, ie, the distance between the center of the canine crown and the midsagittal plane (A3cc to Cg Vertical) and the distance between the jugal process and the midsagittal plane (J to Cg Vertical). The closer the canine crowns to the midsagittal plane and the larger the posterior portion of the hemimaxilla, the higher the probability of canine impaction. Discriminant analysis assigned a classification power of 95.3% to the predictive model. On the basis of the equation generated by the multivariate statistical method, impaction of the maxillary canine for each new case at the age of 8 years can be predicted. The importance of PA cephalograms in the diagnosis and prediction of canine eruption disturbances is emphasized.

**KEY WORDS:** Canine impaction, Palatally displaced canines, Posteroanterior cephalometrics, Discriminant analysis.

Accepted: February 2004. Submitted: January 2004

## INTRODUCTION [Return to TOC](#)

The maxillary canine is second only to the mandibular third molar in its frequency of impaction, with a rate that varies from less than 0.8% to 2.8%.<sup>1</sup> Dachi and Howell<sup>2</sup> pointed out that the condition is more than twice as common in girls as in boys. Canine impaction has been found on the palate in 85% of the cases and to the buccal in 15%.<sup>3-5</sup> It is estimated that 8% of all patients with maxillary impacted canines have bilateral impaction.<sup>6</sup>

Two major theories have been delineated to explain the occurrence of palatal impaction of maxillary canines, ie, the "guidance" theory and the "genetic" one.<sup>6,7-21</sup> The guidance theory<sup>11-14</sup> refers to an excess of space in the apical region of the maxillary bone during the eruption pathway of the permanent canine, owing to either hypoplasia or aplasia of the upper lateral incisors. The displaced canine lacks the "guide" represented by the roots of the neighboring teeth, thus suggesting the predominance of local reasons for the anomaly in the

position of the tooth bud. Crowding may also play a role as an environmental cause of impaction, although arch length deficiency is associated primarily with buccal canine impaction.<sup>15</sup> According to the genetic theory, palatally displaced canines are assigned to a complex of genetically determined tooth anomalies resulting from a developmental disturbance of the dental lamina.<sup>6,16–21</sup> The associated dental features (including aplasia and small size of the lateral incisors) allow for an early clinical diagnosis of the eruption disturbance.<sup>22–27</sup> Familial recurrence of canine impaction has been reported as well.<sup>28,29</sup>

One of the fundamental aspects in the diagnosis and treatment planning of a complex tooth anomaly such as the impaction of the permanent maxillary canine is the ability to recognize the tooth displacement early and to predict the subsequent failure of eruption. “Early” in biology is often considered as occurring before the usual or physiological time.<sup>30</sup> The average age when an upper canine should erupt is 13 years in boys and 12 years and 3 months in girls.<sup>31</sup> So, the ability to diagnose tooth malposition as early as in the early mixed dentition (average age of 8 years) and to predict impaction of the canine in the same time period would be extremely useful for the clinician.

The main diagnostic tools that have been proposed to assess the probability of canine impaction in the individual patient relate both to spatial relationships of the tooth to the surrounding dentofacial structures, and to the associated features of the dentition, with special regard to concurrent dental anomalies. Baccetti<sup>22</sup> demonstrated that palatal displacement of maxillary canines is associated with the early recognition of other tooth disturbances in the individual patient, such as small size of the upper lateral incisors, enamel hypoplasia, aplasia of second premolars, and infraocclusion of primary molars.

The early diagnosis of canine displacement in relation to the surrounding structures is based primarily on radiographic examination. At the age of 8 years the clinical examination does not give any useful information on the high position of the tooth in the bone. Ericson and Kuroi<sup>5,32</sup> studied a sample of children aged 10–13 years and proposed the diagnosis on the panoramic film, which can be defined as “moderately” early. Further, the final observation in the sample investigated by Ericson and Kuroi included the therapeutic effects of an interceptive approach such as the extraction of the deciduous canine. The authors found that the more mesially located the crown of the canine in the panoramic film, the more reduced the likelihood of canine eruption. Lindauer et al<sup>33</sup> used a control group to propose a method to predict canine impaction with a precision of 78% through a modification of the procedure by Ericson and Kuroi.<sup>32</sup> According to Fernandez et al<sup>34</sup> the overlapping of the canine and the lateral incisor in panoramic radiographs when the incisor has completed its development can be considered as a sign of a possible eruptive anomaly of the canine at an early stage. A recent study<sup>35</sup> investigated angulations of unerupted canines in relation to the bicondylar plane measured from panoramic radiographs in addition to sector location of the tooth (in relation to overlapping of the lateral incisor) and concluded that sector location was a significantly better predictor of impaction than tooth angulation.

Other radiographic techniques that are routinely used for orthodontic diagnosis such as lateral and frontal cephalograms can offer additional information for evaluation of upper canine displacement and, eventually, for prediction of canine impaction.<sup>5,36–41</sup> The lateral headfilm may give information on the vertical and sagittal position of the tooth, particularly the relationship of the upper canine to other facial structures (maxillary sinus and floor of the nose). According to Orton et al,<sup>38</sup> the lateral cephalogram also offers information about 3 aspects of unerupted maxillary canines: (1) inclination of the tooth axis, (2) height of the unerupted canine tip relative to the occlusal plane, and (3) sagittal position of unerupted canines relative to the incisor roots. The authors define an ideal axial eruptive path of 10° of labial tipping relative to Frankfort horizontal. Small increases in forward tipping give a sharp worsening in prognosis when combined with midline displacement.

Ricketts et al<sup>39</sup> suggested that the posteroanterior (PA) headfilm could help the clinician to diagnose upper canine displacement early. He described the position of the upper canine at the age of 8 years as straight and lateral to the nasal cavity and pointed out that some parameters on the frontal headfilm (intercanine width, canine position, canine angulation, size of the follicle, symmetry and width of the nasal cavity) might be associated with increased probability of upper canine impaction.<sup>30</sup> In the absence of a cuspid bulge at the age of 8 years, Williams<sup>40</sup> advocated the use of oriented lateral and frontal radiographs at 6-month intervals after removal of the deciduous canine to follow the intraosseous eruptive movement of the permanent canine until the tooth has erupted in the oral cavity. In a longitudinal study from the age of 5 years through 15 years on annual lateral and PA cephalograms, McSherry and Richardson<sup>41</sup> found that the differences in the growth of normal and ectopic canines in the lateral plane of space can be detected as early as 5–6 years of age. To date, no study has been performed to analyze the possibility of predicting impaction of the maxillary permanent canine on the basis of measurements performed on frontal cephalograms at an early developmental stage.

The aim of this study, therefore, was to investigate whether any dentoskeletal characteristics in the early mixed dentition, as derived from frontal headfilms, can be used as predictive variables for upper canine impaction.

## MATERIALS AND METHODS [Return to TOC](#)

A parent sample of 78 subjects with various types of dentofacial relationships was selected from the files of the Department of Orthodontics at the University of Florence, based on the presence of frontal headfilms in the patients' records. Patients with syndromes and cleft palate were excluded (n = 13). A group of 12 patients were excluded further because of poor-quality frontal headfilms. The final sample comprised 43 subjects, 22 male and 21 female, in the mixed dentition, with mean age 8 years and 5 months and skeletal age corresponding to a prepubertal stage (CVMS I) as assessed on lateral cephalograms of the examined subjects according to the cervical

The cephalometric analysis on PA films was the one proposed by Ricketts,<sup>44</sup> with a modification that eliminated the mandibular measurements. Cephalometric variables were limited to transverse measurements because these are least affected by postural alterations of the head during radiographic registration.

The following skeletal and dental landmarks and lines were used ([Figure 1](#) ):

Cranial landmarks—Za (zygomatic arch), center of the zygomatic arch; Cg (crista galli), tip of the structure.

Maxillary landmarks—Nc (nasal cavity), most lateral margin of the nasal cavity; J (jugal process), crossing on the zygomatic process of the maxilla with the outline of the tuberosity; ANS (anterior nasal spine), center of the hard palate at the junction with the septum.

Dental landmarks—UI (upper interincisal point); A6L and A6R (upper molar left and right), the buccalmost point on the crowns of the upper first molars; A3Lcc and A3Rcc (upper canine left/right crown center), defined as the intersection between the 2 maximal diameters of the canine crown.

Reference lines—Za-Za, frontal Frankfort plane; Cg-Vertical, a perpendicular line dropped through frontal Frankfort from crista galli, representing the midsagittal plane.

The following linear measurements were performed: Nc to Nc, width of the nasal cavity; NcL/R to Cg Vertical, width of the heminasal cavity; J to J, width of the maxilla; JL/R to Cg Vertical, width of the hemimaxilla; ANS to Cg Vertical, symmetry of the maxilla; A6L to A6R, upper intermolar width; UI to Cg Vertical, symmetry of the upper dental arch; A3ccL to A3ccR, upper intercanine width; A3ccL/R to Cg Vertical, distance of the upper left/right canine to the sagittal plane; A3ccL/R to NcL/R, distance of the upper left/right canine to the left/right nasal cavity; A3ccL/R to JL/R, distance of the upper left/right canine to the left/right maxilla; A6L/R to A3ccL/R, distance of the upper left/right canine to the left/right upper molar.

The following angular measurement was performed: A3L/R long axis to Za-Za, angulation of the upper left/right canine to the frontal Frankfort plane.

All subjects were reevaluated at a second observation (mean age 14 years and 3 months) after a mean period of 5 years and 11 months, during which they did not receive any specific orthodontic treatment. Based on both clinical and radiographic examination, the sample was split into 2 groups: the first group comprised 31 subjects (16 boys and 15 girls) who had experienced a normal eruption of upper maxillary canines (nonimpacted canine [NIC] group). The remaining 12 subjects (6 boys and 6 girls) presented with unilateral impaction of upper canines (impacted canine [IC] group). Canine impaction was diagnosed when the tooth was unerupted after complete root development and when the contralateral canine was fully erupted.

### Data analysis

The assessment of the method error for the cephalometric measurements was performed with the Dahlberg formula<sup>45</sup> on measures repeated on 15 subjects (10 subjects of the NIC group and 5 subjects of the IC group) selected randomly from the 2 groups. The measurement error for the linear measurements was on average 0.49 mm (range 0.30–0.66 mm), and it was 1.8° for the angular measurement.

The limited number of subjects in the 2 groups required assessment of normality for data distribution. Shapiro-Wilk's test was used and revealed normal distribution of the measures in both the NIC and the IC groups at the time of first observation. Independent samples *t*-test was performed between the 2 groups at the time of first observation.

Discriminant analysis was applied to cephalometric values of the 43 subjects at the time of first observation. Discriminant analysis is a multivariable statistical technique that is specifically designed to separate as widely as possible 2 groups of subjects taken from the same population.<sup>46</sup> The aim of this analysis is to provide a method to forecast which group a new case is most likely to fall into. To arrive at the best model for discrimination, the first phase of the analysis was to select those variables that were most important for group separation between the NIC and the IC groups. Forward selection procedure with *F*-to-enter and *F*-to-remove equal to 4 was chosen.<sup>47</sup> When the smallest set of significant discriminant variables was selected, predictive power (classification power of the model) was tested using discriminant analysis. Nonstandardized discriminant function coefficients were calculated for each previously selected variable, along with a constant.<sup>47</sup> This leads to an equation that assigns a score to each patient. A mean score for each of the 2 groups is given. Halfway between these scores is the dividing value (critical score), which establishes to which of the 2 groups an individual case belongs.<sup>48</sup>

### RESULTS [Return to TOC](#)

Descriptive statistics along with the results of independent sample *t*-test between NIC and IC groups at the time of first observation are

Stepwise variable selection generated a 2-variable model that produced the most efficient separation between the 2 groups (NIC group vs IC group). The variables selected were the distance between the center of the canine crown and the midsagittal plane (A3cc to Cg Vertical) and the distance between the jugal process and the midsagittal plane (J to Cg Vertical). The classification power of the selected 2-variable model was 95.3%. Only 2 cases were not classified correctly.

Unstandardized discriminant function coefficients of the selected variables, along with a calculated constant, lead to the following equation that provides individual scores for the assignment of a new case to either the NIC group or the IC group:

$$\text{individual score} = [\text{A3cc to Cg Vertical} (0.883)] - [\text{J to Cg Vertical} (0.345)] - 1.039.$$

The critical score (ie, the value dividing the NIC group from IC group) was  $-0.565$ , which is the mean value of the group centroids of the 2 groups ( $0.621$  for the NIC group and  $-1.751$  for the IC group). If the individual score is more negative than the critical score at the age of 8 years, the upper canine will be impacted. On the contrary, if the individual score is greater than the critical score (or a positive number) at the age of 8 years, the upper canine will erupt physiologically. Both predictions can be made with a probability of error of about 5%.

## DISCUSSION [Return to TOC](#)

Treating impacted palatal canines usually involves surgery plus orthodontic therapy to place the tooth in its correct position.<sup>49</sup> These procedures offer a high success rate in adolescents but involve substantial time and cost. They also increase the risk of gingival recession, bone loss, and detached gingiva around the treated canine.<sup>50</sup> A series of interceptive treatment options are available to approach palatally displaced canines and to prevent final impaction. For instance, a relatively high percentage of palatally displaced canines can be driven to normal eruption by means of extraction of deciduous canines in association with space maintenance at the upper arch.<sup>51</sup> These methods, however, follow a diagnosis of canine displacement that is immediately antecedent to the diagnosis of canine impaction. It appeared desirable, therefore, to identify a method that would provide the clinician with an earlier tool for both the diagnosis of canine displacement and the prediction of subsequent canine impaction.

The panoramic film has been used extensively for the identification of diagnostic parameters aimed at interceptive treatment planning,<sup>5,31-33</sup> but it unfortunately presents with considerable distortion in the frontal portion of the dentoalveolar regions. Historically, a lack of interest and experience combined with difficulty in attaining consistent orientation of the head in the head holder at the time of exposure has limited the progress of the frontal analysis.<sup>52,53</sup> On the contrary, when performed adequately, PA radiography is able to provide valuable information about the spatial characteristics of the dentoskeletal region. When the patient's head rests against the film, the frontal headfilm presents the anterior area of the face with a minimal amount of distortion. In the frontal headfilm it is easy to identify the position of the canine and its relationship with proximal teeth, the nasal cavity, and the palate.

The aim of the present study was to identify predictive variables for canine impaction on the frontal headfilm in the early mixed dentition phase (at approximately 8 years of age). Discriminant analysis indicated that the larger the hemimaxilla, and the closer the canine crown to the midsagittal plane in the frontal headfilm, the higher the probability of palatal displacement and eventual impaction of the canine in the corresponding side of the dental arch ([Figure 2a-c](#)). The probability of error is slightly less than 5%.

The existence of a normal maxillary arch width in cases with canine impaction had been pointed out by Langberg and Peck.<sup>54</sup> From an etiological point of view the results of the present study, in addition to the ones by Langberg and Peck,<sup>54</sup> confute the role of deficiency in maxillary width as a local mechanical cause of the palatally displaced canines. On the contrary, this theory had been supported by McConnell et al,<sup>55</sup> who used dental measurements to define transverse deficiency.

A recent study by Warford et al<sup>35</sup> investigated angulations and sector location of unerupted canines as measured from panoramic radiographs and concluded that sector location was the best predictor for canine impaction. Measurements for angulation of the canine in relation to reference lines entail a much smaller predictive power.<sup>35</sup> Also, according to the results of the present study, the distance of the canine crown in relation to the midsagittal plane appears to be a crucial factor for the early prediction of canine impaction. The closer the canine crown is to the midfrontal line at the age of 8 years, the higher the probability of eruption disturbance. However, discriminant analysis indicated that the distance of the canine crown to the midline can serve as a reliable predictor only when combined with information pertaining to the width of the maxilla on the side examined.

The proposed method for early identification of subjects susceptible to canine impaction based on radiographic parameters might be complemented advantageously by the early recognition of morphological "risk signs" for canine impaction. It has been demonstrated that a series of concomitant tooth disturbances in the individual patient (small size of upper lateral incisors, enamel hypoplasia, aplasia of second premolars, and infraocclusion of primary molars) can be regarded as factors for an increased prevalence rate of canine impaction.<sup>16,18,22-28</sup> Further, because of the additional radiation exposure, the use of the frontal X-ray could be recommended primarily in those subjects showing tooth anomalies that are recognized as associated with a higher prevalence of canine impaction.

From a clinical point of view the role of the prognosis of canine impaction represented by a deficiency in the distance between the crown of the canine and the midsagittal plane, in the absence of a deficiency in the posterior width of the maxilla, suggests the use of techniques to widen the anterior part of the maxilla without increasing the posterior part of the upper jaw, if not needed for other therapeutical purposes. Methods to expand the palate at an early age in a sectorial way (such as a specifically activated quad-helix or rapid maxillary expanders incorporating a “fan” screw) could be viable options.

## CONCLUSIONS [Return to TOC](#)

The identification of early predictive variables for canine impaction in a sample of orthodontic patients was performed by means of discriminant analysis on cephalometric variables derived from PA films. Two predictive measurements were selected, ie, the distance from the center of the crown of the upper permanent canine to the midsagittal plane and the transverse width of the maxilla on the same side of the evaluated canine. The closer the canine crowns to the midsagittal plane and the larger the posterior portion of the hemimaxilla, the higher the probability of canine impaction. The classification power of the model for the prediction of canine impaction is 95.3% for each new individual case. The method provided the clinician with a diagnostic and prognostic tool to identify eruption disturbances of the upper canine at an early developmental stage.

## ACKNOWLEDGMENTS

The authors wish to thank Prof Isabella Tollaro for providing access to patients' records and Prof Mario Caltabiano for scientific support. This article is dedicated to the memory of Prof Robert M. Ricketts.

## REFERENCES [Return to TOC](#)

1. Shah RM, Boyd MA, Vakil TF. Studies of permanent tooth anomalies in 7886 Canadian individuals. *J Can Dent Assoc.* 1978; 44:262–264.
2. Dachi SF, Howell FV. A survey of 3874 routine full mouth radiographs. *Oral Surg Oral Med Oral Pathol.* 1961; 14:1165–1169. [[PubMed Citation](#)]
3. Hitchin AD. The impacted maxillary canine. *Br Dent J.* 1956; 100:1–14.
4. Rayne J. The unerupted maxillary canine. *Dent Pract.* 1969; 19:194–204.
5. Ericson S, Kurol J. Radiographic examination of ectopically erupting maxillary canines. *Am J Orthod Dentofacial Orthop.* 1987; 91:483–492. [[PubMed Citation](#)]
6. Peck S, Peck L, Kataja M. Site-specificity of tooth maxillary agenesis in subjects with canine malpositions. *Angle Orthod.* 1996; 66:473–476. [[PubMed Citation](#)]
7. Bishara SE. Impacted maxillary canines: a review. *Am J Orthod Dentofacial Orthop.* 1992; 101:159–171. [[PubMed Citation](#)]
8. Jacobs SG. Reducing the incidence of unerupted palatally displaced canines by extraction of deciduous canines. The history and application of this procedure with some case reports. *Aust Dent J.* 1998; 43:20–27. [[PubMed Citation](#)]
9. Jacoby H. The etiology of maxillary canine impactions. *Am J Orthod Dentofacial Orthop.* 1983; 84:125–132.
10. McSherry PF. The ectopic maxillary canine: a review. *Brit J Orthod.* 1998; 25:209–216. [[PubMed Citation](#)]
11. Becker A, Sharabi S, Chaushu S. Maxillary tooth size variation in dentitions with palatal canine displacement. *Eur J Orthod.* 2002; 24:313–318. [[PubMed Citation](#)]
12. Becker A. Ectopic eruption of maxillary canines. *Eur J Orthod.* 1993; 15:425 [[PubMed Citation](#)]
13. Becker A. In defense of the guidance theory of palatal canine displacement. *Angle Orthod.* 1995; 65:95–98. [[PubMed Citation](#)]
14. Becker A. Etiology of maxillary canine impaction. Letters to the editor. *Am J Orthod Dentofacial Orthop.* 1984; 86:437–438.
15. Langberg BJ, Peck S. Adequacy of maxillary dental arch width in patients with palatally displaced canines. *Am J Orthod Dentofacial Orthop.* 2000; 118:220–223. [[PubMed Citation](#)]
16. Baccetti T. A clinical and statistical study of etiologic aspects related to associated tooth anomalies in number, size, and position. *Minerva Stomatol.* 1998; 47:655–663.

17. Peck S, Peck L, Kataja M. Sense and nonsense regarding palatal canines. *Angle Orthod.* 1995; 65:99–102. [[PubMed Citation](#)]
18. Peck S, Peck L, Kataja M. Concomitant occurrence of canine malposition and tooth agenesis: evidence of orofacial genetic fields. *Am J Orthod Dentofacial Orthop.* 2002; 122:657–660. [[PubMed Citation](#)]
19. Pirinen S, Arte S, Apajalahti S. Palatal displacement of canine is genetic and related to congenital absence of teeth. *J Dent Res.* 1996; 75:1742–1746. [[PubMed Citation](#)]
20. Vastardis H. The genetics of human tooth agenesis. New discoveries for understanding dental anomalies. *Am J Orthod Dentofacial Orthop.* 2000; 117:650–656. [[PubMed Citation](#)]
21. Leonardi R, Peck S, Caltabiano M, Barbato E. Palatally displaced canine anomaly in monozygotic twins. *Angle Orthod.* 2003; 73:466–470. [[PubMed Citation](#)]
22. Baccetti T. A controlled study of associated dental anomalies. *Angle Orthod.* 1998; 68:267–274. [[PubMed Citation](#)]
23. Leifert S, Jonas IE. Dental anomalies as microsymptom of palatal canine displacement. *J Orofac Orthop.* 2003; 64:108–120.
24. Brenchley Z, Oliver RG. Morphology of anterior teeth associated with displaced canines. *Br J Orthod.* 1997; 24:41–45. [[PubMed Citation](#)]
25. Mossey PA, Campbell HM, Luffingham JK. The palatal canine and the adjacent lateral incisor: a study of a west of Scotland population. *Br J Orthod.* 1994; 21:169–174. [[PubMed Citation](#)]
26. Oliver RG, Mannion JE, Robinson JM. Morphology of the maxillary lateral incisor in cases of unilateral impaction of the maxillary canine. *Br J Orthod.* 1989; 16:9–16. [[PubMed Citation](#)]
27. Stahl F, Grabowski R. Maxillary canine displacement and genetically determined predisposition to disturbed development of the dentition. *J Orofac Orthop.* 2003; 64:167–177.
28. Svinhufvud E, Myllarniemi S, Norio R. Dominant inheritance of tooth malpositions and their association to hypodontia. *Clin Genet.* 1988; 34:373–381. [[PubMed Citation](#)]
29. Zilberman Y, Cohen B, Becker A. Familial trends in palatal canines, anomalous lateral incisors, and related phenomena. *Eur J Orthod.* 1990; 12:135–139. [[PubMed Citation](#)]
30. Ricketts RM. *Orthodontic Treatment in the Growing Patient. Vol. I.* Scottsdale, Ariz: American Institute for Bioprogressive Education; 1998:16–21.
31. Hurme V. Range of normalcy in the eruption of permanent teeth. *J Dent Child.* 1949; 16:11–15.
32. Ericson S, Kuroi J. Early treatment of palatally erupting maxillary canines by extraction of primary canines. *Eur J Orthod.* 1988; 10:283–295. [[PubMed Citation](#)]
33. Lindauer SJ, Rubenstein LK, Hang WM, Clark Andersen W, Isaacson RJ. Canine impaction identified early with panoramic radiographs. *J Am Dent Assoc.* 1992; 123:91–97.
34. Fernandez E, Bravo LA, Canteras M. Eruption of the permanent upper canine: a radiologic study. *Am J Orthod Dentofacial Orthop.* 1998; 113:414–420. [[PubMed Citation](#)]
35. Warford JH Jr, Grandhi RK, Tira DE. Prediction of maxillary canine impaction using sectors and angular measurement. *Am J Orthod Dentofacial Orthop.* 2003; 124:651–655. [[PubMed Citation](#)]
36. Langland OE, Francis SH, Langlois RD. *Textbook of Dental Radiology.* Springfield, Ill: Charles C Thomas; 1994.
37. Turk MH, Katzenell J. Panoramic localization. *Oral Surg Oral Med Oral Pathol.* 1970; 29:212–215. [[PubMed Citation](#)]
38. Orton HS, Garvey MT, Pearson MH. Extrusion of the ectopic maxillary canine using a lower removable appliance. *Am J Orthod Dentofacial Orthop.* 1995; 107:349–359. [[PubMed Citation](#)]
39. Ricketts RM, Bench RW, Hilgers JJ, Schulhof R. An overview of computerized cephalometrics. *Am J Orthod Dentofacial Orthop.* 1972; 61:1–28.
40. Williams BH. Diagnosis and prevention of maxillary cuspid impaction. *Angle Orthod.* 1981; 51:30–40. [[PubMed Citation](#)]

41. McSherry P, Richardson A. Ectopic eruption of the maxillary canine quantified in three dimensions on cephalometric radiographs between the ages of 5 and 15 years. *Eur J Orthod.* 1999; 21:41–48. [[PubMed Citation](#)]
42. Baccetti T, Franchi L, McNamara JA Jr. An improved version of the cervical vertebral maturation (CVM) method for the assessment of mandibular growth. *Angle Orthod.* 2002; 72:316–323. [[PubMed Citation](#)]
43. Baccetti T, Franchi L, McNamara JA Jr. The cervical vertebral maturation method: some need for clarification. *Am J Orthod Dentofacial Orthop.* 2003; 123:19A–20A.
44. Ricketts RM. *Progressive Cephalometrics. Paradigm 2000.* Scottsdale, Ariz: American Institute for Bioprogressive Education; 1998:26–29.
45. Dahlberg G. *Statistical Methods for Medical and Biological Students.* New York, NY: Interscience Publication; 1940.
46. Norusis MJ. *SPSS/PC+Advanced Statistics V2.0.* Chicago, Ill: SPSS; 1988:B1–B39.
47. Statistical Graphics Corporation. *Statgraphics. Ver. 2.6.* Rockville, Md: STSC; 1987.
48. Battagel J. Discriminant analysis: a model for the prediction of relapse in class III children treated orthodontically by non-extraction technique. *Eur J Orthod.* 1993; 15:199–209. [[PubMed Citation](#)]
49. Bishara SE, Kommer DD, McNeil MH, Montagano LN, Oesterle LJ, Youngquist HW. Management of impacted canines. *Am J Orthod Dentofacial Orthop.* 1976; 69:371–387.
50. Wisth PJ, Norderval K, Boe OE. Periodontal status of orthodontically treated impacted maxillary canines. *Angle Orthod.* 1976; 46:69–76. [[PubMed Citation](#)]
51. Leonardi M, Armi P, Baccetti T, Franchi L. Two interceptive approaches to palatally displaced canines. A prospective longitudinal study. *Angle Orthod.* In press.
52. Ricketts RM. The value of cephalometrics and computerized technology. *Angle Orthod.* 1972; 42:179–199. [[PubMed Citation](#)]
53. Ricketts RM. A foundation for cephalometric communication. *Am J Orthod Dentofacial Orthop.* 1960; 41:330–357.
54. Langberg BJ, Peck S. Adequacy of maxillary dental arch width in patients with palatally displaced canines. *Am J Orthod Dentofacial Orthop.* 2000; 118:220–223. [[PubMed Citation](#)]
55. McConnell TL, Hoffman DL, Forbes DP, Janzen EK, Weintraub NH. Maxillary canine impaction with transverse maxillary deficiency. *ASDC J Dent Child.* 1996; 63:190–195.

---

**TABLES** [Return to TOC](#)

**TABLE 1.** Descriptive Statistics and Independent Sample *t*-Test of the Two Groups (NIC and IC) at T1<sup>a</sup>

Variables	NIC ( <i>n</i> = 31)		IC ( <i>n</i> = 12)		Significance
	Mean	SD	Mean	SD	
Nc to Nc (mm)	25.8	1.6	24.9	2.4	NS
NcL/R to Cg Vertical (mm)	12.3	.8	11.5	1.1	*
J to J (mm)	61.0	3.0	60.4	3.9	NS
JL/R to Cg Vertical (mm)	30.5	1.6	30.1	2.5	NS
ANS to Cg Vertical (mm)	1.6	.9	.5	.8	NS
A6L to A6R (mm)	56.3	3.2	55.3	3.3	NS
UI to Cg Vertical (mm)	-.2	1.1	.0	.9	NS
A3ccL to A3ccR (mm)	27.4	1.9	23.5	2.2	***
A3ccL/R to Cg Vertical (mm)	13.8	1.4	10.8	1.3	***
A3ccL/R to NcL/R (mm)	1.0	1.2	-1.2	1.3	***
A3ccL/R to JL/R (mm)	16.8	1.5	18.9	2.0	**
A6L/R to A3ccL/R (mm)	14.5	1.7	16.0	2.0	*
A3L/R long axis ^ Za-Za (°)	98.3	5.4	98.3	4.2	NS

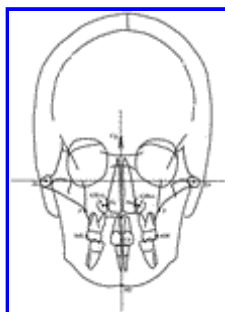
\* NIC indicates nonimpaction canine; IC, impaction canine; Nc, nasal cavity; Cg, Crista galli; J, jugal process; ANS, anterior nasal spine; NS, not significant; and Za, Zygomatic arch.

\*,  $P < 0.05$ .

\*\*,  $P < 0.01$ .

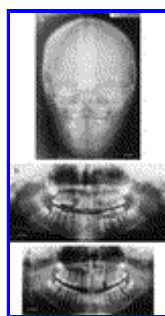
\*\*\*,  $P < 0.001$ .

## FIGURES [Return to TOC](#)



Click on thumbnail for full-sized image.

**FIGURE 1.** Cephalometric landmarks and reference lines



Click on thumbnail for full-sized image.

**FIGURE 2.** (a) MF, female, 8 years and 7 months. Individual score for upper right canine = 0.628; predicted group: nonimpaction. Individual score for upper left canine = -3.541; predicted group: impaction. (b) MF, female, 8 years and 7 months. Panoramic X-ray: right and left upper canines show a very similar eruption pathway. (c) MF, female, 13 years and 8 months. Panoramic X-ray: upper left canine is palatally impacted; upper right canine has erupted physiologically

<sup>a</sup>PhD student, Department of Orthodontics, The University of Catania, Catania, Italy

<sup>b</sup>Assistant Professor, Department of Orthodontics, The University of Florence, Florence, Italy; Thomas M. Graber Visiting Scholar, Department of Orthodontics and Pediatric Dentistry, School of Dentistry, The University of Michigan, Ann Arbor, Mich

<sup>c</sup>Research Associate, Department of Orthodontics, The University of Florence, Florence, Italy; Thomas M. Graber Visiting Scholar,



<sup>d</sup>PhD student, Department of Orthodontics, The University of Florence, Florence, Italy

Corresponding author: Tiziano Baccetti, DDS, PhD, Università degli Studi di Firenze, Via del Ponte di Mezzo, 46-48, 50127 Firenze, Italy  
(E-mail: [t.baccetti@odonto.unifi.it](mailto:t.baccetti@odonto.unifi.it))