

[\[Print Version\]](#)  
[\[PubMed Citation\]](#) [\[Related Articles in PubMed\]](#)

## TABLE OF CONTENTS

[\[INTRODUCTION\]](#) [\[MATERIALS AND...\]](#) [\[RESULTS\]](#) [\[DISCUSSION\]](#) [\[CONCLUSIONS\]](#) [\[REFERENCES\]](#) [\[TABLES\]](#) [\[FIGURES\]](#)

*The Angle Orthodontist*: Vol. 75, No. 3, pp. 305-310.

# Mandibular Asymmetry in Adult Patients with Unilateral Degenerative Joint Disease

Panagiotis Kamyblafkas;<sup>a</sup> Stephanos Kyrkanides;<sup>b</sup> Ross H. Tallents<sup>c</sup>

## ABSTRACT

The purpose of this study was to evaluate the association between unilateral degenerative joint disease (UDJD) and lower facial asymmetry. Twenty symptomatic patients and 20 asymptomatic volunteers were studied. Posteroanterior radiographs and bilateral mandibular laminographs were used to evaluate lower face and mandibular asymmetry. The two-way analysis of variance test was used to compare the groups. The posteroanterior radiographs did not reveal vertical asymmetry for the patients. The group with the left side affected exhibited deviation of the mandibular dental midline, the menton, and the antinion toward the affected side. The laminographs of the same group revealed decreased condylar height and increased antinion notching in the affected side. The results suggest that subjects with UDJD may manifest lower face asymmetry. This can be of clinical value when adult patients exhibiting asymmetry are to be treated.

**KEY WORDS:** Frontals, Degenerative joint disease, Temporomandibular joint, Asymmetries.

Accepted: June 2004. Submitted: January 2004

## INTRODUCTION [Return to TOC](#)


Various pathological conditions that affect the temporomandibular joint (TMJ) can manifest themselves as facial asymmetries, including congenital disorders such as hemifacial microsomia,<sup>1-3</sup> condylar hyperplasia,<sup>4,5</sup> internal derangements (ID),<sup>6,7</sup> rheumatoid arthritis,<sup>8,9</sup> and osteoarthritis.<sup>9-13</sup> Osteoarthritis or degenerative joint disease (DJD) is primarily a noninflammatory disorder of diarthrodial joints characterized by deterioration and abrasion of the articular cartilage and the underlying bone.<sup>14,15</sup>

A potential relationship between TMJ-ID and facial growth aberrations resulting in mandibular asymmetry or retrognathia has been previously suggested.<sup>10,16,17</sup> Although the etiology of skeletal asymmetry is not well understood, it has been suggested that advanced joint degeneration may lead to shortening of the condyle with subsequent skeletal asymmetry.<sup>10,18</sup> Inui et al<sup>17</sup> studied facial asymmetry on frontal cephalometric radiographs in adult female patients (mean age = 23.6) with signs or symptoms of TMJD and reported that the degree of the disc displacement was significantly related to the cant of the occlusal and mandibular plane, indicating reduced vertical dimension of the posterior occlusal level and ramal height ipsilateral to the ID. Trpkova et al<sup>6</sup> also reported using frontal radiographs that female subjects studied with bilateral TMJ-ID had significantly greater asymmetry in the vertical position of the antinion. In the last two studies,<sup>6,7</sup> the asymmetry was correlated to the position of the disc.

This retrospective study evaluated the effect of unilateral TMJ DJD (UDJD) on the facial symmetry. The results were compared with asymptomatic volunteers (AVs) having bilateral normal joints.

## MATERIALS AND METHODS [Return to TOC](#)

### Sample

This study included 20 (11 men and nine women) AVs without disc displacement and 20 (five males and 15 females) patients with UDJD ([Table 1](#) ). The diagnosis for both samples was based on magnetic resonance imaging (MRI) and clinical examination. The AV group was selected from a larger sample that included asymptomatic subjects with and without disc displacement and this has been used in previous studies.<sup>16</sup> The mean age was 29.6 years for the AV group and 32.6 years for the UDJD group. All study participants read and signed an informed consent that was approved by the Research Subjects Review Board of the University of Rochester, School of Medicine and Dentistry.

The AVs were examined by one investigator and were accepted in the study after completion of (1) a TMJ subjective questionnaire documenting the absence of jaw pain, noise, locking, or positive history of temporomandibular disorder (TMD) and (2) a clinical and dental examination for signs and symptoms commonly associated with TMD or ID.

The patients with the DJD presented in the clinic with TMD symptoms including pain and limited opening.

### Magnetic resonance imaging

All study participants had bilateral high-resolution MRI scans in the sagittal (closed and opened) and coronal (closed) planes to evaluate the TMJs as described by Katzberg et al<sup>19</sup> and Westesson et al.<sup>20</sup> The two readers used established criteria for DD and were blinded as to group (AV, symptomatic DJD) and clinical information. The patients with unilateral DJD joints had flattening of the condylar head or osteophyte formation. Each study participant was classified as AV or UDJD.

### Posteroanterior cephalometric analysis

Posteroanterior (frontal) cephalometric radiographs were used to evaluate lower facial asymmetry in all research subjects. These were obtained with the head positioned such that the Frankfurt horizontal plane was oriented parallel to the floor and the mandible was at centric occlusion. The radiographs were traced on acetate paper. Standard cephalometric landmarks were identified, and reference lines were drawn as demonstrated previously by Sassouni,<sup>21</sup> Subtelny,<sup>22</sup> Grummons and Kappeyne,<sup>23</sup> and Laspos et al<sup>24,25</sup> taking under consideration the reproducibility of the landmark identification as reported by Major et al<sup>26</sup> and the validity of reference lines by Trpkova et al.<sup>27</sup> The landmarks and reference lines used are shown in [Figure 1](#).

The following measurements were assessed:

- Vertical asymmetry: the difference of the perpendicular distances of ag and ag', na and na', ma and ma', ju and ju', mo and mo', za and za' from LOL' named DAGV, DNAV, DMAV, DJUV, DMOV, DZAV, respectively.
- Horizontal asymmetry: the difference of the perpendicular distances of ag and ag', na and na', ma and ma', ju and ju', mo and mo', za and za', from LOM named DAGH, DNAH, DMAH, DJUH, DMOH, DZAH, respectively.

The difference between the right (R) and left (L) side for all the measurements was used. The difference (L - R) was negative when R > L.

Also, the angle formed by the LOM and the line connecting the midpoint of lo and lo' and the me named degree of mandibular lateral displacement (Me angle) was measured to confirm the mandibular (me) shifting.

### Full profile mandibular laminographs

Bilateral full profile mandibular laminographs were used to assess mandibular asymmetry in all the individuals. These were obtained at 25 degrees with a Quint Sectograph. The center cut laminograph was selected for measurement. Laminographic films were traced, and the lines drawn are shown in [Figure 2](#). Total ramal height (RamH) was defined as the length on the line tangent to the posterior margin of the ramus from the intersection with the perpendicular to the summit of the condyle and the mandibular plane. Condylar height (ConH) was defined as the length from the intersection with the perpendicular originated from the deepest point of the sigmoid notch to the intersection with the perpendicular to the summit of the condyle. The gonial angle (GoAngle) (defined by lines 1 and 2) was also measured. The depth of the antegonial notching (notch) was measured as the distance from the deepest point of the notch perpendicular to the tangent of the lower border of the mandible. The difference between the right (R) and left (L) side for all the measurements (DRamH, DConH, DGoangle, and Dnotch) was used. The difference (L - R) was negative when R > L.

### Statistical analysis

The two-way analysis of variance was used to reveal any significant differences between three groups (the controls, patients with left and patients with right TMJ DJD) and between the men and women. The *P* value was calculated for each of the variables with a level of significance set *P* < .05.

All the measurements were performed by one investigator (Dr Kamblyafkas). To evaluate intraexaminer reliability, the records of 10 subjects were fully analyzed twice with a one week interval, and the intraexaminer correlation coefficient was calculated to be satisfactory (*r* > .9) for all the measurements performed in this study.

## RESULTS [Return to TOC](#)

There were no significant differences between men and women for any of the mean values of the measurements that were used.

### Posteroanterior radiographs (frontals)

No significant differences between the groups were found for the vertical measurements. No significant differences between the controls and the patients with right joint DJD were observed for the horizontal measurements. However, comparison of AVs with patients having left DJD revealed the differences for the following measurements: the antegonion horizontal (dagh), the deviation of the menton (me) and the mandibular dental midline (Insl), and the mandibular asymmetry degree angle (MeDe). The cant of the occlusal plane, as evaluated by the vertical distance of the point mo (first mandibular molar), was not significantly different between the AV and the UDJD groups ([Table 2](#)).

### Bilateral full-profile laminographs

No significant difference was found between the groups for the total ramal height asymmetry. However, the difference for the condylar height and the depth of the mandibular notching between the patients with left TMJ DJD and the controls was significant. The condylar height was found decreased on the affected side. The antegonial notching was deeper in the affected side. No significant differences were found between the subjects with the right TMJ affected and the controls ([Table 3](#)).

## DISCUSSION [Return to TOC](#)

Many studies have previously suggested that a correlation exists between TMJ-ID and mandibular asymmetry.<sup>6,7</sup> IDs may present with or without condylar remodeling.<sup>28-31</sup> ID has often been associated with condylar resorption and has been known to affect the mandibular growth.<sup>32-34</sup> However, patients may have a mandibular deficiency without disc displacement, and patients with normal mandibular growth commonly have disc displacement. Therefore, it is difficult to assign a cause and affect relationship for disc displacement and mandibular growth deficiency.<sup>35</sup>

Adult patients with a hypoplastic or deformed condyle with DJD have been reported to demonstrate deviation of the chin toward the affected side.<sup>36</sup> It has also been proposed that preexisting asymmetry can either camouflage or exaggerate any reduction or lack of condylar growth in the TMJ.<sup>6</sup> In our study, the group with the right side affected did not exhibit significant differences compared with the controls. An individual with right side dominance and right TMJ DJD may actually present "correction" and even "overcorrection" of the natural asymmetry. If the left side (the small side) is affected the asymmetry will be magnified and probably will be clinically detected.

In this study, no significant asymmetry for the total ramal height was found. However, significant asymmetry in condylar height was demonstrated by the laminographs for the patients with the left DJD. Although the condylar height is reduced because of the degenerative lesions, the total ramal height is not affected or is less affected because of the compensatory mechanism taking place at the gonial angle.<sup>33,37-40</sup>

This study suggests that symptomatic adults with unilateral DJD may have remarkable mandibular notching on the affected side. The formation and the depth of the antegonial notching have been suggested to be affected by the amount and direction of the mandibular growth.<sup>32,41,42</sup> Dibbets et al<sup>43</sup> reported the formation of an antegonial notch in children with a flattened condylar head. The increased depth of the antegonial notch on the side with degenerative disease can be either the result of aberrant growth<sup>42</sup> or the result of adaptive remodeling on the gonial angle.<sup>32</sup> Mandibular asymmetry can be developmental or acquired.<sup>44</sup> In our study, only adult individuals of both sexes participated. One problem in this study, which is a common problem in adult studies, is that the time of the onset of the ID and the arthritic lesions is unknown.

In our study, the vertical measurements were not significantly different for the UDJD group compared with the bilateral normal subjects. A possible explanation is that the changes may have taken place in the mandibular fossa and the cranial base. Among the possible compensatory mechanisms taking place in joints with DJD is the thickening of the roof of the

glenoid fossa, which is observed to increase progressively from normal joints with disk displacement and degenerative disease.<sup>45</sup> Moreover, in growing rabbits surgically induced disc displacement may result in cranial base asymmetries.<sup>46</sup> Lower face asymmetry is the result of three-dimensionally differential growth or changes between the left and right side and can be attributed to the mandible or the cranial base.

The purpose of this study was to compare subjects with unilateral degenerative disease with subjects having normal TMJs as diagnosed by MRI. Treatment planning for orthodontic treatment of adults with degenerative disease and compensatory adapting mechanisms is a problem because surgical treatment may be necessary to treat the transverse asymmetry. In many cases, asymmetry is camouflaged by adapting mechanisms. In some cases, asymmetry is evident and must be an alert for the clinician to diagnose the underlying etiology. The unilateral DJD is a possible differential diagnosis associated with mandibular asymmetry, and in this case further investigation for a more accurate diagnosis and successful treatment is recommended.

## CONCLUSIONS [Return to TOC](#)

The results of this study suggest that the UDJD may be associated with lower face asymmetries in certain cases. Factors like the dominant mandibular side and the side affected by the disease as well as compensatory adaptive mechanisms may mask this asymmetry in adults. The clinician must be aware of this and include the DJD as a possible diagnosis when treatment is to be provided to individuals with mandibular asymmetry.

## REFERENCES [Return to TOC](#)

1. Pruzansky S. Not all dwarfed mandibles are alike. *Birth Defects*. 1969; 5:120–129.
2. Grayson BH, Boral S, Eisig S, Kolber A, McCarthy JG. Unilateral craniofacial microsomia. Part I. Mandibular analysis. *Am J Orthod*. 1983; 84:225–230. [[PubMed Citation](#)]
3. Converse JM, Horowitz SL, Cocco PJ, Wood-Smith D. The corrective treatment of the skeletal asymmetry in hemifacial microsomia. *Plast Reconstr Surg*. 1973; 52:221–232. [[PubMed Citation](#)]
4. Westesson PL, Tallents RH, Katzberg RW, Guay JA. Radiographic assessment of asymmetry of the mandible. *Am J Neuroradiol*. 1994; 15:991–999. [[PubMed Citation](#)]
5. Tallents RH, Guay JA, Katzberg RW, Murphy W, Proskin H. Angular and linear comparisons with unilateral mandibular asymmetry. *J Craniomandib Disord*. 1991; 5:135–142. [[PubMed Citation](#)]
6. Trpkova B, Major P, Nebbe B, Prasad N. Craniofacial asymmetry and temporomandibular joint internal derangement in female adolescents: a posteroanterior cephalometric study. *Angle Orthod*. 2000; 70:81–88. [[PubMed Citation](#)]
7. Inui M, Fushima K, Sato S. Facial asymmetry in temporomandibular joint disorders. *J Oral Rehabil*. 1999; 26:402–406. [[PubMed Citation](#)]
8. Larheim TA, Dale K, Tveito L. Radiographic abnormalities of the temporomandibular joint in children with juvenile rheumatoid arthritis. *Acta Radiol Diagn (Stockh)*. 1981; 22:277–284. [[PubMed Citation](#)]
9. Gynther GW, Tronje G, Holmlund AB. Radiographic changes in the temporomandibular joint in patients with generalized osteoarthritis and rheumatoid arthritis. *Oral Surg Oral Med Oral Pathol Oral Radiol Endod*. 1996; 81:613–618. [[PubMed Citation](#)]
10. Schellhas KP, Piper MA, Omlie MR. Facial skeleton remodeling due to temporomandibular joint degeneration: an imaging study of 100 patients. *Cranio*. 1992; 10:248–259. [[PubMed Citation](#)]
11. Dibbets JM, Carlson DS. Implications of temporomandibular disorders for facial growth and orthodontic treatment. *Semin Orthod*. 1995; 1:258–272.
12. Kjellberg H. Craniofacial growth in juvenile chronic arthritis. *Acta Odontol Scand*. 1998; 56:360–365. [[PubMed Citation](#)]
13. Larheim TA, Haanaes HR, Ruud AF. Mandibular growth, temporomandibular joint changes and dental occlusion in juvenile rheumatoid arthritis. A 17-year follow-up study. *Scand J Rheumatol*. 1981; 10:225–233. [[PubMed Citation](#)]
14. De Bont LG, Boering G, Liem RS, Eulderink F, Westesson PL. Osteoarthritis and internal derangement of the temporomandibular joint: a light microscopic study. *J Oral Maxillofac Surg*. 1986; 44:634–643. [[PubMed Citation](#)]
15. Kopp S, Carlsson GE, Hansson T, Oberg T. Degenerative disease in the temporomandibular, metatarsophalangeal and sternoclavicular joints. An autopsy study. *Acta Odontol Scand*. 1976; 34:23–32. [[PubMed Citation](#)]
16. Gidarakou IK, Tallents RH, Kyrkanides S, Stein S, Moss M. Comparison of skeletal and dental morphology in asymptomatic volunteers and symptomatic patients with bilateral degenerative joint disease. *Angle Orthod*. 2003; 73:71–78. [[PubMed Citation](#)]
17. Schellhas KP, Piper MA, Bessette RW, Wilkes CH. Mandibular retrusion, temporomandibular joint derangement, and orthognathic surgery planning. *Plast Reconstr Surg*. 1992; 90:218–229. [[PubMed Citation](#)]
18. Wilkes CH. Internal derangements of the temporomandibular joint. Pathological variations. *Arch Otolaryngol Head Neck Surg*. 1989; 115:469–477. [[PubMed Citation](#)]
19. Katzberg RW, Westesson PL, Tallents RH, Anderson R, Kurita K, Manzione JVJ, Totterman S. Temporomandibular joint: MR assessment of rotational and sideways disk displacements. *Radiology*. 1988; 169:741–748. [[PubMed Citation](#)]
20. Westesson PL, Katzberg RW, Tallents RH, Sanchez-Woodworth RE, Svensson SA, Espeland MA. Temporomandibular joint: comparison of MR images with cryosectional anatomy. *Radiology*. 1987; 164:59–64. [[PubMed Citation](#)]
21. Sassouni V. Diagnosis and treatment planning via roentgenographic cephalometry. *Am J Orthod*. 1958; 44:433–463.
22. Subtelny JD. Cephalometric diagnosis, growth, and treatment: something old, something new?. *Am J Orthod*. 1970; 57:262–286. [[PubMed Citation](#)]
23. Grummons DC, Kappeyne van de Coppello MA. A frontal asymmetry analysis. *J Clin Orthod*. 1987; 21:448–465. [[PubMed Citation](#)]
24. Laspos CP, Kyrkanides S, Tallents RH, Moss ME, Subtelny JD. Mandibular asymmetry in noncleft and unilateral cleft lip and palate individuals. *Cleft Palate Craniofac J*. 1997; 34:410–416.
25. Laspos CP, Kyrkanides S, Tallents RH, Moss ME, Subtelny JD. Mandibular and maxillary asymmetry in individuals with unilateral cleft lip and palate. *Cleft Palate Craniofac J*. 1997; 34:232–239.

26. Major PW, Johnson DE, Hesse KL, Glover KE. Landmark identification error in posterior anterior cephalometrics. *Angle Orthod.* 1994; 64:447–454. [PubMed Citation]

27. Trpkova B, Prasad NG, Lam EW, Raboud D, Glover KE, Major PW. Assessment of facial asymmetries from posteroanterior cephalograms: validity of reference lines. *Am J Orthod Dentofacial Orthop.* 2003; 123:512–520. [PubMed Citation]

28. de Bont LG, Stegenga B. Pathology of temporomandibular joint internal derangement and osteoarthritis. *Int J Oral Maxillofac Surg.* 1993; 22:71–74. [PubMed Citation]

29. Tallents RH, Hatala M, Katzberg RW, Westesson PL. Temporomandibular joint sounds in asymptomatic volunteers. *J Prosthet Dent.* 1993; 69:298–304. [PubMed Citation]

30. Kircos LT, Ortendahl DA, Mark AS, Arakawa M. Magnetic resonance imaging of the TMJ disc in asymptomatic volunteers. *J Oral Maxillofac Surg.* 1987; 45:852–854. [PubMed Citation]

31. Westesson PL, Eriksson L, Kurita K. Reliability of a negative clinical temporomandibular joint examination: prevalence of disk displacement in asymptomatic temporomandibular joints. *Oral Surg Oral Med Oral Pathol.* 1989; 68:551–554. [PubMed Citation]

32. Legrell PE, Isberg A. Mandibular height asymmetry following experimentally induced temporomandibular joint disk displacement in rabbits. *Oral Surg Oral Med Oral Pathol Oral Radiol Endod.* 1998; 86:280–285. [PubMed Citation]

33. Legrell PE, Isberg A. Mandibular length and midline asymmetry after experimentally induced temporomandibular joint disk displacement in rabbits. *Am J Orthod Dentofacial Orthop.* 1999; 115:247–253. [PubMed Citation]

34. Hatala MP, Macher DJ, Tallents RH, Spoon M, Subtelny JD, Kyrkanides S. Effect of a surgically created disk displacement on mandibular symmetry in the growing rabbit. *Oral Surg Oral Med Oral Pathol Oral Radiol Endod.* 1996; 82:625–633. [PubMed Citation]

35. Arnett GW, Milam SB, Gottesman L. Progressive mandibular retrusion-idiopathic condylar resorption. Part II. *Am J Orthod Dentofacial Orthop.* 1996; 110:117–127. [PubMed Citation]

36. Schellhas KP, Piper MA, Omlie MR. Facial skeleton remodeling due to temporomandibular joint degeneration: an imaging study of 100 patients. *Am J Roentgenol.* 1990; 155:373–383. [PubMed Citation]

37. Olson L, Eckerdal O, Hallonsten AL, Helkimo M, Koch G, Gare BA. Craniomandibular function in juvenile chronic arthritis. A clinical and radiographic study. *Swed Dent J.* 1991; 15:71–83. [PubMed Citation]

38. Ronning O, Valiaho ML, Laaksonen AL. The involvement of the temporomandibular joint in juvenile rheumatoid arthritis. *Scand J Rheumatol.* 1974; 3:89–96. [PubMed Citation]

39. Ronning O, Valiaho ML. [Involvement of the facial skeleton in juvenile rheumatoid arthritis]. *Ann Radiol. (Paris).* 1975; 18:347–353. [PubMed Citation]

40. Ronning O, Valiaho ML. Progress of mandibular condyle lesions in juvenile rheumatoid arthritis. *Proc Finn Dent Soc.* 1981; 77:151–157.

41. Isberg AM, McNamara JAJ, Carlson DS, Isacsson G. Coronoid process elongation in rhesus monkeys (*Macaca mulatta*) after experimentally induced mandibular hypomobility. A cephalometric and histologic study. *Oral Surg Oral Med Oral Pathol.* 1990; 70:704–710. [PubMed Citation]

42. Kyrkanides S, Richter L. Mandibular asymmetry and antignonial notching in individuals with unilateral cleft lip and palate. *Cleft Palate Craniofac J.* 2002; 39:30–35.

43. Dibbets JM, van der Weele LT, Uildriks AK. Symptoms of TMJ dysfunction: indicators of growth patterns?. *J Pedod.* 1985; 9:265–284. [PubMed Citation]

44. Rowe N. Hemifacial hypertrophy: review of literature and addition of four cases. *Oral Surg.* 1962;572–587.

45. Honda K, Larheim TA, Sano T, Hashimoto K, Shinoda K, Westesson PL. Thickening of the glenoid fossa in osteoarthritis of the temporomandibular joint. An autopsy study. *Dentomaxillofac Radiol.* 2001; 30:10–13. [PubMed Citation]

46. Qadan S, Macher DJ, Tallents RH, Kyrkanides S, Moss ME. The effect of surgically induced anterior disc displacement of the temporomandibular joint on the midface and cranial base. *Clin Orthod Res.* 1999; 2:124–132. [PubMed Citation]

TABLES [Return to TOC](#)

TABLE 1. Cross Table Gender Against Affected Side

	Right	Left
Male	0	5
Female	5	10
Total	5	15

TABLE 2. Posteroanterior Radiographs<sup>a</sup>

Posteroanterior Radiographs	AV		Left UDJD		Right UDJD	
	Mean	SD	Mean	SD	Mean	SD
DAGH	2.8	3.79	7.86***	3.82	-2.1	2.25
DAGV	-0.5	3.6	-3.93	2.76	3.6	3.65
DJUH	0.75	2.08	3.07	2.46	0.9	3.71
DJUV	-0.25	2.21	-1.07	1.69	-0.1	1.64
DNAH	1.33	2.26	2.07	1.35	0.6	2.1
DNAV	0.23	1.06	-0.07	0.75	0.4	1.19
DZAH	0.53	1.87	1.93	2.53	0	3.06
DZAV	-1.98	3.3	-1.67	1.92	1.3	1.04
DMOH	1.43	2.65	3.6	3.6	1	2.82
DMOV	-0.15	1.93	-1.5	1.31	0.8	1.57
DMAH	2.15	4.2	3.47	4.16	1.9	4.39
DMAV	-1.55	3.54	-1.27	2.56	0.7	0.67
InS	-0.55	1.89	-2.03	1.38	-0.9	1.52
InI	-0.33	1.81	-2.87***	2.04	-0.9	1.34
ANS	-0.13	1.37	-1.6	1.06	0	2
Me	-0.58	1.86	-5.8***	2.05	0.6	3.2
MeDe	-0.78	2.22	-5.83*	1.67	0.6	2.3

<sup>a</sup> AV indicates asymptomatic volunteer with bilateral normal temporomandibular joints; right degenerative joint disease (DJD) and left DJD indicate patients with the right and left joint, respectively, affected by DJD.

\* *P* values equal to or less than .05 were considered significant, \*\*\* *P* values that were less than .001.

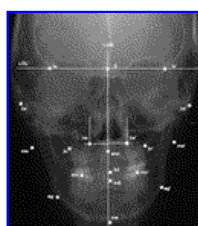
**TABLE 3.** Laminographs<sup>a</sup>

Laminographs	AV-N		Right UDJD		Left DJD	
	Mean	SD	Mean	SD	Mean	SD
DRamH	-0.925	2.04	3.2	5.89	-0.3	5.3
DConH	0.3	2.47	2.4	3.78	-1.73*	3.49
Dnotch	-0.25	1	-1.4	2.4	1.26*	2.46
DGoAngle	2.08	4.69	1.9	5.13	1	5.55

<sup>a</sup> AV-N indicates asymptomatic volunteer with bilateral normal temporomandibular joints; right degenerative joint disease (DJD) and left DJD indicate patients with the right and left joint, respectively, affected by DJD.

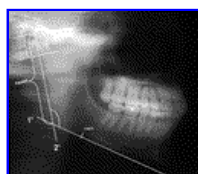\* *P* values equal to or less than .05 were considered significant.

**FIGURES** [Return to TOC](#)



[Click on thumbnail for full-sized image.](#)

**FIGURE 1.** Anteroposterior cephalometric. The landmarks used are (a) Bilateral—lo indicates the intersection of the lateral orbital contour with the innominate line; o, midpoint of lo-lo'; na, nasal point: the intersection of the tangent at the lateral and inferior borders of the nasal cavity; ag, antinionion: the deepest point of the antinionion notch; ju, jugular point: the intersection of the lateral contour of the maxillary alveolar process and the lower contour of the zygomaticomaxillary process of maxilla; mo, molar point: the distal buccal cusp of the first maxillary molar; ma, mastoid point: inferiormost point on the mastoid process. (b) Midline—ans indicates anterior nasal spine; InS, incisor superior: upper dental midline, contact point between maxillary dental incisors; InI, incisor inferior: lower dental midline: contact point between mandibular central incisors; me, midpoint on the inferior border of the mental protuberances. Reference lines—LOL' indicates the line connecting the left and right lo points; LOM, the line at the midpoint of left and right lo perpendicular to LOL'



[Click on thumbnail for full-sized image.](#)

**FIGURE 2.** Mandibular asymmetry was assessed on laminographs. (1') A line tangent to the most prominent points of the inferior border mandible; (2') a tangent along the posterior

margin of the ascending ramus; and (3') a line perpendicular to the posterior margin tangent extending to the most superior outline of the condyle. The condylar height (coH), the total ramal height (ramH), the gonial angle, and the depth of the antgonial notching were measured

<sup>a</sup>Resident, Department of Dentistry, Division of Orthodontics, University of Rochester School of Medicine and Dentistry, Rochester, NY

<sup>b</sup>Associate Professor, Departments of Dentistry and of Neurobiology and Chairman of Division of Orthodontics, Craniofacial Research Core Coordinator, University of Rochester School of Medicine and Dentistry, Rochester, NY

<sup>c</sup>Professor, Department of Dentistry, Division of Orthodontics and Prosthodontics, Program Director Temporomandibular Joint Disorders, University of Rochester School of Medicine and Dentistry, Rochester, NY

Corresponding author: Ross Tallents, DDS, Eastman Dental Center, Orthodontics and TMJD, 625 Elmwood Avenue, Eastman Dental Center, Rochester, NY 14620 (E-mail: [ross\\_tallents@urmc.rochester.edu](mailto:ross_tallents@urmc.rochester.edu))