

[\[Print Version\]](#)

[\[PubMed Citation\]](#) [\[Related Articles in PubMed\]](#)

TABLE OF CONTENTS

[\[INTRODUCTION\]](#) [\[MATERIALS AND...\]](#) [\[RESULTS\]](#) [\[DISCUSSION\]](#) [\[CONCLUSIONS\]](#) [\[REFERENCES\]](#) [\[TABLES\]](#) [\[FIGURES\]](#)

The Angle Orthodontist: Vol. 75, No. 4, pp. 499–505.

Upper Lip Changes Correlated to Maxillary Incisor Retraction—A Metallic Implant Study

Adilson Luiz Ramos;^a Maurício Tatsuei Sakima;^b Ary dos Santos Pinto;^b S. Jay Bowman^c

ABSTRACT

The soft tissue changes after the extraction of maxillary first premolars and subsequent anterior tooth retraction were evaluated for 16 Class II, division 1 patients. Pre- and posttreatment lateral head cephalograms were evaluated using superimpositions on Björk-type metallic implants in the maxilla. The patient sample was divided into group I patients, those who did exhibit lip seal at rest in the pretreatment cephalogram and group II patients, those who did not exhibit lip seal at rest in the pretreatment cephalogram. Upper incisor retraction was followed by a similar ratio of upper lip retraction in both the lip seal and nonsealed groups (1:0.75 and 1:0.70 mean ratios, respectively). However, those without lip seal did demonstrate more retraction at stomion (USt). The final upper lip position (Ls) was reasonably correlated with retraction of the cervical maxillary incisor point (cU1) with determination coefficients of 63.6% in the lip sealed and 68.5% in the lip incompetent groups. Although labial and nasolabial angles tended to open after incisor retraction, there was little predictability for this response.

KEY WORDS: Cephalometry, Implants, Soft tissue profile, Class II treatment, Incisor retraction.

Accepted: July 2004. Submitted: January 2004

INTRODUCTION [Return to TOC](#)


Improved facial esthetics has been an important aspect of orthodontic care, and more recently, a more pronounced labial contour has been proposed as the desired treatment goal.¹⁻¹² Interestingly enough, there appears to be little support in the literature for the assumption that only fuller smiles and profiles are deemed more esthetic.^{13,14}

Quantifying and predicting changes in the soft tissue profile from extractions and subsequent incisor retraction could provide important information for advising patients about treatment alternatives.^{10,15-26} Studies of the profile changes resulting from the removal of only two upper premolars has been infrequently reported despite the fact that this treatment is often used as an alternative to orthognathic surgery for nongrowing patients and for those who exhibit Class II malocclusions with significant overjet.

Unfortunately, there is limited database of evidence of the soft tissue changes subsequent to orthodontic treatment.^{16,27-45} The purpose of this study is to describe the changes in the soft tissue profile after the removal of maxillary first premolars and subsequent retraction of

the anterior teeth as demonstrated with the use of tantalum implants.

MATERIALS AND METHODS [Return to TOC](#)

Pre- and posttreatment cephalograms of 16 Class II, division 1 adolescent patients (seven females, nine males), who had been treated with the removal of only maxillary first premolars and full fixed appliance therapy at the Department of Child Clinic at the Dentistry School of Araraquara—Universidade Estadual Paulista (UNESP), Brazil, were selected⁴⁶ ([Figure 1](#) ) .


All 16 patients had received Björk-type 0.5 × 1.5 mm tantalum implants in the maxilla.⁴⁷ Implants were placed bilaterally below the anterior nasal spine and below the zygomatic processes. Immediately after implant placement and again at the conclusion of treatment, lateral head radiographs were made at maximum intercuspation with the Frankfurt horizontal plane parallel to the ground and the lips in rest position as described by Burstone.⁴⁸


From the sample of 16 patients, two groups were defined.

- Lip seal (group I, N = 8). Pretreatment passive lip seal⁴⁸ was defined as a vertical distance of 0–0.5 mm between the upper and lower lips in the T0 cephalogram.
- Lip incompetence (group II, N = 8). Pretreatment lack of lip seal was defined as a vertical distance greater than two mm between the upper and lower lips in the T0 cephalogram.

No patient who demonstrated 0.5–2.0 mm between the upper and lower lips was evaluated.

Cephalometrics

Selected cephalometric landmarks were traced on acetate paper with the metallic implants used as reference points for registration and orientation^{47–51} ([Figure 2](#) ) . A template for the maxillary incisors was drawn from the initial tracing (T0) and transferred forward to subsequent superimpositions.




The cephalometric points were digitized using a Summa Sketch III tablet (Summagraphics Co., Seymour, Connecticut) with a resolution of 500 lines per inch. The tablet was coupled to a portable Toshiba PC, Pentium II, 266 MHz-MMX (Toshiba Inf. Systems, Irvine, Calif, USA) using digitization software manufactured by the UNESP Department of Child Clinic.⁵² Vertical and horizontal displacements of the cephalometric points along with linear and angular measurements were calculated ([Figure 2](#) ) .




Statistical analysis and error control

All variables were tested and showed normal distribution at the 5% level, according to Lilliefors's test. Analysis of variance was used to evaluate means' differences between groups, and Pearson's correlation coefficients were calculated for dependent variables as a function of independent variables. Multiple linear regression tests were applied to evaluate future alterations of dependent variables.

Measurements were processed by the System for Statistical and Genetic Analysis 5.0 computer program of the Federal University of Viçosa, Brazil. Tracing and digitalization errors were controlled by point markings for all radiographs at two-month intervals. Tracings were repeated and digitized twice.⁵³ Means of the four measurements of each parameter were used for comparison, and all variables were tested at 5% level of significance.⁵ The 8% mean magnification factor produced by the cephalostat used for all patients was corrected by the same program used in data digitizing.⁵²

RESULTS [Return to TOC](#)

Means and changes in angular and linear variables and also point displacements for both group I (lip seal) and group II (lip incompetence), using maxillary superimpositions, are shown in [Tables 1](#)  through 3 and [Figures 3](#)  and 4  .

Mean treatment changes for both groups were similar and included upper incisor retraction, increase in the nasolabial angle, reduction in the thickness of the upper lip, and a reduction in the vertical display of the upper lip vermillion ([Tables 2](#)  and 3 ). Only the variables Ay and UStx showed any statistically significant difference between the two groups during treatment ([Table 3](#) ).

DISCUSSION [Return to TOC](#)

Nasolabial and lip angle

Scheideman et al⁵⁴ reported a normal mean nasolabial angle at 111.4° with a small decrease in this angle expected with age, primarily because of the downward growth of the nose.^{55–58} Fitzgerald et al⁵⁵ emphasized continued nasal development in any analysis of nasolabial angles. In this study, the mean pretreatment values for the nasolabial and labial angles of both groups were slightly less than the norm (Table 1).^{54–56,58} This is likely because of the additional protrusion inherent in a sample comprising only Class II subjects.

During the course of treatment, the mean maxillary incisor (iU1x) retraction was 3.7 mm for group I and 5.6 mm for group II (Figures 3 and 4; Table 3) with a favorable 4° mean increase in the nasolabial angle (Table 2). There was low correlation (46.2%) between the change in the nasolabial angle and incisor retraction. Waldman³⁴ had also reported only a slight correlation ($r = 0.42$) between retraction of incisors and alteration of the nasolabial angle and many other workers have reported this same kind of variability.*

The lip angle, constructed relative to the cranial base (SnLs.SN-7°), demonstrated greater changes than the nasolabial angle during treatment (7.0° for group I; 9.1° for group II, Table 2) with no statistically significant difference between the groups. This larger response in the lip angle compared with the nasolabial angle is probably related to greater downward growth at the tip of the nose during the course of treatment.

The correlation between the changes in lip angle and incisor retraction was also greater than that seen for the nasolabial angle (66.9% compared with 46.2%); however, this difference was dependent upon more than one landmark measured on the maxillary incisors. If examined separately, changes in the cervical point of the maxillary incisor (cU1x) demonstrated a higher correlation with lip angle than did changes in the incisal edge (46% and 24%, respectively). In addition, changes in angulation of the maxillary incisor (U1.SN-7°) were not significantly correlated with the nasolabial or lip angle in this study ($r = 0.30$).

Although incisor retraction and corresponding lip movement differed somewhat between groups I and II, the values were not statistically significant. Individual variation in growth at the lower base of the nose (points Snx and Cmy) appeared to confound a reliable prediction of changes in the nasolabial angle accompanying incisor retraction. As a consequence, the present results support the simple expectation that incisor retraction will result in a larger final nasolabial and lip angle.

It is important to note that extraction of the maxillary first premolars, followed by retraction of the incisors, did increase the nasolabial and lip angles. However, when the final angulations were compared with normal values,^{54–56,58} there was no apparent negative effect from this treatment (Table 1).

Thickness of the upper lip (A-A')

Mamandras⁶² reported a mild increase in the thickness of the upper lip (0.5 mm) for samples of untreated girls 10–12 years of age and an additional 0.3 mm for girls 12–14 years of age. Similar increases in boys occurred between the ages of 12 and 16 years. Subtelny⁶³ and Nanda et al⁶⁴ also described only small changes in the lip thickness for patients from age of 7–14 years. Talass et al,³⁶ Chiavini,⁴⁵ and Ricketts⁶⁵ reported increases in upper lip thickness because of retraction of the maxillary incisor. These three studies used the labial face of the incisor and point Ls as points of reference. If, in fact, points Lsx and iU1x are compared, an increase in lip thickness could be reported (Table 3). In this instance, it appears that where you are measuring matters most.

In this sample, there was an average decrease in lip thickness of 0.7–0.8 mm during the course of treatment (A-A', Table 2). Lamastra¹⁹ reported a slightly greater decrease in lip thickness (one mm) when the labial groove (A') was retracted one mm. Hershey⁵⁹ described 0.71 mm reduction with one mm of retraction, similar to this study.

Vertical extension of the upper lip vermilion

Dainesi⁵⁷ described a mild increase in the display of the upper lip vermilion border (Ls-USt) from age 12 to 14 years with no subsequent change to age 18 years. In this study, after the retraction of the incisors, groups I and II showed a decrease of 1.2 mm and 0.9 mm of the upper lip vermilion, respectively. Perkins and Staley⁴⁰ reported a similar (0.8 mm) reduction but noted that patients starting with a greater vertical display of their maxillary incisors had less reduction of the lip vermilion. There was only a weak correlation (45.1%) between retraction of the maxillary incisors and reduction of the vermilion border for Class II patients. In any event, if a patient begins treatment with minimal display of the upper lip vermilion border, some reduction in that display subsequent to retraction could produce a less esthetic result. Arnett and Bergman⁶⁶ have suggested an upper and lower lip vermilion ratio of 1:1.25, whereas a 1:1 ratio was recommended by Auger and Turley.¹¹

Vertical display of the maxillary incisor

There was no significant difference between groups for the final vertical display of the maxillary incisors (iU1-USt) with the upper lip at rest. Perkins and Staley⁴⁰ reported a significant (0.7 mm) increase in incisor display for patients who began treatment with mild (<6 mm) incisor exposure but an insignificant (0.5 mm) decrease for patients who started with greater than six mm of exposure. These are the same trends found in this study (Tables 1 and 2).

Upper lip movement related to incisor retraction

Upper lip retraction (Lsx) was significantly correlated with maxillary incisor retraction, measured at the cervical point (cU1x). Typically, the incisal edge or the most vestibular point of the incisor has been the most common landmark selected, but this point has minimal predictive value for lip movement (28%).^{28,36,45} Hershey⁵⁹ reported a higher determination (64%) when he used the most labial point of the incisor crown. However, he concluded that the upper lip's movement as a function of retraction could not be predicted because of the great variability (Table 4). [Figure 5](#) shows movements of cU1x and iU1x and the predictability of change of Lsx based on the regression formula ($Lsx = 0.28 + 0.87 \text{ cU1x}$). When predicted movement was compared with actual movement of Lsx, greater retractions resulted in better predictions.

It may seem reasonable to accept that if the patient's initial incisor overjet was caused by extreme upper incisor proclination, then the subsequent correction (by retraction of the incisal edge with little backward displacement of the cervical point) tended to produce less lip change (eg, [Figure 5](#), patients 5/A and 6/B). On the other hand, more lip retraction was seen when the incisor retraction underwent translatory movement and the initial incisor inclination was close to normal.

There was more retraction of the upper lip stomion (USlx) for patients without pretreatment lip seal (group II = -2.7 mm; group I = -0.6 mm), but the regression equation included more variables. Vertical upper lip landmarks (Lsy, A'y, and USty) showed movement in similar proportions to the vertical movement of upper incisors with an approximate 80% coefficient of determination and appeared directly related to the rate of growth of the maxilla.

CONCLUSIONS [Return to TOC](#)

Retraction of the upper lip accompanied maxillary incisor retraction at a mean ratio of 1:0.75 for patients with pretreatment lip seal and 1:0.70 for those with pretreatment lip incompetence. Movement of the cervical point of the upper incisor greatly influenced changes in the upper lip, mainly in the horizontal plane.

Labial and nasolabial angles tended to open after incisor retraction, but there was little predictability for this response. The individuality of nasal base growth and not necessarily the upper lip's anatomy is the likely cause of variability in the nasolabial angle. Despite the small sample size, the results confirm that there is a wide range of individual variation and that an obtuse nasolabial angle is not likely to be an automatic result of treatment featuring upper incisor retraction.

Maxillary implant superimposition helped reduce the confounding factors of facial growth and development when attempting to assess changes related to treatment. For example, when regional superimpositions were used, it appeared that vertical changes in the lips were more related to growth, whereas horizontal alterations were associated with incisor retraction.

REFERENCES [Return to TOC](#)

1. Angle EH. Classification of malocclusion. *Dent Cosmos*. 1899; 41:248–264. 350–357.
2. Downs WB. Variations in facial relationships: their significance in treatment and prognosis. *Am J Orthod*. 1948; 34:812–840.
3. Riedel RA. Esthetics and its relation to orthodontic therapy. *Angle Orthod*. 1950; 20:168–178. [[PubMed Citation](#)]
4. Burstone CJ. The integumental profile. *Am J Orthod*. 1958; 44:1–25.
5. Subtelny JD. The soft tissue profile, growth and treatment changes. *Angle Orthod*. 1961; 31:105–122.
6. Merrifield LL. The profile line as an aid in critically evaluating facial esthetics. *Am J Orthod*. 1966; 52:804–822. [[PubMed Citation](#)]
7. Ricketts RM. Esthetics, environment, and the law of lip relation. *Am J Orthod*. 1968; 54:272–289. [[PubMed Citation](#)]
8. Peck H, Peck S. A concept of facial esthetics. *Angle Orthod*. 1970; 40:284–317. [[PubMed Citation](#)]
9. Cox NJ, Van Der Linden FPGM. Facial harmony. *Am J Orthod*. 1971; 60:175–184. [[PubMed Citation](#)]
10. Park Y, Burstone CJ. Soft tissue-fallacies of hard-tissue standards in treatment planning. *Am J Dentofacial Orthop*. 1986; 90:52–62.
11. Auger TA, Turley P. The female soft tissue profile as presented in fashion magazines during the 1900s: a photographic analysis. *Int Adult Orthod Orthognath Surg*. 1999; 14:7–18. [[PubMed Citation](#)]
12. Andrews LF. The six keys to normal occlusion. *Am J Orthod*. 1972; 62:296–309. [[PubMed Citation](#)]

13. Bowman SJ, Johnston LE Jr. The esthetic impact of extraction and nonextraction treatments on Caucasian patients. *Angle Orthod.* 2000; 70:3–10. [[PubMed Citation](#)]
14. Bowman SJ, Johnston LE Jr. Much ado about facial esthetics. In: McNamara JA, Kelly K, eds. *Treatment Timing: Orthodontics in Four Dimensions*. Craniofacial Growth Series, vol. 39. Ann Arbor: Center for Human Growth and Development, The University of Michigan; 2002:199–217.
15. Angelle PL. A cephalometric study of the soft tissue changes during and after orthodontic treatment. *Trans Eur Orthod Soc.* 1973; 49:267–280.
16. Garner LD. Soft-tissue changes concurrent with orthodontic tooth movement. *Am J Orthod.* 1974; 66:367–377. [[PubMed Citation](#)]
17. Huggins DG, McBride LJ. The influence of the upper incisor position on soft tissue facial profile. *Br J Orthod.* 1975; 2:141–146.
18. Jacobs JD. Vertical lip changes from maxillary incisor retraction. *Am J Orthod.* 1978; 74:396–404. [[PubMed Citation](#)]
19. Lamastra SJ. Relationship between changes in skeletal and integumental points A and B following orthodontic treatment. *Am J Orthod.* 1981; 79:416–423. [[PubMed Citation](#)]
20. Hsu BS. Comparisons of the five analytic reference lines of the horizontal lip position: their consistency and sensitivity. *Am J Orthod Dentofacial Orthop.* 1993; 104:355–360. [[PubMed Citation](#)]
21. Bishara SE, Cummins DM, Jakobsen JR, Zaher AR. Dentofacial and soft tissue changes in Class II, division I cases treated with and without extractions. *Am J Orthod Dentofacial Orthop.* 1995; 107:28–37. [[PubMed Citation](#)]
22. Bravo LA, Canut JA, Pascual A, Bravo B. Comparison of the changes in facial profile after orthodontic treatment, with and without extractions. *Br J Orthod.* 1997; 24:25–34. [[PubMed Citation](#)]
23. Kokodynskj RA, Marshall SD, Ayer W, Weintraub NH, Hoffman DL. Profile changes associated with maxillary incisor retraction in the post adolescent orthodontic patient. *Int Adult Orthod Orthognath Surg.* 1997; 12:129–134. [[PubMed Citation](#)]
24. Bishara SE, Jakobsen J. Profile changes in patients treated with and without extractions: assessments by lay people. *Am J Orthod Dentofacial Orthop.* 1998; 112:639–644.
25. Boley JC, Pontier JP, Smith S, Fulbright M. Facial changes in extraction and nonextraction patients. *Angle Orthod.* 1998; 68:539–546. [[PubMed Citation](#)]
26. James RD. A comparative study of facial profiles in extraction and nonextraction treatment. *Am J Orthod Dentofacial Orthop.* 1998; 114:265–276. [[PubMed Citation](#)]
27. King EW. Variations in profile change and their significance in timing treatment. *Angle Orthod.* 1960; 30:141–153.
28. Rudee DA. Proportional profile changes in Class II treatment. *Am J Orthod.* 1964; 50:421–434.
29. Wisth PJ. Soft tissue response to upper incisor retraction in boys. *Br J Orthod.* 1974; 1:199–204. [[PubMed Citation](#)]
30. Roos N. Soft-tissue profile changes in Class II treatment. *Am J Orthod.* 1977; 72:165–175. [[PubMed Citation](#)]
31. Lo FD, Hunter WH. Changes in nasolabial angle related to maxillary incisor retraction. *Am J Orthod.* 1982; 82:384–391. [[PubMed Citation](#)]
32. Oliver BM. The influence of lip thickness and strain on upper lip response to incisor retraction. *Am J Orthod.* 1982; 82:141–149. [[PubMed Citation](#)]
33. Rains MD, Nanda R. Soft-tissue changes associated with maxillary incisor retraction. *Am J Orthod.* 1982; 81:481–488. [[PubMed Citation](#)]
34. Waldman BH. Changes in lip contour with maxillary incisor retraction. *Angle Orthod.* 1982; 52:129–134. [[PubMed Citation](#)]
35. Kader HMA. Vertical lip height and dental height changes in relation to the reduction of overjet and overbite in Class II, division 1 malocclusion. *Am J Orthod.* 1983; 84:260–263. [[PubMed Citation](#)]
36. Talass MF, Talass L, Baker RC. Soft tissue profile changes resulting from retraction of maxillary incisors. *Am J Orthod Dentofacial Orthop.* 1987; 91:385–394. [[PubMed Citation](#)]

37. Drobocky OB. Changes in facial profile during orthodontic treatment with extraction of four first premolars. *Am J Orthod Dentofacial Orthop.* 1989; 95:220–230. [[PubMed Citation](#)]
38. Park S, Kudlick EM, Abrahamian A. Vertical dimensional changes of the lips in the North American black patient after four first-premolar extractions. *Am J Orthod Dentofacial Orthop.* 1989; 96:152–160. [[PubMed Citation](#)]
39. Yogosawa F. Predicting soft tissue profile changes concurrent with orthodontic treatment. *Angle Orthod.* 1990; 60:199–206. [[PubMed Citation](#)]
40. Perkins RA, Staley RN. Change in lip vermilion height during orthodontic treatment. *Am J Orthod Dentofacial Orthop.* 1993; 103:147–154. [[PubMed Citation](#)]
41. Bravo LA. Soft tissue facial profile changes after orthodontic treatment with four premolars extracted. *Angle Orthod.* 1994; 64:31–42. [[PubMed Citation](#)]
42. Herrmann BD. *Upper Lip Movement in Borderline Extraction-Nonextraction Patients* [master's thesis]. Dallas, Tex: Baylor University; 1994.
43. Diels RM, Lalra V, DeLoach N, Powers M, Nelson SS. Changes in soft tissue profile on African-Americans following extraction treatment. *Angle Orthod.* 1995; 65:285–292. [[PubMed Citation](#)]
44. Caplan MJ. The effect of premolar extraction on the soft-tissue profile in adult African American females. *Angle Orthod.* 1997; 67:129–136. [[PubMed Citation](#)]
45. Chiavini PCR. *Avaliação cefalométrica das alterações labiais em indivíduos portadores de Classe II, divisão 1ª de Angle, tratados com extração dos primeiros pré-molares superiores* [dissertação]. Araraquara, Brazil: Universidade Estadual Paulista; 1999.
46. Sakima MT. *Avaliação cefalométrica comparativa de dois métodos de correção da sobremordida. Estudo com implantes metálicos* [tese]. Araraquara, Brazil: Universidade Estadual Paulista; 1997.
47. Björk A. Variation in the growth pattern of the human mandible: a longitudinal study by the implant method. *J Dent Res.* 1963; 42:400–411. [[PubMed Citation](#)]
48. Burstone CJ. Lip posture and its significance in treatment planning. *Am J Orthod.* 1967; 53:262–284. [[PubMed Citation](#)]
49. Riolo ML, Moyers RE, McNamara JA, Hunter WS. *An Atlas of Craniofacial Growth*. Ann Arbor, Mich: Center for Human Growth and Development, University of Michigan; 1974.
50. Martins DR, Janson GRPJ, Henriques JFC, Freitas MR, Pinzan A. *Atlas de crescimento craniofacial*. São Paulo, Brazil: Editora Santos; 1998.
51. Björk A. Cephalometric X-ray investigations in dentistry. *Internat D J.* 1954; 4:718–744.
52. Sakima PRT. *Efeitos dos erros de projeção sobre as grandezas cefalométricas das análises de Steiner e McNamara* [dissertação]. Araraquara, Brazil: Universidade Estadual Paulista; 2001.
53. Goldreich HN, Martins JCR, Martins LP, Sakima PRI. Considerações sobre os erros em cefalometria. *Rev Dent Press Ortod Ortop Maxilar.* 1998; 3:81–90.
54. Scheideman GB, Bell WH, Legan HL, Finn RA, Reisch JS. Cephalometric analysis of dentofacial normals. *Am J Orthod.* 1980; 78:404–420. [[PubMed Citation](#)]
55. Fitzgerald JP, Nanda RS, Currier RGF. An evaluation of the nasolabial angle and the relative inclinations of the nose and upper lip. *Am J Orthod Dentofacial Orthop.* 1992; 102:328–334. [[PubMed Citation](#)]
56. Prahll-Andersen B, Ligthelm-Bakker ASWMMR, Wattel E, Nanda R. Adolescent growth changes in soft tissue profile. *Am J Orthod Dentofacial Orthop.* 1995; 107:476–483. [[PubMed Citation](#)]
57. Dainesi EA. *A influência dos padrões extremos de crescimento da face sobre o perfil tegumentar, analisada cefalometricamente em jovens leucodermas brasileiros* [tese]. Bauru, Brazil: Universidade de São Paulo; 1998.
58. Zylinski CG, Nanda RS, Kapila S. Analysis of the soft tissue facial profile in white males. *Am J Orthod Dentofacial Orthop.* 1992; 101:514–518. [[PubMed Citation](#)]
59. Hershey HG. Incisor tooth retraction and subsequent profile change in post adolescent female patients. *Am J Orthod.* 1972; 61:45–54.

[\[PubMed Citation\]](#)

60. Valentim ZL, Capelli J Jr, Almeida MA, Bailey LJ. Incisor retraction and profile changes in adult patients. *Int J Adult Orthod Orthognath Surg.* 1994; 9:31–36. [\[PubMed Citation\]](#)

61. Kasai K. Soft tissue adaptability to hard tissue in facial profiles. *Am J Orthod Dentofacial Orthop.* 1998; 113:674–684. [\[PubMed Citation\]](#)

62. Mamandras AH. Linear changes of the maxillary and mandibular lips. *Am J Orthod.* 1988; 94:405–410.

63. Subtelny JD. A longitudinal study of soft tissue facial structures and their profile characteristics, defined in relation to underlying skeletal structures. *Am J Orthod.* 1959; 45:481–507.

64. Nanda RS, Meng H, Kapila S, Goorhuis J. Growth changes in the soft tissue facial profile. *Angle Orthod.* 1990; 60:177–189. [\[PubMed Citation\]](#)

65. Ricketts RM. Cephalometric synthesis. *Am J Orthod.* 1960; 46:647–673.

66. Arnett GW, Bergman RT. Facial keys to orthodontic diagnosis and treatment planning—part II. *Am J Orthod Dentofacial Orthop.* 1993; 103:395–411. [\[PubMed Citation\]](#)

TABLES [Return to TOC](#)

TABLE 1. Comparisons of Means Between Groups I and II and Standard Deviations of Angular and Linear Variables

Variable	Group I		Group II	
	x	SD	x	SD
USt-iU1 T0	2.10	1.88	4.72	1.66
USt-iU1 T1	2.76	1.60	4.79	1.94
Ls-USSt0	9.23	2.46	8.19	1.50
Ls-USSt1	8.06	2.43	7.32	1.72
A-A' T0	16.27	2.59	16.28	1.88
A-A' T1	15.59	2.77	15.50	1.90
Nasolab T0	103.32	12.15	110.58	7.01
Nasolab T1	106.77	12.38	114.93	7.21
U1.SN-7 T0	120.25	11.86	119.61	6.00
U1.SN-7 T1	113.48	8.60	109.99	8.60
SnLs.SN-7 T0	103.70	12.87	102.21	8.54
SnLs.SN-7 T1	96.72	12.79	93.08	9.74

TABLE 2. Comparisons of Means Between Groups I and II and Standard Deviations of the Differences at Start and End of Observation Period, in Angular and Linear Variables

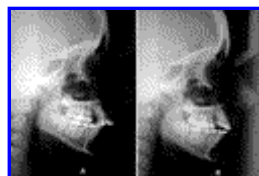
Variable	Group I		Group II	
	x	SD	x	SD
USt-iU1 T1-T0	0.65	1.30	0.06	0.93
Ls-USSt T1-T0	-1.17	-0.50	-0.87	0.20
A-A' T1-T0	-0.68	0.31	-0.78	0.41
Nasolab T1-T0	3.45	1.27	4.35	2.17
U1.SN-7 T1-T0	-6.77	0.38	-9.62	3.24
SnLs.SN-7 T1-T0	-6.98	1.62	-9.13	3.76

TABLE 3. Comparison between means of Groups I and II of the point displacements and their respective standard deviations, evaluated by maxillary superimposition

Variable	Group I		Group II	
	x	SD	x	SD
ANSx	0.35	0.90	0.66	1.48
ANSy	-0.35	0.69	-0.99	0.45
Ax	-0.27	0.71	-0.18	0.97
Ay	-0.59*	0.80	-1.90*	1.15
aU1x	-0.75	1.12	-1.26	1.63
aU1y	-0.61	1.27	-0.76	1.56
cUsx	-2.04	1.39	-2.86	1.56
cU1y	-0.63	1.16	-0.96	1.72
iU1x	-3.74	2.06	-5.55	2.68
iU1y	-1.04	1.23	-1.56	1.59
Cmx	0.27	0.64	1.19	1.35
Cmy	-1.85	1.20	-1.87	1.59
Snx	-0.04	0.50	-0.03	1.31
Sny	-1.08	0.75	-1.48	0.95
A'x	-0.91	0.89	-0.95	1.59
A'y	-1.25	0.65	-1.88	1.02
Lsx	-1.69	1.16	-2.11	2.05
Lsy	-1.40	0.97	-2.28	1.83
UStx	-0.87*	1.39	-2.74*	2.24
USty	-0.37	0.91	-1.42	1.44

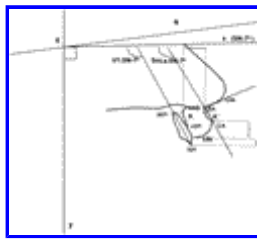
* p < 0.05.

FIGURES [Return to TOC](#)



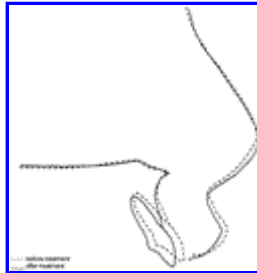[Click on thumbnail for full-sized image.](#)

FIGURE 1. Lateral head radiograph images (A) before and (B) after anterior-superior retraction using segmental mechanics. Note the placement of metallic implants in the maxilla



[Click on thumbnail for full-sized image.](#)

FIGURE 2. Reference lines x and y, angles, and cephalometric points evaluated in maxillary superimposition




[Click on thumbnail for full-sized image.](#)

FIGURE 3. Changes during treatment for group I (patients with pretreatment lip seal) with reference to maxillary superimposition



[Click on thumbnail for full-sized image.](#)

FIGURE 4. Changes during treatment for group II (patients with pretreatment lip incompetence) with reference to maxillary superimposition



[Click on thumbnail for full-sized image.](#)

FIGURE 5. Predicted movement of the upper lip (Lsx) for (A) individual patients in groups I; and (B) individual patients in groups II compared with the actual movement of points Lsx, cU1x, and iU1x during treatment

^aAdjunct Professor, Department of Orthodontics, State University of Maringá, Paraná, Brazil

^bAdjunct Professor, Department of Orthodontics, Araraquara School of Dentistry, São Paulo, Brazil

^cAdjunct Associate Professor, Saint Louis University, Saint Louis, MO

**References 16,17,28,30–32,36,41,43,45,59–61.*