

[\[Print Version\]](#)
[\[PubMed Citation\]](#) [\[Related Articles in PubMed\]](#)

TABLE OF CONTENTS

[\[INTRODUCTION\]](#) [\[MATERIALS AND...\]](#) [\[RESULTS\]](#) [\[DISCUSSION\]](#) [\[CONCLUSIONS\]](#) [\[REFERENCES\]](#) [\[TABLES\]](#) [\[FIGURES\]](#)

The Angle Orthodontist: Vol. 75, No. 4, pp. 532-539.

Efficiency of Noncompliance Simultaneous First and Second Upper Molar Distalization: A Three-dimensional Tooth Movement Analysis

Anestis Mavropoulos;^a Andreas Karamouzos;^b Stavros Kiliaridis;^c Moschos A. Papadopoulos^d

ABSTRACT

Objective of this prospective study was the three-dimensional (3D) analysis of tooth movements after the noncompliance simultaneous distalization of the first and second maxillary molars. Ten patients (five girls and five boys; mean age: 13.2 years) with bilateral Class II molar relationships were treated with a noncompliance, fixed intraoral appliance. Upper second molars had already erupted in all cases. Dental casts and lateral cephalometric radiographs were taken immediately before placement and after removal of the appliance. The casts were 3D digitized and superimposed on a predefined area in the palate. The resulting holograms, as well as the cephalometric radiographs, were digitized and analyzed by means of customized cephalometric software. The whole procedure was repeated after a two- to four-week interval to estimate the error of both methods. The cast assessment of 3D sagittal and vertical tooth movements was more reliable than the cephalometric record. The average maxillary first molar distal movement was 2.8 mm. Anchorage loss was expressed by a 1.9-mm proclination of the central incisors. A substantial variation among patients and among the right and left side in the same patient was observed. Noncompliance simultaneous distalization of the first and second maxillary molars can be an efficient treatment option for the correction of Class II molar relationship. However, anchorage loss and individual variation have to be seriously considered. Bilaterally symmetrical effectiveness should not be relied upon.

KEY WORDS: Class II malocclusion, Noncompliance distalization, Jig assembly, Three-dimensional cast superimposition.

Accepted: June 2004. Submitted: March 2004

INTRODUCTION [Return to TOC](#)

Noncompliance approaches involving distalization of the maxillary molars have become very popular for the correction of Class II malocclusion. A variety of treatment methods that require minimum patient cooperation have been proposed to move molars distally, most notably intramaxillary appliances such as the pendulum appliance, the distal jet, repelling magnets, and the Jones jig.¹ These appliances are commonly used when the second upper molars have already erupted.

In a recent prospective clinical study, the effectiveness of a fixed, noncompliance intraoral appliance² in such clinical context was evaluated on lateral cephalometric radiographs.³ In that study, the Class II relationship was corrected in all cases, but the distal movement of the first molars was accompanied by distal tipping and a considerable loss of anchorage. The anchorage loss was manifested as mesial tipping and displacement of the anterior anchorage unit, as has been reported in previous studies testing analogous noncompliance appliances.⁴⁻⁸ The analysis of the dentoalveolar and skeletal effects of these appliances was done using either lateral cephalometric radiographs or dental casts and used various methods of two-dimensional assessment. However, these methods present significant limitations, notably the difficulties in establishing a valid and reliable reference system,⁹ plus the significant error associated with measuring small linear distances on radiographs or casts.

Recent advances in the application of three-dimensional (3D) imaging for dental purposes have made possible a more accurate assessment of tooth positional changes on dental casts.^{10,11} Laser scanners are now widely used in orthodontics and maxillofacial surgery for the 3D acquisition of dental casts or the face.^{10,12}

The reliability of generating 3D dental images using surface laser scanners has also been investigated, and these devices were reported to have great research potential in orthodontics because of their ability to yield accurate and reproducible data. Differences between direct measurements made on dental casts and those made on computer-reconstructed images generated by surface laser scanners have shown that these devices are highly accurate for dental cast analysis.¹³⁻¹⁵

The aim of this prospective study was the 3D analysis of tooth movements after the noncompliance orthodontic simultaneous distalization of the first and second maxillary molars on 3D reconstructed images generated from 3D surface laser scanning and on lateral cephalometric radiographs. The hypothesis was that cephalometric assessment alone cannot provide an accurate and comprehensive description of the orthodontic tooth movements that occur in such clinical situation.

MATERIALS AND METHODS [Return to TOC](#)

Subjects

Ten patients (five girls and five boys; mean age: 13.2 years) with bilateral Class II molar relationships and maxillary second molars already erupted were treated with a fixed intraoral appliance² during the first phase of their overall orthodontic treatment by Dr Papadopoulos. In all cases a Class I molar relationship was achieved on both sides during an average treatment period of 17.5 weeks. Maxillary dental casts and lateral cephalometric radiographs were taken immediately before placement and after removal of the appliance.

The appliance was a modification of the Jones jig appliance, which consisted of an active and an anchorage unit^{2,3} (Figure 1). The anchorage unit was a modified Nance button, which was attached to the bands of the upper second premolars. The active unit consisted of a 30- to 35-mm-long, round stainless steel wire, a nickel-titanium open coil spring, and two sliding tubes. The spring was activated through ligation of the hook of one of the sliding tubes to the bracket of the second premolar band. Optimal activation of the coil spring delivered 80 g per side. Reactivation was performed at four-week intervals.

3D cast superimposition and analysis

All casts were digitized using a 3D surface laser scanner (Laserscan 3D Pro, Willytec GmbH, Gräfelting, Germany) by placing them on a special base with the occlusal plane in horizontal position (Figure 2A). The image obtained was then transferred through a video acquisition system to a personal computer (Siemens Expert, Siemens AG, Munich, Germany), controlled by the SCAN-3D software (Willytec GmbH).

The pre- and posttreatment 3D images were superimposed on a predefined area in the palate (Figure 2B). This area included the anterior part of the palate comprising the palatal rugae and a zone in the palate along the midline raphe. It has been previously shown that the palatal rugae can be used as reference landmarks for the assessment of tooth movements.¹⁶⁻¹⁸ The zone of the palate along the midline raphe was also used because it significantly enhances the reliability of the 3D superimposition.¹⁹ The result was a new fused hologram, which was projected on the occlusal plane, and the resulting two-dimensional image was digitized on screen by means of customized cephalometric software (Viewbox 3.01, dHAL Orthodontic Software, Athens, Greece).

To evaluate the positional changes of each tooth, the cusps of the first molars, second premolars, and canines, as well as the mesial and distal edges of the central incisors, were digitized (Figure 3). Centroid points were constructed to be used as reference points. To make the results clinically more relevant, tooth movements were measured along the axis where they actually took place, ie, the lateral arch segments. As an example, in the case of the first molar, the term "effective distal movement" represented the projection of the movement of the first molar on the mesiodistal axis of the corresponding lateral segment (Figure 4). The vertical changes were measured directly on the fused hologram by placing the cursor over the mesial fossa of the second premolar and over the central fossa of the first molar to register the differences in the z-axis. The 3D cast analysis performed in this study could not yield any information concerning the mesiodistal inclination (tipping) of the teeth under study.

Lateral cephalometric measurements

All lateral cephalometric radiographs were scanned and digitized on screen by means of customized software (Viewbox 3.01, dHAL Orthodontic Software). All radiographs were taken with the same x-ray equipment (Orthophos 10, Siemens, Erlangen, Germany) and under the same conditions (magnification 10%). Sagittal and vertical movements were estimated by measuring the distances of the centroid points of the first upper molar, the second upper premolar, and the upper central incisor from the pterygoid vertical (PtV) and the palatal planes, respectively (Figure 5). Life-size values were used for the description of the results. Tipping changes were measured with reference of the long axes of the teeth to the Sella-Nasion plane.

Error of the methods

The whole measurement procedure was repeated 2-4 weeks after the initial measurements. The error of both methods was calculated according to the formula $Se = \sqrt{\Sigma d^2 / 2\mu}$ where Σd^2 is the sum of the squared differences between pairs of recordings and μ is the number of duplicate measurements.²⁰

The sagittal tooth changes of the first molars and the second premolars were underestimated on the lateral cephalometric radiographs. It was decided to rely on the results obtained through the 3D laser scanner for all measurements except the tipping of the first molars, second premolars, and central incisors, which could be measured only on the radiographs.

RESULTS [Return to TOC](#)

The 3D cast analysis was associated with significantly less variation and error than the cephalometric assessment (Table 1). Figure 6 shows the mean tracing combining the data obtained from the 3D cast digitization. The total and effective sagittal movements of the first molars, second premolars, canines, and incisors, the mean asymmetric mesiodistal effect, and the vertical, lateral, tipping, and rotational changes are presented in Table 2.

In summary, the space created between the first molars and the second premolars averaged 6.1 mm. However, only 2.8 mm (46%) of this space was due to the distalization of the first molars, which was accompanied by distal tipping (6.8°) and distal rotation (7.9°). Loss of anchorage was demonstrated mainly by a mesial movement and tipping of the canines and second premolars and by a proclination of the central incisors.

DISCUSSION [Return to TOC](#)

Distal movement of both first and second upper molars in full occlusion is considered extremely difficult to accomplish without patient cooperation or substantial anchorage loss. The intraoral appliance used in this study was successfully used for the simultaneous distalization of maxillary first and second molars into a bilateral Class I molar relationship (Figure 7) in all cases. After its removal, the first molars were stabilized by means of a transpalatal appliance for a period of two months before the final stage of orthodontic treatment with full fixed appliances. The stabilization was to encourage the spontaneous distal drift of the first and second premolars, taking advantage of the transeptal fibers pull.

The space created between the maxillary first molars and second premolars using the present noncompliance appliance averaged approximately six mm. A part of this space was due to distal tipping of the first molars and part due to mesial tipping of the second premolars. Distal movement of the molar crown accounted for the 46% of the total space created on each side. However, individual variations as well as differences between the right and the left side in the same patient were significant.

The findings of this study confirm the results of previous studies using similar noncompliance distalizing modalities with nickel-titanium coil springs.^{4,6,7,21-23} In these studies, the samples consisted of patients with either unerupted⁷ or both erupted and unerupted^{6,21,23} second molars. The upper second molars had fully erupted in all cases in only two of these studies.^{4,22} However, the influence of the second molars on the distal movement of the first molars remains a matter of controversy.


It has been reported that the presence of second molars increases the duration of treatment time,^{21,24} produces more tipping⁴ and more anchorage loss,²⁵ and that tipping of the second molar is greater when a third molar bud is present.²⁵ Germectomy of wisdom teeth has been recommended to achieve bodily distalization of both molars.²⁵ On the other hand, some authors have reported that the presence and the position of second molars do not influence the amount and the type of maxillary first molar distalization.²⁶⁻²⁸

In the present study, anchorage loss manifested as mesial movement, mesial tipping, buccal displacement, and a slight mesial rotation of the second premolars. A most interesting finding was the asymmetric effect, which amounted to more than 1.5 mm. This observation could be attributed to the different states of leveling and alignment between the two sides of the dental arch. The canines moved also mesially and buccally. Individual variations and asymmetric effect were also apparent in the case of the anterior teeth, with the midline off to either direction almost one mm on average. The absence or irregularity of contact points between spaced or severely crowded teeth probably diminished the capacity of the anchorage unit to resist forward movement. Another factor that could partially explain individual variation is the anatomical characteristics of the palatal vault. Patients with insufficient seating of the Nance button because of reduced palatal vault inclination might not be suitable candidates for noncompliance maxillary molar distalization.

It has been shown that the palatal rugae can be used as reference for the assessment of tooth movements.¹⁶⁻¹⁸ Although there are small differences concerning the most reliable

among them, there is general agreement that they can be used as reference points for tooth movements. The presence of a Nance holding arch may be a problem because it normally contacts an area of the palate immediately below the major rugae. In the present study, the zone of the palate along the midline raphe was also used for the 3D superimposition because it has been shown to enhance the reliability of the whole procedure.¹⁹ The superimposition area used in this study is thus a multiplanar surface with uniform relief characteristics, clearly and easily defined in the three planes of space even in the case of partially missing or imprecise information (eg, errors in the pouring technique or elastic deformation of the palatal rugae due to the Nance appliance).

In previous studies where treatment changes were measured on cephalometric radiographs, one of the major limitations imposed by the design was the inability to evaluate tooth movements in the transverse dimension. In the present study, lateral cephalometric radiographs were used only for the assessment of mesiodistal inclination changes. The sagittal and vertical tooth movements were also measured on the radiographs using as reference the pterygoid vertical (PtV) and the palatal planes, respectively. These linear measurements, however, were not used because the variation and the error associated with the cephalometric data were significantly greater as compared with the 3D cast analysis.

The sagittal movements of the first molars and the second premolars were somewhat underestimated as compared with the findings of the 3D cast analysis. This was expected to a certain degree because the reference point (centroid) used for the cephalometric measurements lies more apical than the one used for the 3D cast analysis and is, thus, less influenced by the mesiodistal inclination of teeth. Another reason could be that in the lateral cephalometric radiograph the actual tooth movements are inevitably projected on the midsagittal plane (Figure 4 ). These facts could explain why the sagittal displacement of the central incisors, which lie on the midsagittal plane, was almost identical using both methods. The projection of the two sides of the dental arch on the midsagittal plane leads to the problem of double structure identification, which can be extremely difficult to resolve.

Another significant problem was the selection of a reference plane that would remain stable during treatment.²⁰ Small linear changes can be significantly influenced by growth when tooth position is measured as a distance from a remote reference plane, especially during a long observation period. For example, a methodological error of 0.5 mm, which is common in linear cephalometric measurements, can be extremely important when the measured variable has a mean of just a few millimeters.

CONCLUSIONS [Return to TOC](#)

The noncompliance intraoral appliance used in this study helped to distalize the upper first and second molars simultaneously into a bilateral Class I molar relationship in all cases. However, distal movement of the first molar crown accounted only for the 46% of the total space created on each side. Anchorage loss was expressed as a considerable mesial movement and tipping of the anterior anchorage unit. A substantial variation among patients and an asymmetric mesiodistal effect were observed. Noncompliance simultaneous distalization of the first and second maxillary molars can be an efficient option for the correction of Class II molar relationship. However, case selection is strongly recommended because significant anterior crowding or spacing can lead to disproportionate anchorage loss.

REFERENCES [Return to TOC](#)

1. McSherry PF, Bradley H. Class II correction-reducing patient compliance: a review of the available techniques. *J Orthod.* 2000; 27:219–225.
2. Papadopoulos MA. Simultaneous distalization of maxillary first and second molars by means of superelastic NiTi coils. *Hell Orthod Rev.* 1998; 1:71–76.
3. Papadopoulos MA, Mavropoulos A, Karamouzou A. Cephalometric changes following simultaneous first and second maxillary molar distalization using a non-compliance intraoral appliance. *J Orofac Orthop.* 2004; 65:123–136.
4. Bondemark L, Kurol J, Bemhold M. Repelling magnets versus superelastic nickel-titanium coils in simultaneous distal movement of maxillary first and second molars. *Angle Orthod.* 1994; 64:189–198. [[PubMed Citation](#)]
5. Giancotti A, Cozza P. Nickel titanium double-loop system for simultaneous distalization of first and second molars. *J Clin Orthod.* 1998; 32:255–260. [[PubMed Citation](#)]
6. Brickman CD, Sinha PK, Nanda RS. Evaluation of the Jones jig appliance for distal molar movement. *Am J Orthod Dentofacial Orthop.* 2000; 118:526–534. [[PubMed Citation](#)]
7. Haydar S, Uner O. Comparison of Jones jig molar distalization appliance with extraoral traction. *Am J Orthod Dentofacial Orthop.* 2000; 117:49–53. [[PubMed Citation](#)]
8. Bolla E, Muratore F, Carano A, Bowman SJ. Evaluation of maxillary molar distalization with the distal jet: a comparison with other contemporary methods. *Angle Orthod.* 2002; 72:481–494. [[PubMed Citation](#)]
9. Kjellberg H, Kiliaridis S, Thilander B. Dentofacial growth in orthodontically treated and untreated children with juvenile chronic arthritis (JCA). A comparison with Angle Class II division 1 subjects. *Eur J Orthod.* 1995; 17:357–373. [[PubMed Citation](#)]
10. Kuroda T, Motohashi N, Tominaga R, Iwata K. Three-dimensional dental cast analyzing system using laser scanning. *Am J Orthod Dentofacial Orthop.* 1996; 110:365–369. [[PubMed Citation](#)]
11. Motohashi N, Kuroda T. A 3D computer-aided design system applied to diagnosis and treatment planning in orthodontics and orthognathic surgery. *Eur J Orthod.* 1999; 21:263–274. [[PubMed Citation](#)]
12. Papadopoulos MA, Christou PK, Athanasiou AE, Boettcher P, Zeilhofer HF, Sader R, Papadopoulos NA. Three-dimensional craniofacial reconstruction imaging. *Oral Surg Oral Med Oral Pathol Oral Radiol Endod.* 2002; 93:382–393. [[PubMed Citation](#)]
13. Hirogaki Y, Sohura T, Satoh H, Takahashi J, Takada K. Complete 3-D reconstruction of dental cast shape using perceptual grouping. *IEEE Trans Med Imaging.* 2001; 20:1093–1101. [[PubMed Citation](#)]
14. Hayashi K, Uechi J, Mizoguchi I. Three-dimensional analysis of dental casts based on a newly defined palatal reference plane. *Angle Orthod.* 2003; 73:539–544. [[PubMed Citation](#)]
15. Quimby ML, Vig KWL, Rashid RG, Firestone AR. The accuracy and reliability of measurements made on computer-based digital models. *Angle Orthod.* 2004; 74:298–303. [[PubMed Citation](#)]
16. Almeida MA, Phillips C, Kula K, Tulloch C. Stability of the palatal rugae as landmarks for analysis of dental casts. *Angle Orthod.* 1995; 65:43–48. [[PubMed Citation](#)]
17. Bailey LT, Esmailnejad A, Almeida MA. Stability of the palatal rugae as landmarks for analysis of dental casts in extraction and nonextraction cases. *Angle Orthod.* 1996; 66:73–78. [[PubMed Citation](#)]
18. Hoggan BR, Sadowsky C. The use of palatal rugae for the assessment of anteroposterior tooth movements. *Am J Orthod Dentofacial Orthop.* 2001; 119:482–488. [[PubMed Citation](#)]
19. Miller RJ, Kuo E, Choi W. Validation of Align Technology's Treat III digital model superimposition tool and its case application. *Orthod Craniofac Res.* 2003; 6: (suppl. 1). 143–149.
20. Dahlberg G. *Statistical Methods for Medical and Biological Students.* London: Allen & Unwin; 1940:122–132.
21. Gianelly AA, Bednar J, Dietz VS. Japanese NiTi coils used to move molars distally. *Am J Orthod Dentofacial Orthop.* 1991; 99:564–566. [[PubMed Citation](#)]

22. Gulati S, Kharbanda OP, Parkash H. Dental and skeletal changes after intraoral molar distalization with sectional jig assembly. *Am J Orthod Dentofacial Orthop.* 1998; 14:319–327.

23. Runge ME, Martin JT, Bukai F. Analysis of rapid maxillary molar distal movement without patient cooperation. *Am J Orthod Dentofacial Orthop.* 1999; 15:153–157.

24. Gianelly AA, Vaitas AS, Thomas WM. The use of magnets to move molars distally. *Am J Orthod Dentofacial Orthop.* 1989; 96:161–167. [[PubMed Citation](#)]

25. Kinzinger GS, Fritz UB, Sander FG, Diedrich PR. Efficiency of a pendulum appliance for molar distalization related to second and third molar eruption stage. *Am J Orthod Dentofacial Orthop.* 2004; 125:8–23. [[PubMed Citation](#)]

26. Bussick TJ, McNamara JA Jr. Dentoalveolar and skeletal changes associated with the pendulum appliance. *Am J Orthod Dentofacial Orthop.* 2000; 117:333–343. [[PubMed Citation](#)]

27. Byloff FK, Darendeliler MA. Distal molar movement using the pendulum appliance. Part 1: Clinical and radiological evaluation. *Angle Orthod.* 1997; 67:249–260. [[PubMed Citation](#)]

28. Muse DS, Fillman MJ, Emmerson WJ. et al. Molar and incisor changes with Wilson rapid molar distalization. *Am J Orthod Dentofacial Orthop.* 1993; 104:556–565. [[PubMed Citation](#)]

29. Isaacson RJ. Superimposition and structural analysis. *Am J Orthod Dentofacial Orthop.* 1996; 109:193–195. [[PubMed Citation](#)]

TABLES [Return to TOC](#)

TABLE 1. Mean, Standard Deviation, and Error of the Method for the Main Variables Under Study Measured Using the Three-dimensional (3D) Cast Analysis or Cephalometrics (or Both)^a

	Movement	3D Cast Analysis, mm (Mean and SD)	Error of the Method ^b	Cephalometrics (Mean and SD)	Error of the Method ^b
First molars	Sagittal	-2.80 (0.84)	0.21	-1.90 mm (2.12)	0.47
	Vertical	-0.55 (0.33)	0.13	-0.63 mm (0.90)	0.25
	Tipping	—	—	-6.8° (4.8)	1.58
Second premolars	Sagittal	+3.32 (1.02)	0.21	+2.08 mm (2.04)	0.49
	Vertical	+0.87 (0.34)	0.12	+0.72 mm (0.56)	0.23
	Tipping	—	—	+7.5° (5.9)	1.36
Incisors	Sagittal	+1.89 (0.76)	0.16	+1.80 mm (2.86)	0.39
	Tipping	—	—	+5.16° (3.44)	1.19

^a '+' indicates mesial or extrusive movement; '-', distal or intrusive.

^b Estimated using Dahlberg's formula.²⁹

TABLE 2. Evaluation of Movement of All Teeth Under Investigation After the Use of the Noncompliance Molar-distalizing Intraoral Appliance. Values are Given as Mean ± SD (Range in Parentheses)^a

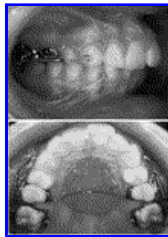
	Total Movement, mm	Effective (Mesiodistal) Movement, mm	Asymmetric Mesiodistal Effect, mm
Active unit			
First molars	2.82 ± 1.08 (0.46 to 4.3)	-2.80 ± 0.84 (-1.45 to -4.29)	0.97 ± 0.70 (0.11 to 2.14)
Anchorage unit			
Second premolars	3.50 ± 1.11 (2.19 to 5.66)	+3.32 ± 1.02 (+2.06 to +5.25)	1.87 ± 1.67 (0.22 to 5.62)
Canines	3.09 ± 0.66 (1.93 to 3.98)	+2.41 ± 1.05 (+0.49 to +3.76)	1.69 ± 1.47 (0.07 to 4.00)
Incisors	2.35 ± 0.80 (1.43 to 3.65)	+1.89 ± 0.76 (+1.11 to +3.48)	0.90 ± 1.01 (0.07 to 3.42)

^a '+' indicates mesial, buccal, or extrusive movement; '-', distal, palatal, or intrusive movement; R, right; L, left.

^b As measured in cephalometric radiographs.

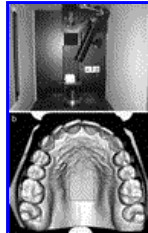
TABLE 2. Extended

Tipping (°) ^b	Vertical Movement, mm	Lateral Movement, mm	Rotation (°)
-6.8 ± 4.8 (-0.6 to -14.4)	-0.55 ± 0.33 (-0.08 to -1.09)	-0.24 ± 0.66 (-1.29 ± +0.96)	-7.9 ± 4.9 (-0.5 to -15.9)
+7.5 ± 5.9 (+3.1 to +20.3)	+0.87 ± 0.34 (+0.29 to +1.30)	+0.73 ± 0.59 (-0.09 to +1.70)	+3.7 ± 1.9 (+0.9 to +8.0)
—	—	+1.25 ± 0.35 (+0.64 to +1.86)	—
5.2 ± 3.4 (+0.1 to +9.5)	—	0.22 R ± 1.37 (1.37 L to 3.42 R)	—



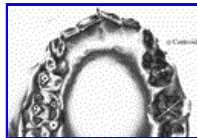
Click on thumbnail for full-sized image.

FIGURE 1. Lateral (A) and occlusal view (B) of the used intraoral appliance



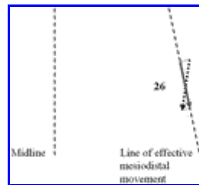
Click on thumbnail for full-sized image.

FIGURE 2. (A) The 3D laser scanner assembly. (B) An example of a cast occlusal surface as seen on screen. The gray shaded area corresponds to the region where the 3D superimposition was performed



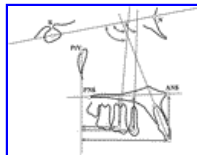
Click on thumbnail for full-sized image.

FIGURE 3. The result of the fusion of the two holograms after their superimposition on the palate. Colors are used to facilitate the reading of the image



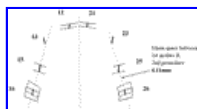Click on thumbnail for full-sized image.

FIGURE 4. The definition of effective movement as applied in this study. The true (effective) mesiodistal movement of the tooth corresponds to the projection of the actual movement on the axis of the lateral segment of the arch where it happens



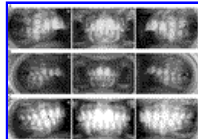
Click on thumbnail for full-sized image.

FIGURE 5. Cephalometric linear and angular measurements



Click on thumbnail for full-sized image.

FIGURE 6. Mean tracing, where the mean positional changes of the teeth under investigation, are shown in solid thick lines. Dashed and solid thin lines represent the position of the teeth before and after treatment, respectively



Click on thumbnail for full-sized image.

FIGURE 7. Presentation of a case: intraoral photographs (A) before treatment, (B) after removal of the distalizing appliance, and (C) after removal of fixed appliances

^aLecturer, Department of Orthodontics, School of Dental Medicine, University of Geneva, Geneva, Switzerland

^bResearch Associate, Department of Orthodontics, School of Dentistry, Aristotle University of Thessaloniki, Thessaloniki, Greece

^cProfessor and Chairman, Department of Orthodontics, School of Dental Medicine, University of Geneva, Geneva, Switzerland

^dAssistant Professor and Postgraduate Program Coordinator, Department of Orthodontics, School of Dentistry, Aristotle University of Thessaloniki, Thessaloniki, Greece

Corresponding author: Moschos A. Papadopoulos, DDS, Dr Med Dent, Department of Orthodontics, School of Dentistry, Aristotle University of Thessaloniki, GR-54124 Thessaloniki, Greece (E-mail: mikepap@dent.auth.gr)