

[\[Print Version\]](#)
[\[PubMed Citation\]](#) [\[Related Articles in PubMed\]](#)

TABLE OF CONTENTS

[\[INTRODUCTION\]](#) [\[MATERIALS AND...\]](#) [\[RESULTS\]](#) [\[DISCUSSION\]](#) [\[CONCLUSIONS\]](#) [\[REFERENCES\]](#) [\[TABLES\]](#) [\[FIGURES\]](#)

The Angle Orthodontist: Vol. 75, No. 4, pp. 568-575.

Magnetic Resonance Imaging of the Condylar Growth Pattern and Disk Position after Chin Cup Therapy: A Preliminary Study

Hatice Gökalp,^a Gökmen Kurt^b

ABSTRACT

This study was conducted on lateral cephalograms and magnetic resonance images (MRIs) obtained from 20 subjects with Class III malocclusion. Only clinically temporomandibular joint (TMJ) symptom-free subjects were included in this study. In the treatment group, a chin cup with 600 g of force was applied in 13 patients (10 girls and three boys) with a mean age of nine years. The chin cup was applied in a direction from the chin toward the TMJ. The control group consisted of seven patients (six girls and one boy) with a mean age of eight year nine months. Orthodontic treatment was not applied in the control group. Records were taken at the beginning and end of chin cup therapy from all the subjects. Measurements were made on lateral cephalograms and unilateral-left sagittal-oblique TMJ MRIs. Variables obtained at the beginning and end of the study were compared by Student's *t*-tests and paired *t*-tests. Relationships between craniofacial and TMJ variables were analyzed by correlation analysis. The mandibular corpus length was increased and condylar head angle was decreased by chin cup therapy. A positive correlation existed between activation of sagittal maxillary and mandibular growth and bending of the condylar head. This study showed that the condylar growth pattern was altered by chin cup. It may be implied that the source of improvement is adaptation of the craniofacial structures to the changes of the condylar growth pattern produced by the chin cup.

KEY WORDS: Chin cup, Class III malocclusion, Condylar growth pattern, MRI, Prognathia inferior, TMJ.

Accepted: July 2004. Submitted: March 2004

INTRODUCTION [Return to TOC](#)

Condylar growth is affected by mechanical stimuli. The chin cup is an orthopedic appliance that is designed to apply pressure on the temporomandibular joint (TMJ) to restrict or redirect the condylar growth. Morphologic and biologic changes of the mandible from orthopedic chin cup forces have been investigated extensively by means of cephalometric and experimental studies.¹⁻¹¹ However, it is not yet clear where the improvement in the skeletal Class III malocclusion originates from with chin cup therapy. Although experimental studies have demonstrated that the remodeling process of the condyle is changed after retraction forces,⁹⁻¹¹ there are a few studies about changes in the condylar and disk morphology and position after chin cup therapy.¹² Magnetic resonance imaging is the most appropriate and noninvasive method that gives almost similar results as histologic sections to clarify the question how the condylar growth is changed by chin cup therapy in humans.

Based on this statement, the aim of this study was to use magnetic resonance imaging to investigate where the improvement in skeletal Class III malocclusion originates from with chin cup therapy.

MATERIALS AND METHODS [Return to TOC](#)

Twenty subjects with mandibular prognathism were included in this study. Thirteen subjects (10 girls and three boys) with a mean age of 9.06 years composed the chin cup treatment group, whereas seven subjects (six girls and one boy) with a mean age of 8.90 years constituted the control group. TMJ functions of all the subjects were evaluated clinically. Each subject was questioned about TMJ pain, joint sounds, and limitation of mouth opening, and only clinically symptom-free subjects were included in this study.

Whereas chin cup was applied on the treatment group, the control group was only observed without any intervening orthodontic treatment. A chin cup with 600 g of force was applied in a TMJ direction. It was worn for 18 hours a day. Lateral cephalograms, hand-wrist films, and unilateral-left sagittal-oblique TMJ magnetic resonance images (MRIs) in a closed mouth position were obtained at the beginning and end of the chin cup therapy and the control period from all subjects. The magnetic resonance imaging was performed on a 1.5-T MR scanner (GE Medical System, Milwaukee, Wis).

Unilateral receiver surface coils with a diameter of eight cm were used. A transaxial locator sequence was used for patient orientation and positioning. The head was supported by a polyurethane foam head positioner to enable stabilization of the skull so that the midsagittal plane of the imager was perpendicular to the midpoint of the long axis of the condyle. A spin echo technique (repetition time [TR] = 0.5 seconds and echo time [TE] = 21 mseconds) was used. Five contiguous three-mm thick parasagittal images with matrix size 256 × 128 were obtained. Central parasagittal planes were used for evaluation of the MRIs. Before and after chin cup therapy MRIs are shown in [Figure 1A,B](#). When positive overjet and overbite were obtained, treatment was finished. The average treatment time was one year seven months.

Points used on the lateral cephalograms and MRIs are shown in [Figures 2 through 5](#). Measurements made on MRIs are shown in [Figures 3 through 5](#). Linear and angular measurements were carried out for the left TMJ on sagittal MRIs to evaluate both the disk position associated with the condyle and the condylar position associated with the glenoid fossa and condylar head morphology.

Angular measurements of the disk position relative to the condyle were made. A line at the 12 o'clock position identified the normal position of the disk. This line was drawn from the

center of the condyle (Cc) to the center of curvature of the top surface of the condyle (Ct) and to the posterior margin of the posterior band of the disk (dp) (junction of posterior band and bilaminar zone). The angle between these lines (dp-Cc-Ct) was measured (Figure 3).¹³⁻¹⁶ To evaluate condyle head morphology, the condylar head angle occurring between the condyle head (Cc-Ct) and the condylar neck (Cc point–long axis of condylar neck) was measured (Figure 4).

To evaluate condyle position relative to the glenoid fossa, the following equation was used:¹⁷

$$\frac{\text{Posterior joint space} - \text{Anterior joint space}}{\text{Posterior joint space} + \text{Anterior joint space}} \times 100$$

By determining posterior and anterior joint spaces, the narrowest posterior (Cp-Cp') and anterior (Ca-Ca') interarticular distances were measured (Figure 5). The percentage was zero when the condyle was positioned concentrically in the glenoid fossa. A positive value indicates anterior condylar positioning, and a negative value indicates posterior condylar positioning. When deviation from concentricity is more than 12%, a definite displacement of the condyle into the glenoid fossa was described.¹⁵ Lateral head cephalograms were analyzed by conventional methods to describe the skeletal features of the subjects (Figure 2).

Error of the method

Measurements were made twice with a 20-day interval to determine the repeatability of landmark identification and measurement techniques. All angular and linear variables had a coefficient of intrarater reliability ($r = \frac{\Sigma^2_{\text{total}}}{\Sigma^2_{\text{between}}}$) between 0.88 and 1.00. This means, the error is considered negligible.

Statistical method

Study groups were matched by Student's *t*-tests at the beginning of the study to evaluate similarity (Table 1). The same analysis was used for comparing both groups at the end of treatment (Table 2). Changes obtained from chin cup therapy and spontaneous changes obtained at the end of observation period were evaluated by paired *t*-tests (Tables 3 and 4, respectively). Skeletal parameters obtained from lateral cephalograms and TMJ parameters obtained from MRIs were analyzed with a Pearson correlation analysis for both chin cup and observation groups (Tables 5 and 6, respectively).

RESULTS [Return to TOC](#)

When the groups were compared at the beginning of the study, the TMJ and skeletal variables were similar, except for Go-Gn and Co-Gn (Table 1). A paired *t*-test was used for evaluating changes in TMJ and skeletal variables occurring during treatment and the control period (Tables 2 and 3, respectively). Minimum changes were observed between TMJ components and condylar morphology by using the chin cup. However, significant changes in skeletal variables occurred in the chin cup group. Although sagittal maxillary growth was activated by chin cup therapy, sagittal mandibular growth was inhibited ($P < .01$, Table 2). As a result of this change, the ANB angle was reduced. Although retraction forces were applied by the chin cup, the increase in mandibular corpus and ramus lengths continued ($P < .05$, Table 2). In addition to these changes, reduction of the gonial angle and positive changes in overjet were observed in the chin cup therapy group.

Statistically significant changes were not obtained in TMJ variables during the control period (Table 3). Vertical ramus length and effective mandibular length were spontaneously increased in the control group ($P < .05$ and $P < .01$, respectively, Table 3).

At the end of the treatment, no differences could be measured between the skeletal variables except for the mandibular corpus length in both study groups ($P < .01$, Table 4).

Correlation coefficients were calculated between the TMJ variables on MRI and the skeletal variables on lateral cephalograms separately in both groups. A positive correlation existed between the condyle position in the glenoid fossa and gonial angle in the control group ($P < .05$, Table 5). A positive correlation was found between maxillary and mandibular sagittal growth and the condylar head morphology in the chin cup group ($P < .05$, Table 6). A negative correlation was observed between the condyle position in the glenoid fossa and the overjet ($P < .05$, Table 6).

DISCUSSION [Return to TOC](#)

Because the control group was younger than the chin cup group, a significant difference in mandibular corpus length and effective mandibular length existed between the groups. Although the study was not able to evaluate the difference in effective mandibular length between the groups, mandibular corpus length was found to be shorter in the control group than in the treatment group, despite the application of chin cup therapy.

Whether mandibular growth is restricted or redirected by chin cup therapy has been a matter of debate in the literature. However, the mechanism by which a chin cup results in improvement in the case of skeletal Class III malocclusion has not yet been made clear. It is well known that mandibular growth is affected primarily by condylar growth.¹⁸ However, it must be emphasized that the condylar growth is not a unique factor in growth and development of the craniofacial complex.¹⁸ Thus, it would be an oversimplification to attribute mandibular growth to condylar growth potential only. The literature offers different concepts for the clarification of growth and development of the craniofacial complex.¹⁸⁻²³ The mandible grows through condylar growth and mandibular remodeling. The direction of the condylar growth may vary considerably.²⁰ This is especially well demonstrated by studies involving the use of metallic implants, which show that the growth of the condyle varies between upward-backward and upward-forward. The size of the mandible changes by periosteal and endosteal apposition and resorption.^{19,21}

With the chin cup, a posterosuperior orthopedic force is directed from the chin to the condyle, applying pressure on the TMJ. The results of our study clearly indicate that the condylar head in the chin cup group was bent forward, although the change in position was not statistically significant. In contrast, the condylar head angle in the control group was not noticeably changed. Forward bending of the condylar head led to a degree of remodeling in the condyle.

Through the application of posterosuperior pressure on the mandible, the lateral pterygoid muscle is stretched in the manner of an activated spring. The resulting tension is distributed to the anterior surface of the condylar head and the posterior surface of the pterygoid plates because of the attachment of the medial pole of the lateral pterygoid muscle to the processus pterygoideus and that of the distal pole to the anterior surface of the condylar head. Tensional stress causes bone deposition on the anterior surface of condylar head.

A number of methods have been used to reveal the tensional effects of these retractile forces.^{24,25} Tanne et al²⁵ demonstrated that a chin cup creates compressive stress that is concentrated at the neck of the condyle and leads to inhibition of the bone deposition on the anterior surface of the condylar neck.⁸ The combined stimulation of bone deposition on the anterior surface of the condylar head and inhibition of bone deposition on the condylar neck results in forward bending of the condylar head.

Changes in the condylar growth due to external forces effect remodeling of the mandible. Björk²¹ stated that when the direction of condylar growth is upward and forward in relation to the mandibular base, the lowering of the posterior part of the mandible will usually exceed that of its anterior part. The resulting mandibular rotation is termed forward growth of rotation. In this case the mandibular border displays marked resorption below the gonial angle and apposition below the symphysis. In a forward condylar growth pattern, the condylar neck is relocated in a higher position because of apposition on the lower segment of ramus and resorption on its upper segment.²¹ In this study, mandibular body length increased during chin cup therapy. Ramus height (Co-Go) was increased in the chin cup group through forward bending of the condylar head. However, the length of the ramus was longer in the control group

than in the chin cup group. Accordingly, it may be concluded that a chin cup controls increases in the mandibular ramus length.

The TMJ disk is fibrocartilaginous and more flexible than the condyle. The inferior head of the lateral pterygoid muscle is attached to the anterior surface of the mandible, and the superior head is attached to the anterior border of the TMJ disk. When the condyle head is bent forward because of chin cup pressure, the condyle head rotates along the inferior surface of the disk. Both rotational movement of the condyle and stretching of the superior head of the lateral pterygoid muscle move the disk anteriorly. In our study, the disk was relocated in a slightly anterior position relative to the condyle as a result of this process.

Our study found similar increases in the maxillary length of both groups after treatment. This may indicate that correction of the anterior crossbite accelerated forward growth of the maxilla in the chin cup group.

There was a positive correlation between the increase of condylar head bending and the maxillomandibular positioning relative to the cranium. This correlation supports the idea that a chin cup creates a new growth pattern in the condyle.

CONCLUSIONS [Return to TOC](#)

This study shows that application of a chin cup creates morphologic changes in the temporomandibular area and that these changes stimulate a remodeling of the mandible. For this reason, improvement of skeletal Class III malocclusion can be understood to consist of a combination of both morphologic changes of the TMJ and remodeling of the mandible.

A chin cup triggers the following cycle:

- tension of lateral pterygoid muscle;
- activation of sagittal maxillary growth;
- bending of condylar head by apposition of anterior surface of condylar head and resorption of anterior surface of condylar neck;
- changes in the condylar growth pattern;
- activation of compensation mechanism in the mandible;
- increase in ramus height;
- decrease in the gonial angle;
- maintenance of positive overjet and overbite;
- control of sagittal mandibular growth;
- protection of ideal relationship between TMJ components.

REFERENCES [Return to TOC](#)

1. Irie M, Nakamura S. Orthodontic approach to severe skeletal Class III malocclusion. *Am J Orthod.* 1975; 67:377–392. [[PubMed Citation](#)]
2. Graber LW. Chincup therapy for mandibular prognathism. *Am J Orthod.* 1977; 72:23–41. [[PubMed Citation](#)]
3. Sakamoto T. Effective timing for the application of orthopedic force in the skeletal Class III malocclusion. *Am J Orthod.* 1981; 80:411–416. [[PubMed Citation](#)]
4. Wendell PD, Nanda R. The effects of chin cup therapy on the mandible: a longitudinal study. *Am J Orthod.* 1985; 87:265–274. [[PubMed Citation](#)]
5. Sugawara J, Asano T, Endo N, Mitani H. Long-term effects of chincap therapy on skeletal profile in mandibular prognathism. *Am J Orthod Dentofacial Orthop.* 1990; 98:127–133. [[PubMed Citation](#)]
6. Mitani H, Fukasawa H. Effects of chincap force on the timing and amount of mandibular growth associated with anterior reversed occlusion (Class III malocclusion) during puberty. *Am J Orthod Dentofacial Orthop.* 1986; 90:454–463. [[PubMed Citation](#)]
7. Mitani H, Sakamoto T. Chin cap force to a growing mandible: long-term clinical reports. *Angle Orthod.* 1984; 54:93–122. [[PubMed Citation](#)]
8. Mimura H, Deguchi T. Morphologic adaptation of temporomandibular joint after chincup therapy. *Am J Orthod Dentofacial Orthop.* 1996; 110:541–546. [[PubMed Citation](#)]
9. Janzen EK, Bluher JA. The cephalometric, anatomic, and histologic changes in *Macaca mulatta* after application of a continuous-acting retraction force on the mandible. *Am J Orthod.* 1965; 51:823–855. [[PubMed Citation](#)]
10. Joho JP. The effects of extraoral low-pull traction to the mandibular dentition of *Macaca mulatta*. *Am J Orthod.* 1973; 64:555–577. [[PubMed Citation](#)]
11. Asano T. The effects of mandibular retroactive force on the growing rat mandible. *Am J Orthod Dentofacial Orthop.* 1986; 90:464–474. [[PubMed Citation](#)]
12. Gökalp H, Arat M, Erden İ. The changes in temporomandibular joint disc position and configuration in early orthognathic treatment: a magnetic resonance imaging evaluation. *Eur J Orthod.* 2000; 22:217–224. [[PubMed Citation](#)]
13. Katzberg RW, Westesson P-L. *Diagnosis of the Temporomandibular Joint.* 1st ed. Philadelphia, Penn: WB Saunders; 1993:9.
14. Drace JE, Enzmann DR. Defining the normal temporomandibular joint: closed-, partly open-, and open-mouth MR imaging of asymptomatic subjects. *Radiology.* 1990; 177:67–71. [[PubMed Citation](#)]
15. Drace JE, Young SW, Enzmann DR. TMJ meniscus and bilaminar zone: MR imaging of the structure—diagnostic landmarks and pitfalls of interpretation. *Radiology.* 1990; 177:73–76. [[PubMed Citation](#)]
16. Katzberg RW. Temporomandibular joint imaging. *Radiology.* 1989; 170:297–307. [[PubMed Citation](#)]
17. Pullinger GA, Hollender L, Solberg KW, Petersson A. A tomographic study of mandibular condyle position in an asymptomatic population. *J Prosthet Dent.* 1985; 53:706–713.

18. Koshi K. Cranial growth centers; fact or fallacies?. *Am J Orthod.* 1968; 54:566–583. [PubMed Citation]
19. Enlow DH, Harris DB. A study of the postnatal growth of the human mandible. *Am J Orthod.* 1964; 50:25–50.
20. Ricketts RM. Facial and denture changes during orthodontic treatment as analyzed from the temporomandibular joint. *Am J Orthod.* 1955; 41:163–179.
21. Björk A. Variations in the growth pattern of the human mandible: longitudinal radiographic study by the implant method. *J Dent Res.* 1963; 42:400–411. [PubMed Citation]
22. Solow B. The dentoalveolar compensatory mechanism: background and clinical implications. *Br J Orthod.* 1980; 7:145–161. [PubMed Citation]
23. Moss LM, Salentijn L. The primary role of functional matrices in facial growth. *Am J Orthod.* 1969;566–577.
24. de Alba IA, Chaconas SJ, Caputo AA. Orthopedic effect of the extraoral chin cup appliance on the mandible. *Am J Orthod.* 1976; 69:29–41. [PubMed Citation]
25. Tanne K, Tanaka E, Sakuda M. Stress distribution in the temporomandibular joint produced by orthopedic chin cup forces applied in varying directions: a three-dimensional analytic approach with the finite element method. *Am J Orthod Dentofacial Orthop.* 1996; 110:502–507. [PubMed Citation]

TABLES [Return to TOC](#)

TABLE 1. Comparison of the Skeletal and TMJ^a Variables of the Chin Cup and Control Groups at the Beginning of the Study

Variables	Before Chin Cup Therapy ($\bar{x} \pm s\bar{x}$)	Before Observation Period ($\bar{x} \pm s\bar{x}$)	Significance ^b
TMJ measurements			
Disk position	2.99 ± 6.77	7.01 ± 4.51	NS
Condyle position	11.25 ± 24.98	13.56 ± 13.70	NS
Condyle angle	110.65 ± 8.59	114.45 ± 7.01	NS
Skeletal measurements			
SNA	78.27 ± 2.41	78.29 ± 5.53	NS
SNB	80.92 ± 3.92	80.71 ± 4.67	NS
ANB	-2.65 ± 2.86	-2.42 ± 1.92	NS
GoGn-SN	33.92 ± 6.58	36.14 ± 7.43	NS
Go-Gn	70.31 ± 3.08	65.31 ± 4.65	**
Co-Go	46.11 ± 4.17	46.22 ± 3.95	NS
Co-Gn	103.72 ± 4.44	99.05 ± 5.39	*
Gonial angle	132.72 ± 6.92	128.78 ± 11.59	NS
Overjet	-3.88 ± 3.89	-1.61 ± 1.05	NS
Overbite	2.55 ± 2.87	2.321 ± 1.37	NS
Chronological age	9.06 ± 1.82	8.90 ± 1.78	NS

^a TMJ, temporomandibular joint.

^b Significance level: NS, nonsignificant; * $P < .05$; ** $P < .01$.

TABLE 2. Evaluation of Treatment Effects Created by Chin Cup

Variables	Before Chin Cup Therapy ($\bar{x} \pm s\bar{x}$)	After Chin Cup Therapy ($\bar{x} \pm s\bar{x}$)	Significance ^a
TMJ measurements^b			
Disk position	2.99 ± 6.77	4.53 ± 7.41	NS
Condyle position	11.25 ± 24.98	11.90 ± 25.12	NS
Condyle head angle	110.65 ± 8.59	105.69 ± 11.20	NS
Skeletal measurements			
SNA	78.27 ± 2.41	79.81 ± 3.30	**
SNB	80.92 ± 3.92	78.00 ± 3.51	**
ANB	-2.65 ± 2.86	1.73 ± 2.33	**
GoGn-SN	33.92 ± 6.58	35.50 ± 5.65	NS
Go-Gn	70.31 ± 3.08	71.533 ± 2.63	*
Co-Go	46.11 ± 4.17	47.04 ± 3.94	*
Co-Gn	103.72 ± 4.44	104.30 ± 5.45	NS
Gonial angle	132.72 ± 6.92	130.70 ± 6.59	*
Overjet	-3.88 ± 3.89	1.94 ± 1.31	**
Overbite	2.55 ± 2.87	1.10 ± 1.45	NS
Chronological age	9.06 ± 1.82	10.72 ± 1.97	**

^a Significance level: NS, nonsignificant; * $P < .05$; ** $P < .01$.

^b TMJ, temporomandibular joint.

TABLE 3. Evaluation of Spontaneous Changes Created by Observation Period in the Control Group

Variables	Before Observation Period ($\bar{x} \pm s\bar{x}$)	After Observation Period ($\bar{x} \pm s\bar{x}$)	Significance ^a
TMJ measurements^b			
Disk position	7.01 ± 4.51	4.07 ± 3.92	NS
Condyle position	13.56 ± 13.70	15.90 ± 29.60	NS
Condyle angle	114.45 ± 7.01	114.46 ± 8.18	NS
Skeletal measurements			
SNA	78.29 ± 5.53	79.86 ± 5.34	NS
SNB	80.71 ± 4.67	81.00 ± 4.55	NS
ANB	-2.42 ± 1.92	-1.14 ± 1.43	NS
GoGn-SN	36.14 ± 7.43	36.00 ± 7.42	NS
Go-Gn	65.31 ± 4.65	67.86 ± 2.60	NS
Co-Go	46.22 ± 3.95	48.91 ± 3.27	**
Co-Gn	99.05 ± 5.39	103.16 ± 3.80	*
Gonial angle	128.78 ± 11.59	130.88 ± 6.41	NS
Overjet	-1.61 ± 1.05	-1.80 ± 0.86	NS
Overbite	2.321 ± 1.37	1.80 ± 1.42	NS
Chronological age	8.90 ± 1.78	10.78 ± 2.08	**

^a Significance level: NS, nonsignificant; * $P < .05$; ** $P < .01$.

^b TMJ, temporomandibular joint.

TABLE 4. Comparison of the Skeletal and TMJ Variables Belonging to the Chin Cup and Control Groups at the End of the Study

Variables	After Chin Cup Therapy ($\bar{x} \pm s\bar{x}$)	After Observation Period ($\bar{x} \pm s\bar{x}$)	Significance ^a
TMJ measurements^b			
Disk position	4.53 ± 7.41	4.07 ± 3.92	NS
Condyle position	11.90 ± 25.12	15.90 ± 29.60	NS
Condyle head angle	105.69 ± 11.20	114.46 ± 8.18	NS
Skeletal measurements			
SNA	79.81 ± 3.30	79.86 ± 5.34	NS
SNB	78.00 ± 3.51	81.00 ± 4.55	NS
ANB	1.73 ± 2.33	-1.14 ± 1.43	NS
GoGn-SN	35.50 ± 5.65	36.00 ± 7.42	NS
Go-GN	71.533 ± 2.63	67.86 ± 2.60	**
Co-Go	47.04 ± 3.94	48.91 ± 3.27	NS
Co-Gn	104.30 ± 5.45	103.16 ± 3.80	NS
Gonial angle	130.70 ± 6.59	130.88 ± 6.41	NS
Overjet	1.94 ± 1.31	-1.80 ± 0.86	*
Overbite	1.10 ± 1.45	1.80 ± 1.42	NS
Chronological age	10.72 ± 1.97	10.78 ± 2.08	NS

^a Significance level: NS, nonsignificant; * $P < .05$; ** $P < .01$.

^b TMJ, temporomandibular joint.

TABLE 5. Correlation of Differences During Control Period in Control Group Parameters Between Temporomandibular Joint and Skeletal Structures

	r^a				
	Disk Position	Condyle Position	Go-Gn	SNB	ANB
Co-Go	-.657*	NS	NS	NS	NS
Co-Gn	NS	NS	-.770*	NS	NS
Gonial angle	NS	-0.562*	NS	NS	NS
GoGn-SN	NS	NS	NS	-.844**	.673*

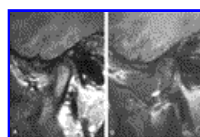
^a Significance level: NS, nonsignificant; * $P < .05$; ** $P < .01$.

TABLE 6. Correlation of Differences During Treatment Period in Treatment Group Parameters Between Temporomandibular Joint and Skeletal Structures

	r^a			
	Condyle Position	Condylar Head Angle	Go-Gn	SNA
Co-Go	NS	NS	.767*	NS
Co-Gn	NS	NS	.955**	NS
SNA	NS	.799*	NS	NS
SNB	NS	.835*	NS	.794*
Overjet	-.901*	NS	NS	NS

^a Significance level: NS, nonsignificant; * $P < .05$; ** $P < .01$.

FIGURES [Return to TOC](#)



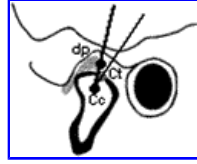
Click on thumbnail for full-sized image.

FIGURE 1. (A, B) TMJ MRIs obtained before and after chin cup therapy, respectively



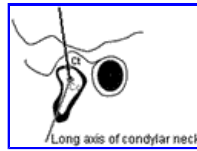
Click on thumbnail for full-sized image.

FIGURE 2. Conventional points are used on lateral cephalograms



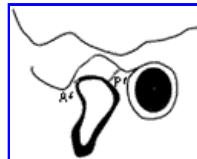
Click on thumbnail for full-sized image.

FIGURE 3. Posterior diskal angle is constructed on points between Ct-Cc-dp. Ct, top of the condyle head; Cc, center of the condyle head; dp, middle point of posterior margin of the posterior band of the disk



Click on thumbnail for full-sized image.

FIGURE 4. Condylar head angle is constructed between Ct-Cc points and long axis of condylar neck



Click on thumbnail for full-sized image.

FIGURE 5. P†: posterior joint space is measured, the narrowest distance between posterior condylar head surface and posterior glenoid fossa surface. A†: anterior joint space is measured, the narrowest distance between anterior condylar head surface and posterior eminence slope

^aAssociate Professor, Department of Orthodontics, School of Dentistry, Ankara University, Ankara, Turkey

^bResearch Assistant, Department of Orthodontics, School of Dentistry, Ankara University, Ankara, Turkey

Corresponding author: Hatice Gökalp, DDS, PhD, Ankara Üniversitesi, Diş Hekimliği Fakültesi, Ortodonti Anabilim Dalı, 06500 Beşevler, Ankara, Turkey (E-mail: haticegokalp@yahoo.com)