

[\[Print Version\]](#)  
[\[PubMed Citation\]](#) [\[Related Articles in PubMed\]](#)

## TABLE OF CONTENTS

[\[INTRODUCTION\]](#) [\[MATERIALS AND...\]](#) [\[RESULTS\]](#) [\[DISCUSSION\]](#) [\[CONCLUSIONS\]](#) [\[REFERENCES\]](#) [\[TABLES\]](#) [\[FIGURES\]](#)

*The Angle Orthodontist*: Vol. 75, No. 6, pp. 959–963.

# Soft and Hard Tissue Changes after Bimaxillary Surgery in Chinese Class III Patients

Ming Tak Chew<sup>a</sup>

## ABSTRACT

Cephalometric studies have shown that the Chinese race tends to have a greater preponderance of skeletal Class III malocclusion. It has also been reported that the soft tissue response to hard tissue movement varies among racial types. The aims of this retrospective cephalometric study were to assess the results of bimaxillary surgery on Chinese subjects presenting with Class III malocclusions and to evaluate the correlation between soft and hard tissue change. The sample consisted of 34 Chinese patients treated with bilateral sagittal split osteotomy and Le Fort I advancement. Lateral cephalograms were taken immediately before surgery and at least six months after surgery. Soft and hard tissue changes were recorded by computer-supported measurements of presurgical and postsurgical lateral cephalograms. Linear regression procedures were used to assess the degree of correlation in terms of soft to hard tissue changes between the two cephalograms. The results showed that there was normalization of the cephalometric variables after surgery. Mandibular soft and hard tissue movements showed a strong correlation in the horizontal direction and a moderate correlation in the vertical direction. Maxillary soft and hard tissue movement showed a moderate to weak correlation in both the horizontal and vertical directions. The ratios of soft to hard tissue movements derived from this study would contribute to the database for planning prediction.

**KEY WORDS:** Class III malocclusion, Orthognathic surgery, Cephalometric analysis.

Accepted: October 2004. Submitted: July 2004

## INTRODUCTION [Return to TOC](#)

Treatment of moderate to severe Class III malocclusion frequently requires a combination of orthodontics and orthognathic surgical procedures. In most cases, the aims of such procedures are not only to correct the dental malocclusions but also to improve facial esthetics and to harmonize the facial profile. Therefore, it is important for the clinician to be able to predict the soft tissue changes resulting from alterations of the hard tissue. Many studies have attempted to evaluate the relationship between hard tissue surgery and the effects it has on the overlying soft tissue.<sup>1-6</sup>

Studies among racial groups have demonstrated that the Chinese tend to have a greater preponderance of skeletal III discrepancies.<sup>7</sup> Lew et al<sup>8</sup> evaluated changes in the soft tissue profile after intraoral ramus osteotomy in 25 Chinese adults with mandibular prognathism and reported ratios of the soft tissue response to hard tissue movement. He concluded that these ratios varied from those reported in Caucasian samples and reiterated the need for different ratios for different racial types. A recent study by Hu et al<sup>9</sup> evaluated the differences by sex in the ratios of soft tissue to hard tissue change in 43 Chinese patients and concluded that there was a need for different ratios for men and women.

It has also been observed that a great proportion of orthognathic cases treated in our Centre involve bimaxillary surgery to correct skeletal III problems. However, little information is available on the soft tissue changes resulting from hard tissue surgery in this group of patients. The aims of this retrospective cephalometric study were (1) to assess the results of bimaxillary surgery on Chinese subjects presenting with Class III malocclusions and (2) to evaluate the correlation between soft and hard tissue change.


## MATERIALS AND METHODS [Return to TOC](#)

### Sample selection

The sample consisted of 34 Chinese skeletal Class III patients (20 women, 14 men) with a mean age 22.1 years (standard deviation 6.2). This sample was selected from the cohort of patients who were treated during the period 1997 to 2000 and was included in the study based on the following inclusion criteria:

1. All patients had combined Le Fort I and bilateral sagittal split osteotomies and surgical stabilization with internal rigid fixation using titanium mini bone plates and monocortical screws.
2. No additional surgical procedures were performed. Patients with cleft lip and palate and other congenital craniofacial anomalies were excluded.
3. All patients had undergone presurgical orthodontics, and lateral cephalograms were taken after the completion of presurgical and postsurgical orthodontics.

The presurgical cephalograms were taken within two months of the surgery, and the postsurgical cephalograms were obtained at least six months (range, 6.2 to 2.2 months) after the surgery. All radiographs were taken with teeth together in centric occlusion and lips in repose.

The presurgical and postsurgical cephalograms were digitized using the CASSOS 2001 software (Hong Kong) program by a single examiner (Dr Chew). The cephalograms were analyzed using a modified soft tissue analysis of Legan and Burstone<sup>10</sup> and Lew et al<sup>8</sup> (see [Figure 1](#) ) .

The horizontal reference line was constructed by raising a line 7 degrees from sella-nasion, and a perpendicular to this line at nasion was used as the vertical reference line. The hard and soft tissue landmarks were measured in millimeters to both the horizontal and vertical reference lines in both the presurgical and postsurgical cephalograms, and any differences in the distance were recorded as the surgical change.




### Method error and statistical analysis

Descriptive statistics were generated for the soft tissue measurements for both the presurgical and postsurgical cephalograms using the SPSS statistical software. The paired-sample *t*-test was used to assess soft and hard tissue changes. Pearson correlation analysis and linear regression procedures were used to assess the degree of correlation between soft to hard tissue changes and to generate soft tissue to hard tissue movement ratios.


The reproducibility of the measurements was determined by selecting 10 cephalometric radiographs at random and by repeating the on-screen digitization by the same examiner one month after the initial digitization. No significant errors were found when the repeat measurements were evaluated with paired *t*-tests.

## RESULTS [Return to TOC](#)


### Surgical outcome

[Tables 1](#)  and [2](#)  summarize the means and standard deviations of the hard and soft tissue changes. Significant angular, horizontal, and vertical changes were found in all parameters except for the labiomental fold and vertical changes of ANS, A, and Li. Greater changes were seen in the horizontal direction with all parameters showing changes at the  $P < .001$  significance level ([Table 1](#) ) .

### Correlations between hard and soft tissue movements

Strong and moderate correlation occurred between corresponding mandibular soft and hard tissue movements in the horizontal ( $r > .9$ ) and vertical directions ( $.82 > r > .63$ ) respectively ([Table 3](#) ). Moderate to weak correlation occurred in corresponding maxillary soft and hard tissue movements in both horizontal ( $.78 > r > .56$ ) and vertical ( $r < .6$ ) directions. Correlations improved generally from pronasale to soft tissue pogonion in both horizontal and vertical directions.

### Ratio of soft tissue to hard tissue movement

The soft-to-hard tissue movement ratios ranged from 0.78 to 1.08 for mandibular variables and from 0.33 to 0.73 for maxillary variables ([Table 3](#) ). The ratios of maxillary soft-to-hard tissue movement were generally lower than that of the mandibular movement in both horizontal and vertical directions.

## DISCUSSION [Return to TOC](#)

### Surgical outcome

The subjects included in this study presented with moderate to severe skeletal Class III discrepancies as indicated by the low presurgical mean ANB and overjet values of  $-4.9^\circ$  and  $-7.5$  mm, respectively. Frequently, a bimaxillary surgical approach is necessary in patients with severe skeletal discrepancies to achieve facial profile harmony and occlusal objectives. Surgical limitations and higher relapse risks may also determine the need for a bimaxillary approach in these cases. In this study, the postsurgical values showed normalization of both the ANB and overjet as a result of the two-jaw surgery.

In a similar study by Lin and Kerr<sup>6</sup> on Caucasian Class III patients treated by bimaxillary surgery, the mean ANB value was  $-3.65^\circ$ . The relatively higher presurgical mean ANB value of the current sample is an indication of the greater severity of dentofacial deformities among patients of Chinese ethnic origin. This was supported by the study by Ngan et al<sup>11</sup> that compared the cephalometric parameters of Chinese and Caucasian surgical Class III patients.

Soft tissue profile changes were significantly altered because of the surgery. All subjects presented presurgically with a concave profile and a protrusive lower lip. The bimaxillary surgery improved the facial convexity, nasolabial angle, and upper- and lower-lip protrusion to approximate the esthetic Chinese norms established by an earlier study by Lew et al.<sup>12</sup>

### Soft tissue response

Besides the study by Lin and Kerr,<sup>6</sup> there is a lack of studies on soft tissue changes after bimaxillary surgery of Class III patients. Comparing the results of this study with that of Lin and Kerr,<sup>6</sup> most of the ratios of soft tissue to hard tissue movement were similar except for the vertical ratios of pronasale to anterior nasal spine and subnasale to point A. This comparison, however, must be interpreted with caution because the sample in the latter study is of Caucasian origin and the sample size was limited to 17 patients.

The study by Enacar et al<sup>2</sup> suggested that the soft tissue responses to two-jaw surgery were similar to those seen in mandibular setback surgery alone, with the exception of the changes in nasal tip projection and the upper-lip area. Comparing the present findings with studies on mandibular setback only, the effects of bimaxillary surgery on the mandibular soft tissue profile in the current patients were, on the whole, in agreement with the findings of these studies.

In this study, the ratio of lower lip (Li) to mandibular incisal tip (L1E) change in the horizontal direction was 0.84:1, and this is similar to the studies by Lines and Steinhauser<sup>5</sup> (0.75:1), Ingervall et al<sup>13</sup> (0.88:1), and Suckiel and Kohn<sup>14</sup> (0.83:1). A 1.01:1 ratio of mentolabial sulcus (Si) to point B horizontal movement is also similar to the results reported by Fanibunda<sup>15</sup> (1.07:1), Ingervall et al<sup>13</sup> (1.06:1), Gjørup and Athanasiou<sup>16</sup> (1.03:1), and Robinson et al<sup>17</sup> (1:1) but somewhat higher than that described by Lew et al<sup>8</sup> (0.89:1) and Hu et al<sup>9</sup> (0.90:1 for men and 0.92 for women). The 0.85:1 ratio of soft tissue pogonion (Pg) to hard tissue pogonion (Pg) horizontal change in this study was somewhat lower than the results reported by Lines and Steinhauser<sup>5</sup> (1:1), Fanibunda<sup>15</sup> (0.94:1), Ingervall et al<sup>13</sup> (1.07:1), Lew et al<sup>8</sup> (0.95:1), and Hu et al<sup>9</sup> (0.94:1 for men and 1.06:1 for women).

Lew et al<sup>8</sup> in 1990, evaluated changes in the soft tissue profile after intraoral ramus osteotomy in 25 Chinese adults with mandibular prognathism and concluded that there is

need for different soft tissue to hard tissue movement ratios for different racial types. Comparing the results of this study with other similar studies on Caucasian samples, the majority of the ratios of soft tissue to hard tissue movement were similar, and in cases where there are differences, the discrepancy is small. Such direct comparison, however, must be treated with caution because of differences in sample size, types of initial dysgnathia, and the types of surgical procedures performed.

The results of this study supported the findings of other studies in that the ratio of maxillary soft tissue movement is lower than that of the mandibular soft tissue in both the horizontal and vertical directions.<sup>1,2,6</sup> The correlation of maxillary soft to hard tissue movement was also weaker compared with the mandibular counterparts, and this is similar to previous reports on maxillary advancement surgery using Caucasian samples.<sup>6,18,19</sup> This may be explained in part by the variability in the amount of anterior nasal spine resection and the surgical closure of the soft tissue incision in maxillary surgery.

Vertically, the maxillary and mandibular soft tissue responses after surgery showed a poor or weak correlation to hard tissue. This made accurate prediction of soft tissue changes in this dimension difficult. In a study evaluating soft tissue prediction accuracy of computer prediction software in a sample of skeletal Class III patients treated by bimaxillary surgery, vertical changes were indeed less accurately predicted compared with horizontal changes.<sup>20</sup>

Although there is general agreement on the anticipated average impact of surgery, more needs to be known about the influence of presurgical, perioperative, and postoperative factors on soft tissue response. With the increasing use of computerized prediction software as a treatment-planning tool in orthognathic surgery, similar studies are needed to contribute to the database for such planning predictions.

## CONCLUSIONS [Return to TOC](#)

- Bimaxillary surgery was effective in producing an orthognathic profile that approximated the Chinese esthetic norms.
- Stronger correlations between corresponding soft and hard tissue movements occurred in the mandible compared with the maxilla. A stronger correlation was also found in the horizontal direction compared with the vertical direction.
- The ratios of soft to hard tissue movements derived from this study would contribute to the database for planning prediction.

## REFERENCES [Return to TOC](#)

1. Jensen AC, Sinclair PM, Wolford LM. Soft tissue changes associated with double jaw surgery. *Am J Orthod Dentofacial Orthop.* 1992; 101:266–225. [[PubMed Citation](#)]
2. Enacar A, Taner T, Toroglu S. Analysis of soft tissue profile changes associated with mandibular setback and double-jaw surgeries. *Int J Adult Orthod Orthognath Surg.* 1999; 14:27–35. [[PubMed Citation](#)]
3. Hershey HG, Smith LH. Soft tissue profile change associated with surgical correction of the prognathic mandible. *Am J Orthod.* 1974; 83:382–390.
4. Kerr WJS, Ten Have TR. Changes in soft tissue profile during the treatment of Class III malocclusion. *Br J Orthod.* 1987; 14:243–249. [[PubMed Citation](#)]
5. Lines PA, Steinhauser WW. Soft tissue changes in relationship to movement of hard structures in orthognathic surgery: a preliminary report. *J Oral Surg.* 1974; 32:891–896.
6. Lin SS, Kerr WJS. Soft and hard tissue changes in Class III patients treated by bimaxillary surgery. *Eur J Orthod.* 1998; 20:25–33. [[PubMed Citation](#)]
7. Lew KK, Foong WC, Loh E. Malocclusion prevalence in an ethnic Chinese population. *Aust Dent J.* 1993; 38:442–449. [[PubMed Citation](#)]
8. Lew KKK, Loh FC, Yeo JF, Loh SA. Evaluation of soft tissue profile following intraoral ramus osteotomy in Chinese adults with mandibular prognathism. *Int J Adult Orthod Orthognath Surg.* 1990; 5:189–197. [[PubMed Citation](#)]
9. Hu J, Wang D, Luo S, Chen Y. Differences in soft tissue profile changes following mandibular setback in Chinese men and women. *J Oral Maxillofac Surg.* 1999; 57:1182–1186. [[PubMed Citation](#)]
10. Legan HL, Burstone CJ. Soft tissue cephalometric analysis for orthognathic surgery. *J Oral Surg.* 1980; 38:744–751. [[PubMed Citation](#)]
11. Ngan P, Hägg U, Yiu C, Mervin D, Wei SH. Cephalometric comparisons of Chinese and Caucasian surgical Class III patients. *Int J Adult Orthod Orthognath Surg.* 1997; 12:177–188. [[PubMed Citation](#)]
12. Lew KKK, Ho KK, Keng SB, Ho KH. Soft-tissue cephalometric norms in Chinese adults with esthetic facial profiles. *J Oral Maxillofac Surg.* 1992; 50:1184–1189. [[PubMed Citation](#)]
13. Ingervall B, Thuer U, Vuillemin T. Stability and effect on the soft tissue profile of mandibular setback with sagittal split osteotomy and rigid internal fixation. *Int J Adult Orthod Orthognath Surg.* 1995; 10:15–25. [[PubMed Citation](#)]
14. Suckiel JM, Kohn MW. Soft tissue changes related to the surgical management of mandibular prognathism. *Am J Orthod.* 1978; 73:676–680. [[PubMed Citation](#)]
15. Fanibunda KB. Changes in the facial profile following correction for mandibular prognathism. *Br J Oral Maxillofac Surg.* 1989; 27:277–286. [[PubMed Citation](#)]
16. Gjørup H, Athanasiou AE. Soft tissue and dentoskeletal profile changes associated with mandibular setback osteotomy. *Am J Orthod Dentofacial Orthop.* 1991; 100:312–323. [[PubMed Citation](#)]
17. Robinson WW, Spiedel TM, Isaacson RJ, Worms TW. Soft tissue profile change produced by reduction of mandibular prognathism. *Angle Orthod.* 1971; 41:227–235.
18. Mansour S, Burstone C, Legan H. An evaluation of soft tissue changes resulting from Le Fort I maxillary surgery. *Am J Orthod.* 1983; 84:37–47. [[PubMed Citation](#)]
19. Rosen HM. Lip-nasal aesthetics following LeFort I osteotomy. *Plast Reconstr Surg.* 1988; 81:171–179. [[PubMed Citation](#)]
20. Koh CH, Chew MT. Predictability of soft tissue profile changes following bimaxillary surgery in skeletal III Chinese patients. *J Oral Maxillofac Surg.* In press.

**TABLE 1.** Horizontal and Vertical Changes (mm) of Hard and Soft Tissue Landmarks (T2-T1)

Landmark	Horizontal		Vertical	
	Mean	SD	Mean	SD
<b>Hard tissue</b>				
ANS	3.3***	1.9	-0.4	1.4
A	3.3***	1.9	-0.4	1.4
U1E	4.6***	2.5	-0.8*	1.8
L1E	-6.1***	3.3	-2.3***	2.8
B	-5.4***	3.1	-2.0***	2.9
Pg'	-4.8***	3.9	-1.8***	2.5
<b>Soft tissue</b>				
Pn	1.0***	1.2	-0.9***	1.3
Sn	1.9***	1.5	-0.6*	1.4
Ls	1.9***	2.3	1.2**	2.1
Li	-5.5***	3.1	-1.1	3.9
Si	-5.3***	3.3	-1.9**	3.5
Pg'	-4.5***	3.4	-1.7**	3.2

\*  $P < .05$ , \*\*  $P < .01$ , \*\*\*  $P < .001$ .

**TABLE 2.** Surgical Outcome Assessed by Hard and Soft Tissue Measurements<sup>a</sup>

Variables	T1		T2		T2-T1		P
	Mean	SD	Mean	SD	Mean	SD	
SNA (°)	81.2	4.9	84.2	5.8	3.0	1.8	***
SNB (°)	86.0	5.9	83.1	5.8	-2.9	1.7	***
ANB (°)	-4.9	2.8	1.0	2.6	5.9	2.0	***
OJ (mm)	-7.5	3.2	3.2	1.1	10.7	3.2	***
OB (mm)	0.6	2.7	2.0	1.0	1.4	2.8	**
Facial convexity (°)	-4.1	5.1	3.4	4.9	7.5	3.3	***
Nasolabial angle (°)	87.8	12.2	92.7	11.2	4.9	7.9	**
Labiomental fold (mm)	5.1	1.3	5.3	1.2	0.2	1.2	NS
Upper-lip protrusion (mm)	4.3	2.1	5.8	1.8	1.4	1.3	***
Lower-lip protrusion (mm)	7.8	2.4	4.2	2.2	-3.6	1.9	***
Upper-lip length (mm)	22.3	2.5	23.7	2.0	1.5	1.5	***

<sup>a</sup> NS, not significant.

\*\*  $P < .01$ , \*\*\*  $P < .001$ .

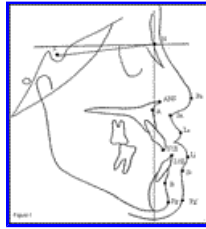**TABLE 3.** Correlations Between Corresponding Soft-to-Hard Tissue Movements and Soft-to-Hard Tissue Movement Ratios (S:H) in Both Horizontal and Vertical Planes<sup>a</sup>

Soft Tissue Variable (S)	Hard Tissue Variable (H)	<i>r</i>	<i>R</i> <sup>2</sup> (adj)	S:H
Horizontal				
Pn	ANS	0.56**	0.29	0.35
Sn	A	0.76***	0.57	0.60
Ls	U1E	0.78***	0.60	0.73
Li	L1E	0.90***	0.80	0.84
Si	B	0.93***	0.87	1.01
Pg'	Pg	0.98***	0.95	0.85
Vertical				
Pn	ANS	0.36*	0.11	0.33
Sn	A	0.59***	0.32	0.57
Ls	U1E	0.58***	0.31	0.66
Li	L1E	0.63***	0.38	0.88
Si	B	0.63***	0.38	0.78
Pg'	Pg	0.82***	0.66	1.08

<sup>a</sup> *r*, Pearson correlation coefficient; *R*<sup>2</sup> (adj), adjusted coefficient of determination.

\* *P* < .05, \*\* *P* < .01, \*\*\* *P* < .001.

FIGURES [Return to TOC](#)



[Click on thumbnail for full-sized image.](#)

**FIGURE 1.** Cephalometric landmarks and reference planes: S indicates sella; N, nasion; ANS, anterior nasal spine; A, point A; U1E, maxillary incisor tip; L1E, mandibular incisor tip; B, point B; Pg, pogonion; Pn, pronasale; Sn, subnasale; Ls, labrale superius; Li, labrale inferius; Si, mentolabial sulcus; and Pg', soft tissue pogonion

<sup>a</sup>Consultant, Department of Orthodontics, National Dental Centre, Singapore

Corresponding author: Ming Tak Chew, BDS, MDS, M Orth RCSEd, FAMS, Department of Orthodontics, National Dental Centre, 5, Second Hospital Avenue, Singapore 168938 (E-mail: [mingtak@pacific.net.sg](mailto:mingtak@pacific.net.sg))