

[\[Print Version\]](#)

[\[PubMed Citation\]](#) [\[Related Articles in PubMed\]](#)

TABLE OF CONTENTS

[\[INTRODUCTION\]](#) [\[MATERIALS AND...\]](#) [\[RESULTS\]](#) [\[DISCUSSION\]](#) [\[CONCLUSIONS\]](#) [\[REFERENCES\]](#) [\[FIGURES\]](#)

The Angle Orthodontist: Vol. 75, No. 6, pp. 993–995.

Expression of Notch1 and Math1 in Mandibular Condyle Cartilage in Neonatal Mice

Takako Shimizu;^a Hidetsugu Tsujigiwa;^b Hitoshi Nagatsuka;^c Norimasa Okafuji;^d Saburo Kurihara;^e Noriyuki Nagai;^f Toshiyuki Kawakami^g

ABSTRACT

On the basis of the cellular morphological changes in the cartilaginous area, the mandibular condylar cartilage is histopathologically composed of four different cell layers—fibrous, proliferative, maturative, and hypertrophic. Reaction for Notch1 was present in the hypertrophic cells only. However, Math1 was locally distributed in the hypertrophic layer and partially in the proliferative layer. The expression patterns of Notch1 and Math1 were slightly different. These results suggest that the morphogenesis regulation factors of Notch1 and Math1 may play some role in mandibular condylar cartilage. Positive reactions to osteopontin, as a control, were detected in the cytoplasm of all layers, although they varied from published data.

KEY WORDS: Notch1, Math1, Osteopontin, Mandibular condylar cartilage, Immunohistochemistry.

Accepted: September 2004. Submitted: June 2004

INTRODUCTION [Return to TOC](#)

The mandibular condylar cartilage is recognized as secondary cartilage. It differs from the primary cartilage in morphological and biochemical organization.^{1,2} Recently, various studies have shown that mandibular condylar cartilage formation is related to morphogenesis regulation factors and their signaling, such as fibroblast growth factor receptor, platelet-derived growth factor receptor,^{3,4} and core binding factor $\alpha 1$.⁵ We considered that morphogenesis regulation factors play a major role in morphogenesis, during development of mandibular condylar cartilage. Both Notch1 and Math1 are important regulation factors of morphogenesis.^{6,7} However, there are no reports on mandibular condylar cartilage, although there are reports on the distribution of articular cartilage.




The purpose of this study was to investigate the distribution of Notch1 and Math1, with osteopontin as a control, in young mice using immunohistochemistry techniques.


MATERIALS AND METHODS [Return to TOC](#)

The materials examined were mandibular condylar cartilages which were removed from ddY mice on the 13th neonatal day under ether anesthesia. The material was immediately fixed in 4% paraformaldehyde/ 0.05 M phosphate-buffered solution and decalcified in 10% ethylenediaminetetraacetic acid. The materials were then dehydrated by passage through a series of ethanols and embedded in paraffin. Samples were cut at four- μ m serial sections. Serial sections were then collected onto silane-coated slides and examined by histopathological (hematoxylin and eosin [HE]) and immunohistochemical techniques.

Immunohistochemical examination was carried out using a Dako EnVision™ Kit-K4006 (Dako Cytomation, Copenhagen, Denmark) and three monoclonal antibodies: anti-human Notch1 (Notch intracellular domain, NICD: 1/20), anti-Math1 (Math1: 1/100), and anti-osteopontin (OPN: 1/50). Samples were then counterstained with hematoxylin. OPN was used as a control. The NICD monoclonal antibody (bTAN 20) was developed by Artavanis-Tsakonas, Math1 monoclonal antibody (Math1) was developed by Johnson, and the OPN monoclonal antibody (MPIIB10) was developed by Solush and Franzen. They were obtained from the Developmental Studies Hybridoma Bank maintained by The University of Iowa, Department of Biological Science, Iowa City, Ia, under contract NO1-HD-7-3236 from the National Institute of Child Health and Human Development. Diaminobenzidine was applied for the observation of immunohistochemical activity. We included immunohistochemical staining using phosphate buffered saline in place of the primary antibody as negative control. The Matsumoto Dental University Committee for Animal Experimentation approved the study.

RESULTS [Return to TOC](#)

On the basis of the cellular morphological changes, mandibular condylar cartilage is histopathologically composed of four different cell layers: fibrous, proliferative, maturative, and hypertrophic ([Figure 1](#) ). Immunohistochemistry showed that a reaction for NICD was present in the hypertrophic layer only. There was no detectable immunoreaction for NICD in the upper three layers ([Figure 2](#) ). However, Math1 was distributed in the hypertrophic layer and partially in the proliferative layer ([Figure 3](#) ). Therefore, the expression pattern of NICD and Math1 showed slight differences.

[Figure 4](#)  shows the result of immunostaining for OPN, as a control. It was detected throughout almost all layers, and it was most distinct in the cytoplasm, though the positive reactions showed slight difference among the layers.

DISCUSSION [Return to TOC](#)

In general, OPN is known as a typical bone matrix protein. However, OPN is expressed by cells in a variety of tissues, including bone, dentin, cementum, kidney, brain, bone-marrow-derived metrial gland cells, vascular tissues, and in cytotrophoblasts of the chorionic villas in the uterus and decidua, ganglia of the inner ear, brain cells, and specialized epithelia found in mammary, salivary, and sweat glands, in bile and pancreatic ducts, and in distal renal tubules and in the gut, as well as in activated macrophages and lymphocytes.⁸ Moreover, in developing limbs, OPN expression is seen in hypertrophic cartilage.⁹ In view of this background, we used OPN as a control in this examination. Our results showed that OPN was expressed in almost all layers and not only in the hypertrophic layer in the mandibular condyle cartilage of neonatal mice. Verification of this result requires further study.

In recent articles, the Notch family has been shown to be a highly conserved family of cell surface signaling molecules that regulates many asymmetric developmental cell fate decisions.^{10,11} With reference to developing cartilage, NICD localized condensed mesenchymal cells in the expected cartilage region; in the later stage, the distribution of NICD was in the periphery of the developing cartilage, and immunoreactions decreased in proliferating chondrocytes. Delta-Notch signaling pathway has been reported to be important in regulating the progression of prehypertrophic chondrocytes to hypertrophic chondrocytes in examinations using chick.¹² Furthermore, Hayes et al⁷ described that Notch signaling is closely related to the formation of the articular cartilage and allows for cooriented ossification in the growth plate in mice.

Math1 is also a regulation factor of morphogenesis. Some reports were published on Math1 in the developing organs of mice,¹³ but there have been no reports about mandibular condylar cartilage. Therefore, we undertook these examinations. According to our results for mandibular condylar cartilage, NICD and Math1 were similarly localized to the hypertrophic compartment only. Despite the distribution of NICD during articular cartilage development, NICD was present in occasional prehypertrophic and in the majority of hypertrophic chondrocytes.⁶ However, there are no reports on the expression pattern of NICD and Math1 in mandibular condyle cartilage.

Our results show that expression patterns of morphogenesis regulation factors are slightly different in mandibular condylar cartilage, which is designated secondary cartilage. These results suggest that regulation factors play an essential role in mandibular condylar cartilage, the same as that for articular cartilage.⁷ The localization of Math1 was similar to that of NICD, which means Math1 also may play some essential role in mandibular condyle cartilage. The examination of the expression of these factors in developing mandibular condyle cartilage during fetal and postnatal stages in mice is now progressing. These results will be presented at a near future date.

CONCLUSIONS [Return to TOC](#)

In the present examination of mandibular cartilage of mice, immunohistochemically positive reactions to OPN were detected in almost all layers of the cytoplasm. The reaction for NICD was present, localized in the hypertrophic cells. Math1 was distributed mainly in the hypertrophic layer and partially in the proliferative layer. Therefore, the expression patterns of NICD and Math1 were slightly different. These results suggest that regulation factors of morphogenesis— Notch1 and Math1—may play some essential role in mandibular condyle cartilage.

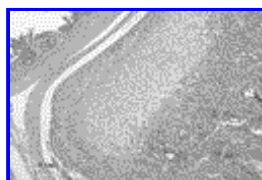
ACKNOWLEDGMENTS

This research was partially supported by the Ministry of Education, Science, Sports and Culture, Japan, Grant-in-Aid for Scientific Research (A), 2003-2006, 15209060.

REFERENCES [Return to TOC](#)


1. Rabie ABM, Hägg U. Factors regulating mandibular condylar growth. *Am J Orthod Dentofacial Orthop.* 2002; 122:401–409. [[PubMed Citation](#)]
2. Shibata S, Fukuda K, Suzuki S, Ogawa T, Yamashita Y. *In situ* hybridization and immunohistochemistry of bone sialoprotein and secreted phosphoprotein 1 (osteopontin) compared with limb bud cartilage. *J Anat.* 2002; 200:309–320. [[PubMed Citation](#)]
3. Hamada T, Suda N, Takayuki K. Immunohistochemical localization of fibroblast growth factor receptors in the rat mandibular condylar cartilage and tibial cartilage. *J Bone Miner Metab.* 1999; 17:274–282. [[PubMed Citation](#)]
4. Visnapuu V, Peltomäki T, Rönning O, Vahlberg T, Helenius H. Distribution of fibroblast growth factors (FGFR-1 and -3) and platelet-derived growth factor receptors (PDGFR) in rat mandibular condyle during growth. *Orthod Craniofacial Res.* 2002; 5:147–153.
5. Rabie ABM, Tang GH, Hägg U. Cbfa1 couples chondrocytes maturation and endochondral ossification in rat mandibular condylar cartilage. *Arch Oral Biol.* 2004; 49:109–118. [[PubMed Citation](#)]
6. Artavanis-Tsakonas S, Rand MD, Lake RJ. Notch signaling: cell fate control and signal integration in development. *Science.* 1999; 284:770–776.
7. Hayes AJ, Dowthwaite GP, Webster SV, Archer CW. The distribution of Notch receptors and their ligands during articular cartilage development. *J Anat.* 2003; 202:495–502. [[PubMed Citation](#)]
8. Sodek J, Ganss B, Mckee MD. Osteopontin. *Crit Rev Oral Biol Med.* 2000; 11:279–303. [[PubMed Citation](#)]
9. Nomura S, Wills AJ, Edwards DR, Heath JK, Hogan BL. Developmental expression of 2ar (osteopontin) and SPARC (osteonectin) RNA as revealed by *in situ* hybridization. *J Cell Biol.* 1988; 106:441–450. [[PubMed Citation](#)]
10. Watanabe N, Tezuka Y, Matsuno K. et al. Suppression of differentiation and proliferation of early chondrogenic cells by Notch. *J Bone Miner Metab.* 2003; 21:344–352. [[PubMed Citation](#)]
11. Sciaudone M, Gazzero E, Priest L, Anne MD, Canalis E. Notch 1 impairs osteoblastic cell differentiation. *Endocrinology.* 2003; 144:5631–5639. [[PubMed Citation](#)]
12. Crowe R, Zikherman J, Niswander L. Delta-1 negatively regulates the transition from prehypertrophic to hypertrophic chondrocytes during cartilage formation. *Development.* 1999; 126:987–998.
13. Zine A, de Ribaupierre F. Notch/Notch ligands and Math1 expression patterns in the organ of Corti of wild-type and Hes1 and Hes5 mutant mice. *Hear Res.* 2002; 170:22–31. [[PubMed Citation](#)]

FIGURES [Return to TOC](#)




[Click on thumbnail for full-sized image.](#)

FIGURE 1. Histopathological view of mandibular condylar head or cartilage (HE, 60x)




Click on thumbnail for full-sized image.

FIGURE 2. The distribution of NICD (NICD, 250x)



Click on thumbnail for full-sized image.

FIGURE 3. The distribution of Math1 (Math1, 250x)



Click on thumbnail for full-sized image.

FIGURE 4. The distribution of OPN (OPN, 250x)

^aPostgraduate Student, Matsumoto Dental University Graduate School of Oral Medicine, Shiojiri, Japan

^bAssistant Professor, Okayama University Graduate School of Medicine and Dentistry, Okayama, Japan

^cAssociate Professor, Okayama University Graduate School of Medicine and Dentistry, Okayama, Japan

^dAssociate Professor, Matsumoto Dental University School of Dentistry, Shiojiri, Japan

^eProfessor, Matsumoto Dental University School of Dentistry, Shiojiri, Japan

^fProfessor, Okayama University Graduate School of Medicine and Dentistry, Okayama, Japan

^gProfessor, Matsumoto Dental University Graduate School of Oral Medicine, Shiojiri, Japan

Corresponding author: Takako Shimizu, DDS, Hard Tissue Pathology Unit, Department of Hard Tissue Research, Matsumoto Dental University Graduate School of Oral Medicine, 1780 Hirooka-Gobara, Shiojiri 399-0781, Japan (E-mail: stg0317@po.mdu.ac.jp)