

[\[Print Version\]](#)

[\[PubMed Citation\]](#) [\[Related Articles in PubMed\]](#)

TABLE OF CONTENTS

[\[INTRODUCTION\]](#) [\[MATERIALS AND...\]](#) [\[RESULTS\]](#) [\[DISCUSSION\]](#) [\[CONCLUSIONS\]](#) [\[REFERENCES\]](#) [\[FIGURES\]](#)

The Angle Orthodontist: Vol. 74, No. 1, pp. 26-30.

Morphologic Characteristics of the Dentition and Palate in Cases of Skeletal Asymmetry

Kazuo Hayashi, DDS, PhD;^a Takeshi Muguruma, DDS;^b Meiri Hamaya, DDS, PhD;^c Itaru Mizoguchi, DDS, PhD^d

ABSTRACT

The purpose of this study was to clarify the three-dimensional morphological characteristics of the dentition and palate in skeletal asymmetry in patients with skeletal Class III malocclusion using a newly defined palatal reference plane in a dental cast. Twenty patients (5 males and 15 females) who had skeletal Class III malocclusion with facial asymmetry were selected. Pretreatment posteroanterior cephalometric radiographs and maxillary dental casts were used. The lateral deviation of Me was measured as the distance from a line perpendicular to Lo-Lo' that passed through CG. The angle between the Lo-Lo' plane and the J-J' plane was measured. Each maxillary dental cast was measured using a three-dimensional surface-scanning system, and the newly defined palatal reference plane was calculated. The right/left difference in the radius of curvature of the palate and right/left differences in the vertical and mesiodistal positions of the first molars were analyzed. Linear correlation and regression techniques were used. Our findings demonstrate that the lateral deviation of the mandible is closely related to the morphology of the alveolar process and to the vertical height of the dentition. In this study, the three-dimensional application of a new palatal reference plane is very useful in morphological research, and the results provide detailed information on the characteristics of facial asymmetry.

KEY WORDS: Facial asymmetry, Three-dimensional analysis, New palatal reference plane.

Accepted: March 2003. Submitted: February 2003

INTRODUCTION [Return to TOC](#)

It is important to understand the components of facial asymmetry for diagnosing and planning of orthodontic treatment or orthognathic surgery. Asymmetries can be classified according to the structures involved: ie, skeletal, dental, and functional.¹ Morphological studies using radiography continue to provide useful results, and posteroanterior cephalograms play an important role in the evaluation of skeletal asymmetry.²⁻⁵ Several characteristics of the dentition in skeletal asymmetry, which compensates for a skeletal discrepancy, have also been reported.⁶ However, many previous studies^{7,8} have used an occlusal plane as a reference for measurements in dental cast analysis.

Recently, quantification with greater accuracy of dental cast information has become possible because of advances in the application of three-dimensional measuring devices to dentistry.⁹⁻¹¹ However, the skeletal and dental information obtained from cephalometric and dental cast analyses has been isolated. To solve this problem, we had established the three-dimensional application of a newly defined palatal reference plane, as a reference structure, which provides orthodontic diagnosticians with accurate and abundant three-dimensional data

concerning malocclusion.¹² It is also very useful in morphological research on facial asymmetry.

The purpose of this study was to clarify the three-dimensional morphological characteristics of the dentition and palate in skeletal asymmetry in patients with skeletal Class III malocclusion using a newly defined palatal reference plane in a dental cast.

MATERIALS AND METHODS [Return to TOC](#)

Subjects

Twenty patients (5 males and 15 females, mean age 22 years; range 16 years 4 months to 28 years 9 months) from the orthodontic clinic of Health Sciences University of Hokkaido were selected. They were diagnosed as having skeletal Class III malocclusion with facial asymmetry and did not have congenital craniofacial anomalies or missing teeth. They had deviation in Me of more than 2 mm from a line perpendicular to Lo-Lo' that passed through CG in posteroanterior cephalometric radiography (range 2.2 to 15.7 mm). In addition, 70% of the subjects (2 males and 12 females) were diagnosed as having internal derangement of the temporomandibular joint (TMJ). These patients exhibited TMJ noise on opening their mouth, sometimes with pain (bilateral, 50%; unilateral-deviation side, 43%; unilateral-opposite side, 7%). All subjects were informed of the experimental protocols and signed an informed consent form that was previously approved by the Institutional Review Board. The subjects' rights were protected at all times.

Cephalometric analysis

Each pretreatment posteroanterior cephalometric radiograph was scanned using a flathead scanner (GT-9000, EPSON, Tokyo, Japan), and landmarks were identified directly on the digital image using image-analysis software (NIH Image; developed at the U.S. National Institutes of Health). The measurement error was checked on the digital images by the repeated identification of all landmarks. The x and y coordinates were calculated separately using the formula: $\text{error} = \sqrt{\sum d^2 / 2n}$.

The error was within 0.1 mm for the X coordinate and within 0.1 mm for the Y coordinate. Landmarks and planes in posteroanterior cephalometric radiography are shown in [Figure 1](#). The lateral deviation of Me was measured as the distance from a line perpendicular to Lo-Lo' that passed through CG. The angle between the Lo-Lo' plane and the J-J' plane was measured.

Dental cast analysis

A three-dimensional surface-scanning system using a slit laser beam (VMS-150RD, UNISN, Osaka, Japan) was used to measure the dental casts. We had reported the reliability of this measuring device,¹³ and in this study we have provide a summary in the "Discussion." The system consisted of a slit laser projector, two charge-coupled device cameras, an autorotating mounting unit, and a personal computer with postprocessing software. The resolution in the X-direction was 0.01 mm, and the Z-direction could be measured to within ± 0.05 mm. The three-dimensional shape data-analysis system consisted of a graphical workstation (Zx1, Intergraph, Huntsville, AL) and data processing and analyzing software (I-DEAS, SDRC, Milford, OH).

Each maxillary dental cast was measured by the three-dimensional surface-scanning system with a measuring pitch of 0.25 mm, and the palatal reference plane was calculated.¹² The three-dimensional shape data from the dental cast were segmented on the basis of differences in mean curvature H (1/mm: the curvature is the reciprocal of the radius of curvature). The flatter region of the palatal surface was extracted after setting a threshold ($0 < H < 0.21$). The extracted region was composed of 2000–3000 points, and the flat plane was fitted by the least-squares method. Fitting was carried out automatically by searching for the minimum amount of mismatch between the extracted region and a flat plane. Therefore, it was possible to define the palatal reference plane.

First, the right/left difference in the radius of curvature of the palate was analyzed. The palate shape data for the posterior teeth (15 mm anterior from the distal surface of the first molars) were divided into right and left sides by the median palatal raphe, and the data were subdivided into 10 cross-sectional lines. Each angle between a midline determined by the median palatal raphe to the subdivided lines was 90°. The radii of curvature were approximated using the least-squares method. Therefore, the mean values of radii of curvature for lines 1 to 10 ([Figure 2](#)) were calculated. Next, the right/left differences in the vertical and mesiodistal positions of the first molars were analyzed. The vertical position was measured as the linear distance from the reference plane to the tip of the mesiolingual cusp, and the mesiodistal position was measured as the linear distance from the YZ-plane to the tip of the mesiolingual cusp ([Figure 3](#)).

Statistical analysis

Linear correlation and regression tests were used to evaluate relationships between the lateral deviation of Me and the J-J' plane angle in posteroanterior cephalograms, the right/left difference in the radius of curvature of the palate, and right/left differences in the vertical and mesiodistal positions of the first molars in the three-dimensional analysis of dental casts.

RESULTS [Return to TOC](#)

[Figure 4a](#) shows a scatter diagram and regression lines for the lateral deviation of Me vs the J-J' plane angle in a posteroanterior cephalogram. [Figure 4b](#) through d also shows a scatter diagram and regression lines for the lateral deviation of Me in a posteroanterior cephalogram vs the right/left difference in the radius of curvature of the palate and the right/left differences in the vertical and the mesiodistal positions of the first molars in the three-dimensional analysis of dental casts. With the data points, best-fit straight lines were drawn and regression equations were determined, with correlation coefficients of $r = 0.359, 0.755, 0.671,$ and -0.165 . A significant correlation was found between the lateral deviation of Me and the right/left difference in the radius of curvature of the palate in the posterior teeth ($P < .001$) and the right/left difference in the position height of the first molars ($P < .01$). A similar trend was detected between the lateral deviation of Me and the J-J' plane. However, a correlation was not found between the lateral deviation of Me and the right/left difference in the mesiodistal positions of the first molars.

DISCUSSION [Return to TOC](#)

Reliability of the analysis method

We had reported the reliability of the three-dimensional measuring device used in this study.¹³ A calibrating plane plate was measured using the device, and the best-fit expression for the plane was calculated from the entire data, to within ± 3 SD, by the least-squares method. The reliability of the measurement was evaluated by calculating the maximum error between the calculated plane and the obtained data. The result was ± 0.05 mm. Therefore, the reliability of the three-dimensional measuring device is sufficient for dental cast analysis. We also had reported the reliability of the newly defined palatal reference plane used in this study.¹² The newly defined palatal reference plane in the three-dimensional dental cast analysis corresponds to the A-PNS plane in a lateral cephalogram and to the J-J' plane in a posteroanterior cephalogram, which have been shown to be sufficiently accurate as references for measurement.

Characteristics of skeletal asymmetry

Facial asymmetry is not rare.¹⁴ Shah and Joshi¹⁵ reported that even pleasing and apparently symmetrical faces exhibit skeletal asymmetry. Farkas and Cheung¹⁶ used anthropometry to measure normal facial asymmetry and noted that although asymmetries were not always obvious, they were common. Haraguchi et al³ reported that facial asymmetry was found in 70–85% of subjects with skeletal Class III deformity. They considered subjects to have asymmetry if they had a deviation of more than 2 mm from the facial midline associated with any of the landmarks. In this study, we selected subjects who had skeletal Class III deformity with a deviation in Me of more than 2.0 mm from a line perpendicular to Lo-Lo' that passed through CG.

Although there is no clear explanation of the etiologic force underlying facial asymmetry, trauma, infection, and TMJ disorder must be considered when encountering facial asymmetry^{1,2,17,18}; 70% of the subjects in this study had temporomandibular disorder (TMD). Many morphological characteristics of facial asymmetry have been reported,¹⁹ and asymmetry is apparently more remarkable in the lower one-third of the face than in the middle.¹⁴ In this study, a similar trend was detected between the lateral deviation of Me and the J-J' plane. In our analysis using only postero-anterior cephalometric radiographs, it was difficult to obtain detailed information on the palate form and the axis of buccal teeth. As a solution to this problem, computerized tomography (CT) scan is better for acquiring three-dimensional information.^{20–22} However, the level of radiation is too high for routine use.

As another option, advances in measuring devices and the use of computers have greatly improved three-dimensional dental cast analysis.^{9–13} In this study, a significant correlation was found between the lateral deviation of Me and the right/left difference in the radius of curvature of the palate in the posterior teeth ($P < .001$) and the right/left difference in the vertical position of the first molars ($P < .01$). These findings demonstrate that the compensation for lateral deviation of the mandible is closely related to the morphology of the alveolar process and dentition. This supports findings that the inclination of the occlusal plane is closely associated with facial asymmetry.^{6,19} A correlation was not found between the right/left difference in the mesiodistal position of the first molars. This result also indicates that vertical asymmetry in the maxillary dental arch significantly affects facial asymmetry. However, one of the most critical limitations of this study might be that we did not perform an evaluation on the basis of submentovertex radiography. Therefore, horizontal asymmetry of the maxillary dental arch based on cranial base structures was not evaluated.

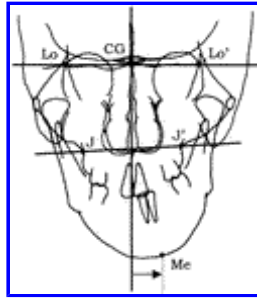
CONCLUSIONS [Return to TOC](#)

Our study shows that the three-dimensional application of a new palatal reference plane is useful in morphological research, and the results provide detailed information about characteristics of facial asymmetry.

REFERENCES [Return to TOC](#)

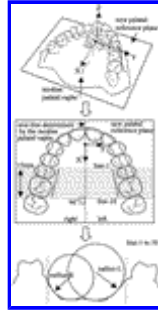
1. Bishara SE, Burkey PS, Kharouf JG. Dental and facial asymmetries: a review. *Angle Orthod.* 1994; 64:89–98. [[PubMed Citation](#)]

2. Pirttiniemi PM. Associations of mandibular and facial asymmetries: a review. *Am J Orthod Dentofacial Orthop.* 1994; 106:191–200. [[PubMed Citation](#)]
3. Haraguchi S, Takada K, Yasuda Y. Facial asymmetry in subjects with skeletal Class III deformity. *Angle Orthod.* 2002; 72:28–35. [[PubMed Citation](#)]
4. Janson GR, Metaxas A, Woodside DG, de Freitas MR, Pinzan A. Three-dimensional evaluation of skeletal and dental asymmetries in Class II subdivision malocclusions. *Am J Orthod Dentofacial Orthop.* 2001; 119:406–418. [[PubMed Citation](#)]
5. Severt TR, Proffit WR. Postsurgical stability following correction of severe facial asymmetry. *Int J Adult Orthod Orthognath Surg.* 1997; 12:251–261.
6. Pirttiniemi P, Kantomaa T, Lahtela P. Relationship between craniofacial and condyle path asymmetry in unilateral cross-bite patients. *Eur J Orthod.* 1990; 12:408–413. [[PubMed Citation](#)]
7. Maurice TJ, Kula K. Dental arch asymmetry in the mixed dentition. *Angle Orthod.* 1998; 68:37–44. [[PubMed Citation](#)]
8. de Araujo TM, Wilhelm RS, Almeida MA. Skeletal and dental arch asymmetry in individuals with normal dental occlusion. *Int J Adult Orthod Orthognath Surg.* 1994; 9:111–118. [[PubMed Citation](#)]
9. Motohashi N, Kuroda T. A 3D computer-aided design system applied to diagnosis and treatment planning in orthodontics and orthognathic surgery. *Eur J Orthod.* 1999; 21:263–274. [[PubMed Citation](#)]
10. Kusnoto B, Evans CA. Reliability of 3D surface laser scanner for orthodontic applications. *Am J Orthod Dentofacial Orthop.* 2002; 122:342–348. [[PubMed Citation](#)]
11. Kuroda T, Motohashi N, Tominaga R, Iwata K. Three-dimensional dental cast analyzing system using laser scanning. *Am J Orthod Dentofacial Orthop.* 1996; 110:365–369. [[PubMed Citation](#)]
12. Hayashi K, Uechi J, Mizoguchi I. Three-dimensional analysis of dental casts based on a newly defined palatal reference plane. *Angle Orthod.* 2003 In press.
13. Hayashi K, Araki Y, Uechi J, Ohno H, Mizoguchi I. A novel method for the three-dimensional (3-D) analysis of orthodontic tooth movement—calculation of rotation about and translation along the finite helical axis. *J Biomech.* 2002; 35:45–51. [[PubMed Citation](#)]
14. Severt TR, Proffit WR. The prevalence of facial asymmetry in the dentofacial deformities population at the University of North Carolina. *Int J Adult Orthod Orthognath Surg.* 1997; 12:171–176. [[PubMed Citation](#)]
15. Shah SM, Joshi MR. An assessment of asymmetry in the normal craniofacial complex. *Angle Orthod.* 1978; 48:141–148. [[PubMed Citation](#)]
16. Farkas LG, Chung G. Facial asymmetry in healthy North American Caucasians. *Angle Orthod.* 1981; 51:70–77. [[PubMed Citation](#)]
17. Trpkova B, Major P, Nebbe B, Prasad N. Craniofacial asymmetry and temporomandibular joint internal derangement in female adolescents: a posteroanterior cephalometric study. *Angle Orthod.* 2000; 70:81–88. [[PubMed Citation](#)]
18. Inui M, Fushima K, Sato S. Facial asymmetry in temporomandibular joint disorders. *J Oral Rehabil.* 1999; 26:402–406. [[PubMed Citation](#)]
19. Padwa BL, Kaiser MO, Kaban LB. Occlusal cant in the frontal plane as a reflection of asymmetry. *J Oral Maxillofac Surg.* 1997; 55:811–817. [[PubMed Citation](#)]
20. Troulis MJ, Evertt P, Seldin EB, Kikinis R, Kaban LB. Development of a three-dimensional treatment planning system based on computed tomographic data. *Int J Adult Orthod Orthognath Surg.* 2002; 31:349–357.
21. Maki K, Miller AJ, Okano T, Hatcher D, Yamaguchi T, Kobayashi H, Shibasaki Y. Cortical bone mineral density in asymmetrical mandibles: a three-dimensional quantitative computed tomography study. *Eur J Orthod.* 2001; 23:217–232. [[PubMed Citation](#)]
22. Masumoto T, Hayashi I, Kawamura A, Tanaka K, Kasai K. Relationship among facial type, buccolingual molar inclination, and cortical bone thickness of the mandible. *Eur J Orthod.* 2001; 23:15–23. [[PubMed Citation](#)]



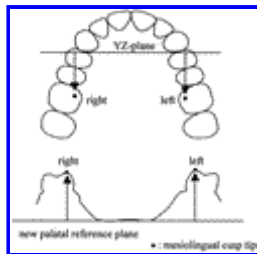
[Click on thumbnail for full-sized image.](#)

FIGURE 1. Landmarks and planes in posteroanterior cephalometric radiography. CG indicates upper point of the crista galli process; Lo, Lo', intersection of the lateral wall of the orbit and the greater wing of the sphenoid; J, J', intersection between the jugal crests and maxillary tuberosities; Me, median point of the lower border of the mandibular symphysis




[Click on thumbnail for full-sized image.](#)

FIGURE 2. Right/left difference in the radius of curvature of the palate. The palate shape data for the posterior teeth (15 mm anterior from the distal surface of the first molars) were divided into right and left sides by the median palatal raphe, and the data were subdivided into 10 cross-sectional lines. Each angle between a midline determined by the median palatal raphe to the subdivided lines was 90°. The radii of curvature were approximated using the least-squares method. The results obtained the mean values of radii of curvature for lines 1 to 10



[Click on thumbnail for full-sized image.](#)

FIGURE 3. Right/left differences in the vertical and mesiodistal positions of the first molars were analyzed. The vertical position was measured as the linear distance from the reference plane to the tip of the mesiolingual cusp, and the mesiodistal position was measured as the linear distance from the YZ plane to the tip of the mesiolingual cusp



[Click on thumbnail for full-sized image.](#)

FIGURE 4. A scatter diagram and regression lines for the lateral deviation of Me vs the J-J' plane angle in a posteroanterior cephalogram (a), right/left difference in the radius of curvature of the palate (b), right/left differences in the vertical (c) and mesiodistal (d) positions of the first molars in a three-dimensional analysis of dental casts

^bResearch Assistant, Department of Orthodontics, School of Dentistry, Health Sciences University of Hokkaido, Hokkaido, Japan

^cResearch Assistant, Department of Orthodontics, School of Dentistry, Health Sciences University of Hokkaido, Hokkaido, Japan

^dProfessor and Chairman, Department of Orthodontics, School of Dentistry, Health Sciences University of Hokkaido, Hokkaido, Japan

^aCorresponding author: K. Hayashi, DDS, PhD, Department of Orthodontics, School of Dentistry, Health Sciences University of Hokkaido, Kanazawa 1757, Ishikari-Tobetsu, Hokkaido 061-0293, Japan (E-mail: kazu@hoku-iryo-u.ac.jp)