

[\[Print Version\]](#)

[\[PubMed Citation\]](#) [\[Related Articles in PubMed\]](#)

TABLE OF CONTENTS

[\[INTRODUCTION\]](#) [\[CASE REPORT\]](#) [\[RESULTS AND...\]](#) [\[CONCLUSIONS\]](#) [\[REFERENCES\]](#) [\[TABLES\]](#) [\[FIGURES\]](#)

The Angle Orthodontist: Vol. 74, No. 2, pp. 280–285.

Severe Class II Anterior Deep Bite Malocclusion Treated with a C-Lingual Retractor

Seong-Hun Kim, DMD, MS;^a Young-Guk Park, DMD, MS, PhD;^b Kyurhim Chung, DMD, MS, PhD^c

ABSTRACT

A C-lingual retractor was placed on the lingual aspects of the six maxillary anterior teeth in a 24-year-old female patient with a Class II anterior deep-bite malocclusion. The treatment plan consisted of extracting both the upper first premolars and intruding and retracting the upper six anterior teeth. Transpalatal arches were soldered to the upper first and second molar bands and used as an intra-arch anchor unit for upper space closure. Double NiTi closed coil springs were used palatally between the hooks of the C-lingual retractor and the transpalatal arches. A high-pull headgear was used for anchorage reinforcement during en masse retraction. It took 14 months to treat this patient. The correct overbite and overjet was obtained by simultaneously intruding and retracting the upper six anterior teeth into their proper positions by C-lingual retractor mechanics, which contributed to an improvement in facial balance. The treatment result was stable 6 months after debonding. The application of this new appliance, consideration in case selection, and sequence of treatment are presented.

KEY WORDS: Lever-arm appliance, High-pull headgear, Deep bite, En masse retraction, Intrusion.

Accepted: May 2003. Submitted: February 2003

INTRODUCTION [Return to TOC](#)


Numerous treatment protocols have been advocated for the management of Class II malocclusions because they do not constitute a single diagnostic entity.¹ These treatment modalities include a variety of fixed appliances, extraction procedures, extraoral traction and arch expansion appliances, functional jaw orthopedic appliances, and surgery.²⁻⁴ Likewise, deep overbite malocclusions, commonly seen in children as well as adults, needs careful diagnosis, various treatment plan options, and appliance designs in accordance with the factors contributing to excessive overbite.⁵⁻⁷

Moyers and Riolo⁸ reported that deep bite, as a clinical problem, is not defined in terms of millimeters present today, but in the light of future changes in esthetics and function. In addition, deep bite is usually more difficult to correct and retain in a Class II than in a Class I malocclusion because of the dominance of skeletal morphology. Nanda⁵ classified the correction of deep overbite by four types of tooth movement, ie, extrusion of posterior teeth, flaring of anterior teeth in the case of lingually tipped incisors, intrusion of incisors, and the surgical method. Among the other types of tooth movement, Dermaut and De Pauw⁹ stressed the importance of intrusion of incisors in adults for whom bite opening is a goal. Increasing the lower anterior facial height by extrusion of molars may not always result in a stable

situation in adult patients.

Patients exhibiting a large interlabial gap, a large incision-stomion distance, a short upper lip, a high gingival smile line, and a long lower facial height especially need intrusion of incisors.⁵ Intrusion should be the treatment of choice for adult patients who have had significant bone loss around the incisors.¹⁰ A clinical study by Burzin and Nanda¹¹ showed that the relapse of intruded teeth (intruded an average of 2.3 mm) is almost insignificant (an average of 0.15 mm) up to 2 years after treatment.


The C-lingual retractor for intrusion and retraction



The C-lingual retractor mechanics developed by Chung et al.¹² and Kim et al.¹³ is an alternative method for obtaining a direct controlled retraction force on the maxillary anterior teeth.^{14–18} A C-lingual retractor for intrusion and retraction has three components: (1) mesh part soldered lever arm, (2) wire with bent hook, and (3) auxiliary hook soldered for intrusion force (Figure 1 ). The position of the bent hook follows the line of action of the force and passes through the center of resistance. In the study by Vanden Bulcke et al.,¹⁹ the center of resistance for a rigid anterior segment that included the six anterior teeth was situated on a line projected perpendicular to the occlusal plane that was distal to the first premolar. The retraction forces are applied directly to the C-lingual retractor according to the segmental arch wire technique of Burston.²⁰



In this case report, we document a new approach to treatment of a Class II anterior deep bite malocclusion using a C-lingual retractor with controlled intrusion and retraction mechanics. The clinical and radiographic changes are described.

CASE REPORT [Return to TOC](#)

Pretreatment evaluation




A 24-year-old-patient presented with a complaint of lip protrusion and was eager to have an attractive smile. The extraoral examination revealed the facial characteristics typical of a Class II anterior deep bite patient, with short anterior facial height, deep labiomental sulcus, prominent upper lip, an everted lower lip, and increased interlabial gap (Figure 2 ). The incision-stomion distance, which represents the extent of maxillary central incisor crown display when the lips are in a relaxed position, was six mm (3–4 mm is esthetically pleasing).

The intraoral examination revealed a severe Class II malocclusion with an anterior deep overbite and a severe overjet. There was no occlusion-centric relationship discrepancy on closure. Skeletal and dental characteristics showed a flat occlusal plane, severely protruded upper incisors, and slightly procumbent lower incisors. Temporomandibular joint function was normal. The maxillary and mandibular midline coincided with the facial midline (Figures 2  and 3 .


Radiographic examination revealed that the patient had a convex profile (an ANB angle of 5°), a slightly retrognathic mandible (SNB, 77.5; SN-Pg, 79°), a low mandibular plane (FMA, 17°; SN-OP angle, 16°), and protrusive incisors (interincisal angle, 103°; maxillary incisor to NA angle, 33°; maxillary incisor to NA distance, nine mm; mandibular incisor to NB angle, 39.5°; mandibular incisor to NB distance, eight mm) (Figure 11A , Table 1 ). The pretreatment panoramic radiograph illustrates excellent periodontal support and the presence of the impacted third molars.

Treatment plan

The patient requested conventional orthodontic treatment using a more esthetic method. The treatment objectives based on the results of cephalometric and study model analyses were to establish a Class I canine relationship, create ideal overjet and overbite and correct the incisor lingual inclination, improve occlusal interdigitation, and improve facial balance.

We made two tentative diagnostic setup models using our own method,²¹ which showed the treatment result of C-lingual retraction (Figure 4A ) and the final occlusion (Figure 4B ). This allowed us to measure the arch-width discrepancies present and to determine the extent of intrusion and retraction needed. The extent needed were three mm of intrusion and five mm of retraction, as determined from the diagnostic set. The treatment strategy was, therefore, to extract the upper first premolars, correct the Class II canine relationship, place a C-lingual retractor for intrusion and retraction, and use a high-pull headgear for anchorage reinforcement. A diagram of the intrusion and retraction mechanics is shown in Figure 5 .

Treatment progress

Treatment was initiated with the leveling and intrusion of the lower anterior dentition (Figure 6A ). Because of the patient's dental and skeletal problems, the maxillary first premolars were removed to create space for the intrusion and retraction of the maxillary anterior teeth. The lower mandibular third molars also were removed. Preadjusted 0.022 × 0.028-inch brackets were placed on all teeth except the maxillary anterior segment, and this was followed by the placement of buccal segments of 0.018 × 0.025-inch stainless steel stabilizing arch wires. The permanent first and second molars were banded. transplanter arches (TPAs) were soldered to the lingual aspects of both the upper molar bands.

The C-lingual retractor was placed on the upper six anterior teeth ([Figures 6B](#) and [11B](#)) and used until space closure was complete. The point of force application of the C-lingual retractor was determined on cephalometric film by using a gutta-percha cone as a radiopaque guide. NiTi coils that delivered 300 g per side provided a retraction force for space closure. In addition, the intrusion force of the C-lingual retractor was 60 g per side. The patient was instructed to wear her high-pull headgear during the night to reinforce anchorage (350 g per side). After 5 months of active tooth movement (about one mm/mo), the extracted space was almost completely closed ([Figures 7](#), [8](#), and [11C](#)). At the cessation of C-lingual retractor therapy, routine orthodontic mechanics were initiated to complete treatment. However, the patient requested removal of the fixed appliance during the finishing stage because of her new job. After 8 months of leveling, the fixed appliances were all removed, and a tooth positioner was used for a month for finishing. Upper and lower Hawley retainers provided retention. The changes in maxillary dentition during the treatment period are shown in [Figure 12](#).

RESULTS AND DISCUSSION [Return to TOC](#)

After treatment, a Class I canine relationship and a full Class II molar relationship with coincident midlines, correct tooth position, and proper alignment were obtained. Ideal overjet, overbite, and facial balance also were achieved ([Figures 9](#), [10](#), and [11C](#)). The posttreatment facial photographs showed great improvement of facial esthetics because dentally protruded patients such as this patient tend to exhibit significant facial change. The incisors were no longer procumbent.

Cephalometric analysis showed slight downward and backward mandibular movement as well as intrusion and retraction of the maxillary anterior teeth. The FMA changed a little from 17° to 18° ([Figure 11D](#), [13](#), and [Table 1](#)). The backup with the high-pull headgear produced an intrusive force to the upper molars, which minimized any steepening of the mandibular plane. The occlusal plane leveled because of the combined intrusion of the mandibular anterior teeth and extrusion of the mandibular posterior teeth (SN to OP angle, 16° to 18°). The upper incisors were remarkably retracted (FH-U1 angle, 127° to 114.5°; maxillary incisor to NA distance, nine to three mm; maxillary incisor to NA angle, 33° to 20°). The lower incisors were set upright and retracted (IMPA, 113° to 107°; FMIA, 50° to 55°; mandibular incisor to NB distance, eight to six mm, and mandibular incisor to NB angle, 39.5° to 34°).

The lips were competent in repose (upper lip to E-plane, 0.5 to -2 mm; lower lip to E-plane, 0.5 to -1 mm). The interincisal angle was improved to normal range (105° to 121°). The ANB changed a little during treatment (SNA, 82.5° to 81°; SNB, 77.5° to 77°). Posterior facial–anterior facial height ratio did not change after treatment (88 mm/125 mm, 70.4%). The upper six anterior teeth were intruded and retracted successfully using C-lingual retraction. The treatment result was quite acceptable and almost the same as the simulated result, even though a slight extraction space remained ([Figure 12D.E](#), arrow: less than one mm in posttreatment). The patient was pleased with the final treatment result. Even though a slight upper extraction space remained, the treatment results were maintained 6 months after retention ([Figures 14](#) and [15](#)).

Use of the C-lingual retractor for intrusion and retraction follows Burstone's²² six principles in incisor or canine intrusion. Orthodontists can apply a single point force by using a C-lingual retractor. Double NiTi coil springs between the hooks of the retractor and TPAs deliver an optimal and constant force (300 g per side for retraction and 60 g per side for intrusion) as compared with that delivered by elastics or elastomeric chains. Biomechanically, the position of the hook in the lever-arm wire can change the point of force application with respect to the center of resistance of the teeth to be intruded and retracted.

In this case, we used high-pull headgear to reinforce the posterior anchorage unit during en masse retraction of upper six anterior teeth. A posteriorly and intrusively directed force from the headgear (350 g per side) acting anterior to the center of resistance of the molar segment produces a moment that minimizes any steepening of the occlusal plane.²³ After en masse retraction of upper six anterior teeth in this patient, however, the occlusal plane increased a little, and we assumed that the lower molars were extruded during initial leveling in spite of maintenance of upper molar position. A skeletal anchorage system can be used for anchorage reinforcement instead of an extraoral appliance to provide absolute anchorage for orthodontic tooth movements.^{24,25}

In this patient, brackets were first bonded on the lower dentition to produce a space for bonding the C-lingual retractor on the lingual side of upper incisors. We used overlay intrusion arch wires on the lower anterior teeth, but the lower incisors became more flared than intruded after initial leveling (Mn1 to NB angle: pretreatment, 39.5°; after C-lingual retraction, 40°). It was assumed that the overlay utility arch worsened the incisor's axial inclination in this patient with flared incisors. Many authors warn against the conventional mechanics that involve the use of continuous arch wire to correct the deep overbite malocclusion in patients with flared incisors.^{23,26,27} Leveling a mandibular curve of Spee by extrusion of the posterior teeth steepens the occlusal plane and causes backward rotation of the mandible, which is undesirable in many Class II patients. Therefore, we used tip-back mechanics on the lower dentition to correct the lower incisor axial inclination during the treatment period.

There are several advantages of C-lingual retractor mechanics.¹³ This technique requires no complicated wire bending and can produce controlled retraction of the maxillary incisors. Because no brackets are bonded to the anterior portion during the C-lingual retractor period, there is no need for rebracketing or making compensating bends in the arch wire after the retraction period, in contrast to the conventional segmental approach.

The segmented approach can treat the deep overbite precisely in cases where incisor intrusion is indicated and molar extrusion is to be avoided. The C-lingual retractor mechanics, an alternative method of segmental orthodontics, can be applied as an effective tool for closing the extracted space in the various vertical dimensions. It can broaden the range of tooth movement, especially in adult patients.

In this article, the timing, sequencing, and treatment effect of the C-lingual retractor were described. Further research and studies on C-lingual retractor mechanics are required to further facilitate easy fabrication methods, establish the selection of an accurate point of force application, combine it with other treatment mechanics, and determine the retention period required for long-term stability.

ACKNOWLEDGMENTS

We thank Dr Jeong-Hyun Ji, who has a private practice in Chungju, Mr Hye-woong Kim in the Department of Orthodontics at Kyunghee University Dental Hospital, and Miss Jung-Kyung Kim at TP Korea Orthodontics Lab for their expert technical assistance in the preparation of this article.

REFERENCES [Return to TOC](#)

1. McNamara JA, Peterson JE, Alexander RG. Three-dimensional diagnosis and management of Class II malocclusion in the mixed dentition. *Semin Orthod.* 1996; 2:114–137.
2. Klontz H. Tweed-Merrifield sequential directional force treatment. *Semin Orthod.* 1996; 2:254–267.
3. Spalding P. Treatment of Class II malocclusions. In: Bishara SE, ed. *Textbook of Orthodontics*. Philadelphia, Pa: W.B. Saunders Co; 2001:324–374.
4. Bell WH, Jacobs JD, Legan HL. Treatment of Class II deep bite by orthodontic and surgical means. *Am J Orthod.* 1984; 85:1–20. [[PubMed Citation](#)]
5. Nanda R. Correction of deep over bite in adults. *Dent Clin North Am.* 1997; 41:67–87. [[PubMed Citation](#)]
6. Sadowsky C, Selke T. Management of overbite by controlling incisor and molar movements. *Semin Orthod.* 2000; 6:43–49.
7. Vaden JL. Alternative nonsurgical strategies to treat complex orthodontic problems. *Semin Orthod.* 1996; 2:90–113.
8. Moyers RE, Riolo ML. Early treatment. In: Moyers RE, ed. *Handbook of Orthodontics*. 4th ed. Chicago, Ill: Year Book Medical Publishers Inc; 1988:422–426.
9. Dermaut LR, De Pauw G. Biomechanical aspects of Class II mechanics with special emphasis in deep bite correction as part of the treatment goal. In: Nanda R, ed. *Biomechanics in Clinical Orthodontics*. Philadelphia, Pa: W.B. Saunders Co; 1997:86–98.
10. Melsen B. Intrusion of incisors in adult patients with marginal bone loss. *Am J Orthod.* 1989; 96:232–241.
11. Burzin J, Nanda R. The stability of deep overbite correction. In: Nanda R, Burstone CJ, eds. *Retention and Stability in Orthodontics*. Philadelphia, Pa: W.B. Saunders Co; 1993:61–79.
12. Chung KR, Oh MY, Ko SJ. Corticotomy-assisted orthodontics. *J Clin Orthod.* 2001; 35:331–339. [[PubMed Citation](#)]
13. Kim SH, Park YG, Chung KR. Severe anterior open bite malocclusion with multiple odontoma treated by C-lingual retractor and horseshoe mechanics. *Angle Orthod.* 2003; 73:206–212. [[PubMed Citation](#)]
14. Kucher G, Weiland FJ, Bantleon HP. Modified lingual lever arm technique. *J Clin Orthod.* 1993; 27:18–22. [[PubMed Citation](#)]
15. Fontanelle A. Lingual orthodontics in adults. In: Melsen B, ed. *Current Controversies in Orthodontics*. Chicago, Ill: Quintessence Publishing Co; 1991:227–246.
16. Siatkowski RE. Lingual lever-arm technique for en masse translation in patients with generalized marginal bone loss. *J Clin Orthod.* 1999; 33:700–704. [[PubMed Citation](#)]
17. Lindauer SJ, Isaacson RJ. One-couple orthodontic appliance systems. *Semin Orthod.* 1995; 1:12–24.
18. Park YC, Choi KC, Lee JS, Kim TK. Lever-arm mechanics in lingual orthodontics. *J Clin Orthod.* 2000; 34:601–605. [[PubMed Citation](#)]

19. Vanden Bulcke MM, Dermaut LR, Sachdeva RCL, et al. The center of resistance of anterior teeth during intrusion using the laser reflection technique and holographic interferometry. *Am J Orthod.* 1986; 90:211–220.
20. Burston CJ. The segmented arch approach to space closure. *Am J Orthod.* 1982; 82:361–378. [[PubMed Citation](#)]
21. Kim SH, Park YG. Easy wax setup technique for orthodontic diagnosis. *J Clin Orthod.* 2000; 34:140–144.
22. Burstone CJ. Deep over bite correction by intrusion. *Am J Orthod.* 1977; 72:1–22. [[PubMed Citation](#)]
23. Burstone CJ. Biomechanics of deep overbite correction. *Semin Orthod.* 2001; 7:26–33.
24. Park HS, Bae SM, Kyung HM, Sung JH. Micro-implant anchorage for lingual treatment of a skeletal Class II malocclusion. *J Clin Orthod.* 2001; 35:643–647. [[PubMed Citation](#)]
25. Chung KR, Kim YS, Linton JL, Lee YJ. The miniplate with tube for skeletal anchorage. *J Clin Orthod.* 2002; 36:407–412. [[PubMed Citation](#)]
26. Nanda R. The differential diagnosis and treatment of excessive overbite. *Dent Clin North Am.* 1981; 25:69–84. [[PubMed Citation](#)]
27. Shroff B, Nanda R. Biomechanics of Class II correction. In: Nanda R, ed. *Biomechanics in Clinical Orthodontics*. Philadelphia, Pa: W.B. Saunders Co; 1997 : 143–155.

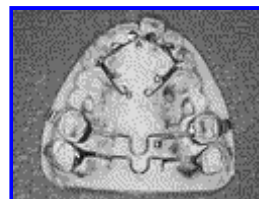TABLES [Return to TOC](#)

TABLE 1. Cephalometric Survey^a

	Average (Female)	Pretreatment	C-Retraction	Posttreatment	6 m-Retention
SNA (°)	81.6	82.5	81	81	81
SNB (°)	79.2	77.5	77	77	77
ANB (°)	2.4	5	4	4	4
PFH/AFH (%)	85.1/127.4 (66.8%)	88/125 (70.4%)	88/125	88/125	88/125
SN-OP (°)	17.9	16	19	18	19
FH-UI (°)	116.0	127	117.5	114.5	115
FMA (°)	24.3	17	18	18	18
IMPA (°)	95.9	113	113	107	107.5
FMIA (°)	59.8	50	49	55	54.5
UL-E plane (mm)	-0.9	0.5	-1.5	-2	-2
LL-E plane (mm)	0.6	0.5	0.5	-1	-1
Interincisal angle (°)	123.8	105	111	121	120
Mx 1 to NA (mm)	7.3	9	5	3	4
Mx 1 to NA (°)	25.3	33	25	20	21.5
Mn 1 to NB (mm)	7.9	8	8	6	6
Mn 1 to NB (°)	28.4	39.5	40	34	34
SN to PP (°)	10.2	9	9.5	9.5	10

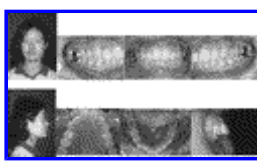
^a Supplement Korea J Orthod. (1997).

FIGURES [Return to TOC](#)



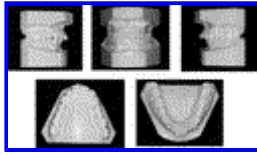
[Click on thumbnail for full-sized image.](#)

FIGURE 1. C-lingual retractor for retraction and intrusion. (A) Mesh part soldered. (B) Lever-arm wire with bent hook. (C) Auxiliary hook soldered for intrusion force. (D) Transpalatal arch soldered



[Click on thumbnail for full-sized image.](#)

FIGURE 2. Pretreatment extraoral and intraoral photographs



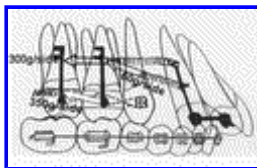
[Click on thumbnail for full-sized image.](#)

FIGURE 3. Pretreatment study models



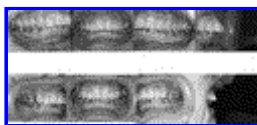
[Click on thumbnail for full-sized image.](#)

FIGURE 4. (A) Diagnostic setup model of en masse retraction of upper six anterior teeth. (B) Tentative diagnostic setup model



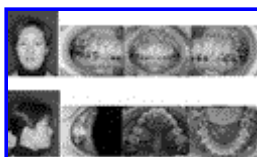
[Click on thumbnail for full-sized image.](#)

FIGURE 5. Diagram of C-lingual retractor and high-pull headgear anchorage




[Click on thumbnail for full-sized image.](#)

FIGURE 6. Progress intraoral photographs. (A) Lower dentition leveling. (B) After C-lingual retractor delivery



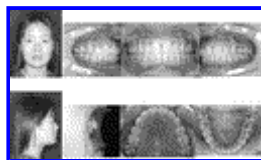
[Click on thumbnail for full-sized image.](#)

FIGURE 7. Progress extraoral and intraoral photograph after en masse retraction of upper six anterior teeth



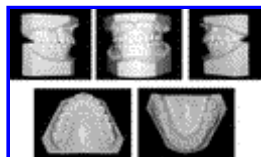
[Click on thumbnail for full-sized image.](#)

FIGURE 8. Progress study models after en masse retraction of upper six anterior teeth



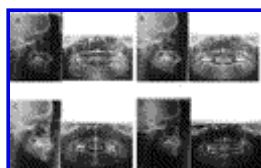
[Click on thumbnail for full-sized image.](#)

FIGURE 9. Posttreatment extraoral and intraoral photos



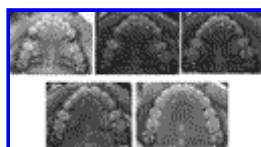
[Click on thumbnail for full-sized image.](#)

FIGURE 10. Posttreatment study models



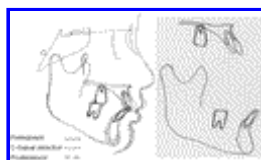[Click on thumbnail for full-sized image.](#)

FIGURE 11. Cephalometric radiograph and panoramic radiograph. (A) Pretreatment. (B) After C-lingual retractor delivery. (C) After en masse retraction of upper six anterior teeth. (D) Posttreatment



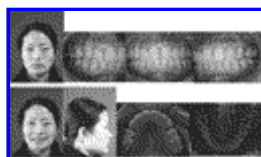
[Click on thumbnail for full-sized image.](#)

FIGURE 12. Occlusal view of orthodontic treatment. (A) After C-lingual retractor delivery. (B) During en masse retraction. (C) After en masse retraction of upper six anterior teeth. (D) During leveling. (E) Posttreatment



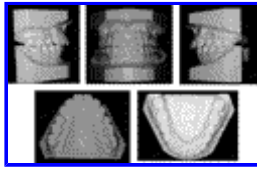
[Click on thumbnail for full-sized image.](#)

FIGURE 13. Superimpositions of lateral cephalograms: pretreatment (solid line) to en masse retraction (dotted line) to posttreatment (double dotted line)



[Click on thumbnail for full-sized image.](#)

FIGURE 14. Six-month postretention extraoral and intraoral photograph



Click on thumbnail for full-sized image.

FIGURE 15. Six-month postretention study models

^aInstructor, Department of Orthodontics, The Catholic University of Korea, Uijongbu St Mary's Hospital, Uijongbu, South Korea

^bProfessor and Chairman, Department of Orthodontics, School of Dental Medicine, Kyung Hee University, Seoul, South Korea

^cPrivate Practice, Seoul, South Korea

Corresponding author: Seong-Hun Kim, DMD, MS, Department of Orthodontics, The Catholic University of Korea, Uijongbu St Mary's Hospital, 65-1 Kumoh-dong Uijongbu Kyunggi-do 480-130, South Korea (E-mail: bravortho@hanmail.net)