

[\[Print Version\]](#)

[\[PubMed Citation\]](#) [\[Related Articles in PubMed\]](#)

TABLE OF CONTENTS

[\[INTRODUCTION\]](#) [\[MATERIALS AND...\]](#) [\[RESULTS\]](#) [\[DISCUSSION\]](#) [\[CONCLUSIONS\]](#) [\[REFERENCES\]](#) [\[TABLES\]](#) [\[FIGURES\]](#)

The Angle Orthodontist: Vol. 74, No. 4, pp. 480-486.

The Role of a High Pull Headgear in Counteracting Side Effects from Intrusion of the Maxillary Anterior Segment

E. van Steenberg, DDS, MDS;^a C. J. Burstone, DDS, MS;^b B. Pahl-Andersen, DDS, PhD;^c I. H. A. Aartman, MSc, PhD

ABSTRACT

Intrusion of incisors is often the preferred treatment of a deep overbite. This study focuses on deep overbite correction by intrusion of maxillary incisors. The purpose of this study is to determine whether high-pull headgear wear can prevent steepening of the buccal segment, extrusion of the buccal segment, maintain arch width, and increase the rate of incisor intrusion. The number of patients needed for this study was calculated to be 20. Patients were between nine and 14 years of age and assigned to one of two groups. In each group, intrusion of maxillary incisors was performed. Patients in one group wore a high-pull headgear at night, and patients in the other group did not. For each patient, a lateral head film, impressions with a wax bite in centric occlusion, and intraoral photographs were taken at the beginning and end of intrusion. This study demonstrated that high-pull headgear had no effect on steepening and extrusion of the buccal segments or on the rate of intrusion but did have an effect on narrowing of the buccal segments. By performing intrusion as described in this study, no statistically significant side effects were observed in the buccal segments, whereas a statistically significant amount of incisor intrusion of 2.24 mm in the no-headgear group and 2.37 mm in the headgear group was observed.


KEY WORDS: Biomechanics, Overbite.


Accepted: August 2003. Submitted: April 2003

INTRODUCTION [Return to TOC](#)

In Class II cases, correction of a deep overbite is often one of the major steps in orthodontic treatment.¹ Depending on diagnosis and treatment objectives, deep overbites can be treated orthodontically by intrusion of maxillary or mandibular incisors (or both), extrusion of buccal segments, or a combination of these. In Class II cases, hinging open of the mandible is not often desired because then the patient's profile will become more convex.

This study focuses on the correction of deep overbite by intrusion of the maxillary central and lateral incisors and evaluates whether a high-pull headgear can decrease the side effects and thereby increase efficiency. To date, very few clinical studies have focused on intrusion.^{2,3,4} Most investigations were performed to compare different methods of deep overbite correction.^{3,4} Other reports on intrusion were on the basis of in vitro or laboratory studies^{1,5,6} and animal studies.^{7,8} Because intrusion is often the preferred way of deep overbite correction, a randomized clinical trial focusing on all aspects related to intrusion is needed as a scientific basis for clinical work and to increase treatment efficiency. This report discusses the most common side effects and the options to reduce these side effects.

Steepening of the buccal segment is caused by the moment $M = F \times D$, where F is the intrusive force, and D is the distance from the point of force application to the center of resistance^{1.2.9-13} ([Figure 1](#) ).

Methods that have been suggested to decrease this side effect include increasing the number of teeth included in the buccal segment,^{1.2.10,11} high-pull headgear wear and decreasing the amount of intrusive force.^{1.2.10} Including the canine in the buccal segment not only increases the size of the buccal segment but also moves the center of resistance anteriorly, thereby decreasing the moment on the buccal segment.^{1.2.6,9,14} A high-pull headgear with a force anterior to the center of resistance counteracts the moment from the intrusion arch that causes steepening of the buccal segment^{1.2.9-12,15} ([Figure 2](#) ).

Extrusion of the buccal segment is caused by a force, F , which is equal in magnitude but opposite in direction to the intrusive force.^{1.2.9-11} Occlusal forces in part counteract extrusion.^{1.2.9,13} To decrease the possibility of extrusion, the clinician has the option of keeping the intrusive force on the anterior segment as low as possible, increasing the size of the buccal segment, and counteracting the extrusive force on the buccal segment by an intrusive force delivered by a high-pull headgear.^{1.2.9,15-17}

Because the extrusive force is delivered buccally to the center of resistance of the maxillary molar or buccal segment, it creates a moment that can decrease the maxillary arch width.^{1.2.9} Besides keeping the forces as low as possible and using a high-pull headgear to counteract the vertical force, the clinician can use a passive transpalatal arch to maintain the intermolar distance.¹⁸ Besides a counteracting force and moment, a high-pull headgear also provides a rigid arch of constant width.

The location of the point of force application in relation to the center of resistance of the anterior segment can alter the axial inclination of that segment.^{1.3.5,6,19,20} A more anterior location of the point of force application causes flaring, whereas a more posterior location causes uprighting of the anterior teeth.^{1.2.5,9-11} Studies on dry skulls have determined that the center of resistance for a segment of four maxillary incisors lies apical to a point on the distal side of the lateral incisor.¹⁶ Therefore, if an intrusion arch is attached at that point, the anterior segment will move bodily in an apical direction.

The force delivered should be at a constant and optimal level,²¹⁻²⁴ and this requires a spring with a low load-deflection ratio. A large fluctuation in the force level causes side effects when the forces are too high or causes no movement at all when the forces are too low, thereby decreasing efficiency. A more constant force can be delivered by bending helices in a stainless steel wire or by using a material such as Titanium Molybdenum Alloy, TMA,^{22,23} which has a lower stiffness and therefore does not need helices. A low load-deflection rate also makes the amount of activation less critical and decreases the need for frequent reactivations. The optimal force level has been reported to be as low as five g/tooth in patients with a decreased periodontal attachment.⁴ Commonly 10–20 g of force is advocated for maxillary incisor intrusion on the basis of clinical experience.^{1.2.3,9} Comparing a low-stiffness with a high-stiffness design is unethical because of the high probability of side effects in the high-stiffness group. A more subtle comparison between higher and lower intrusive forces is more meaningful in creating a more efficient approach toward intrusion. It is important to investigate which amount of force intrudes incisors more efficiently, meaning as fast as possible with the least amount of side effects.

To be able to calculate the magnitude of the moments and forces delivered, the force system should be determinate.^{10,11,25,26} The intrusive force has to be delivered through a point contact to the anterior segment. This can be achieved by tying the intrusion arch in a piggyback fashion onto the anterior segment. The segments should be as rigid as possible to minimize side effects from wire deformation^{1.10} and to evenly distribute the moment and forces over the buccal segment as a unit.^{1.2.9-11}

The purpose of the present study was to determine whether high-pull headgear wear had an effect on steepening, extrusion, and narrowing of the buccal segments and on the rate of incisor intrusion. To evaluate this effect, one group of 10 patients with a rigid buccal segment including first molar, first- and second premolar, and canine where no headgear was worn (group 1) were compared with another group of 10 patients with the same buccal segment where a high-pull headgear with a force anterior to the center of resistance was worn at night (for eight hours per day) (group 2).

To make orthodontic treatment more effective, intrusion is often combined with alignment.^{1.9,10} However, in this study, the primary focus was on the side effects caused by intrusion. Therefore, it was decided that intrusion would be performed after alignment of the buccal and anterior segments.

Null hypothesis

High-pull headgear has no effect on steepening, extrusion, and narrowing of the buccal segments or on the rate of incisor intrusion.

MATERIALS AND METHODS [Return to TOC](#)

Size of the clinical trial

The main purpose of this study was to determine the importance of a high-pull headgear in counteracting side effects from the intrusion arch. The chance of successfully preventing side effects using the high-pull headgear was estimated to be 90%, and the chance of successfully preventing side effects when not using it 10%. Using the formula

$$n = \frac{p_1 \times (100 - p_1) + p_2 \times (100 - p_2)}{p_1 - p_2} f(\alpha, \beta)^{27}$$

the number of patients per group was calculated to be 10. The significance level α was set at 0.05. The power, $1 - \beta$, was set at 0.90. According to these assumptions, 10 patients were required in each group, for a total of 20 patients.

Sample

Twenty orthodontic patients needing maxillary central and lateral incisor intrusion of at least two mm were recruited for this study from a pool of patients referred to the principal investigator's practice. Treatment was performed by this orthodontist only. Patients included in the sample had at least maxillary first molars, first and second premolars, canines, and all maxillary incisors fully erupted and were between nine and 14 years of age. Patients with extremely flared or upright incisors (such as in Class II division 2 patients) were excluded, as were patients with periodontal disease. Patients who needed premolar extractions prior to intrusion were also excluded. No other form of orthodontic treatment was performed in these patients during the time of maxillary incisor intrusion. All patients willing to participate in this study were included in the sample if they met the above-mentioned requirements. The group was subdivided into two subgroups. Assignment of patients to each of the two subgroups was performed by simple randomization.²⁷

Records

For each patient, one lateral cephalometric radiograph and one set of impressions with a wax bite in centric occlusion were taken at the start of intrusion and when intrusion of the four maxillary incisors was complete. Lateral cephalometric radiographs were taken by the principal investigator with the aid of a cephalostat. The patient's head position in the cephalostat was documented so that the pre- and postintrusion cephalometric radiographs were taken with the patient's head in the same position. To distinguish the patient's right and left side, a ligature wire was tied around the right canine bracket in such a way that it was clearly visible on the lateral cephalometric radiograph. Impressions were poured in plaster and trimmed in centric occlusion.

Measurements

Lateral cephalometric radiographs were traced on a computer screen,^{28,29} and a maxillary superimposition (structural) was made from each set of lateral cephalometric radiographs.³⁰ The tracings were digitized and analyses performed by computer.³¹ The following measurements were performed: vertical movement of the center of resistance of the maxillary central incisor perpendicular to the palatal plane (indicating the amount of intrusion); change in axial inclination of the buccal segment; vertical movement of the buccal segment; change in inter molar width, measured on the models; and rate of intrusion, expressed in millimeters per week.

Treatment protocol

Patients were recruited after explanation of the treatment plan by the orthodontist. First, bands and brackets (0.022 × 0.028 inch slot) were placed and segments aligned. Alignment was performed in the anterior segment (right to left lateral incisor) and the buccal segment (canine to first molar), while controlling vertical forces as much as possible.^{1,9,10} When the wire segments had progressed to a passive 0.018 × 0.025 inch stainless steel, one lateral cephalometric radiograph, five intraoral photographs (one frontal, two buccal, and two occlusal), and one set of impressions with a wax bite in centric occlusion were obtained. To be certain that the segments were passive, the wires were left in place for five weeks after insertion, before records were taken and intrusion was started. During the same visit, the intrusion arch was placed and activated to a force level of 40 g measured in the midline (20 g/side).

The clockwise moment produced by the extrusive force on the buccal segment was approximately 600 gmm/side, when the distance from the point of force application in the anterior segment to the center of resistance of the buccal segment was 30 mm and the intrusive force 20 g/side. This moment acted 24 h/day making a total of 14,400 gmmh.

A 20-g extrusive force was present on each buccal segment produced by an intrusion arch that delivered 40 g of force in the midline. This force was delivered 24 h/day for a total of 480 gh.

To prevent steepening of the buccal segment, it was very important to use a high-pull headgear at night with a force anterior to the center of resistance of the buccal segment. To fully counteract the clockwise moment delivered by the intrusion arch, a counterclockwise moment of 1800 gmm was needed during eight hours³² (eight hours × 1800 gmm = 14,400 gmmh).

In this study, the moment delivered to the buccal segment in each patient was calculated from the original cephalometric radiograph by multiplying the intrusive force by the distance from the point of force application at the anterior segment to the center of resistance of the

buccal segment perpendicular to the line of force.^{1,5,6,16,19,32} A mark was made on the headgear so that it delivered 200 g of force per side and could be checked easily and when necessary, adjusted by the patient or parent. The force was assumed to be delivered at 45° to the occlusal plane. In each patient, the outer bow was bent in such a manner that the moment delivered by the headgear was three times the moment delivered by the intrusion arch and in the opposite direction. The amount of gram hours on the buccal segment would therefore be zero. The distance from the buccal cusp tips to the center of resistance of the buccal segment was measured on the original cephalometric radiograph. The distance from the cusp tips to the buccal tube was measured directly in the mouth. Using these measurements, the facebow was bent upward to the extent that the line of force (with a magnitude of 200 g) was nine mm above the center of resistance to deliver the desired moment of 1800 gmm. The outer bow extended as far distally as the inner bow.

Assuming that the line of force was 45° to the occlusal plane, an intrusive force of 141 g (200 times the sine of 45°) acted on the buccal segment while the headgear was worn for a total of 1131 gh (eight hour × 141.42 g). This resulted in a net intrusive force in gram hours on the buccal segment (480 gh extrusive force minus 1131 gh intrusive force). In this clinical trial, the decision was made that it was important to fully counteract the clockwise moment delivered to the buccal segment by the intrusion arch.

Visits were scheduled every five weeks. During each visit, the intrusive force and headgear force were measured, recorded, and, when necessary, adjusted to the proper level. When the incisors were intruded to the proper level, the intrusion arch was removed, and a lateral cephalometric radiograph, impressions, and wax bite were obtained. The same actions were undertaken when side effects were clearly present. Loose bands and brackets were recorded and replaced in a manner that the segment remained passive.

RESULTS [Return to TOC](#)

To test the null hypothesis, an analysis of variance (ANOVA) for repeated measures was used (General Linear Models; GLM procedure in SPSS 10).

Vertical movement of the center of resistance of the maxillary central incisor (indicating the amount of intrusion) is shown in [Table 1](#). The intrusion was statistically significant in both groups, $F_{1,18} = 179.007$ and $P = .000$, but the difference in intrusion between the headgear and no-headgear groups was not statistically significant, $F_{1,18} = 0.142$ and $P = .71$.

Change in axial inclination of the buccal segment is shown in [Table 2](#). The overall change in axial inclination of the buccal segments of both groups combined was small and not statistically significant, $F_{1,18} = 4.41$, $P = .05$. The difference in axial inclination change between both groups was not statistically significant, $F_{1,18} = 0.89$, $P = .36$.

Vertical movement of the buccal segment is shown in [Table 3](#). The difference in vertical movement of the buccal segment between the start and finish of both groups was not statistically significant, $F_{1,18} = 0.00$ and $P = 1.00$. The difference in vertical movement between both groups also was not statistically significant, $F_{1,18} = 1.06$ and $P = .32$.

The change in intermolar width, measured on the models, is shown in [Table 4](#). The change in intermolar width of both groups combined between start and finish was not statistically significant $F_{1,18} = 0.63$ and $P = .44$. However, the difference in change in intermolar width between both groups was statistically significant, $F_{1,18} = 6.00$ and $P = .025$.

The rate of intrusion, expressed in millimeters per week, is shown in [Table 5](#). A one-way ANOVA showed no statistically significant difference in the rate of intrusive movement between the headgear and no-headgear groups.

To test the difference in initial measurements between both groups, a one-way ANOVA was used for the initial measurements. This test revealed no statistically significant differences. To determine the measurement error, the measurements on five patients were repeated. Paired Student's *t*-tests revealed no statistically significant differences between the second set of measurements and the original measurements.

DISCUSSION [Return to TOC](#)

To have the smallest possible measurement error, the digital image of the cephalometric radiograph was enlarged to the extent that the cross-hair symbol used for landmark identification was much smaller than the enlarged landmark itself. Initially, landmark identification was done on the computer screen without enlargement, which resulted in several inaccuracies, which were not coincident with the clinical findings.

The next step was to make acetate tracings of the cephalometric radiographs and to make digital images of these tracings. To make the superimpositions more reliable, it was decided to make structural superimpositions on maxillary skeletal structures using the acetate tracings. This has the clear advantage over the computer superimposition because the complete outlines of the skeletal structures are

used and not just a few digitized points. This method was checked independently by reanalyzing the start and finish cephalometric radiographs of five patients, which revealed no statistically significant differences with the earlier analyses.

The mean amount of maxillary incisor intrusion was 2.24 and 2.37 mm in the no-headgear and headgear group, respectively. Although the intrusion of both groups combined was statistically significant, the difference in intrusion between both groups was not. However, this was not the purpose of this study.

The amount of steepening of the buccal segments was very small (no-headgear group 0.63° and headgear group 0.24°), which was not statistically significant. The amount of steepening was so small that it could be concluded that 20 g of intrusive force per side did not steepen the occlusal plane. Therefore, a high-pull headgear was not necessary to prevent steepening of the buccal segment, if the buccal segment extended from canine to first molar.

The mean vertical movement of the buccal segment was 0.13 mm extrusion for the no-headgear group and 0.13 mm intrusion for the headgear group. Both movements were not statistically significant nor was the difference in vertical movement between both groups. It can be concluded that by performing intrusion as described in this study no extrusion of buccal segments occurs. Apparently the occlusal forces were sufficient to prevent extrusion.

The difference in change in intermolar width between the no-headgear and headgear group was statistically significant. However, the mean changes were small (no-headgear group 0.27-mm decrease and headgear group 0.53-mm increase). The directions of these changes were expected. The decrease in the no-headgear group could be explained by the point of force application of the extrusive force acting buccally to the center of resistance of the buccal segment. An increase in arch width in the headgear group was expected because the intrusive component from the high-pull headgear exceeded the extrusive force from the intrusion arch, resulting in an intrusive force buccal to the center of resistance. To prevent changes in arch width, a passive transpalatal arch has been recommended.¹⁸ The amount of change reported in this study was so small that in a situation where a large buccal segment could be used and the amount of force is around 20 g/side, a transpalatal arch is not necessary.

The mean rate of intrusion was not statistically significant (no-headgear group 0.15 mm/wk and headgear group 0.14 mm/wk). The weekly averages do not mean that the rate of intrusion was constant. To determine constancy in the rate of intrusion, more lateral cephalometric radiographs need to be taken during treatment. When intrusion takes place, the force decreases when the incisor or the buccal segments, or both are moving. This study shows that movement of the buccal segment, with intrusion performed as described, was negligible and did not contribute to a decreased force on the anterior segment. It is important that, when force decreases, the force level does not go beyond the threshold level. A low load-deflection wire such as TMA is therefore important to maintain a constant force above the threshold level.^{22,23} A high-pull headgear increases the intrusive force to the anterior segment,²⁴ but this increase did not make a significant contribution to the increase in the rate of intrusion.

CONCLUSIONS [Return to TOC](#)

The null hypothesis can be partially accepted and partially rejected. High-pull headgear had no effect on steepening and extrusion of the buccal segments or on the rate of intrusion. High-pull headgear did have an effect on narrowing of the buccal segments. The narrowing that occurred without using the high-pull headgear and the widening that occurred because of the high-pull headgear were so small that they were considered clinically irrelevant.

This study shows that statistically significant intrusion of maxillary incisors can be performed without statistically significant side effects on the buccal segments in a population of adolescents. The possible side effects that were measured were change in axial inclination, extrusion, and change in width of the buccal segments. Using 20 g of intrusive force per side, a buccal segment extending from canine to first molar, with both premolars included, is sufficient to counteract side effects. A high-pull headgear to prevent possible side effects is not necessary in this situation.

REFERENCES [Return to TOC](#)

1. Burstone CJ. Deep overbite correction by intrusion. *Am J Orthod.* 1977; 72:1–22. [[PubMed Citation](#)]
2. Gottlieb BS. *The Effects of an Intrusive Base Arch on Tooth Position: A Radiographic Study.* Unpublished thesis University of Connecticut, 1979.
3. Weiland FJ, Bantleon HP, Droschl H. Evaluation of continuous arch and segmented arch leveling techniques in adult patients— a clinical study. *Am J Orthod Dentofacial Orthop.* 1996; 110:6647–652. [[PubMed Citation](#)]
4. Melsen B, Agenbæk N, Markenstam G. Intrusion of incisors in adult patients with marginal bone loss. *Am J Orthod Dentofacial Orthop.* 1989; 96:3232–241. [[PubMed Citation](#)]

5. Vanden Bulcke M, Sachdeva R, Burstone CJ. The center of resistance of anterior teeth during intrusion using the laser reflection technique and holographic interferometry. *Am J Orthod.* 1986; 90:3211–219.
6. Dermaut LR, Vanden Bulcke MM. Evaluation of intrusive mechanics of the type “segmented arch” on a macerated human skull using the laser reflection technique and holographic interferometry. *Am J Orthod Dentofacial Orthop.* 1986; 89:3251–263.
7. Dellinger EL. A histological and cephalometric investigation of premolar intrusion in the macaca speciosa monkey. *Am J Orthod.* 1967; 53:325–355. [[PubMed Citation](#)]
8. Steigman S, Michaeli Y. Experimental intrusion of rat incisors with continuous loads of varying magnitude. *Am J Orthod.* 1981; 80:4429–436. [[PubMed Citation](#)]
9. Burstone CJ, van Steenberg E, Hanley KJ. *Modern Edgewise Mechanics and The Segmented Arch Technique.* Farmington, Conn: University of Connecticut Health Center; 1995:23–30.
10. Burstone CJ. The rationale of the segmented arch. *Am J Orthod.* 1962; 48:11805–821. [[PubMed Citation](#)]
11. Smith RJ, Burstone CJ. Mechanics of tooth movement. *Am J Orthod.* 1984; 85:4294–307. [[PubMed Citation](#)]
12. van Steenberg E, Nanda R. Biomechanics of orthodontic correction of dental asymmetries. *Am J Orthod Dentofacial Orthop.* 1995; 107:6618–624. [[PubMed Citation](#)]
13. Romeo DA, Burstone CJ. Tip-back mechanics. *Am J Orthod.* 1977; 72:4414–421. [[PubMed Citation](#)]
14. Woods MG. The mechanics of lower incisor intrusion: experiments in nongrowing baboons. *Am J Orthod Dentofacial Orthop.* 1988; 93:3186–195. [[PubMed Citation](#)]
15. Firouz M, Zernik J, Nanda R. Dental and orthopedic effects of high-pull headgear in treatment of Class II, division 1 malocclusion. *Am J Orthod Dentofacial Orthop.* 1992; 102:3197–205. [[PubMed Citation](#)]
16. Dermaut LR, Kleutghen JPJ, De Clerck HJJ. Experimental determination of the center of resistance of the upper first molar in a macerated, dry human skull submitted to horizontal headgear traction. *Am J Orthod Dentofacial Orthop.* 1986; 90:29–36. [[PubMed Citation](#)]
17. Armstrong MM. Controlling the magnitude, direction and duration of extraoral force. *Am J Orthod.* 1971; 59:217–243. [[PubMed Citation](#)]
18. Burstone CJ, Manhartsberger C. Precision lingual arches—passive applications. *J Clin Orthod.* 1981; 22:7444–451.
19. Burstone CJ, Pryputniewicz RJ. Holographic determination of centers of rotation produced by orthodontic forces. *Am J Orthod.* 1980; 77:396 [[PubMed Citation](#)]
20. Melsen B, Fotis V, Burstone CJ. Vertical force considerations in differential space closure. *J Clin Orthod.* 1990; 24:678–683. [[PubMed Citation](#)]
21. Goldberg AJ, Vanderby R, Burstone CJ. Reduction in the modulus of elasticity in orthodontic wires. *J Dent Res.* 1977; 56:11227–1231. [[PubMed Citation](#)]
22. Goldberg AJ, Burstone CJ. An evaluation of beta titanium alloys for use in orthodontic appliances. *J Dent Res.* 1979; 58:92593–600. [[PubMed Citation](#)]
23. Burstone CJ, Goldberg AJ. Beta titanium: a new orthodontic alloy. *Am J Orthod.* 1980; 72:121–132.
24. Burstone CJ, Baldwin JJ, Lawless DT. The application of continuous force to orthodontics. *Angle Orthod.* 1961; 31:1–14.
25. Burstone CJ, Koenig HA. Force systems from an ideal arch. *Am J Orthod.* 1974; 65:270–289. [[PubMed Citation](#)]
26. Burstone CJ, Koenig HA. Creative wire bending—the force system from step and V bends. *Am J Orthod Dentofacial Orthop.* 1988; 93:59–67. [[PubMed Citation](#)]
27. Pocock SJ. *Clinical Trials, a Practical Approach.* Wiley & Sons; 1984:73–76.
28. Baumrind S, Frantz R. The reliability of headfilm measurements: 1 landmark identification. *Am J Orthod.* 1971; 60:111–127. [[PubMed Citation](#)]

29. Baumrind S. The reliability of headfilm measurements: 2 linear and angular measurements. *Am J Orthod.* 1971; 60:506–517.

30. Baumrind S, Miller D, Molthen R. The reliability of headfilm measurements: 3 tracing superimpositions. *Am J Orthod.* 1976; 70:506–517.

31. Faber R, Burstone CJ, Solonche DJ. System of computerized treatment planning. *Am J Orthod.* 1978; 73:136–46. [[PubMed Citation](#)]

32. Braun S, Bluestein M. A new concept: impulse in orthodontics. *Am J Orthod Dentofacial Orthop.* 1997; 111:437–440. [[PubMed Citation](#)]

TABLES [Return to TOC](#)

TABLE 1. Mean Vertical Movement of the Center of Resistance of the Maxillary Central Incisor to the Palatal Plane (mm)

Group	Start (SD)	Finish (SD)	Difference (SD)
No headgear	10.44 (1.45)	8.20 (1.75)	2.24 (0.53)
Headgear	10.49 (3.04)	8.12 (2.68)	2.37 (0.86)

TABLE 2. Change in Axial Inclination of the Buccal Segment in Degrees. The Start and Finish Columns Show the Mean Angle Between the Maxillary Left Buccal Segment and the Palatal Plane in Degrees. The Difference Indicates the Change in Axial Inclination of the Buccal Segment

Group	Start (SD)	Finish (SD)	Difference (SD)
No headgear	8.84 (3.61)	9.47 (3.92)	0.63 (1.15)
Headgear	7.62 (3.36)	7.86 (3.66)	0.24 (0.64)

TABLE 3. The Start and Finish Columns Show the Mean Distance in Millimeters Between the Center of Resistance of the Buccal Segment and the Palatal Plane. The Difference Means the Vertical Movement, Which is an Extrusive Movement in the No Headgear Group and an Intrusive Movement in the Headgear Group

Group	Start (SD)	Finish (SD)	Difference (SD)
No headgear	9.38 (1.64)	9.51 (1.30)	0.13 (0.60)
Headgear	9.43 (2.24)	9.30 (1.99)	–0.13 (0.53)

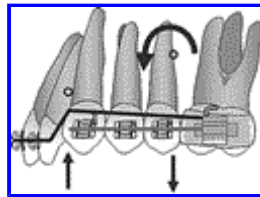
TABLE 4. The Mean Intermolar Arch Widths in Millimeters are Shown in the Start and Finish Columns. The Difference Indicates the Change in Intermolar Width

Group	Start (SD)	Finish (SD)	Difference (SD)
No headgear	50.88 (3.80)	50.61 (3.33)	0.27 (0.53)
Headgear	50.13 (3.37)	50.66 (2.65)	0.53 (0.89)

TABLE 5. The Mean Amount of Vertical Movement Per Week (mm) is Shown with the Maximum and Minimum Amount of Movement in Each Group

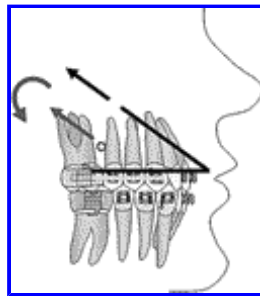
Group	Rate (SD)	Minimum	Maximum
No headgear	0.15 (0.05)	0.08	0.26
Headgear	0.14 (0.07)	0.03	0.27

FIGURES [Return to TOC](#)



Click on thumbnail for full-sized image.

FIGURE 1. Force system delivered by the intrusion arch with an intrusive force on the anterior segment and an extrusive force and a counterclockwise moment on the buccal segments



Click on thumbnail for full-sized image.

FIGURE 2. Force system delivered by a high-pull headgear with a force above the center of resistance of the buccal segment

^aPrivate practice, Apeldoorn, The Netherlands

^bProfessor Emeritus, University of Connecticut Health Center, Department of Orthodontics, University of Connecticut, Farmington, Conn

^cChairperson, Orthodontic Department, Academic Centre of Dentistry, Amsterdam, The Netherlands

^dAssistant Professor, Methodologist, Department of Orthodontics and Social Dentistry, Section of Social Dentistry and Dental Health Education, Academic Centre for Dentistry Amsterdam, Amsterdam, The Netherlands

Corresponding author: E. van Steenberg, DDS, MDS, Orthodontiepraktijk Van Steenberg, Hofdwarstraat 1 c, 7311 KK Apeldoorn, The Netherlands (E-mail: ecbt@vansteenbergen.nl)