

[\[Print Version\]](#)  
[\[PubMed Citation\]](#) [\[Related Articles in PubMed\]](#)

## TABLE OF CONTENTS

[\[INTRODUCTION\]](#) [\[MATERIALS AND...\]](#) [\[RESULTS\]](#) [\[DISCUSSION\]](#) [\[CONCLUSIONS\]](#) [\[REFERENCES\]](#) [\[TABLES\]](#) [\[FIGURES\]](#)

*The Angle Orthodontist*: Vol. 73, No. 3, pp. 281–285.

# Maxillary Expansion in Class II Correction with Orthopedic Cervical Headgear. A Posteroanterior Cephalometric Study

Mirja Kirjavainen, DDS;<sup>a</sup> Turkka Kirjavainen, MD, DScMed<sup>b</sup>

## ABSTRACT

Class-II, division-1 malocclusion appears to be associated with a narrow maxilla. A class-II malocclusion may be corrected to a class-I relationship in children using a cervical headgear provided that the narrow maxilla is expanded. This expansion is possible using headgear by dental cast analysis, but this has not been confirmed by cephalometry. We studied the effects of orthopedic cervical headgear on dental and skeletal facial widths in 40 children aged 9.1 (7.2–11.5) who had class-II, division-1 malocclusions. The headgear consisted of a long outer bow bent 15° upward and a large inner bow expanded by 10 mm. Posteroanterior cephalographs and dental casts were taken before and after treatment. The results were compared with the control values presented in the literature. The malocclusion was treated to a class-I relationship in all children. The average treatment time was 1.6 (0.3–3.1) years. The maxilla was widened significantly ( $P < .0001$ ). The upper first molar width (um-um) and maxillary width (mx-mx) increased 3.2 and 1.6 mm/y, respectively. Maxillary widening was also observed in the nasal structure as indicated by an increase in lateronasal width (lap-lap) by 1.0 mm/y ( $P < .005$ ). With maxillary widening, the mandibular dental arch widened spontaneously. The lower first molar width (lm-lm) increased 0.8 mm/y, which was more than the increase in the controls ( $P < .0001$ ). However, the antegonial width (ag-ag) remained unaffected. By using a widened inner bow in headgear therapy with class-II malocclusions, a widening of maxilla and nasal cavity may be obtained.

**KEY WORDS:** Orthopedic cervical pull, Class II division 1 correction, Posteroanterior, Cephalometric.

Accepted: August 2002. Submitted: June 2002

## INTRODUCTION [Return to TOC](#)

Class-II, division-1 malocclusion and dental crowding are the two most common indications for orthodontic treatment in Finland.<sup>1</sup> For the correction of a class-II malocclusion, orthopedic cervical headgear is widely used as an early treatment appliance because it is easy to use and is acceptable by children. The principle of orthopedic headgear treatment is to apply a strong pulling force on the maxillary first molars to restrict the forward growth of maxilla.<sup>2</sup>

In children with a class-II, division-1 malocclusion, the maxilla is often narrow.<sup>3,4</sup> This may be seen already at the age of five years when children still have the deciduous dentition.<sup>3,5</sup> When correcting the malocclusion with a headgear, it appears to be essential to widen the narrow maxilla to avoid a downward and backward growth rotation of the mandible.<sup>2,6,7</sup> Studies with dental casts indicate that expansion of

the maxilla can be achieved by using a cervical headgear with large, expanded inner bows.<sup>8,9</sup> The results have not been confirmed by cephalographic analysis.<sup>9</sup>

Posteroanterior (PA) cephalographs are used to diagnose and quantify facial asymmetries and skeletal structural abnormalities.<sup>10,11</sup> However, the use of PA cephalography in orthodontic practice is rare, and hence, there are only a limited number of studies available concerning this method.

The purpose of the present study was to investigate the effects of orthopedic cervical headgear therapy on skeletal facial widths in children with class-II, division-1 malocclusion. The headgear used had a large, expanded inner bow. Skeletal facial widths were measured by PA cephalometry and pre- and posttreatment measurements were compared.

## MATERIALS AND METHODS [Return to TOC](#)

### Patients

Forty healthy school children, 20 boys and 20 girls, who were consecutively referred to the Health Center of Forssa for the treatment of class-II, division-1 malocclusion, were included in the present study. The inclusion criteria were (1) class-II first molar relationship with an overjet more than two mm, (2) a protrusive maxilla confirmed by cephalometric analysis where A-point was in the front of the nasion-pogonion line, (3) availability of pre- and posttreatment plaster models, lateral and PA cephalograms, (4) the age of six to 12 years at the date of referral, (5) otherwise healthy condition, and (6) expectancy of good or at least moderate cooperation.

The first author treated the subjects with the orthopedic cervical headgear without any other appliances. The mean age of the children at the beginning of the treatment was 9.1 (SD 1.0, range 7.2–11.5) years and at the end of the treatment was 10.7 (SD 1.1, range 8.6–13.0) years. Thirty-three children had good cooperation and seven had moderate cooperation.


For ethical reasons, we were not able to use our own control data. Therefore, all PA cephalometric measurements were compared with the normal control values presented by Athanasiou et al.<sup>12</sup> The control population consisted of 588 Austrian schoolchildren (157 girls and 431 boys) aged between six and 15 years. They were examined during the years of 1974 and 1975.



### Methods

The class-II, division-1 malocclusions were treated with a KloeHN-type cervical headgear with a large inner bow and long outer bow.<sup>2,7,9</sup> To keep teeth out of contact with cheeks and lips, horizontal bayonets were bent in the inner bow. The distance between the bow and the anterior teeth was set to three mm. The ends of the inner bow were bent inward to prevent the mesiopalatine rotation of the first molars or to rotate the first molars into their correct position. The inner bow of the headgear also was expanded 10 mm larger than the distance between the maxillary first molar tubes and made parallel to the occlusal plane. The long rigid outer bow was bent 15° upward to prevent distal tipping of the first molar crowns. To prevent buccal and distal tipping of the first molar crowns, the molar tubes were placed as close to the gingival margin as possible.<sup>13</sup>

A force of 500 g per side was used for cervical traction. The expansion of the inner bow and the amount of force used were adjusted at six to eight week intervals. The subjects were asked to wear the headgear for 12 to 14 hours a day, in the evenings and at nights. Children were asked to keep a daily diary of their headgear wearing. Cooperation was estimated according to the diary notes and the signs of use in the headgear such as tearing of the elastic band and neck strap. The treatment was finished when the class-I molar relationship was achieved. Some children needed further treatment for horizontal overjet. Dental cast analysis has been previously described.<sup>9</sup>

### Posteroanterior cephalometry

To analyze the effects of cervical headgear therapy on the facial and dental widths, PA cephalographs were taken before and after the treatment. The cephalographs were taken using a cephalostat (Cranex DC2 cephalostat). The distance between the ear rods and the film was fixed at 20 cm and the distance between the anode and the film at 170 cm. The landmarks used are presented in [Figure 1](#) .

To estimate a correction factor for magnification for each of the landmarks used, metal buttons 1.5 mm in diameter were implanted in a dry human adult skull, and a lateral cephalogram was exposed in the cephalostat. The correction factor for each of the landmarks used was calculated using the method described by Hsiao et al.<sup>14</sup> Correction factors are presented in [Table 1](#) . In the description of the control population, Athanasiou et al.<sup>12</sup> did not use any correction factor. Hence, we preferred the use of relationships of distances regarding latero-orbital distance (lo-lo) ([Table 2](#) ). However, the results were also compared with the normal control values without any correction.

### Measurement reproducibility

Serial pre- and posttreatment measurements were taken in five randomly selected children to assess measurement repeatability. The mean difference between the two measurements was 0.27 mm (SD 0.34, range 0–1.5 mm). The measurements were free of systematic

error.

## Statistical methods

All the statistical analyses were performed with SPSS® statistical software (SPSS for Windows, release 10.0.7, SPSS Inc, Chicago, Ill). Paired *t*-tests were used to compare pre- and posttreatment measurements. The Student's *t*-test was used to compare differences between sexes and to compare values with the normal cohort presented by Athanasiou et al.<sup>12</sup> Correlations between variables were calculated by linear regression analyses using the least squares method. *P* values less than 0.05 were considered statistically significant.

## RESULTS [Return to TOC](#)

The treatment was successful in all the children, and a class-I molar relationship was achieved. The mean treatment time was 1.6 (SD 0.7, range 0.3–3.1) years. The changes in skeletal facial widths are presented in [Tables 1](#) and [2](#) and in [Figure 2](#). The pre- and posttreatment values of Im-Im were wider in boys than in girls (*P* < .01). However, no other differences were observed between the sexes, and hence, the results are presented together.

The maxilla was widened by the treatment in parallel with the correction of the malocclusion. The upper first molar width (um-um/lo-lo) and the maxillary width (mx-mx/lo-lo) increased more than the increase in the controls (*P* < .0001). The treatment also caused widening in the nasal cavity. The lateronasal width (lap-lap/lo-lo) was increased somewhat more than in the controls (*P* < .005). The mandibular dental arch widened spontaneously. The lower first molar width (lm-lm/lo-lo) increased more than in the controls (*P* < .0001), whereas the antegonial width (ag-ag/lo-lo) remained unaffected.

The treatment was delivered exclusively to the upper first molars. Despite this, the widening of maxillary alveolar process and nasal cavity were accompanied with the widening of intermolar distance. The changes in mx-mx ( $r^2 = 0.28$ , *P* < .001) and lap-lap ( $r^2 = 0.30$ , *P* < .001) correlated with the change seen in um-um ([Figure 3](#)). Also, the change in lap-lap correlated with the change in mx-mx ( $r^2 = 0.19$ , *P* < .01).

## Dental cast analysis

To confirm the results of PA cephalographs, the dental casts of the children were also analyzed. Before the treatment, the dental arch widths of these children were smaller than the dental arch widths of normal 9-year-old Finnish children (*P* < .02).<sup>15</sup> The treatment expanded the maxillary and mandibular dental arches significantly. This was seen in the intercanine (maxilla, *P* < .001; mandible, *P* < .05) and intermolar (*P* < .001) distances, which increased more rapidly than in the control children.<sup>16</sup>

The change in intermolar distance measured from the plaster models correlated significantly to the change in um-um ( $r^2 = 0.62$ , *P* < .001) and mx-mx ( $r^2 = 0.19$ , *P* < .01) distances as determined from the PA cephalographs. However, the change in lap-lap distance did not correlate with the change in maxillary cuspal intermolar distance ( $r^2 = 0.06$ , ns) but correlated with the gingival intermolar distance ( $r^2 = 0.11$ , *P* < .05).

## DISCUSSION [Return to TOC](#)

We have shown in this study, with PA cephalometry, that the dental arches, the maxilla, and nasal cavity can be widened in parallel with the correction of class-II, division-1 malocclusion by the use of orthopedic cervical headgear. The inner bow of the headgear was expanded to achieve widening of the maxilla and mandible. With this method, the malocclusion was successfully treated in all children, and a concurrent significant widening of the upper dental arch and the maxilla was noted together with the spontaneous widening of the mandibular dental arch. The width of the mandibular body remained unaffected.

We used PA cephalometry to estimate the effects of the treatment on skeletal facial and dental widths. The use of PA cephalometry is not as standardized as the use of lateral cephalometry. This causes problems especially in different magnifications, which we overcame in our study using two methods. First, we compared our results as ratios of measured widths over the latero-orbital distance (lo-lo) to control values previously reported by others.<sup>12</sup> The latero-orbital distance is relatively constant in older children and, therefore, is probably not affected by treatment interventions. In children used in this study, this distance grew only by 0.6 mm/y (*P* < .001). Second, we corrected the measurements by using the method described by Hsiao et al.<sup>14</sup> The comparison with the control values was limited because the control measurements were reported without any correction factor. To be able to compare the real values to the control values, we used the same correction factors for both our patients and the control patients. This could have caused some errors in the comparisons ([Tables 1](#) and [2](#)).

Dental casts were analyzed to confirm the effects of the treatment on dental arch widths. The results of the dental cast analysis were similar to our previous study.<sup>9</sup> Dental cast and PA cephalographic measurements correlated more weakly than expected. This is likely to reflect some inaccuracy in the imaging with PA cephalometry despite the use of the cephalostat. Also, the fact that molar bands were

absent in the pretreatment cephalograms and present in the posttreatment ones may have added some inaccuracy.

The children with class-II malocclusion have a narrow maxilla.<sup>3-5</sup> This narrowness together with the maxillary and mandibular interarch discrepancy are seen already in the deciduous dentition.<sup>3</sup> A narrow maxilla is likely to be a key factor in the development of the malocclusion. The narrowness leads to an interarch discrepancy and consequently to a counterclockwise rotation or a functional retrusion of the mandible without a marked effect on the size of the mandible.<sup>4,17,18</sup> The expansion of the maxillary dental arch and the maxilla itself may enable normal mandibular growth and its clockwise rotation upward and forward.<sup>7,17,19</sup> During the past few decades, there has been a significant tendency toward narrower maxillary transverse dimensions.<sup>20</sup> These issues emphasize the significance of the maxillary expansion. Without any intervention and maxillary widening, interarch discrepancy is expected to increase with age.<sup>21,22</sup> This is because of the maxillary and mandibular growth pattern.<sup>17,19,23</sup>

In the present study, the achieved significant maxillary widening was on average 3.7 mm (6.2%). This increase in the maxillary width is likely also to have beneficial effects other than its effect on the interarch discrepancy and the development of the occlusion. The widening of the maxillary dental arch enhances facial appearance when smiling. The larger dental arch does not leave excessive space at the corner of the lips.<sup>24</sup> Together with the widening of the maxillary dental arch, the width of nasal cavity increased by 2.2 mm (9.2%). This increase is expected to decrease the nasal breathing resistance,<sup>25</sup> although the decrease is not predictable for an individual patient according to the increase in the nasal width.<sup>26</sup> The importance of this increase in nasal width may also be reduced because although resistance may decrease, it is not necessarily accompanied by an improvement in nasal function.<sup>27</sup>

We started headgear therapy when the children were between 7 and 12 years of age. At this age, the midpalatal suture is still at the infantile or juvenile stage without stable and firm overlapping bony interdigitation.<sup>28</sup> Hence, the expansion of the palate is still possible. The increase in maxillary width has been attributed to sutural growth.<sup>29</sup> Therefore, it is likely that the headgear therapy induced this growth. Another treatment appliance binding the teeth together during the therapy may have had a preventive effect on the sutural widening, and thus, an adverse effect on the results.

## CONCLUSIONS [Return to TOC](#)

Class-II, division-1 malocclusions can be corrected to a class-I molar relationship with orthopedic cervical headgear as the only treatment appliance. The growth of the midpalatal suture may be attained to a degree sufficient to cause a significant widening of the maxillary dental arch while increasing intranasal capacity.

## REFERENCES [Return to TOC](#)

1. Heikinheimo K, Salmi K, Myllärniemi S. Long term evaluation of orthodontic diagnoses made at the ages of 7 and 10 years. *Eur J Orthod.* 1987; 9:151–159. [[PubMed Citation](#)]
2. Bench RW, Gugino CF, Hilgers JJ. Bioprogressive therapy. Part 5. *J Clin Orthod.* 1978; 12:48–69. [[PubMed Citation](#)]
3. Baccetti T, Franchi L, McNamara JA Jr, Tollaro I. Early dentofacial features of Class II malocclusion: a longitudinal study from the deciduous through the mixed dentition. *Am J Orthod Dentofacial Orthop.* 1997; 111:502–509. [[PubMed Citation](#)]
4. Tollaro I, Baccetti T, Franchi L, Tanasescu CD. Role of posterior transverse interarch discrepancy in Class II, Division 1 malocclusion during the mixed dentition phase. *Am J Orthod Dentofacial Orthop.* 1996; 110:417–422. [[PubMed Citation](#)]
5. Varrela J. Early developmental traits in Class II malocclusion. *Acta Odontol Scand.* 1998; 56:375–377. [[PubMed Citation](#)]
6. Haas AJ. Palatal expansion: just the beginning of dentofacial orthopedics. *Am J Orthod.* 1970; 57:219–255. [[PubMed Citation](#)]
7. Kirjavainen M, Kirjavainen T, Hurmerinta K, Haavikko K. Orthopedic cervical headgear with an expanded inner bow in Class II correction. *Angle Orthod.* 2000; 70:317–325. [[PubMed Citation](#)]
8. Ricketts RM, Bench RW, Gugino CF, Hilgers JJ, Schulhof RJ. *Bioprogressive Therapy*. Denver, Colo: Rocky Mountain Orthodontics; 1979.
9. Kirjavainen M, Kirjavainen T, Haavikko K. Changes in dental arch dimensions by use of an orthopedic cervical headgear in Class II correction. *Am J Orthod Dentofacial Orthop.* 1997; 111:59–66. [[PubMed Citation](#)]
10. Ricketts RM. Perspectives in the clinical application of cephalometrics. The first fifty years. *Angle Orthod.* 1981; 51:115–150. [[PubMed Citation](#)]

11. Athanasiou AE, Vander Meij AJW. Postero-anterior (frontal) cephalometry. In: Athanasiou AE, ed. *Orthodontic Cephalometry*. London: Mosby-Wolfe; 1995:141–161.
12. Athanasiou AE, Droschl H, Bosch C. Data and patterns of transverse dentofacial structure of 6- to 15-year-old children: a posteroanterior cephalometric study. *Am J Orthod Dentofacial Orthop*. 1992; 101:465–471. [[PubMed Citation](#)]
13. Worms FW, Isaacson RJ, Speidel TM. A concept and classification of centers of rotation and extraoral force systems. *Angle Orthod*. 1973; 43:384–401. [[PubMed Citation](#)]
14. Hsiao TH, Chang HP, Liu KM. A method of magnification correction for posteroanterior radiographic cephalometry. *Angle Orthod*. 1997; 67:137–142. [[PubMed Citation](#)]
15. Huggare J, Lahtela P, Viljamaa P, Nystrom M, Peck L. Comparison of dental arch dimensions in children from southern and northern Finland. *Proc Finn Dent Soc*. 1993; 89:95–100.
16. Moorrees CFA. *The Dentition of the Growing Child*. Cambridge, Mass: Harvard University Press; 1959.
17. Björk A. Prediction of mandibular growth rotation. *Am J Orthod*. 1969; 55:585–599. [[PubMed Citation](#)]
18. Staley RN, Stuntz WR, Peterson LC. A comparison of arch widths in adults with normal occlusion and adults with Class II, Division 1 malocclusion. *Am J Orthod*. 1985; 88:163–169. [[PubMed Citation](#)]
19. Skieller V, Björk A, Linde-Hansen T. Prediction of mandibular growth rotation evaluated from longitudinal implant sample. *Am J Orthod*. 1984; 86:359–370. [[PubMed Citation](#)]
20. Lindsten R, Ogaard B, Larsson E. Transversal dental arch dimensions in 9-year-old children born in the 1960s and the 1980s. *Am J Orthod Dentofacial Orthop*. 2001; 120:576–584. [[PubMed Citation](#)]
21. Ricketts RM. The influence of orthodontic treatment on facial growth and development. *Angle Orthod*. 1960; 30:103–133.
22. Mills CM, Holman RG, Graber TM. Heavy intermittent cervical traction in Class II treatment: a longitudinal cephalometric assessment. *Am J Orthod*. 1978; 72:361–379.
23. Huertas D, Ghafari J. New posteroanterior cephalometric norms: a comparison with craniofacial measures of children treated with palatal expansion. *Angle Orthod*. 2001; 71:285–292. [[PubMed Citation](#)]
24. Sarver DM. The importance of incisor positioning in the esthetic smile: the smile arc. *Am J Orthod Dentofacial Orthop*. 2001; 120:98–111. [[PubMed Citation](#)]
25. Hershey HG, Stewart BL, Warren DW. Changes in nasal airway resistance associated with rapid maxillary expansion. *Am J Orthod*. 1976; 69:274–284. [[PubMed Citation](#)]
26. Hartgerink DV, Vig PS, Abbott DW. The effect of rapid maxillary expansion on nasal airway resistance. *Am J Orthod Dentofacial Orthop*. 1987; 92:381–389. [[PubMed Citation](#)]
27. Warren DW, Hershey HG, Turvey TA, Hinton VA, Hairfield WM. The nasal airway following maxillary expansion. *Am J Orthod Dentofacial Orthop*. 1987; 91:111–116. [[PubMed Citation](#)]
28. Melsen B. Palatal growth studied on human autopsy material. A histologic microradiographic study. *Am J Orthod*. 1975; 68:42–54. [[PubMed Citation](#)]
29. Björk A, Skieller V. Growth of the maxilla in three dimensions as revealed radiographically by the implant method. *Br J Orthod*. 1977; 4:53–64. [[PubMed Citation](#)]

---

TABLES [Return to TOC](#)

**TABLE 1.** Pre- and Posttreatment Values and Changes in the Skeletal and Dental Measures (mm)

Measure	Corr factor	Pretreatment		Posttreatment		Change	
		Mean	SD	Mean	SD	(mm/y)	SD
<b>Skeletal widths</b>							
mx-mx	0.919	59.1 <sup>0***</sup>	2.5	62.7 <sup>0***</sup>	3	1.6 <sup>***</sup>	1
ag-ag	0.898	74.8 <sup>0*</sup>	3.4	78.1 <sup>0*</sup>	3.8	1.5	1.1
lap-lap	0.93	23.6 <sup>1***</sup>	2.4	25.8 <sup>1*</sup>	2.7	1.0 <sup>**</sup>	0.8
lo-lo	0.927	84.0 <sup>1***</sup>	2.9	85.3 <sup>1***</sup>	3.4	0.6	0.9
<b>Dental widths</b>							
um-um	0.919	54.9 <sup>0***</sup>	2.3	61.5 <sup>0***</sup>	3	3.2 <sup>***</sup>	1.7
lm-lm	0.919	54.7 <sup>0***</sup>	2	56.3 <sup>0***</sup>	2	0.8 <sup>***</sup>	0.8

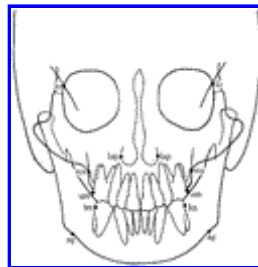\*  $P < .05$ ; \*\*  $P < .01$ ; \*\*\*  $P < .001$ . Superscript at the end of the number indicates whether the value is larger (<sup>0</sup>) or smaller (<sup>1</sup>) than the normal mean<sup>12</sup> or if the treatment has changed width significantly in comparison to the change observed in the normal population.<sup>12</sup> All measurements were changed significantly ( $P < .001$ ) when pre- and posttreatment values were compared to each other. Values are corrected with the presented correction factor.

**TABLE 2.** Pre- and Posttreatment Relationships of Widths over the lo-lo Measurement (mm)

Measure	Pretreatment		Posttreatment		Change	
	Mean	SD	Mean	SD	in Ratio	SD
<b>Skeletal widths</b>						
mx-mx/lo-lo	0.710 <sup>0***</sup>	0.027	0.742 <sup>0***</sup>	0.031	0.033 <sup>***</sup>	0.03
ag-ag/lo-lo	0.920 <sup>0***</sup>	0.048	0.946 <sup>0***</sup>	0.05	0.026 <sup>***</sup>	0.024
lap-lap/lo-lo	0.280 <sup>1*</sup>	0.028	0.301	0.03	0.021 <sup>***</sup>	0.015
<b>Dental widths</b>						
um-um/lo-lo	0.660 <sup>0***</sup>	0.026	0.727 <sup>0***</sup>	0.033	0.067 <sup>***</sup>	0.03
lm-lm/lo-lo	0.657 <sup>0***</sup>	0.024	0.666 <sup>0***</sup>	0.026	0.009 <sup>***</sup>	0.014


\*  $P < .05$ ; \*\*  $P < .01$ ; \*\*\*  $P < .001$ . Superscript at the end of the number indicates whether the value is larger (<sup>0</sup>) or smaller (<sup>1</sup>) than the normal mean<sup>12</sup> or if the treatment has significantly changed the ratio in comparison to the change in the normal population.<sup>12</sup> All ratios were changed significantly ( $P < .001$ ) when pre- and post-treatment values were compared to each other.

**FIGURES** [Return to TOC](#)




[Click on thumbnail for full-sized image.](#)

**FIGURE 1.** The skeletal and dental cephalometric landmarks used in this study. lo-lo = latero-orbitale distance; lap-lap = internasal distance; mx-mx = maxillary width; um-um = upper first molar width; lm-lm = lower first molar width; ag-ag = mandibular width



Click on thumbnail for full-sized image.

**FIGURE 2.** Pre- (open) and posttreatment (solid) values of PA measurements in boys (●) and girls (▼) as a ratio to lo-lo measurement



Click on thumbnail for full-sized image.

**FIGURE 3.** Correlations between the changes in maxillary upper first molar width and maxillary width and between the upper first molar width and the nasal width

<sup>a</sup>Pedodontics and Orthodontics, University of Helsinki, Finland

<sup>b</sup>Registrar of Neonatology, Department of Pediatrics, University of Helsinki, Finland

Corresponding author: Mirja Kirjavainen, DDS, Venhontie 7, 31300 Tammela, Finland (E-mail: [mirja.kirjavainen@fimnet.fi](mailto:mirja.kirjavainen@fimnet.fi))