

[\[Print Version\]](#)  
[\[PubMed Citation\]](#) [\[Related Articles in PubMed\]](#)

## TABLE OF CONTENTS

[\[INTRODUCTION\]](#) [\[MATERIALS AND...\]](#) [\[RESULTS\]](#) [\[DISCUSSION\]](#) [\[CONCLUSIONS\]](#) [\[REFERENCES\]](#) [\[TABLES\]](#) [\[FIGURES\]](#)

*The Angle Orthodontist*: Vol. 73, No. 5, pp. 493-501.

# Amount and Direction of Temporomandibular Joint Growth Changes in Herbst Treatment: A Cephalometric Long-Term Investigation

Hans Pancherz, DDS, Odont Dr, FCDSHK (Hon);<sup>a</sup> Svenja Fischer, DDS, Dr med dent<sup>b</sup>

## ABSTRACT

The amount and direction of condylar growth, glenoid fossa displacement, and "effective" temporomandibular joint (TMJ) changes (a summation of condylar growth, glenoid fossa displacement, and condylar position changes within the fossa) were analyzed in 35 Class II, Division 1 malocclusions (23 boys and 12 girls) treated with the Herbst appliance. Lateral head films in habitual occlusion and with the mouth wide open from before (T1) and after 7.5 months of Herbst treatment (T2) as well as 7.5 months (T3) and three years (T4) after treatment were evaluated. As a control group, a sample of 12 untreated male Class II, Division 1 malocclusions was used during a 7.5-month time period corresponding to the treatment period (T2-T1) of the Herbst cases. The results revealed that during the treatment period (T2-T1) condylar growth was directed posteriorly about twice the amount as in the control subjects, and the fossa was displaced in an anterior inferior direction. The effective TMJ changes showed a pattern similar to condylar growth but were more pronounced. During the first posttreatment period (T3-T2), all TMJ changes reverted. The glenoid fossa was displaced backward; the amount of condylar growth and effective TMJ changes was reduced, and the changes were more superiorly directed. During the second posttreatment period (T4-T3), all TMJ changes were considered physiological. Conclusion: During Herbst treatment, the amount and direction of TMJ changes (condylar growth, fossa displacement, and effective TMJ changes) were only temporarily affected favorably by Herbst treatment.

**KEY WORDS:** Dentofacial orthopedics, Condylar growth, Fossa displacement, "Effective", TMJ change.

Accepted: January 2003. Submitted: October 2002

## INTRODUCTION [Return to TOC](#)

In a number of publications<sup>1-13</sup>, the efficiency of the Herbst appliance<sup>14</sup> in the treatment of Class II malocclusions has been verified. Enhancement of mandibular growth<sup>1,15-20</sup> can, to a great extent, explain the treatment success. Three adaptive processes in the temporomandibular joint (TMJ) are thought to be responsible for the increase in mandibular prognathism during treatment: (1) increased condylar growth due to condylar remodeling, (2) anterior glenoid fossa displacement due to fossa remodeling, and (3) anterior positioning of the condyle within the fossa.

In previous Herbst studies, the three TMJ adaptive mechanisms have been analyzed as single factors by the use of profile cephalometric roentgenograms,<sup>1,5,16,18,21</sup> orthopantomograms,<sup>22</sup> computerized tomography scans,<sup>23</sup> bone scintigraphs,<sup>24</sup> and magnetic resonance images (MRI).<sup>19,20</sup> Although condylar and glenoid fossa remodeling were assessed by visual inspection of the roentgenograms and MRIs, the condylar-fossa relationship changes were analyzed metrically on both lateral head films and MRIs. In three recent Herbst studies,<sup>19,20,25</sup> the summation effect of the three TMJ adaptive mechanisms (condylar remodeling, glenoid fossa remodeling, and condylar-fossa relationship changes) was assessed metrically using lateral head films.

However, no Herbst investigation that quantitatively analyzes the different TMJ adaptive processes separately exists. Therefore, the aim of the present cephalometric roentgenographic long-term study in patients treated with the Herbst appliance was to analyze the amount and direction of condylar growth and glenoid fossa displacement as single components as well as the combination effect of the three TMJ adaptive components (condylar growth, fossa displacement, and condylar-fossa relationship changes).

## MATERIALS AND METHODS [Return to TOC](#)

### Herbst group

The original patient material consisted of 118 consecutive Class II, Division 1 malocclusion subjects treated with the Herbst appliance. The Herbst therapy resulted in Class I or overcorrected Class I dental arch relationships in all 118 cases. From this sample, 35 subjects (23 boys and 12 girls) who had complete records available at the following times of examination were selected: before Herbst treatment (T1), after 7.5 months (5-12 months) of Herbst treatment when the appliance was removed (T2), 7.5 months (6-12 months) after treatment when the occlusion had settled<sup>17</sup> (T3), and at follow-up three years (2-4 years) after treatment (T4). No active treatment after Herbst therapy was performed in any of the subjects. Retention after T2 was performed for 1-2 years in 18 subjects using an activator or maxillary plate/mandibular canine to canine retainer. No retention appliances were used in the remaining 17 subjects. The retention/no-retention decision was based on the stability of the occlusion (cuspal interdigitation) at T2. The average age at T1 for the male subjects was 13.2 years (11.5-16.0 years) and that for the female subjects was 12.4 years (11.4-13.9 years). The selected 35 subjects were considered to be representative of the original sample of 118 cases and were not subject to selection bias.

Lateral head films in habitual occlusion and with the mouth wide open (to make the condylar head visible) were evaluated for all subjects at all examination times.

## Control group

A sample of 12 untreated male Class II, Division 1 malocclusions were used as controls.<sup>1</sup> All these subjects had lateral head films both in habitual occlusion and with the mouth wide open at two occasions corresponding to T1 and T2 of the Herbst group. The average age of the control group at T1 was 11.8 years (9.8–13.9 years), and the average observation period (T1-T2) was 7.5 months.

All lateral head films were traced and evaluated by one person (Dr Fischer). Linear measurements were performed with a ruler to the nearest 0.5 mm. The linear roentgenographic enlargement of 7% was not corrected. To reduce the method error in defining the different measuring points and reference structures, all roentgenograms in a series from each patient were traced and evaluated simultaneously.

## Head film superimposition technique

The habitual occlusion head films in a series (T2, T3, and T4) were superimposed on the T1 film. Anterior cranial base and mandibular superimpositions were performed using the method of Björk and Skieller,<sup>26</sup> with stable bone structures used for orientation. The condylar head was identified on the mouth-open radiograph and transferred to the mouth-closed head film after mandibular superimposition of the films.

## Reference grid

A reference line (RL)/reference line perpendicular (RLp) reference grid was defined on the T1 head film and then transferred to the other head films in a series (T2, T3, and T4) after superimposition of the head films on the stable bone structures of the anterior cranial base.<sup>26</sup> The treatment and growth changes of the measuring points (see below) were related to the RL/RLp reference grid. The sagittal (X) and vertical (Y) coordinates of the measuring points were assessed on all films (T1 to T4). The RL and RLp lines were defined as follows:


- RL: a line that connects the incisal edge of the most prominent mandibular central incisor and the distobuccal cusp tip of the first permanent mandibular molar. The line corresponds to the X-axis of the grid.
- RLp: a line perpendicular to RL through the midpoint of the sella tursica. The line corresponds to the Y-axis of the grid.


## Measuring points


Co (anatomic condylar point): the most superior-posterior point of the condylar head in relation to the RL/RLp reference grid. This point was individually defined on each head film in a series (T1 to T4).

Co-A (arbitrary condylar point): an arbitrary point in the area of the condylar head.<sup>27</sup> The point was defined on the T1 head film and transferred to the other head films in a series (T2, T3, and T4) after superimposition of the films on the stable bone structures of the cranial base.<sup>26</sup>

## Measured variables

*Condylar growth.* For its assessment, the radiographs (T1 to T4) were superimposed on the stable bone structures of the mandible.<sup>26</sup> The change of the Co point in relation to its T1 position represents the condylar growth ([Figure 1](#) ) .


*Glenoid fossa displacement.* For its assessment, the method of Buschang and Santos-Pinto<sup>28</sup> was used. The radiographs (T1 to T4) were superimposed on the stable bone structures of cranial base.<sup>26</sup> The change of the Co point in relation to its T1 position represents the fossa displacement ([Figure 2](#) ) . The validity of the method is dependent on an unchanged condyle-fossa relationship at all times of registration (T1 to T4).

*“ Effective” TMJ changes.* For their assessment, the method of Creekmore<sup>27</sup> was used. The Co-A point marked on the T1 radiograph was transferred to the other radiographs (T2, T3, and T4) after superimposition of the films on the stable bone structures of the cranial base.<sup>26</sup> Thereafter, the radiographs T2, T3, and T4 were superimposed on the T1 film using the stable bone structures of the mandible.<sup>26</sup> The change of the Co-A point in relation to its T1 position represents the effective TMJ changes<sup>27</sup> ([Figure 3](#) ) that are the sum of (1) condylar growth, (2) glenoid fossa displacement, and (3) condylar displacement in the fossa.

## Statistical methods

The mean and standard deviation (SD) were calculated for each variable. Despite the relatively small sample size, the different variables were considered normally distributed (coincidence of the median and mean values). Therefore, Student's *t*-test for paired samples was used to assess the significance of changes during different examination periods. Student's *t*-test for unpaired samples was used to assess the significance of the differences between the Herbst and the control groups and between the male-female groups. The significance levels used were  $P < .001$ ,  $P < .01$ , and  $P < .05$ . A  $P \geq .05$  value was considered not significant (ns). All calculations were performed with Microsoft Excel software.

## Method error

The size of the combined method error (ME) in locating the reference points, superimposing the radiographs, and measuring the position of the variables in relation to the RL/RLp grid at the different times of examination was assessed in 20 randomly selected Herbst cases on double registrations. The formula of Dahlberg<sup>29</sup> was used in the calculations:  $ME = ((\sum d^2)/2n)^{1/2}$  where  $d$  is the difference between two registrations of a pair and  $n$  is the number of double registrations. The results of the method error calculations are shown in [Table 1](#)  .


## RESULTS [Return to TOC](#)

No differences existed between the 18 retention and 17 no-retention cases at any time of examination. Therefore, the two groups were pooled in the presentation of the results.

### Condylar growth ([Figure 4](#) ; [Tables 2 through 5](#) )

Condylar growth was expressed as a positional change of the Co point using a mandibular base superimposition of the head films.

*Treatment period (T2-T1) changes.* For the total Herbst sample (boys and girls), condylar growth was directed posteriorly (mean = 1.8 mm;  $P < .001$ ) and superiorly (mean = 2.9 mm;  $P < .001$ ). The condylar growth in the male sample was larger than that in the female sample. This was true for both posterior (mean = 1.0 mm;  $P < .001$ ) and superior (mean = 0.5 mm;  $P < .001$ ) growth directions. In comparison with the male control group, the growth changes in the male Herbst group were significantly ( $P < .001$ ) larger. The group differences were more pronounced for sagittal (mean = 1.0 mm) than for vertical (mean = 0.5 mm) condylar growth.

*Posttreatment period (T3-T2 and T4-T3) changes.* For the total Herbst sample (boys and girls), condylar growth during the posttreatment periods (T3-T2 and T4-T3) was more vertically oriented than during the treatment period (T2-T1). During the first posttreatment period (T3-T2), the amount of growth was reduced in relation to that during the treatment period. Female subjects exhibited less posttreatment growth than did male subjects ([Figure 2](#) ).

Fossa displacement was assessed as a positional change of the Co point using a cranial base superimposition of the head films.

*Treatment period (T2-T1) changes.* For the total Herbst sample (boys and girls), the fossa was displaced anteriorly (mean = 0.4 mm;  $P < .001$ ) and inferiorly (mean = 0.9 mm;  $P < .001$ ) during treatment. Inferior fossa displacement in the male sample was larger (mean = 1.2 mm;  $P < .001$ ) than that in the female sample. In the male control group, the fossa was displaced insignificantly in a posterior and superior direction.

*Posttreatment period (T3-T2 and T4-T3) changes.* For the total Herbst sample (boys and girls), the fossa was significantly ( $P < .001$ ) displaced posteriorly during the two posttreatment periods. Insignificant vertical changes occurred. During the first posttreatment period (T3-T2), the male subjects exhibited larger (mean = 0.6 mm;  $P < .01$ ) sagittal changes than did female subjects. During the second posttreatment period (T4-T3), the female subjects exhibited larger (mean = 0.4 mm;  $P < .05$ ) sagittal changes than did male subjects.

### Effective TMJ changes (Figure 6; Tables 2 through 5)

As an expression of the sum of (1) condylar growth, (2) glenoid fossa displacement, and (3) condylar displacement in the fossa, the position change of the Co-A point was assessed using a mandibular base superimposition of the head films.

*Treatment (T2-T1) and posttreatment (T3-T2 and T4-T3) period changes.* For the total Herbst sample (boys and girls) as well as for the boys and girls separately, the pattern of effective TMJ changes during treatment and after treatment was similar to that of condylar growth. However, in relation to condylar growth, the effective TMJ changes were larger (mainly in male subjects) and more vertically directed. The latter was especially true during the two posttreatment periods (T3-T2 and T4-T3).

## DISCUSSION [Return to TOC](#)

This study aimed at assessing the long-term effects of continuous (24 hours/day) mandibular protrusion during a fixed time period (7.5 months) on TMJ growth. This was done using the Herbst appliance,<sup>14</sup> which is fixed to the teeth and therefore the cooperation of the patient is not necessary for its correct functioning, making it advantageous for research purposes. Furthermore, the subject material was sufficiently large ( $n = 35$ ) for statistical analyses. All cases had the same type of malocclusion (Class II, Division 1) and were treated by the same person (Dr Pancherz). Finally, a control group of untreated Class II, Division 1 malocclusions was available for the treatment period (T2-T1) evaluation.

In interpreting the present findings, it must be remembered that anteriorly directed glenoid fossa displacement changes and posteriorly directed condylar growth and effective TMJ changes are favorable in the treatment of Class II malocclusions. These changes contribute to increasing mandibular forward positioning. Posteriorly directed fossa changes and anteriorly directed condylar growth and effective TMJ changes are, on the other hand, unfavorable. These changes contribute to decreasing mandibular forward positioning. Vertical TMJ changes (affecting mandibular growth rotation) only indirectly contribute to the outcome of Class II treatments.<sup>25</sup> In a later report, the influence of the separate TMJ changes on mandibular growth rotation as well as on the position of the chin will be considered.

Methodologically, the largest problem was the analysis of glenoid fossa displacement. The prerequisite for the validity of the method of Buschang and Santos-Pinto<sup>28</sup> is an unchanged condyle-fossa relationship at all times of examination. If a change in condyle position (not ascertainable by roentgenographic cephalometry) occurs, this will misleadingly be appraised as fossa displacement. However, Ruf and Pancherz,<sup>19</sup> using MRIs of the TMJ, showed that Herbst therapy had an unaffected average condyle-fossa relationship, ie, the condyle had the same centered position before and after Herbst treatment. Furthermore, by the method of lateral TMJ tomography, Hansen et al<sup>30</sup> proved a normal centered position of the condyle in relation to the fossa in Herbst patients who were followed up for 7.5 years after treatment.

An anatomic condylar point was used for the analysis of condylar growth. As the condylar head is difficult/impossible to identify on the mouth-closed head films, mouth-open head films were used as well to see the condyle and then to transfer its contour to the mouth-closed films after mandibular superimposition of the films. The point Ar (articulare)<sup>31</sup> has been proposed as an alternative to an anatomic condylar point.<sup>28,32,33</sup> However, the position of the Ar point is affected by growth changes in the skull and is thus not suitable for longitudinal growth studies.<sup>34</sup>

To circumvent the problem of defining reliable measuring points for the assessment of condyle and fossa changes the effective TMJ changes<sup>27</sup> were also evaluated. By the use of an arbitrary condylar point (Co-A) and two techniques of head film superimposition, it was possible to assess the sum of condylar growth and fossa displacement changes as well as the unknown factor of condylar positional change within the fossa.

### Condylar growth

In the T2-T1 period of 7.5 months, an increased amount of condylar growth occurred in a posterior-superior direction in the Herbst group.<sup>18-20</sup> In the untreated male control group, on the other hand, condylar growth was predominantly vertically upward directed, and the amount of growth was significantly smaller than in the male Herbst subjects.

In the first posttreatment period (T3-T2) of 7.5 months, the condylar growth amount was reduced in relation to the treatment period, and the growth direction became more vertically upward (male subjects).<sup>18,21</sup> These changes could be described as "recovery" after Herbst therapy.<sup>21</sup>

In the second posttreatment period (T4-T3), the more vertically upward-directed condylar growth seen during the T3-T2 period was maintained. The amount and direction of the growth seemed to correspond to that of normal growth.<sup>28</sup>

Condylar growth changes during the different periods of examination were larger in male subjects than in female subjects. Again, this could be explained by the male-female differences in growth potential. Thus, Herbst treatment temporarily stimulates condylar growth and directs it posteriorly.

### Glenoid fossa displacement

Physiologically the fossa is displaced in a posterior and inferior direction during growth development.<sup>28,35</sup> During Herbst treatments of 7.5 months (T2-T1), the Co measuring point, however, was displaced in an anterior and inferior direction. This is most likely due to an anterior displacement of the fossa as a reaction to the Herbst therapy. The remodeling processes at the posterior fossa wall, histologically seen in mandibular protrusion experiments in animals<sup>36-42</sup> and by MR imaging in Herbst patients,<sup>19,20</sup> confirm this assumption. However, as mentioned before, the possibility of a change in condylar position within the fossa could misleadingly be appraised as a fossa displacement.

The female subjects, in comparison with the male subjects, exhibited significantly less downward movement of the Co point. As a gender-independent reaction in Co point displacement during Herbst treatment would be expected, the female-male difference found indicates a fossa growth displacement and not a condyle-fossa relationship change because the growth potential in female subjects is less than that in male subjects.<sup>43,44</sup>

In the first (T3-T2) and second (T4-T3) posttreatment periods, the Co point movement reverted to a posterior direction. Again, the Co point changes were less in female subjects than in male subjects. This was especially true during the first posttreatment period (T3-T2). Also, in this study, the male-female difference could be explained by the relatively smaller growth potential in the female subjects.

When looking at the total observation period (T4-T1), the Co point moved in a posterior and inferior direction, corresponding to normal growth displacement of the fossa.<sup>28,35</sup>

It thus seems as if the Herbst appliance has only a temporary effect on physiologic posterior glenoid fossa growth displacement in the anterior direction.

### Effective TMJ changes

As mentioned previously, the change in the Co-A point reflects the sum of the three possible TMJ changes (condylar growth, glenoid fossa displacement, and condylar position change within the fossa) occurring during and after Herbst treatment. The pattern of effective TMJ changes was comparable with that of condylar growth. This was true for both male and female subjects. However, during the treatment period (T2-T1), the amount of effective TMJ changes was larger than that of condylar growth, whereas their growth directions were comparable (Figures 7 and 8). Furthermore, during the first (T3-T2) and second (T4-T3) posttreatment periods, the change in growth direction to a more vertical pattern was more pronounced for the effective TMJ changes (Figure 6) than for condylar growth (Figure 4). On the other hand, with respect to the amount of posttreatment changes, comparable results were found for effective TMJ changes and condylar growth.

The opposing glenoid fossa displacement changes during and after Herbst therapy (Figure 5) can explain the difference in the amount and direction of changes when comparing the effective TMJ changes and the condylar growth changes (Figures 7 and 8). Anterior fossa displacement changes during Herbst treatment (T2-T1) are added to sagittal condylar growth changes. Posterior fossa displacement changes during the posttreatment periods (T3-T2 and T4-T3) are subtracted from the sagittal condylar growth changes.

Thus, the effective TMJ changes mainly reflect the changes in condylar growth. However, fossa displacement changes (and possible condyle-fossa relationship changes) during and after Herbst treatment will affect the amount and direction of the effective TMJ changes.

### CONCLUSIONS [Return to TOC](#)

The amount and direction of TMJ changes (condylar growth, glenoid fossa displacement, and effective TMJ changes) were affected favorably, although only temporarily, in an anterior direction by Herbst treatment.

### REFERENCES [Return to TOC](#)

1. Pancherz H. Treatment of Class II malocclusions by jumping the bite with the Herbst appliance. A cephalometric investigation. *Am J Orthod.* 1979; 76:423–442. [\[PubMed Citation\]](#)
2. Pancherz H. The Herbst appliance—its biologic effects and clinical use. *Am J Orthod.* 1985; 87:1–20. [\[PubMed Citation\]](#)
3. Pancherz H. The modern Herbst appliance. In: Graber ThM, Rakosi Th, Petrovic AG, eds. *Dentofacial Orthopedics With Functional Appliances.* 2nd ed. St Louis, Mo: Mosby; 1997:336–366.
4. Pancherz H. The effects, limitations, and long-term dentofacial adaptations to treatment with the Herbst appliance. *Semin Orthod.* 1997; 3:232–243.
5. Wieslander L. Intensive treatment of severe Class II malocclusions with a headgear-Herbst appliance in the early mixed dentition. *Am J Orthod.* 1984; 86:1–13. [\[PubMed Citation\]](#)
6. Valant JR, Sinclair PM. Treatment effects of the Herbst appliance. *Am J Orthod Dentofacial Orthop.* 1989; 95:138–147. [\[PubMed Citation\]](#)
7. Pancherz H, Anehus-Pancherz M. The head-gear effect of the Herbst appliance. A cephalometric long-term study. *Am J Orthod Dentofacial Orthop.* 1993; 103:510–520. [\[PubMed Citation\]](#)
8. Windmiller EC. The acrylic-splint Herbst appliance: a cephalometric evaluation. *Am J Orthod Dentofacial Orthop.* 1993; 104:73–84. [\[PubMed Citation\]](#)
9. Croft RS, Buschang PH, English JD, Meyer R. A cephalometric and tomographic evaluation of Herbst treatment in the mixed dentition. *Am J Orthod Dentofacial Orthop.* 1999; 116:435–443. [\[PubMed Citation\]](#)
10. Franchi L, Baccetti T, McNamara JA. Treatment and posttreatment effects of acrylic splint Herbst appliance therapy. *Am J Orthod Dentofacial Orthop.* 1999; 115:429–438. [\[PubMed Citation\]](#)
11. Pancherz H, Ruf S. The Herbst appliance: research based updated clinical possibilities. *World J Orthod.* 2000; 1:17–31.
12. Du X, Hägg U, Rabie ABM. Effects of headgear Herbst and mandibular step-by-step advancement versus conventional Herbst appliance and maximal jumping of the mandible. *Eur J Orthod.* 2002; 24:167–174. [\[PubMed Citation\]](#)
13. von Bremen J, Pancherz H. Efficiency of early and late Class II Division 1 treatment. *Am J Orthod Dentofacial Orthop.* 2002; 121:31–37. [\[PubMed Citation\]](#)
14. Herbst E. *Atlas und Grundriss der Zahnärztlichen Orthopädie.* München: JF Lehmann; 1910. pp 371–375.
15. Pancherz H. The mechanism of Class II correction in Herbst appliance treatment. A cephalometric investigation. *Am J Orthod.* 1982; 82:104–113. [\[PubMed Citation\]](#)
16. Pancherz H, Hägg U. Dentofacial orthopaedics in relation to somatic maturation. An analysis of 70 consecutive cases treated with the Herbst appliance. *Am J Orthod.* 1985; 88:273–287. [\[PubMed Citation\]](#)
17. Pancherz H, Hansen K. Occlusal changes during and after Herbst treatment: a cephalometric investigation. *Eur J Orthod.* 1986; 8:215–228. [\[PubMed Citation\]](#)
18. Pancherz H, Littmann C. Morphologie und Lage des Unterkiefers bei der Herbst Behandlung. Eine kephalometrische Analyse der Veränderungen bis zum Wachstumsabschluss. *Inf Orthod Orthop.* 1989; 21:493–513.
19. Ruf S, Pancherz H. Temporomandibular joint growth adaptation in Herbst treatment: a prospective magnetic resonance imaging and cephalometric roentgenographic study. *Eur J Orthod.* 1998; 20:375–388. [\[PubMed Citation\]](#)
20. Ruf S, Pancherz H. Temporomandibular joint remodeling in adolescents and young adults during Herbst treatment: a prospective longitudinal magnetic resonance imaging and cephalometric radiographic investigation. *Am J Orthod Dentofacial Orthop.* 1999; 115:607–618. [\[PubMed Citation\]](#)
21. Pancherz H. The effect of continuous bite jumping with the Herbst appliance on the dentofacial complex: a follow-up study after Herbst appliance treatment of Class II malocclusions. *Eur J Orthod.* 1981; 3:49–60. [\[PubMed Citation\]](#)
22. Paulsen HU. Changes of the condyles of 100 patients treated with the Herbst appliance from puberty to adulthood: a long-term radiographic study. *Eur J Orthod.* 1997; 19:657–668. [\[PubMed Citation\]](#)
23. Paulsen HU, Karle A, Bakke M, Herskind A. A CT-scanning and radiographic analysis of temporomandibular joints and cephalometric analysis in a case of Herbst treatment in late puberty. *Eur J Orthod.* 1995; 17:165–167. [\[PubMed Citation\]](#)

24. Paulsen HU, Rabol A, Sorensen S. Bone scintigraphy of human temporomandibular joints during Herbst treatment: a case report. *Eur J Orthod.* 1988; 20:369–374.

25. Pancherz H, Ruf S, Kohlhas P. “Effective condylar growth” and chin position changes in Herbst treatment: a cephalometric roentgenographic long-term study. *Am J Orthod Dentofacial Orthop.* 1998; 114:437–446. [[PubMed Citation](#)]

26. Björk A, Skieller V. Normal and abnormal growth of the mandible. A synthesis of longitudinal cephalometric implant studies over a period of 25 years. *Eur J Orthod.* 1983; 5:1–46. [[PubMed Citation](#)]

27. Creekmore TD. Inhibition or stimulation of the vertical growth of the facial complex—its significance to treatment. *Angle Orthod.* 1967; 37:285–297. [[PubMed Citation](#)]

28. Buschang PH, Santos-Pinto A. Condylar growth and glenoid fossa displacement during childhood and adolescence. *Am J Orthod Dentofacial Orthop.* 1998; 113:437–442. [[PubMed Citation](#)]

29. Dahlberg G. *Statistical Methods for Medical and Biological Students.* New York, NY: Interscience Publication; 1940.

30. Hansen K, Pancherz H, Petersson A. Long-term effects of the Herbst appliance on the craniomandibular system with special reference to the TMJ. *Eur J Orthod.* 1990; 12:244–253. [[PubMed Citation](#)]

31. Björk A. The face in profile. An anthropological X-ray investigation on Swedish children and conscripts. *Swed Dental J.* 1947; 40:1–180.

32. Isaacson RJ, Zapfel RJ, Worms FW, Bevis RR, Speidel TM. Some effects of mandibular growth on the dental occlusion and profile. *Angle Orthod.* 1977; 47:97–106. [[PubMed Citation](#)]

33. Williams S, Melsen B. Condylar development and mandibular rotation and displacement during activator treatment. *Am J Orthod.* 1982; 81:322–326. [[PubMed Citation](#)]

34. Stickel A, Pancherz H. Can “articulare” be used in the cephalometric analysis of mandibular length?. *Eur J Orthod.* 1988; 10:362–368. [[PubMed Citation](#)]

35. Björk A, Skieller V. Facial development and tooth eruption. An implant study at the age of puberty. *Am J Orthod.* 1972; 62:339–383. [[PubMed Citation](#)]

36. Breitner C. Experimentelle Veränderungen der mesiodistalen Beziehungen der oberen und unteren Zahnreihen. *Zschr Stomatol.* 1930; 28:620–635.

37. Stöckli PW, Willert HG. Tissue reactions in the temporomandibular joint resulting from anterior displacement of the mandible in the monkey. *Am J Orthod.* 1971; 60:142–155. [[PubMed Citation](#)]

38. Woodside DG, Metaxas A, Altuna G. The influence of functional appliance therapy on glenoid fossa remodeling. *Am J Orthod Dentofacial Orthop.* 1987; 92:181–198. [[PubMed Citation](#)]

39. Rabie ABM, Zhao Z, Shen G, Hägg U, Robinson W. Osteogenesis in the glenoid fossa in response to mandibular advancement. *Am J Orthod Dentofacial Orthop.* 2001; 119:390–400. [[PubMed Citation](#)]

40. Rabie ABM, Chayanupatkul A, Hägg U. Stepwise advancement using functional appliances. Experimental perspectives. *Semin Orthod.* 2003; 9:41–46.

41. Peterson JE, McNamara JA. Temporomandibular joint adaptation associated with Herbst appliance treatment in juvenile rhesus monkeys (*Macaca mulatta*). *Semin Orthod.* 2003; 9:12–25.

42. McNamara JA, Peterson JE, Pancherz H. Histologic changes associated with the Herbst appliance in adult rhesus monkeys (*Macaca mulatta*). *Semin Orthod.* 2003; 9:26–40.

43. Björk A, Helm S. Prediction of the age of maximum pubertal growth in body height. *Angle Orthod.* 1967; 37:134–143. [[PubMed Citation](#)]

44. Taranger J, Hägg U. The timing and duration of adolescent growth. *Acta Odontol Scand.* 1980; 38:57–67. [[PubMed Citation](#)]

TABLES [Return to TOC](#)

**TABLE 1.** Assessment of the Combined Method Error in Locating the Measuring Points, Superimposing the Head Films, and Measuring the Changes of the Variables in Relation to the Before Treatment (T1) Findings. Double Registrations in 20 Herbst Subjects at T2 (after treatment), T3 (7.5 Months After Treatment), and T4 (Three Years After Treatment)<sup>a</sup>

Variable (mm)	Time of Registration		
	T2	T3	T4
Anatomic condyle position—sagittal [MB] Co/RLp	0.47	0.67	0.55
Anatomic condyle position—vertical [MB] Co/RL	0.38	1.22	0.49
Fossa position—sagittal [CB] Co/RLp	0.36	0.47	0.41
Fossa position—vertical [CB] Co/RL	0.45	0.47	0.39
Arbitrary condyle position—sagittal [MB] Co-A/RLp	0.56	0.32	0.45
Arbitrary condyle position—vertical [MB] Co-A/RL	0.41	0.51	0.43

<sup>a</sup> [CB] indicates cranial base superimposition; [MB] = mandibular base superimposition.

**TABLE 2.** Changes of the Cephalometric Variables in 35 Herbst Subjects (23 boys and 12 girls) During Different Examination Periods: T2-T1 (Treatment Period), T3-T2 (First Posttreatment Period), T4-T3 (Second Posttreatment Period), and T4-T1 (Total Observation Period)<sup>a</sup>

Variable (mm)	Group	T2-T1		T3-T2		T4-T3		T4-T1	
		Mean (d)	Significance <sup>b</sup>	Mean (d)	Significance	Mean (d)	Significance	Mean (d)	Significance
Condylar growth—sagittal [MB] Co/RLp	m	+2.2	***	+0.9	***	+2.3	***	+5.4	***
	f	+1.2	***	+0.5	**	+0.6	**	+2.3	***
	m+f	+1.8	***	+0.8	***	+1.7	***	+4.3	***
Condylar growth—vertical [MB] Co/RL	m	+3.1	***	+2.5	***	+5.7	***	+11.3	***
	f	+2.6	***	+0.9	**	+2.5	***	+0.6	***
	m+f	+2.9	***	+1.9	***	+4.6	***	+9.4	***
Fossa displacement—sagittal [CB] Co/RLp	m	-0.4	***	+1.2	***	+0.8	***	+1.6	***
	f	-0.3	**	+0.6	***	+0.7	***	+1.0	***
	m+f	-0.4	***	+1.0	***	+0.8	***	+1.4	***
Fossa displacement—vertical [CB] Co/RL	m	-1.3	***	+0.0	ns	-0.1	ns	-1.4	***
	f	-0.1	ns	-0.1	ns	+0.3	***	+0.1	ns
	m+f	-0.9	***	+0.0	ns	+0.1	ns	-0.8	***
Effective TMJ changes—sagittal [MB] Co-A/RLp	m	+2.7	***	-0.2	***	+1.4	***	+3.9	***
	f	+1.5	***	+0.0	ns	-0.1	ns	+1.4	***
	m+f	+2.2	***	-0.1	***	+0.9	***	+3.0	***
Effective TMJ changes—vertical [MB] Co-A/RL	m	+4.5	***	+2.2	***	+5.6	***	+12.3	***
	f	+2.8	***	+1.0	***	+2.0	***	+5.8	***
	m+f	+3.9	***	+1.9	***	+4.3	***	+10.1	***

<sup>a</sup> [MB] indicates mandibular base superimposition; [CB] = cranial base superimposition; plus (+) = posterior/superior condylar growth, fossa displacement, or effective TMJ change; minus (-) = anterior/inferior condylar growth, fossa displacement, or effective TMJ change.

<sup>b</sup> \*\*\*  $P < .001$ ; \*\*  $P < .01$ ; ns  $P \geq .05$ .

**TABLE 3.** Comparison of 35 Herbst Subjects (23 boys and 12 girls) During Different Examination Periods: T2-T1 (Treatment Period), T3-T2 (First Posttreatment Period), T4-T3 (Second Posttreatment Period), and T4-T1 (Total Observation Period)<sup>a</sup>

Variable (mm)	m-f							
	T2-T1		T3-T2		T4-T3		T4-T1	
	Mean (d)	Significance <sup>b</sup>	Mean (d)	Significance	Mean (d)	Significance	Mean (d)	Significance
Condylar growth—sagittal [MB] Co/RLp	1.0 (a)	***	0.4 (a)	ns	1.7 (a)	***	3.1 (a)	***
Condylar growth—vertical [MB] Co/RL	0.5 (a)	***	1.6 (a)	***	3.2 (a)	***	5.3 (a)	***
Fossa displacement—sagittal [CB] Co/RLp	0.1 (a)	ns	0.6 (a)	**	0.1 (a)	ns	0.6 (a)	*
Fossa displacement—vertical [CB] Co/RL	1.2 (a)	***	0.1 (b)	ns	0.4 (b)	*	1.5 (a)	***
Effective TMJ changes—sagittal [MB] Co-A/RLp	1.2 (a)	***	0.2 (a)	ns	1.5 (a)	***	2.5 (a)	***
Effective TMJ changes—vertical [MB] Co-A/RL	1.7 (a)	***	1.2 (a)	***	3.6 (a)	***	6.5 (a)	***

<sup>a</sup> [MB] indicates mandibular base superimposition; [CB] = cranial base superimposition; (a) = larger changes in male subjects; (b) = larger changes in female subjects.

<sup>b</sup> \*\*\*  $P < .001$ ; \*\*  $P < .01$ ; \*  $P < .05$ ; ns  $P \geq .05$ .

**TABLE 4.** Changes of the Cephalometric Variables in 12 Untreated Boys (Control Subjects) During Examination Period T2-T1 (Corresponding to the Treatment Period of the Herbst Subjects)<sup>a</sup>

Variable (mm)	T2-T1		
	Mean (d)	SD (d)	Significance <sup>b</sup>
Condylar growth—sagittal [MB] Co/RLp	+0.1	0.55	ns
Condylar growth—vertical [MB] Co/RL	+1.6	0.10	***
Fossa displacement—sagittal [CB] Co/RLp	+0.2	0.48	ns
Fossa displacement—vertical [CB] Co/RL	+0.1	0.40	ns
Effective TMJ changes—sagittal [MB] Co-A/RLp	+0.2	0.03	***
Effective TMJ changes—vertical [MB] Co-A/RL	+1.3	0.40	***

<sup>a</sup> [MB] indicates mandibular base superimposition; [CB] = cranial base superimposition; plus (+) = posterior/superior condylar growth, fossa displacement, or effective TMJ change.

<sup>b</sup> \*\*\*  $P < .001$ ; ns  $P \geq .05$ .

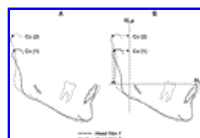
**TABLE 5.** Changes of Cephalometric Variables During Examination Period T2-T1. Comparison of 35 Herbst (23 boys and 12 girls)<sup>a</sup>

Variable (mm)		T2-T1		
		Mean (d)	SD (d)	Significance <sup>b</sup>
Condylar growth—sagittal [MB] Co/RLp	H-C	2.1 (a)	0.47	***
Condylar growth—vertical [MB] Co/RL	H-C	1.5 (a)	0.34	***
Fossa displacement—sagittal [CB] Co/RLp	H-C	0.6 (a)	0.39	***
Fossa displacement—vertical [CB] Co/RL	H-C	1.4 (a)	0.55	***
Effective TMJ changes—sagittal [MB] Co/A-RLp	H-C	2.5 (a)	0.19	***
Effective TMJ changes—vertical [MB] Co-A/RL	H-C	3.2 (a)	0.70	***

<sup>a</sup> [MB] indicates mandibular base superimposition; [CB] = cranial base superimposition; (a) = larger changes in Herbst subjects than in control subjects.

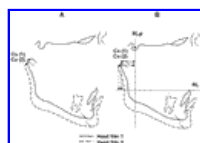
<sup>b</sup> Level of significance: \*\*\*  $P < .001$ .

FIGURES [Return to TOC](#)



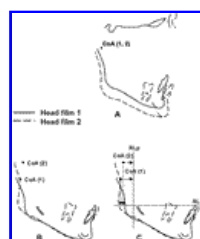
[Click on thumbnail for full-sized image.](#)

**FIGURE 1.** Method for the assessment of condylar growth (Co). (A) Mandibular base superimposition. (B) Measurement of condylar growth (Co point changes) in relation to the RL/RLp reference grid




[Click on thumbnail for full-sized image.](#)

**FIGURE 2.** Method for the assessment of glenoid fossa displacement (Co). (A) Cranial base superimposition. (B) Measurement of fossa displacement (Co point changes) in relation to the RL/RLp reference grid




[Click on thumbnail for full-sized image.](#)

**FIGURE 3.** Method for the assessment of effective TMJ changes. (A) Arbitrary point Co-A in the area of condylar head marked on head film 1 and then transferred to head film 2 after cranial base superimposition of the head films. (B) Mandibular base superimposition. (C) Measurement of effective TMJ changes (Co-A point changes) in relation to the RL/RLp reference grid




[Click on thumbnail for full-sized image.](#)

**FIGURE 4.** Average condylar growth (Co point changes) in 23 male and 12 female Herbst subjects and 12 male control subjects. T1, before Herbst treatment; T2, after 7.5 months of Herbst treatment; T3, 7.5 months after treatment; T4, three years after treatment




[Click on thumbnail for full-sized image.](#)

**FIGURE 5.** Average glenoid fossa displacement (Co point changes) in 23 male and 12 female Herbst subjects and 12 male control subjects. T1, before Herbst treatment; T2, after 7.5 months of Herbst treatment; T3, 7.5 months after treatment; T4, three years after treatment




Click on thumbnail for full-sized image.

**FIGURE 6.** Average effective TMJ changes in 23 male and 12 female Herbst subjects and 12 male control subjects. T1, before Herbst treatment; T2, after 7.5 months of Herbst treatment; T3, 7.5 months after treatment; T4, three years after treatment



Click on thumbnail for full-sized image.

**FIGURE 7.** Average condylar growth and effective TMJ changes in 23 male Herbst subjects. T1, before Herbst treatment; T2, after 7.5 months of Herbst treatment; T3, 7.5 months after treatment; T4, three years after treatment



Click on thumbnail for full-sized image.

**FIGURE 8.** Average condylar growth and effective TMJ changes in 12 female Herbst subjects. T1, before Herbst treatment; T2, after 7.5 months of Herbst treatment; T3, 7.5 months after treatment; T4, three years after treatment

<sup>a</sup>Professor and Chairman, Department of Orthodontics, School of Dentistry, University of Giessen, Germany

<sup>b</sup>Doctoral Student, Department of Orthodontics, School of Dentistry, University of Giessen, Germany

Corresponding author: Hans Pancherz, DDS, Odont Dr, FCDSHK (Hon), Department of Orthodontics, School of Dentistry, University of Giessen, Schlangenzahl 14, D-35392 Giessen, Germany (E-mail: [hans.pancherz@dentist.med.uni-giessen.de](mailto:hans.pancherz@dentist.med.uni-giessen.de))