

[\[Print Version\]](#)

[\[PubMed Citation\]](#) [\[Related Articles in PubMed\]](#)

## TABLE OF CONTENTS

[\[INTRODUCTION\]](#) [\[MATERIALS AND...\]](#) [\[RESULTS\]](#) [\[DISCUSSION\]](#) [\[REFERENCES\]](#) [\[TABLES\]](#) [\[FIGURES\]](#)

*The Angle Orthodontist*: Vol. 73, No. 5, pp. 539-544.

# Three-Dimensional Analysis of Dental Casts Based on a Newly Defined Palatal Reference Plane

Kazuo Hayashi, DDS, PhD;<sup>a</sup> Jun Uechi, DDS;<sup>a</sup> Itaru Mizoguchi, DDS, PhD<sup>a</sup>

## ABSTRACT

The purpose of this study was to establish a new method for orthodontic diagnosis that integrates the three-dimensional (3-D) shape of a dental cast and the craniofacial morphology using a newly defined palatal reference plane. We also measured the accuracy of this new palatal reference plane as a reference for measurement and its spatial relationship to the framework of the craniofacial skeleton using lateral and frontal cephalometric radiography and maxillary dental casts, which were transferred using an anatomical face-bow. Eighteen female subjects were included in this study. The new reference plane in dental cast analysis corresponded to the A-PNS plane in the lateral view and to the J-J' plane in the frontal view, which have been shown to be sufficiently accurate as a reference for measurement. These results indicate that the application of this palatal reference plane, as a reference structure, should provide accurate and abundant 3-D data concerning malocclusion.

**KEY WORDS:** Dental cast, Three-dimensional surface scanning, New palatal reference plane.

Accepted: November 2002. Submitted: June 2002

## INTRODUCTION [Return to TOC](#)

In orthodontic treatment, a wealth of information obtained from dental casts plays a significant role in diagnosis, treatment planning, and evaluation.<sup>1-4</sup> To diagnose occlusion in the craniofacial skeleton, Simon<sup>5</sup> devised a gnathostatic model that reproduces the Frankfort plane, orbital plane, and sagittal plane on a dental cast. The decision regarding whether tooth extraction should be performed is based on an analysis similar to those described by Jarabak et al,<sup>6</sup> Tweed,<sup>7</sup> and Steiner.<sup>8</sup> The data needed for such an analysis are obtained by measuring a dental cast. This measurement is most frequently carried out using calipers and a ruler, which allow one- and two-dimensional measurements. Recently, a more accurate quantification of dental cast information has become possible as a result of advances in the application of three-dimensional (3-D) measuring devices to dentistry.<sup>9</sup> Motohashi and Kuroda<sup>10</sup> simulated orthognathic surgery on digital images based on 3-D information from dental casts. Furthermore, Yamamoto et al<sup>3</sup> evaluated the distal driving behavior of the canine using 3-D information.

In morphological research on facial asymmetry, the relationship between skeletal mandibular deviation and dental arch asymmetry has been evaluated by dental cast analysis.<sup>11,12</sup> Klami and Horowitz<sup>13</sup> clarified the relationship between lateral crossbite and the palate

contour. However, many previous studies used an occlusal plane as a measurement reference in dental cast analysis.<sup>14,15</sup> The skeletal and dental information obtained from cephalometric and dental cast analysis has been isolated because there is as yet no clear standard to integrate this information. Although the transfer of a maxillary cast to an articulator using a face-bow gives a reliable estimation of the distance between the dentition and axis-orbitale plane,<sup>16–18</sup> another reference is needed to estimate the positional relation between the dentition and maxillary corpus.

The purpose of this study was to establish a new method for orthodontic diagnosis that integrates the 3-D shape of a dental cast and the craniofacial morphology using a new palatal reference plane. In addition, we measured the accuracy of this palatal reference plane as a reference for measurement and its spatial relationship to the framework of the craniofacial skeleton using lateral and frontal cephalometric radiography and 3-D shape data from a maxillary dental cast, which were transferred using an anatomical face-bow.

## MATERIALS AND METHODS [Return to TOC](#)

### Sample



Eighteen women who were studying dental hygiene at a school attached to the Health Sciences University of Hokkaido volunteered for this study. They had malocclusion for which orthodontic treatment was necessary. All the subjects were informed of the experimental protocols and signed an informed consent form that was previously approved by the Institutional Review Board. The subjects' rights were protected at all times. Lateral and frontal cephalometric radiographs were taken after all the subjects had given their informed consent. Impressions for dental cast models were taken using alginate, which was poured with a die stone. Maxillary casts were mounted on a SAM articulator (SAM3, SAM, Munchen, Germany) using the SAM face-bow recording and SAM axiosplit system. This face-bow is used assuming that the orbitale is located 25 mm downward from the nasion and that the anatomical mean value for the orbitale, external auditory meatus (center of the face-bow ear rods), and hinge-axis are in the same plane (axis-orbitale plane).

### Cephalometric analysis


The cephalometric radiographs were scanned using a flat-head scanner (GT-9000, Epson, Tokyo, Japan), and landmark identification was performed directly on digital images using image-analysis software (NIH Image; developed at the US National Institutes of Health). The measurement error was checked on digital images by repeating the identification of all landmarks. Calculations were made for x- and y-coordinates separately using the formula


$$\text{error} = (\sum d^2 / 2n)^{1/2}.$$


The error was within 0.08 mm for x-coordinates and within 0.07 mm for y-coordinates.

Landmarks and planes in a lateral cephalometric radiograph are shown in [Figure 1a](#) . Because the axis-orbitale plane in a SAM articulator passes through the center of the face-bow ear rods, in the cephalometric analysis, the plane made by the orbitale and center of the ear rods was used as the axis-orbitale plane. The angles between the axis-orbitale plane and the ANS-PNS plane, A-PNS plane, and UIE-UMT plane (maxillary occlusal plane) were then measured. Landmarks and planes in frontal cephalometric radiography are shown in [Figure 1b](#) . The angle between the axis-orbitale plane and the J-J' plane was measured.

### 3-D surface scanning of dental casts

A 3-D surface-scanning system using a slit laser beam (VMS-150RD, UNISN, Osaka, Japan) was used to measure dental casts. The system consisted of a slit laser projector, two charge-coupled device cameras, an autorotating mounting unit, and a personal computer with postprocessing software ([Figure 2a](#) ). We previously reported the accuracy of this measuring device<sup>19</sup> and provide a summary in the Discussion section. The resolution in the x-direction was 0.01 mm, and the z-direction could be measured to within  $\pm 0.05$  mm. A 3-D shape data-analysis system, which consisted of a graphical workstation (Zx1, Intergraph, Huntsville, Ala) and data-processing and data-analyzing software (I-DEAS, SDRC, Milford, OH), was used.

The dental casts were positioned using the SAM axiosplit system on the x-y table that paralleled the x-y plane in the measuring device ([Figure 2a](#) ). Because the base plane of the SAM axiosplit exists on the axis-orbitale plane, the x-y plane in the measuring device was made even with the axis-orbitale plane.

To minimize blind sectors, the dental cast was scanned from three different directions by tilting the autorotating mounting unit on the measuring device. The three resulting data files were merged into one file automatically by a postprocessor ([Figure 2b](#) ).

### Definition of a new reference plane

First, the curvature of a curved line on a curved surface is considered. The shape in the vicinity of point **P** on a curved line on a curved surface is approximated by a circle. The radius of this circle is the radius of curvature, and the reciprocal is the curvature at point **P**. The

curvature of a straight line is zero. The plane that is the unit tangent vector  $\mathbf{t}$  at point  $\mathbf{P}$  on a curved surface and unit normal vector  $\mathbf{k}$  at point  $\mathbf{P}$  is the normal plane ([Figure 3](#)). The curvature at point  $\mathbf{P}$  is the normal curvature  $k$ , and the value of  $k$  varies according to the position of the normal plane. Next, the maximum and minimum values of normal curvature are considered. When the normal plane rotates about the normal line as an axis of rotation, the curved line changes and the normal curvature  $k$  also changes. In this case, the maximum curvature  $k_1$  and minimum curvature  $k_2$  can generally be obtained in two directions for a normal plane, except for planar and spherical surfaces. These are the principal directions, and they intersect at right angles. Therefore, the mean curvature  $\mathbf{H}$  and the Gaussian curvature  $\mathbf{K}$  can be expressed as

$$\mathbf{H} = 1/2(k_1 + k_2), \text{ and } \mathbf{K} = k_1 k_2.$$

The mean curvature  $\mathbf{H}$  reflects the overall convexity or concavity of a curved surface. If the concavity and convexity are close to equilibrium,  $\mathbf{H}$  is close to zero. The 3-D shape data from the dental cast were divided on the basis of differences in the mean curvature  $\mathbf{H}$  of the curved surfaces. The size of each curved surface was approximately  $1.0 \text{ mm}^2$ . The flatter region of a palatal surface was extracted after setting a threshold ( $0 < \mathbf{H} < 0.21$ ). The extracted region was composed of 2000–3000 points, and a flat plane was fitted by the least squares method. Fitting was carried out automatically by searching for the amount of mismatching of the extracted region, and the flat plane became minimum. As a result, it was possible to define the palatal reference plane ([Figure 4](#)).

### Dental cast and statistical analysis

To ensure correspondence between the lateral and frontal cephalometric radiographs, the angle between the axis-orbitale plane and the newly defined reference plane was measured in the x-z (lateral) and y-z (frontal) views ([Figure 5](#)). In the x-z (lateral) view, to minimize the technical error in model mounting, the results in the cephalometric analysis and dental cast analysis were compensated by the angle difference between the UIE-UMT planes (maxillary occlusal planes).

Linear correlation and regression techniques were used to evaluate relationships between the new reference plane in the 3-D analysis of dental casts and the ANS-PNS, A-PNS, and J-J' planes in lateral and frontal cephalometric radiographs. The mean value and standard deviation of the angle differences for each plane were calculated.

## RESULTS [Return to TOC](#)

### New reference plane

[Figure 6a–c](#) shows a scatter diagram and regression lines for the new reference plane in a dental cast analysis vs the ANS-PNS, A-PNS, and J-J' planes in lateral and frontal cephalometric radiographs. Adequate correlations were obtained in all three relationships ( $P = .01$ ). Using the data points, best-fit straight lines were drawn and regression equations were determined, with correlation coefficients of  $r = 0.701, 0.735, \text{ and } 0.866$ , respectively.

[Table 1](#) shows the mean, standard deviation, and range of the difference in the angle between the axis-orbitale plane and reference planes in the cephalometric analysis and dental casts analysis. In the lateral view, the A-PNS plane was more similar to the new reference plane in the dental cast analysis (mean difference = 2.0 degrees, SD = 1.1 degrees). In the frontal view, the mean difference in the angle between the J-J' plane and the novel reference plane in the dental cast analysis was 1.1 degrees (SD = 1.1 degrees).

## DISCUSSION [Return to TOC](#)

### Accuracy of the 3-D measuring device

We previously reported the accuracy of the measuring device in detail.<sup>19</sup> To examine the accuracy of the 3-D measuring device, a calibrating plane plate was measured using the device, and the best-fit expression for the plane was calculated from all the data, to within  $\pm 3 \text{ SD}$ , by the least squares method. The accuracy of measurement was evaluated by calculating the maximum error between the calculated plane and the obtained data. The result was  $\pm 0.05 \text{ mm}$ . Therefore, this 3-D measuring device is sufficiently accurate for dental cast analysis.

### New reference plane

The new reference plane in the 3-D dental cast analysis corresponds to the A-PNS plane in the lateral view and to the J-J' plane in the frontal view, which have been shown to be sufficiently accurate as measurement references. Because a rotation error, where the ear rod acts as the center of rotation, has considerable influence on the lateral side,<sup>17</sup> only the lateral side needs to be corrected. To confirm the morphological stability of the palate used as a reference, Yamamoto et al<sup>3</sup> evaluated its deformation during 6–21 months of orthodontic treatment in nine patients. The average difference in depth for each patient before and after treatment was only 0.05–0.13 mm, calculated by excluding the palate data around realigned teeth. Therefore, Yamamoto et al<sup>3</sup> used the palate data within 5.0 mm from the bottom

(deepest point) as a reference. The new reference plane in this study satisfies the condition of superscription because the flatter region of the palate within 5.0 mm from the deepest point was used.

The 3-D analysis of dental casts should play an increasingly important role in future orthodontic practice and research.<sup>3-5,9,10,19,20</sup> The ability to obtain a plane that can be used as a skeletal reference from an analysis of dental casts enhances the value of all dentition models. The new reference plane established in this study should not only enhance future analysis but should also make it possible to obtain new information from existing models. The application of this new palatal reference plane, as a reference structure, should provide accurate and abundant 3-D data concerning malocclusion and may therefore be very useful in morphological research on facial asymmetry.

## REFERENCES [Return to TOC](#)

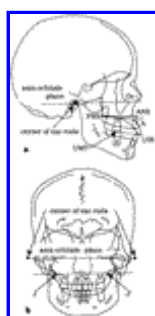
1. Andrews LF. *Straight Wire: The Concept and Appliance*. San Diego, Calif: LA Wells Co; 1989:25–33.
2. Yamamoto K, Toshimitsu A, Mikami T, Hayashi S, Harada R, Nakamura S. Optical measurement of dental cast profile and application to analysis of three-dimensional tooth movement in orthodontics. *Front Med Biol Eng*. 1989; 1:119–130. [[PubMed Citation](#)]
3. Yamamoto K, Hayashi S, Nishikawa H, Nakamura S, Mikami T. Measurement of dental cast profile and three-dimensional tooth movement during orthodontic treatment. *IEEE Trans Biomed Eng*. 1991; 38:360–365. [[PubMed Citation](#)]
4. Iwasaki LR, Haack JE, Nickel JC, Morton J. Human tooth movement in response to continuous stress of low magnitude. *Am J Orthod Dentofacial Orthop*. 2000; 117:175–183. [[PubMed Citation](#)]
5. Simon PW. *Fundamental Principles of a Systematic Diagnosis of Dental Anomalies*. Boston, Mass: The Stratford Co; 1926. [Translated by Lischer BE, from “Grundzüge einer systematischen Diagnostik der Gebiss-anomalien,” Berlin, 1922.].
6. Jarabak JR, Fizzell JA. *Technique and Treatment with Light-Wire Edgewise Appliances*. 2nd ed. St Louis, Mo: CV Mosby Co; 1972.
7. Tweed CH. The Frankfort-mandibular incisor angle (FMIA) in orthodontic diagnosis, treatment planning and prognosis. *Angle Orthod*. 1954; 24:121–169.
8. Steiner CC. The use of cephalometrics as an aid to planning and assessing orthodontics treatment. *Am J Orthod Dentofacial Orthop*. 1960; 46:721–735.
9. Kuroda T, Motohashi N, Tominaga R, Iwata K. Three-dimensional dental cast analyzing system using laser scanning. *Am J Orthod Dentofacial Orthop*. 1996; 110:365–369. [[PubMed Citation](#)]
10. Motohashi N, Kuroda T. A 3D computer-aided design system applied to diagnosis and treatment planning in orthodontics and orthognathic surgery. *Eur J Orthod*. 1999; 21:263–274. [[PubMed Citation](#)]
11. de Araujo TM, Wilhelm RS, Almeida MA. Skeletal and dental arch asymmetry in individuals with normal dental occlusion. *Int J Adult Orthod Orthognath Surg*. 1994; 9:111–118. [[PubMed Citation](#)]
12. Maurice TJ, Kula K. Dental arch asymmetry in the mixed dentition. *Angle Orthod*. 1998; 68:37–44. [[PubMed Citation](#)]
13. Klami O, Horowitz SL. An analysis of the relationship between posterior dental cross-bite and vertical palatal asymmetry. *Am J Orthod*. 1979; 76:51–58. [[PubMed Citation](#)]
14. Hsu BS. The nature of arch width difference and palatal depth of the anterior open bite. *Am J Orthod Dentofacial Orthop*. 1998; 113:344–350. [[PubMed Citation](#)]
15. Handelman CS, Wang L, BeGole EA, Haas AJ. Nonsurgical rapid maxillary expansion in adults: report on 47 cases using the Haas expander. *Angle Orthod*. 2000; 70:129–144. [[PubMed Citation](#)]
16. Palik JF, Nelson DR, White JT. Accuracy of an earpiece face-bow. *J Prosthet Dent*. 1985; 53:800–804. [[PubMed Citation](#)]
17. Ellis E III, Tharanon W, Gambrell K. Accuracy of face-bow transfer: effect on surgical prediction and postsurgical result. *J Oral Maxillofac Surg*. 1992; 50:562–567. [[PubMed Citation](#)]
18. Choi DG, Bowley JF, Marx DB, Lee S. Reliability of an ear-bow arbitrary face-bow transfer instrument. *J Prosthet Dent*. 1999; 82:150–156. [[PubMed Citation](#)]
19. Hayashi K, Araki Y, Uechi J, Ohno H, Mizoguchi I. A novel method for the three-dimensional (3-D) analysis of orthodontic tooth movement—calculation of rotation about and translation along the finite helical axis. *J Biomech*. 2002; 35:45–51. [[PubMed Citation](#)]

TABLES [Return to TOC](#)

**TABLE 1.** Angle Difference Between Axis-Orbitale Plane and Reference Planes in the Comparison of Cephalometric and Dental Casts Analyses

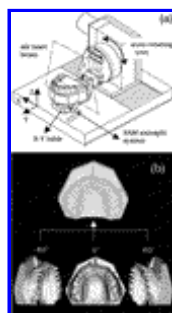
	Mean, degrees	SD	Range
<b>Lateral view</b>			
ANS-PNS	5.6	3.5	0.5–10.5
A-PNS	2.0	1.1	0.5–4.0
<b>Frontal view</b>			
J-J'	1.1	1.1	0.1–3.5

FIGURES [Return to TOC](#)



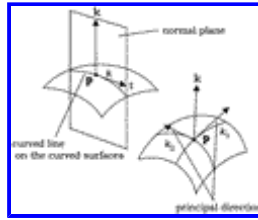
[Click on thumbnail for full-sized image.](#)

**FIGURE 1.** Landmarks and planes in (a) lateral and (b) frontal cephalometric radiographs. Or indicates orbitale; ANS, anterior nasal spine; A, point A; PNS, posterior nasal spine; UIE, upper incisor edge; UMT, upper molar mesial cusp tip; and J-J', jugal process (intersection of the jugal crests and maxillary tuberositas)



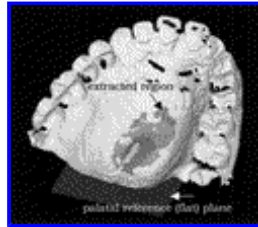[Click on thumbnail for full-sized image.](#)

**FIGURE 2.** A three-dimensional (3-D) surface-scanning system (a) and a 3-D scanned shape of the maxillary dental cast (b). On the basis of the known axis of rotation of the autorotating unit, the three data files were merged into one file



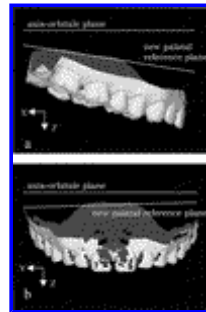
Click on thumbnail for full-sized image.

**FIGURE 3.** A curved surface in three-dimensional space.  $\mathbf{p}$  indicates a point on the curved surface;  $\mathbf{k}$ , normal vector;  $\mathbf{t}$ , tangent vector;  $k$ , normal curvature; and  $k_1$ ,  $k_2$ , principal curvature




Click on thumbnail for full-sized image.

**FIGURE 4.** Definition of a new reference plane using the least squares method



Click on thumbnail for full-sized image.

**FIGURE 5.** Axis-orbitale plane and new palatal reference planes used in (a) lateral and (b) frontal analysis of dental casts



Click on thumbnail for full-sized image.

**FIGURE 6.** Scatter diagram and regression lines of the new reference plane in dental cast analysis vs the ANS-PNS (a), A-PNS (b), and J-J' (c) planes in lateral and frontal cephalometric radiographs

<sup>a</sup>Research Assistant, Department of Orthodontics, School of Dentistry, Health Sciences University of Hikkaido, Hikkaido, Japan

<sup>b</sup>Professor and Chairman, Department of Orthodontics, School of Dentistry, Health Sciences University of Hikkaido, Hikkaido, Japan

