

[\[Print Version\]](#)  
[\[PubMed Citation\]](#) [\[Related Articles in PubMed\]](#)

## TABLE OF CONTENTS

[\[INTRODUCTION\]](#) [\[HISTORY AND...\]](#) [\[RESULTS AND...\]](#) [\[CONCLUSIONS\]](#) [\[REFERENCES\]](#) [\[TABLES\]](#) [\[FIGURES\]](#)

*The Angle Orthodontist*: Vol. 73, No. 6, pp. 745-752.

# Spontaneous Correction of Class II Malocclusion After Rapid Palatal Expansion

Roberto M. A. Lima Filho, DDS, MS;<sup>a</sup> Anna Carolina Lima, DDS, MS;<sup>b</sup> Antonio Carlos de Oliveira Ruellas, DDS, PhD<sup>c</sup>

## ABSTRACT

A case of a Class II, division 1 malocclusion with reduced transpalatal width is reported. The only treatment provided for this patient was rapid palatal expansion. After expansion, the mandible seemed to be carried forward to its normal position, resulting in a spontaneous correction of the Class II malocclusion. This case report illustrates the outcome of the method of treatment used with a long-term (14-year posttreatment) follow-up.

**KEY WORDS:** Class II malocclusion, Spontaneous correction, Rapid palatal expansion.

Submitted: April 2003  
Accepted: February 2003.

## INTRODUCTION [Return to TOC](#)

Rapid palatal expansion has been used for more than a century as a treatment for maxillary constriction. There are many reports on this subject; however, practically all pertain to reactions within the maxillary complex. Very little has been written regarding the changes that occur in the mandible and mandibular dentition under the influence of maxillary expansion.

Although this procedure was initially used to correct posterior crossbites, a greater number of possible indications for this technique have been proposed.<sup>1</sup> Widening the maxilla often leads to a spontaneous forward positioning of the mandible during the retention period in cases of Class II malocclusion in mixed dentition associated with maxillary constriction.<sup>2,3</sup>

This case report illustrates the treatment of a Class II, division 1 malocclusion associated with transverse maxillary-mandibular skeletal discrepancy. The patient was treated in the early mixed dentition with a Haas-type rapid palatal expansion appliance<sup>1</sup> as the only intervention. Treatment revealed a remarkable and positive clinical effect in the correction of this Class II malocclusion. No subsequent comprehensive orthodontic treatment was implemented in either the maxillary or mandibular arch.

## HISTORY AND DIAGNOSIS [Return to TOC](#)

The patient was a girl aged 7 years and 3 months when she was referred by her family dentist for the evaluation and treatment of her maxillary constriction. Her profile was mesognathic-convex, and a facial asymmetry was evident ([Figure 1](#)). The labial musculature tonicity was normal. The parents reported a history of severe respiratory and ear problems. The patient's occlusion showed a posterior crossbite and Class II molar and canine relationships, all on the right side. The left side showed a Class I molar relationship. She presented with anterior open bite, midline deviation, and arch length deficiency for the eruption of permanent maxillary lateral incisors. The diagnosis was Class II, division 1 malocclusion ([Figure 2A,C](#)). The level of attached gingiva was satisfactory, and oral hygiene was fair. Cephalometrics showed that both the maxilla and the mandible were slightly retrusive relative to SN (SNA = 79.5° and SNB = 75.5°), whereas the mandibular plane angle was high (SN-GoGn = 38°). The etiology could have been a combination of an inherited growth pattern and a chronic airways obstruction. The patient's chief complaint was posterior crossbite.

## Treatment options

Because of a good lower arch in the presence of acceptable skeletal and facial relationships, a nonextraction approach to treatment seemed ideal. Two options regarding timing of treatment were considered.

**One-phase treatment.** One alternative would be to defer the orthodontic treatment until the late mixed or early permanent dentition stage of development was established. This alternative would allow the growth potential of the patient to be known and would provide the opportunity for an efficient one-phase treatment. Essentially, treatment would be accomplished in just one phase without the need for a resting period between the phases. The disadvantage of this option is that the patient is left with the functional problem for a longer period to allow the adaptations and limitations that are often associated with this type of malocclusion in late adolescence. This approach probably also increases the possibility of developing a permanent skeletal asymmetry and dentoalveolar compensations.

**Two-phase treatment.** The second alternative would be to perform a two-phase treatment. Because of the reduced transpalatal width, both maxillary and mandibular posterior teeth were compensated, resulting in unfavorable inclination of the lower segments lingually and upper segments buccally. By widening the maxillary dental arch and apical base through rapid palatal expansion, it would be possible to remove the functional interferences caused by maxillary constriction, thus allowing the mandible to move to a more comfortable anterior position. This would facilitate the anteroposterior correction. A two-phase treatment would allow correction of the skeletal, dental, and muscular problems and would produce an environment that promotes unimpeded optimal eruption of the permanent dentition, providing more pleasing facial esthetics.

[Table 1](#) lists the problems and treatment objectives.

## General plan of treatment

Because of the patient's young age, treatment was accomplished in two phases. The plan for phase I was to expand the maxilla with a Haas-type cemented rapid palatal expansion appliance. After screw activation, the appliance would be stabilized and left in place for 3 months for retention of the expanded maxilla. A maxillary acrylic plate would then be placed and trimmed from those teeth which were to be permitted to tip lingually. After phase I treatment, the patient would be placed under supervision to maintain the correction achieved during early treatment and to guide the eruption of the remaining permanent teeth. In the second phase, necessary teeth would be bonded for leveling, aligning, and finishing details.

## Treatment progress

In the initial stage of this mixed dentition treatment, a Haas-type palatal expander was secured to the first deciduous molars and first permanent molars. The patient's mother was instructed to activate the screw two turns per day and stop activation in the event of pain. Twenty-one days later, the screw had been opened 10 mm and the central incisors separated 4 mm when manipulation of the screw was discontinued ([Figure 2D, F](#)). After three weeks, the appliance was stabilized and left in place for three months to allow bone formation at the sutures. A loose-fitting maxillary acrylic palate piece was then put in place when the appliance was removed. The overexpanded teeth were controlled by trimming one side of the acrylic more than the other. The patient was seen for another three months and examined for adjustment of the acrylic plate. The patient was observed until the eruption of the permanent teeth with the exception of third molars.

## RESULTS AND DISCUSSION [Return to TOC](#)

The objective of early treatment was not necessarily to eliminate the need for phase II but to minimize the problems that occurred in the permanent dentition.

The results of the phase I treatment turned out to be so positive that after one year not only was the transverse dimension properly corrected, but the mandible also was carried forward to its normal position, resulting in a spontaneous correction of the Class II malocclusion ([Figure 2G, I](#)). No subsequent comprehensive orthodontic treatment was implemented in either the maxillary or mandibular arch. The only treatment provided for this patient was rapid palatal expansion. During the interim period, the contained jaw was able to move forward because the environment was set up for this to happen.

Haas<sup>1</sup> noted that virtually all Class II, division 2 and most Class II, division 1 patients present mandibular functional retrusion. In the Class II, division 2 group, the retrusion was due to lingual inclination of upper central incisors. In the Class II, division 1 group, the retrusion was due to constriction of the maxillary dental arch, especially between the canines. Haas emphasized that in such cases, it is important to expand the maxillary arch to obtain a permanent orthopedic effect on the maxilla by releasing the mandible to move anteriorly.

Class II malocclusion is related to a deficiency in the maxillary arch width.<sup>4-7</sup> Wending<sup>8</sup> reported that rapid palatal expansion may favor a spontaneous correction of some Class II malocclusions. This procedure induces forward positioning of the mandible during the retention period (6 to 12 months after expansion) in moderate Class II cases. Wending<sup>8</sup> reported that by expanding the maxillary arch, it is possible to release the mandible to move forward, thus creating an excellent condition for the mandible to grow to its full extent, helping in Class II correction.

In this case report, a spontaneous correction of Class II occurred after rapid palatal expansion after the expander appliance had been stabilized. During retention, without any loss of the Es, the anteroposterior discrepancy on the right side moved from a Class II to a Class I molar relationship.

After rapid palatal expansion, an initial downward and forward movement of the maxilla, together with a downward and backward rotation of the mandible, occur which, in fact, have a negative effect on Class II correction. During the retention period, a slight forward positioning of the mandible is observed. The expansion in the transverse dimension seems to lead to positive anteroposterior mandibular changes and to the mandible being carried forward to its normal position.<sup>6,9,10</sup>

All the goals of treatment in this case were achieved. The transverse, anteroposterior, and vertical dimensions appear to be properly corrected and stable, whereas posterior interdigtation, overjet, and overbite are excellent. Dentofacial esthetics were markedly improved ([Figure 3](#)). Molar relationship at the right side achieved Class I simply by a proper mandibular positioning.

Lateral cephalograms from 7 to 22 years of age are shown in [Figure 4](#) and cephalometric measurements in [Table 2](#). Superimposition of cephalometric tracings revealed that both anterior and posterior face height increased significantly ([Figure 5](#)). PA cephalogram at age 22 years shows good symmetry ([Figure 6A](#)). Upper third molars were missing, and lower third molars were extracted because of impaction at age 21 years. A final panoramic radiograph at age 22 years shows good root parallelism in both arches ([Figure 6B](#)).

The only type of retention used in this case was the maxillary removable acrylic plate that was used for two years after active rapid palatal expansion. Because of a good lower arch at the beginning of treatment, retention procedures seemed to be unnecessary given that minimum treatment was performed in this particular case. Currently, the patient is 14 years posttreatment. All tooth relationships have improved. Most importantly, it seems that good stability in the correction of the transverse dimension and dentofacial esthetics were nicely maintained ([Figure 7](#)). The supporting structures were not adversely affected during treatment. The patient is free of facial pain and shows no crepitus or clicking in either temporomandibular joint and has no limitation in motion.

Although there was a small shift in the midline, parents and patient were pleased with the final result, which was accomplished only by rapid palatal expansion. Not all cases have the same response. In this case, rapid palatal expansion created an optimum environment for the contained jaw to promote its growth to its full potential, eliminating the orthodontic problem and creating a stable occlusion ([Figure 4](#)).

## CONCLUSIONS [Return to TOC](#)

In selected cases with mild Class II relationships associated with transverse problems, rapid palatal expansion has proven to be an effective method of treatment to widen the maxillary apical base to its full potential as well as to assist in the anteroposterior correction. This type of treatment is comfortable for the patient because of its short duration and cost effectiveness.

## REFERENCES [Return to TOC](#)

1. Haas AJ. Palatal expansion: just the beginning of dentofacial orthopedics. *Am J Orthod*. 1970; 57:219-255. [[PubMed Citation](#)]
2. Haas AJ. Entrevista: Dr. Andrew J. Haas. *R Dental Press Ortodon Ortop Facial*. 2001; 6:1-10.
3. McNamara JA. Maxillary transverse deficiency. *Am J Orthod Dentofacial Orthop*. 2000; 117:567-570. [[PubMed Citation](#)]
4. Kirjavainen M, Kirjavainen T, Haavikko K. Changes in dental arch dimensions by use of an orthopedic cervical headgear in Class II correction. *Am J Orthod Dentofacial Orthop*. 1997; 111:59-66. [[PubMed Citation](#)]
5. Lima RMA, Lima AL. Case report: long-term outcome of Class II division 1 malocclusion treated with rapid palatal expansion and cervical traction. *Angle Orthod*. 2000; 70:89-94.

6. Baccetti T, Franchi L, McNamara J, Tollaro I. Early dentofacial features of Class II malocclusion: a longitudinal study from the deciduous through the mixed dentition. *Am J Orthod Dentofacial Orthop.* 1997; 111:502–509. [PubMed Citation]

7. Will LA. Transverse maxillary deformities: diagnosis and treatment. *Oral Maxillofacial Surg.* 1996; 5:1–28.

8. Wendling LK. *Short-Term Skeletal and Dental Effects of the Acrylic Splint Rapid Maxillary Expansion Appliance* [master's thesis]. Ann Arbor, Mich: The University of Michigan; 1997.

9. McNamara JA, Brudon WL. *Orthodontic and Dentofacial Orthopedics.* Ann Arbor, Mich: Needham Press; 2001 p. 97–110.

10. Tollaro I, Baccetti T, Franchi L, Tanasescu CD. Role of posterior transverse interarch discrepancy in Class II, division 1 malocclusion during the mixed dentition phase. *Am J Orthod Dentofacial Orthop.* 1996; 110:417–422. [PubMed Citation]

TABLES [Return to TOC](#)

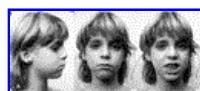TABLE 1. Problem List and Treatment Objectives

Problem List		Treatment Objectives
Maxilla	Transverse maxillary deficiency, posterior cross-bite	Expand transverse relationships, correct posterior crossbite
Mandible	Slightly retruded, mandibular shift	Encourage forward posture, proper position the mandible
Maxillary dentition	Severe crowding, buccal inclined posterior teeth	Gain arch length, proper position canines, correct posterior teeth axial inclination
Mandibular dentition	Buccal inclined posterior teeth	Upright lingual inclined posterior teeth, prevent labial movement of incisors
Occlusion	Dental Class II, unilateral, openbite	Achieve Class I dental relationship, correct openbite, establish good functional occlusion
Function	Respiratory problems	Improve nasal breathing
Esthetics	Poor dental esthetics, facial asymmetry	Improve dentofacial esthetics

TABLE 2. Cephalometric Measurements (°)

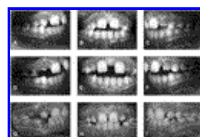
Variables	7 y	8 y	11 y, 6 m
SNA	79.5	79.5	80.0
SNB	75.5	76.0	77.0
ANB	4.0	3.5	3.0
Convexity	8.0	6.5	5.0
SN-GoGn	38.0	38.5	38.5

FIGURES [Return to TOC](#)



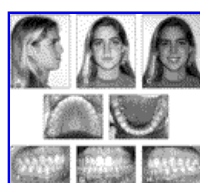Click on thumbnail for full-sized image.

FIGURE 1. Pretreatment facial photographs at age 7 years. (A) Right profile. (B) Frontal rest. (C) Frontal smile. Note the facial asymmetry (B and C)



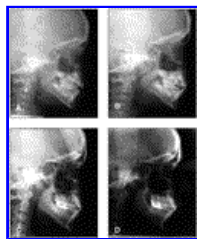
Click on thumbnail for full-sized image.

FIGURE 2. Intraoral photographs: right lateral, central, and left lateral. Pretreatment (A-C), postexpansion (D-F), progress (G-I). Note the tendency toward a buccal crossbite bilaterally (D-F) and a forward sagittal movement of the mandible and the spontaneous correction of the Class II on the right side (G)



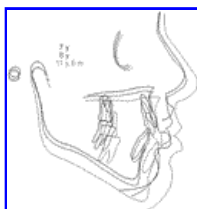Click on thumbnail for full-sized image.

**FIGURE 3.** Posttreatment facial and intraoral photographs at age 15 years. (A) Right lateral. (B) Frontal rest. (C) Frontal smile. (D) Maxillary occlusal. (E) Mandibular occlusal. (F) Right lateral. (G) Central. (H) Left lateral



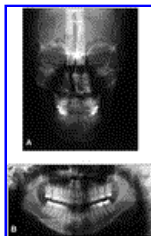
Click on thumbnail for full-sized image.

**FIGURE 4.** Lateral cephalograms. (A) Pretreatment at age 7 years. (B) Progress at age 8 years. (C) Posttreatment at age 15 years. (D) Follow-up at age 22 years



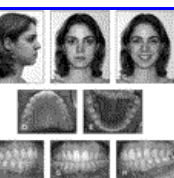Click on thumbnail for full-sized image.

**FIGURE 5.** Cephalometric superimposition of tracings at ages 7 years, 8 years, and 11 years and 6 months



Click on thumbnail for full-sized image.

**FIGURE 6.** (A) PA cephalogram at age 22 years. (B) Panoramic at age 22 years.



Click on thumbnail for full-sized image.

**FIGURE 7.** Long-term facial and intraoral photographs at age 22 years. (A) Right lateral. (B) Frontal rest. (C) Frontal smile. (D) Maxillary occlusal. (E) Mandibular occlusal. (F) Right lateral. (G) Central. (H) Left lateral

<sup>a</sup>Diplomate of the ABO, private practice, S. J. Rio Preto, São Paulo, Brazil

<sup>b</sup>Private practice, S. J. Rio Preto, São Paulo, Brazil

<sup>c</sup>Professor of Orthodontics, Universidade Federal do Rio de Janeiro, Rio de Janeiro, Brazil

Corresponding author: Roberto M. A. Lima Filho, DDS, MS, Avenida Alberto Andaló, 4025, S. J. Rio Preto, São Paulo 15015-000, Brazil (E-mail: [robertolima@riopreto.com.br](mailto:robertolima@riopreto.com.br))