

[\[Print Version\]](#)

[\[PubMed Citation\]](#) [\[Related Articles in PubMed\]](#)

## TABLE OF CONTENTS

[\[INTRODUCTION\]](#) [\[CASE REPORT\]](#) [\[DISCUSSION\]](#) [\[CONCLUSIONS\]](#) [\[REFERENCES\]](#) [\[FIGURES\]](#)

*The Angle Orthodontist*: Vol. 73, No. 6, pp. 763–768.

# Orthodontic and Orthopedic Treatment of a Patient with Incontinentia Pigmenti

Cenk Doruk, DDS, MS;<sup>a</sup> Ali Altug Bicakci, DDS, MS;<sup>b</sup> Hasan Babacan, DDS, MS<sup>b</sup>

## ABSTRACT

Incontinentia pigmenti is an uncommon, inherited disorder with predominantly ectodermal manifestations that is associated with skin (100%), dental (90%), skeletal (40%), central nervous (40%), and ocular (35%) deformities. It is an X-linked dominant disease, usually lethal in males and occurring in female infants. The dental effects include delayed eruption, partial anodontia, microdontia, and cone or peg-shaped teeth. The dental, clinical, and radiological findings in a 16-year-old female are presented here. The patient had peg-shaped teeth and a unilateral maxillary transverse discrepancy associated with oligodontia in the maxillary and mandibular arches. Orthodontic treatment included rapid maxillary expansion and fixed orthodontic therapy for prosthetic purposes and elimination of the functional midline shift.

**KEY WORDS:** Incontinentia pigmenti, Partial anodontia, Rapid maxillary expansion.

Accepted: January 2003. Submitted: January 2003

## INTRODUCTION [Return to TOC](#)

Incontinentia pigmenti (IP), also called Bloch-Sulzberger Syndrome or Bloch-Siemens syndrome, is a complex hereditary disease with ectodermal, neurological, ocular, and dental manifestations.<sup>1</sup>

The cause of IP has been traced to a defect in a gene called *NEMO*, which is present on the X chromosome. The *NEMO* gene is of less than average size, spanning about 23,000 bp. The *NEMO* gene produces a protein that is essential for cells, and defects in it result in IP. Males with IP cannot survive without a functioning *NEMO* gene and thus die in utero. More than 95% of the reported cases are females, the few males probably being the result of spontaneous mutations and die soon after birth. In females, some cells have a normal functioning *NEMO* gene (from the normal X chromosome), whereas other cells have a defective *NEMO* gene. A major review of 635 cases by Carney included only 16 affected males.<sup>2</sup>

*IKK gamma/NEMO* is the essential regulatory subunit of I kappa B kinase (IKK), encoded by an X-linked gene in humans. The regulator subunit of *IKK* is required for nuclear factor B activation and resistance to tumor necrosis factor-induced apoptosis. Biopsies and cells from IP patients exhibit defective *IKK gamma/NEMO* expression but normal expression of *IKK* catalytic subunits. This unique self-limiting disease, the first to be genetically linked to the *IKK* signaling pathway, is dependent on X-chromosome inactivation.<sup>3</sup>

The disease is mostly characterized by dermatological features that occur in four stages, although all stages may not occur and several stages may overlap. Stage 1 is characterized by erythema, vesicles, and pustules; stage 2 by papules, verrucous lesions, and hyperkeratosis; stage 3 by hyperpigmentation; and stage 4 by pallor, atrophy, and scarring.<sup>4</sup> The pigmentary disturbance, an autochthonous tattooing, is evident at or soon after birth and may be preceded by a phase suggesting inflammation in the skin. The pigmentation and other residue of skin manifestations gradually resolve and usually disappear by adulthood.<sup>1,2</sup>

IP may affect the stomatognathic system and causes partial anodontia, microdontia, dysplastic (cone or peg-shaped) teeth, and delayed eruption of teeth.<sup>2,5-10</sup> Researchers have reported the dental defects in IP many times; however, only one of these reports includes orthodontic treatment.<sup>11</sup>

## CASE REPORT [Return to TOC](#)

The case presented here illustrates the problems associated with multiple missing teeth in both arches, including the absence of all molars in the maxillary arch, malpositioned teeth, and a maxillary transverse deficiency. The patient underwent rapid maxillary expansion therapy, although no molars were present for anchorage, and treatment continued with fixed orthodontic appliances for prosthetic purposes.

### Diagnosis and treatment plan

The patient was a 16-year-old Caucasian female who presented for multidisciplinary treatment at the University of Cumhuriyet, Faculty of Dentistry. Her problem was “the absence of posterior teeth and poor smile” (Figure 1A-E). A diagnosis of IP had been made at birth. Her mother had noted inflammatory vesicular skin alterations that changed into pigmented skin alterations especially on the trunk. These gradually faded and disappeared by childhood. No other abnormalities were noted during childhood, except partial anodontia.

The intraoral panoramic radiograph showed that multiple teeth were missing in both arches (12, 16, 17, 26, 27, 36, 37, 41, 46, and 47), that the wisdom teeth were not present, and that 15 and 22 were peg shaped (Figure 2). The mandible had a functional shift to the left with a maxillary transverse discrepancy.

The cephalometric analysis revealed an SNA of 77°, SNB of 75°, and ANB of 2°, a CI 1 jaw relationship, and a normal mandibular plane angle (FMA = 25°). The upper and lower incisors were retroclined ( $U_1/FH = 90^\circ$ ,  $L1/MP = 83^\circ$ ) (Figure 3).

The functional midline shift, combined with some teeth that had migrated into the edentulous spaces, made prosthetic reconstruction difficult without tooth preparation. Therefore, orthodontic treatment was planned to correct the midline and reposition the teeth.

The first step in the treatment plan for the establishment of good occlusal function was to expand the maxilla. A full-coverage acrylic rapid maxillary expander was used to expand the maxilla transversally. The wide spaces and free ends at the maxillary molar region presented a difficult problem for fixed prosthodontic therapy. Therefore, we planned to move the maxillary second premolars distally for use as abutments. However, the distal movement of these teeth was delayed until expansion of the maxillary arch was completed.

### Treatment progress

Expanding the maxilla was the first step in treatment. We choose a tooth- and tissue-borne full-coverage bonded acrylic splint expander and covered all the teeth because of a reduced number of anchorage teeth (Figure 4). This type of expander is also effective for avoiding unwanted tooth tipping.<sup>12,13</sup> The patient's maxilla was expanded by activating the appliance twice per day for 20 days (Figure 5). After expansion had been achieved and the functional midline shift had corrected spontaneously, the appliance was cleaned and reused as a removable retention appliance.

Retention treatment lasted 91 days after expansion. After the retention period, fixed appliances were placed in the maxillary arch, and the second premolars were moved distally using nickel-titanium push coils with light forces. After the desired second premolar position was achieved, Hawley retainers were inserted for retention. The total active treatment time was one year and three months (Figure 6A-E).

## DISCUSSION [Return to TOC](#)

Kuster and Olbing<sup>14</sup> reported a mentally retarded woman with an incomplete dentition and a history of skin lesions at birth. She had one son and 11 daughters. Six of the girls showed incomplete dentition and IP.

Yamashiro et al<sup>11</sup> presented a 21-year-old female who had multiple missing teeth, peg-shaped lower right canine and lower left premolars, and some teeth that had migrated into the edentulous spaces. They concluded that prosthetic reconstruction without excessive

tooth preparation was difficult. Therefore, they used orthodontic treatment to reposition the teeth.

Partial anodontia and peg-shaped or otherwise malformed teeth are the most common abnormalities associated with IP.<sup>2,6,9</sup> Our patient had multiple missing teeth in both the maxilla and mandible in combination with late eruption. Before the orthodontic treatment, there was almost no posterior occlusal function because of the absence of molar teeth. However, there was a good occlusal dimension in this case.

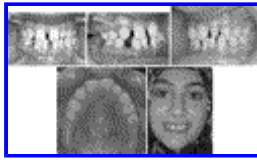Our patient had multiple missing teeth in both arches, and the residual teeth had migrated into the neighboring and opposing edentulous spaces. There was a functional midline shift due to the maxillary transverse discrepancy. These undesired conditions made prosthetic procedures difficult because proper spaces for abutments were not available. Rapid maxillary expansion eliminated the functional midline shift, and orthodontic repositioning of the malpositioned teeth provided a better basis for subsequent prosthetic procedures. In this case, orthodontic treatment made the case manageable for prosthetic purposes (Figure 7A,B). Although the literature contains many research reports on this subject, this case is only the second reported example of orthodontic treatment of a patient with IP.

## CONCLUSIONS [Return to TOC](#)

- IP has characteristic abnormalities of the dentition that may aid in its diagnosis: hypodontia, delayed eruption, and cone or peg-shaped crowns of the primary and permanent dentitions. These changes are similar to those observed in the anhidrotic form of ectodermal dysplasia, which strongly suggest that IP is related.
- Patients with IP, like all other patients with hypodontia, require the combined specialist care of pediatric dentists, orthodontists, and prosthodontists to achieve an optimal outcome.

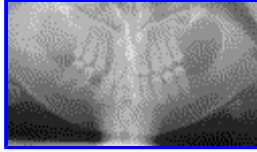
## REFERENCES [Return to TOC](#)

1. Carney RG, Carney RG Jr. Incontinentia pigmenti. *Arch Dermatol.* 1970; 102:157–162. [[PubMed Citation](#)]
2. Carney RG. Incontinentia pigmenti: a world statistical analysis. *Arch Dermatol.* 1976; 112:535–542. [[PubMed Citation](#)]
3. Makris C, Godfrey VL, Krahn-Senftleben G. et al. Female mice heterozygous for IKK gamma/NEMO deficiencies develop a dermatopathy similar to the human X-linked disorder incontinentia pigmenti. *Mol Cell.* 2000; 5:969–979. [[PubMed Citation](#)]
4. Landy SJ, Donnai D. Incontinentia pigmenti (Bloch Sulzberger Syndrome). *J Med Genet.* 1993; 30:53–59. [[PubMed Citation](#)]
5. Wiklund DA, Weston WL. Incontinentia pigmenti: a four-generation study. *Arch Dermatol.* 1980; 116:701–703. [[PubMed Citation](#)]
6. Baddour HM, Steed DL, Tilson HB. Incontinentia pigmenti: report of case. *J Oral Surg.* 1981; 39:701–703.
7. Shotts N, Emery AEH. Bloch Sulzberger Syndrome (incontinentia pigmenti). *J Med Genet.* 1966; 3:148–152. [[PubMed Citation](#)]
8. Browne RM, Bryne JPH. Dental dysplasia in incontinentia pigmenti achromians. *Br Dent J.* 1976; 140:211, 214
9. O'Brien MD, Feingold M. Incontinentia pigmenti. *Am J Dis Child.* 1985; 139:711–712. [[PubMed Citation](#)]
10. Welbury TA, Welbury RR. Incontinentia pigmenti (Bloch Sulzberger Syndrome): report of case. *J Dent Child.* 1999; 66:213–215.
11. Yamashiro T, Nakagawa K, Takada K. Case report: orthodontic treatment of dental problems in incontinentia pigmenti. *Angle Orthod.* 1998; 3:281–284.
12. Sarver MD, Johnston WM. Skeletal changes in vertical and anterior displacement of the maxilla with bonded rapid palatal expansion appliances. *Am J Orthod.* 1989; 95:462–466.
13. Basciftci FA, Karaman AI. Effects of a modified acrylic bonded rapid maxillary expansion appliance and vertical chin cap on dentofacial structures. *Angle Orthod.* 2002; 72:61–71. [[PubMed Citation](#)]
14. Kuster F, Olbing H. Incontinentia pigmenti. Bericht ueber neun Erkrankungen in einer Familie und einem Obdiktianbefund. *Ann Paediatr.* 1964; 202:92–100.



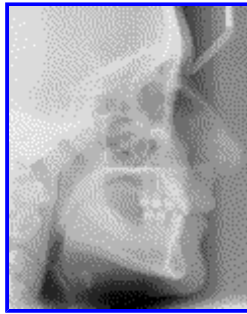
[Click on thumbnail for full-sized image.](#)

**FIGURE 1.** (A–E) Patient before treatment. Note multiple missing teeth in both arches and posterior unilateral crossbite. Mandible shift to left due to the transverse maxillary discrepancy.



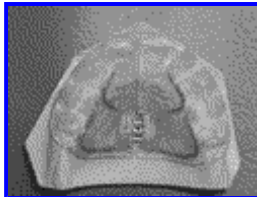
[Click on thumbnail for full-sized image.](#)

**FIGURE 2.** Pretreatment panoramic radiograph. Note multiple missing teeth in the upper and lower arches



[Click on thumbnail for full-sized image.](#)

**FIGURE 3.** Pretreatment cephalometric radiograph. The patient showed a skeletal Class I jaw-base relationship



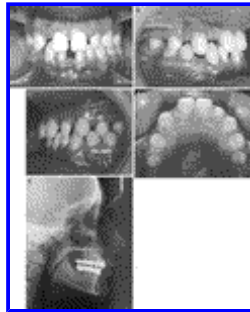
[Click on thumbnail for full-sized image.](#)

**FIGURE 4.** Full-coverage acrylic rapid maxillary expander



[Click on thumbnail for full-sized image.](#)

**FIGURE 5.** Panoramic radiograph of patient after 20 days of expansion.



Click on thumbnail for full-sized image.

**FIGURE 6.** (A–E) Posttreatment intraoral photographs and cephalometric radiograph. Note the distalization of upper second premolars and correction of functional midline shift due to the expansion of the maxilla.



Click on thumbnail for full-sized image.

**FIGURE 7.** (a, b) Patient before and after orthodontic and prosthodontic treatment

<sup>a</sup>Assistant Professor, Orthodontics, Faculty of Dentistry, University of Cumhuriyet, Sivas, Turkey

<sup>b</sup>Assistant Professor, Orthodontics, Faculty of Dentistry, University of Cumhuriyet, Sivas, Turkey

Corresponding author: Ali Altug Bicakci, DDS, MS, Orthodontics, Faculty of Dentistry, University of Cumhuriyet, 58140 Sivas, Turkey (E-mail: [abicakci@cumhuriyet.edu.tr](mailto:abicakci@cumhuriyet.edu.tr))