

[\[Print Version\]](#)
[\[PubMed Citation\]](#) [\[Related Articles in PubMed\]](#)

TABLE OF CONTENTS

[\[INTRODUCTION\]](#) [\[MATERIALS AND...\]](#) [\[RESULTS\]](#) [\[DISCUSSION\]](#) [\[CONCLUSIONS\]](#) [\[REFERENCES\]](#) [\[FIGURES\]](#)

The Angle Orthodontist: Vol. 72, No. 5, pp. 431-438.

The Correlation Between Neovascularization and Bone Formation in the Condyle During Forward Mandibular Positioning

A. B. M. Rabie, MS, Cert Ortho, PhD, FHKAM, FCDSHK;^a F. Y. C. Leung, BDS;^b A. Chayanupatkul, DDS;^c U. Hägg, DDS, Odont Dr, Cert Comp Orth, FCDSHK, FHKAM^d

ABSTRACT

The aim of the present study was to investigate the temporal pattern of expression of VEGF (Vascular Endothelial Growth Factor) and new bone formation in the condyle during forward mandibular positioning. The importance of vascularization during endochondral ossification was investigated during natural growth of the condyle and compared to that after forward mandibular positioning. The goal was to further our understanding of the cellular responses during functional appliance therapy with a view to extending the experiment into maturity. One hundred and fifty 35 days old Sprage-Dawley rats, 100 fitted with a bite-jumping appliance and 50 untreated, were divided into 10 groups. One group was sacrificed on each of experimental days 3, 7, 14, 21, 30, 33, 37, 44, 51 and 60 respectively. Sagittal sections were cut and stained with VEGF antibodies and Periodic acid and Schiff's reagent (PAS). Each section was quantitatively analyzed with a computer assisted analyzing program and the temporal sequence of expression of VEGF and new bone formation during natural growth and after mandibular forward positioning was compared. There was significant increase in both vascularization and mandibular bone growth upon forward mandibular positioning and the highest amount of both were expressed in the posterior region of the condyle. The highest acceleration of vascularization preceded that of new bone formation. Thus, forward mandibular positioning was found to solicit a sequence of cellular events leading to increased vascularization and subsequently new bone formation resulting in enhanced condylar growth.

KEY WORDS: Mandibular condylar growth, Functional appliance therapy, New bone formation, Vascular Endothelial Growth Factor, Vascularization.

Accepted: March 2002. Submitted: November 2001

INTRODUCTION [Return to TOC](#)

Endochondral ossification begins with the proliferation and aggregation of non-differentiated mesenchymal cells.¹ Blood invasion into hypertrophic cartilage matrix is later required for cartilage removal and replacement by bone.² Non-differentiated mesenchymal cells which migrate along with the new blood vessels differentiate into osteoprogenitor cells, which has the potential to differentiate to osteoblasts and give rise to bone formation.² Forward mandibular positioning induces new bone formation in the condyles.³ The mechanisms through which these changes are triggered are not understood and the factors regulating such changes are not known. Vascular Endothelial Growth Factor (VEGF), a potent regulator of neovascularization, was expressed in the condyles and glenoid fossa of growing rats.⁴ A close

correlation existed between VEGF expression and osteogenesis in long bones.⁵⁻⁷ Postnatal partial inhibition of VEGF expression was found to cause stunted body growth, impaired organ development and increased mortality.⁸ In order to determine the role of VEGF in bone growth, Gerber et al⁸ inactivated VEGF through the systemic administration of a soluble receptor chimeric protein to 24 old-day rats. Blood vessel invasion was almost completely suppressed. This was concomitant with impaired bone formation and impaired expansion of the hypertrophic cartilage zone. Cessation of such an inhibition of VEGF treatment was followed by capillary invasion and restoration of bone growth.⁸ Therefore, it was concluded that VEGF plays a central role in vascularization and bone growth.

Cellular and molecular events responsible for the formation of bone during embryogenesis, bone remodeling and fracture repair are almost identical.⁹ The rules that govern the behavior of such cells and tissues are extraordinarily conserved throughout development and adulthood.⁹ Therefore the pattern of expression of such regulatory factors governing bone formation during natural growth could be used as a baseline data against which changes in their pattern of expression induced by forward mandibular positioning could be compared. Since neovascularization and new bone formation are closely related, then it is of importance to quantitatively assess and compare the pattern of expression of VEGF and the amount of new bone formation induced by forward mandibular positioning in the condyles to their pattern of expression during natural growth.

Therefore, the purposes of our study are

- To identify the temporal sequence of expression of VEGF and to correlate it to the pattern of new bone formation in the condyle during mandibular forward positioning.
- To correlate the expression of VEGF and new bone formed during forward mandibular positioning to their pattern of expression during natural growth.
- To follow and compare the patterns of expression of VEGF and osteogenesis during forward mandibular positioning to their levels at the late stages of natural growth.


This way, the long-term effect of functional appliance therapy could be identified and the stability of the newly formed bone could be monitored.

MATERIALS AND METHODS [Return to TOC](#)

Experimental group

One hundred and fifty 35-day-old female Spague-Dawley rats were used in this study. The rats were randomly divided into 10 groups. Each group consisted of 10 rats with bite-jumping appliances and five untreated. Both groups were fed with a soft diet. One group was sacrificed on days 3, 7, 14, 21, 30, 33, 37, 44, 51 and 60 respectively.

Bite-jumping appliance

Bite jumping appliances ([Figure 1](#) ) made from polymethylmethacrylate with identical inclined planes were cemented onto the upper central incisors of the experimental group with dental adhesive resin cement (Panavia-F™, Kuraray Co Ltd, Osaka, Japan). The appliances were worn 24 hours producing a continuous forward and downward positioning of the mandible according to the method reported recently by Rabie & coworkers, 2001.¹⁰

Tissue preparation

The rats were sacrificed by intraperitoneal injection of Dorminal 20% (200 mg pentobarbital sodium, Alfasan) with a dosage of 200 mg/kg body weight. Immediately after death, the heads were fixed in 10% paraformaldehyde. Heads were dissected into two halves and tissues were removed until the areas surrounding the temporomandibular condyle were exposed. The sectioned temporomandibular joint areas were then decalcified in 20% EDTA (Ethylenediamine Tetraacetic Acid, pH 7.2). Any excess tissues were removed and specimens were embedded in paraffin with the ramus parallel to the surface of the block. Serial sections of 7 µm were cut through the TMJ at the parasagittal plane using a rotary microtome (Leica RM 2155) and were floated onto glass slides coated with TESPA. Sections were left to dry.

VEGF Immunostaining

Sections were submerged in 3% H₂O₂ for 10 minutes to block endogenous peroxidase activity. After washing, sections were incubated with Proteinase K (10ug/ml, Sigma, St Louis, Mo) for 30 minutes at 37°C for protease digestion. Sections were then washed and incubated in normal rabbit serum (1:10 diluted with TBS 1X, DAKO, Glostrup, Denmark) for 30 minutes, followed by incubation with primary goat-anti-VEGF antibody (1:50 diluted with PBS, Sigma, St Louis, Mo) overnight under 4°C. After washing, sections were incubated with secondary Biotin-conjugated rabbit-anti-goat IgG (1:400 diluted with PBS, DAKO, Glostrup, Denmark) for 30 minutes at 37°C, followed again by

washing. Strep ABCComplex (1:100 diluted with 1X TBS HRP, DAKO, Glostrup, Denmark) was applied for one hour at 37°C and washed with 1x TBS plus 0.1% tween-20 before dipping in 3,3-Diaminobenzidine Tetrahydrochloride (DAB, Sigma, St Louis, Mo) for five minutes to identify the binding sites. Brown staining indicates positive VEGF. Sections were then counterstained with Mayer Haematoxylin for background staining.

Periodic acid and Schiff's reagent (PAS)

Sections were prepared and stained with PAS following the method by Rabie & coworkers.¹⁰



Quantitative analysis

The amount of VEGF expression and new bone formation in the anterior, middle and posterior regions of the condyle were quantified via a true-color red-green-blue (RGB) computer-assisted image analyzing system (Leica Q5501W, Leica Microsystems Imaging Solutions Ltd, Clifton R, Cambridge CB1 3QH, UK) with Leica Qwin Pro (Version 2.2) software, following the method by Rabie and coworkers.¹⁰ This system acquires high definition digital images of the specimen and features from the acquired images are selected by the operator and recognized by the computer according to color, shade and contrast. The operator marked out the hypertrophic zone and the amount of VEGF expression in the hypertrophic zone was quantified under a fixed measuring frame and expressed as area in mm². The hypertrophic zone is recognized as directly beneath the proliferative zone where the chondrocytes become widely separated, with a large and spherical shape.¹¹ Magnification of 200x (Leitz Orthoplan) was used. A halogen light source connected to a stabilized, adjustable power supply (12V, 100W) provided illumination.

The data was processed with SPSS® for Windows (Version 10.1, SPSS Inc.) for both *t*-test and ANOVA.





RESULTS [Return to TOC](#)




Control Groups

During the late stages of somatic growth, quantitative analysis of the temporal expression of VEGF, in rat condyles past the growth spurt was consistently higher in the posterior region when compared to anterior and middle regions ([Figure 2a](#) ). The pattern of new bone formation in the condyle throughout the same period followed a similar pattern ([Figure 3a](#) ).

After the peak height velocity, both VEGF and bone formation showed a gradual decrease concomitant with the slow down of the growth.

Experimental groups

Forward mandibular positioning led to a constant increase in the expression of VEGF in the posterior region of the condyle when compared to anterior and middle regions ([Figure 2](#) ). Mandibular advancement caused a gradual increase in the expression of VEGF when compared to normal growth, with the highest amount of change in the posterior region observed on experimental day 14 of 0.0036 mm², which is 48% of that expressed during natural growth ([Figure 5](#) ). The expression levels of VEGF gradually decreased towards that expressed during natural growth ([Figure 2](#) ). A similar pattern was observed for the formation of new bone during mandibular advancement where the posterior region of the condyles consistently expressed more bone than anterior and middle ([Figure 3](#) ).

The temporal pattern of new bone formation revealed a gradual increase with the highest change from normal growth observed on day 30 followed by a gradual decline to the levels found during natural growth ([Figures 3](#)  and [6](#) ). When this temporal pattern of increase in new bone formation was compared to that of VEGF expression, as displayed in [Figure 4](#) , the highest increase of VEGF expression preceded that of new bone formation.

The body weight of the rats was monitored as an indicator of general growth. There is an initial significant decrease in body weight of 8.27% after initial placement of the bite-jumping appliance. However, this is followed by gradual increase, resulting in no significant difference between the body weight of the control and the experimental growth towards the end of the observation period.

DISCUSSION [Return to TOC](#)

Ruf and Pancherz¹² and Hansen et al¹³ proposed that functional appliances deliver a more stable result if treated in the post-pubertal period. Therefore, in the current study, we carried out the mandibular advancement on 35 days old rats because, according to Luder et al¹⁴ the post-pubertal period in rats starts from day 31.5. Furthermore, Hägg et al¹⁵ reported that the longer the duration of mandibular advancement, the better the treatment effects. Therefore, in the present study we carried out the advancement for up to 60 days.

The current study identified the pattern of expression of the central regulator of vascularization, VEGF, in the condyle during forward mandibular positioning and compared it to its pattern of expression during natural growth. The VEGF expression is present primarily in the

hypertrophic zone, in agreement with Gerber et al.^{5,8} However, traces of VEGF expression were also found in the proliferative zone, possibly due to the presence of primary chondrocytes, which were found to express VEGF mRNA by Gracia-Ramirez et al.¹⁶ Furthermore, inflammatory cells in and around the disc area like macrophages were found to also express VEGF, which could contribute to the positive immunostaining.

Forward mandibular positioning solicited cellular responses that led to significant increase in the invasion of new blood vessels into the condyle when compared to natural growth. Furthermore, we correlated the pattern and amount of new bone formation to neovascularization in the hypertrophic cartilage matrix of the condyle during forward mandibular positioning and compared that to the pattern of expression during natural growth. The posterior region of the condyle showed the highest amount of VEGF expression during natural growth and during advancement. Interestingly, the highest amount of bone formed during natural growth and in response to advancement also occurred in the posterior region of the condyle. Such a close correlation could be explained by the fact that new blood vessels contribute to the population size of non-differentiated mesenchymal cells¹⁷ because the connective tissues of the invading blood vessels are repository of undifferentiated mesenchymal cells.^{18,19} Results of immunostaining showed that VEGF is expressed by hypertrophic chondrocytes in the growing condyle. Similar to its function in long bones, VEGF could therefore be the regulator of the process of recruiting new blood vessels into the hypertrophic cartilage matrix of the condyle. The newly recruited blood vessels deliver the mesenchymal cells required to replenish the population size of the osteoprogenitor cells needed for differentiation into bone making cells in order to replace the hypertrophic cartilage matrix in the condyle with bone. The invasion of new blood vessels into the hypertrophic cartilage matrix marks the onset of endochondral ossification. Thus pointing to the importance of the invading blood vessels and their direct contribution to bone formation in the condyles. In the mandibular condyles, it is important to understand that there are two different populations of mesenchymal cells contributing to growth. One population is those present in the proliferative layer that differentiates into chondroblasts and regulates the amount of cartilage formed into the condyle.²⁰ A second population is those recruited with the blood vessels invading into the hypertrophic cartilage matrix where they differentiate into osteoblasts and engage in osteogenesis.

Interestingly, the highest levels of expression of VEGF in response to forward mandibular positioning in the condyle preceded the highest level of bone formation induced by mandibular protrusion. Time is required for the vascular invasion following VEGF expression, leading to the recruitment of mesenchymal cells and the subsequent cascade of events leading to new bone formation. This temporal expression together with the fact that VEGF expression was concentrated in the upper hypertrophic chondrocytes indicates that the mechanical strain caused by the pull of the disc attachment can solicit a cellular response that leads to the expression of factors by the cells in the condyles leading to enhanced endochondral ossification. In summary, mechanical strain produced by mandibular advancement causes an increase in the expression of VEGF by hypertrophic chondrocytes and subsequently lead to an increase in vascular invasion into the hypertrophic cartilage layer in the condyle. This triggers the removal of the hypertrophic cartilage and marks the onset of endochondral ossification in the condyle.

Another important aspect in the design of the present experiment is the length of the treatment period. Several researchers advocated that a longer period of functional appliance therapy produced more stable results.^{15,21} Therefore, in the present study, the mandible was advanced for 60 days between days 35–95 of age which extends the treatment period well into the late stages of natural growth. This way, the treatment effect could be identified and the stability of the newly formed bone could be examined. Mandibular advancement led to a significant increase in VEGF expression and these levels were maintained at an either significantly higher or equal levels to those expressed during natural growth but not at lower levels. Similarly, in response to mandibular advancement, the levels of bone formation were either significantly higher or equal to the levels expressed during the late stage of natural growth but not at lower levels. Based on the present data, it is safe to conclude that, functional appliance therapy enhances condylar growth by enhancing neovascularization and new bone formation and this period of enhanced growth is not followed up by a period of subnormal growth.

In the present study, a detailed analysis of the pattern of new blood vessel invasion as well as new bone formation in response to advancement was carried out between the posterior, middle and anterior regions of the condyle. In the posterior region, the amount of VEGF was almost twice as much as that present in the middle and that measured in the middle was almost twice as much as that in the anterior. Similarly the amount of bone formed in the posterior region of the condyle was significantly higher than that in the middle and that measured in the middle was significantly higher than the anterior. These results support the earlier clinical results by Pancherz and Hägg²² where sagittal condylar growth in a group of patients receiving Herbst appliance at the peak height velocity was measured to be 3.3 mm vs 2.3 mm in the vertical direction. When the same measurements were carried out in non-treated growing patients, it was also shown that sagittal growth showed an increase of 2 mm vs 1.3 mm in the vertical direction in the examined period. This indicates that more growth occurred in the posterior than the middle region. It is important to consider the outcomes of functional appliance therapy in light of the current results. Mandibular advancement leads to changes in the biophysical environment that causes a significant increase in the expression of VEGF leading to increase in the invading blood vessels and subsequent increase in the amount of bone formed. This sequence of events leads to increased condylar growth in a sagittal and vertical direction. The length of period of mandibular advancement should be increased from the commonly reported period in the literature of six months^{23–25} to probably double that period of treatment to allow for the newly formed bone matrix to mature into the more stable type I collagenous matrix. The type of collagenous matrix that forms in the human condyle in situations of repair is known to be type III collagen.²⁶ Type III collagen is the emergency type of collagen that occurs during bone repair as well as bone development.^{27,28} The reason that type III collagen is a good candidate for the repair bone matrix is that the nature of the cross links to stabilize the collagen molecules to form collagen fibrils are weaker than those present in type I collagen matrix. This makes its removal at a later stage and its replacement by the more stable type I collagen matrix an easier process. Type III collagen is then removed at a later stage and replaced with Type I collagen, the more permanent type of collagen matrix and the most stable due to its very strong cross links.²⁷ Therefore, the stability of the newly formed bone in the condyle in response to mandibular advancement could be

influenced by whether the clinician allowed the newly formed bone to remodel into the more stable type I collagen matrix. This could be achieved by keeping the mandible in a forward position for a longer period of time, and that could be the reason why better results were seen in patients treated for an extended period of time with functional appliance therapy.¹⁵

CONCLUSIONS [Return to TOC](#)

In conclusions, mandibular advancement causes cellular changes that lead to increased neovascularization and new bone formation in the condyles. These changes continued to be either significantly higher or equal to the levels towards the end of growth spurt but not at lower levels.

ACKNOWLEDGMENTS

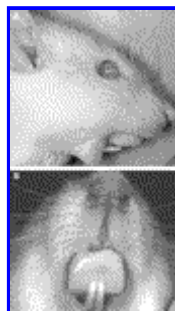
We thank Mr W. Robinson for his assistance in the making of the appliances, Mr Shadow Yeung for his superb support in the statistical analysis and in producing the illustrations, Mr Ying Yip Chui of the Bio-Science Laboratory for his assistance on tissue preparation and Dr KS Lo, Dr WK Tse and Ms A Lam of the Laboratory Animal Unit for their guidance in handling the animals. Supported by The Committee on Research and Conference Grant, University of Hong Kong. Grant CRCG Grant 10203770/22311/08003/323/01 and CRCG Grant 10203764/15633/08003/323/01.

REFERENCES [Return to TOC](#)

1. Ross M, Romrell LJ, Kaye GI. *Histology. A text and atlas.* 2nd ed. Williams & Wilkins, Maryland;1995:132–186.
2. Caplan AI. Mesenchymal stem cells. *J Orthopaedic Research.* 1991; 9:641–650. [[PubMed Citation](#)]
3. Petrovic A, Stutzmann J, Oudet C. *Control processes in the postnatal growth of the condylar cartilage of the mandible.* In: McNamara JA, ed. *Determinants of Mandibular Form and Growth.* Monograph No.4. Craniofacial Growth Series, Center for Human Growth and Development, The University of Michigan, Ann Arbor. 1975:101–154.
4. Leung FYC, Rabie ABM, Hägg U. Expression of vascular endothelial growth factor in the condyle during mandibular forward positioning. *Eur J Orthod.* 2001; 23:620 Abst.
5. Gerber HP, Hillian KJ, Ryan AM, Kowalski J, Keller GA, Rangell L, Wright BD, Radtke F, Aguet M, Ferrara N. VEGF is required for growth and survival in neonatal mice. *Development.* 1999; 126:1149–1159. [[PubMed Citation](#)]
6. Horner A, Bishop NJ, Bord S, Beeton C, Kelsall AW, Coleman N, Compston JE. Immunolocalisation of vascular endothelial growth factor (VEGF) in human neonatal growth plate cartilage. *J Anat.* 1999; 194:519–524. [[PubMed Citation](#)]
7. Carlevaro MF, Cermelli S, Cancedda R, Descalzi Cancedda F. Vascular endothelial growth factor (VEGF) in cartilage neovascularization and chondrocyte differentiation: auto-paracrine role during endochondral bone formation. *J Cell Science.* 2000; 113:59–69. [[PubMed Citation](#)]
8. Gerber HP, Vu TH, Ryan AM, Kowalski J, Werb Z, Ferrara N. VEGF couples hypertrophic cartilage remodeling, Ossification and angiogenesis during endochondral bone formation. *Nature Medicine.* 1999; 5:623–8. [[PubMed Citation](#)]
9. Bruder SP, Fink DJ, Caplan AI. Mesenchymal stem cells in bone development, bone repair, and skeletal regeneration therapy. *J Cellular Biochemistry.* 1994; 56:283–294. [[PubMed Citation](#)]
10. Rabie ABM, Shen G, Hägg U. Osteogenesis in the glenoid fossa in response to mandibular advancement. *Am J Orthod Dentofacial Orthop.* 2001; 119:390–400. [[PubMed Citation](#)]
11. Hinton RJ. *Form and function in the temporomandibular joint.* In: Carlson DS, ed. *Craniofacial Biology.* Monograph Number 10, Craniofacial Growth Series, Center for Human Growth and Development, The University of Michigan, Ann Arbor, Michigan. 1981;37–60.
12. Ruf S, Pancherz H. Temporomandibular joint remodeling in adolescent and young adult during Herbst treatment: A prospective longitudinal magnetic resonance imaging and cephalometric radiographic investigation. *Am J Orthod and Dentofacial Orthop.* 1999; 115:607–618. [[PubMed Citation](#)]
13. Hansen K, Pancherz H, Hagg U. Long-term effects of the Herbst appliance in relation to the treatment growth period: a cephalometric study. *Eur J Orthod.* 1991; 13:471–481. [[PubMed Citation](#)]
14. Luder H. *Postnatal development, aging, and degeneration of the temporomandibular joint in humans, monkeys, and rats.* In: McNamara JA, ed. *Craniofacial Growth Series, Center for Human Growth and Development, The University of Michigan, Ann Arbor, 1993.*


15. Hagg U, Du X, Rabie ABM. Growth modification of severe skeletal class II malocclusions by dentofacial orthopedics. Lecture presented at: 77th European orthodontic society congress; June 19–23, 2001, Ghent, Belgium.
16. Gracia-Ramirez M, Toran N, Andaluz P, Carrascosa A, Audi L. Vascular endothelial growth factor is expressed in human fetal growth cartilage. *J Bone and Mineral Research*. 2000; 15:534–540. [[PubMed Citation](#)]
17. Brighton CT, Lorch DG, Kupcha R, Reilly TM, Jones AR, Woodbury RA. The pericyte as a possible osteoblast progenitor cell. *Clinical Orthopedics and related Research*. 1992; 275:287–299.
18. Diaz-Flores L, Gutierrez R, Varela H. Behaviour of postcapillary venule pericytes during postnatal angiogenesis. *J Morphology*. 1992; 213:33–45. [[PubMed Citation](#)]
19. Diaz-Flores L, Gutierrez R, Lopez-Alonso A, Gonzalez R, Varela H. Pericytes as a supplementary source of osteoblasts in periosteal osteogenesis. *Clinical Orthopedics and Related Research*. 1992; 275:280–286.
20. She TT, Rabie ABM. Expression of SOX9 in the mandibular condyle. Lecture presented at: 77th European orthodontic society congress; June 19–23, 2001, Ghent, Belgium.
21. McNamara JA. Long term mandibular adaptations to protrusive function: An experimental study in macaca mulatta. *Am J Orthod and Dentofacial Orthop*. 1987; 92:98–108. [[PubMed Citation](#)]
22. Pancherz H, Hägg U. Dentofacial orthopedics in relation to somatic maturation. An analysis of 70 consecutive cases treated with the Herbst appliance. *Am J Orthod*. 1985; 88:273–87. [[PubMed Citation](#)]
23. Pancherz H. Treatment of Class II malocclusions by jumping the bite with the Herbst appliance: A cephalometric investigation. *Am J of Orthod*. 1979; 76:423–442. [[PubMed Citation](#)]
24. Weislander L. Intensive treatment of severe Class II malocclusion with a headgear-Herbst appliance in the early mixed dentition. *Am J Orthod*. 1984; 86:1–13. [[PubMed Citation](#)]
25. Pancherz H. The Herbst appliance; its biological effects and clinical use. *Am J Orthod*. 1985; 87:1–20. [[PubMed Citation](#)]
26. Salo LA., Raustia AM. Type II and type III collagen in mandibular condylar cartilage of patients with temporomandibular joint pathology. *J Oral & Maxillofac Surg*. 1995; 53:39–44. discussion 45. [[PubMed Citation](#)]
27. Crofton PM, Stirling HF, Schonau E, Kelnar CJ. Bone alkaline phosphatase and collagen markers as early predictors of height velocity response to growth-promoting treatments in short normal children. *Clinical Endocrinology (Oxford)*. 1996; 44:385–394. [[PubMed Citation](#)]
28. Delvin H. Early bone healing events following rat molar tooth extraction. *Cells Tissues Organs*. 2000; 167:33–37. [[PubMed Citation](#)]

FIGURES [Return to TOC](#)




Click on thumbnail for full-sized image.

FIGURE 1. Bite-jumping appliances with continuous forward and downward positioning of the mandible in a) lateral and b) occlusal views




[Click on thumbnail for full-sized image.](#)

FIGURE 2. The temporal pattern of expression of VEGF in the anterior, middle and posterior regions of the condyle from day 3 to day 60 during natural growth of the condyle and during mandibular forward positioning. Significantly higher expression was found in the posterior region: A) During natural growth B) During forward mandibular positioning. Significant differences in VEGF expression existed between the control and the experimental groups: 1.) In the anterior regions on days 21 and 30 with an increase of 55.46% and 66.35% in the experimental groups respectively, 2.) In the middle regions on days 14, 21 and 30 with an increase of 63.09%, 57.84% and 45.53% in the experimental groups respectively, and 3.) In the posterior regions on days 14, 21, 30 and 33 with an increase of 48.04%, 37.10%, 41.78% and 35.19% in the experimental groups respectively. * $P < .05$, ** $P < .01$, *** $P < .001$



[Click on thumbnail for full-sized image.](#)

FIGURE 3. The temporal pattern of formation of new bone in the anterior, middle and posterior regions of the condyle from day 3 to day 60 during natural growth of the condyle and during forward mandibular positioning. Significantly higher expression was found in the posterior region: A) During natural growth and B) During forward mandibular positioning. Significant differences in new bone formation existed between the control and the experimental groups: 1.) In the anterior regions on days 14, 21, 30, 33 and 37 with an increase of 25.87%, 40.13%, 49.04%, 50.78% and 38.91% in the experimental groups respectively, 2.) In the middle regions on days 14, 21, 30, 33 and 37 with an increase of 59.43%, 58.94%, 80.11%, 67.66% and 46.35% in the experimental groups respectively, and 3.) In the posterior regions on days 14, 21, 30, 33 and 37 with an increase of 30.05%, 59.23%, 90.54%, 67.80% and 38.65% in the experimental group respectively. *** $P < .001$



[Click on thumbnail for full-sized image.](#)

FIGURE 4. The temporal pattern of VEGF expression and new bone formation during mandibular forward positioning

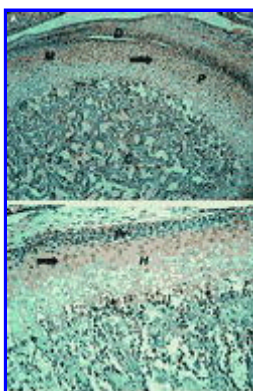
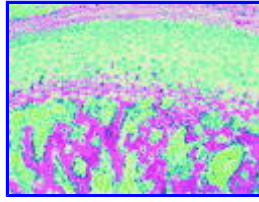


FIGURE 5a. Photomicrograph showing positive immunostaining of VEGF expression (→) in the posterior (P) and middle (M) regions of the mandibular condyle with forward mandibular positioning on Day 14. (C)= Condyle, (D) = Articular Disc. Scale Bar = 100 µm. **FIGURE 5b.** Photomicrograph showing positive immunostaining of VEGF expression (→) in the posterior region of the mandibular condyle during normal growth on Day 14. (Pr) = Proliferative zone. (H) = Hypertrophic zone. Scale Bar = 50 µm



Click on thumbnail for full-sized image.

FIGURE 6. Photomicrograph showing positive PAS staining of new bone formation (B) in the posterior region of the mandibular condyle during forward mandibular positioning on Day 30. Scale bar = 50 µm

^aAssociate Professor in Orthodontics, Director, Hard Tissue Research, Faculty of Dentistry, The University of Hong Kong, Hong Kong SAR, China

^bMaster student in Orthodontics, Faculty of Dentistry, The University of Hong Kong, Hong Kong SAR, China

^cMaster student in Orthodontics, Faculty of Dentistry, The University of Hong Kong, Hong Kong SAR, China

^dChair Professor in Orthodontics, Faculty of Dentistry, The University of Hong Kong, Hong Kong SAR, China

Correspondence Author: Dr ABM Rabie, Orthodontics, Faculty of Dentistry, The University of Hong Kong, Prince Philip Dental Hospital, 34 Hospital Road, Hong Kong SAR (E-mail: rabie@hkusua.hku.hk).