

[\[Print Version\]](#)

[\[PubMed Citation\]](#) [\[Related Articles in PubMed\]](#)

TABLE OF CONTENTS

[\[INTRODUCTION\]](#) [\[REVIEW OF...\]](#) [\[CONCLUSIONS\]](#) [\[REFERENCES\]](#) [\[TABLES\]](#) [\[FIGURES\]](#)

The Angle Orthodontist: Vol. 71, No. 1, pp. 12-22.

Transmigrant Mandibular Canines: A Record of 28 Cases and a Retrospective Review of the Literature

M. R. Joshi, MDS^a

ABSTRACT

The transmigrant mandibular canine is a rare phenomenon. Most authors have described singular cases of unilateral or bilateral occurrence; however, a few authors have published more cases. This paper describes 28 cases exhibiting transmigratory canines. The observations are compared with observations from 39 earlier reports. Women are affected more than men. The left canine undergoes transmigration more commonly than does the right canine. Transmigration and impaction appear to be more common. Most of the patients do not have any symptoms, and these canines are often discovered at the radiological examination before orthodontic treatment. The etiology is obscure; however, abnormal displacement of the tooth bud in embryonic life is a commonly accepted explanation. Prolonged retention of the deciduous canine is a good clinical sign for a thorough radiological examination, preferably including an orthopantomographic radiograph. This would help in preventive measures. However, once established, a transmigrated canine requires surgical extraction. If possible, and if space is available and the patient is willing, all orthodontic efforts should be made to restore the normal position of this functionally very useful tooth in the human dentition.

KEY WORDS: Malocclusion, Tooth impaction, Orthopantomography, OPG, in diagnosis, Developing dentition, Canine transmigration treatment, Mandibular permanent canine eruption pattern, Prolonged deciduous canine retention.

Accepted: August 2000. Submitted: November 1999.

INTRODUCTION [Return to TOC](#)

Impacted teeth are important to dentistry and are particularly significant in orthodontics, especially if the impacted tooth is a canine. In the human dentition, maxillary and mandibular canines are strong teeth and are very relevant from an aesthetic as well as a functional point of view when they are present in their normal position. Nevertheless, it is not uncommon to find impacted canines, unerupted canines, and canine deviations that create many problems for the orthodontist and the oral surgeon in particular and the dental practitioner in general. The occurrence of impacted mandibular canines is more rare than that of the maxillary canines. It is an even more rare phenomenon when such an impacted mandibular canine migrates to the other side of the mandible, crossing the mandibular midline. This abnormal movement

of a tooth has been termed transmigration, or movement of an unerupted tooth without the influence of any pathological entity. Most of the time, such a migrated tooth remains impacted; however, it may subsequently sometimes erupt at its new position. Keeping this in mind, 28 cases exhibiting this phenomenon are described in this article, and a retrospective review of the literature up to 1996 on this exceptional phenomenon is briefly presented.

REVIEW OF THE LITERATURE [Return to TOC](#)

Writing about the history, causes, and treatment of aberrant teeth, Nodine¹ mentioned that the oldest human specimen showing an impacted and unerupted left mandibular canine is that of a Mousterian youth found in Vezere, France, in 1908, and estimated as being 40,000 years old. Nodine has also mentioned that a prehistoric specimen of the mandible of a child showing a partially developed inverted canine was found among a number of skulls and jaws of prehistoric origin taken from a Wiltshire barrow in England by Bennet.² Thoma³ described this anomaly in living patients for the first time.

Observations

A chronological resume of the clinical features of the transmigratory mandibular canine, as observed by various earlier authors, is given in [Table 1](#). Findings of the present study of 28 patients are given in [Table 2](#). All the transmigrated canines were impacted except in 1 patient, in whom the right canine had transmigrated and erupted mesial to the left canine in a mirror-image position ([Figure 1](#)). [Figure 2](#) shows a patient's orthopantomographic picture of the dentition having bilateral transmigration of lower canines. [Table 3](#) shows the comparison of the clinical features of such canines from earlier reports and the present one.

To find out whether the prevalence of clinical features of the present investigation differs significantly from those observed by earlier authors, chi-square tests were carried out. The results did not show statistically significant differences between the 2 studies at the 95% confidence level with 1 to 5 degrees of freedom ([Table 4](#)).

Retrospection and Discussion

Nomenclature. The condition described here has been identified by various names, such as *aberrant*, *impacted*, *imprisoned*,¹ *anomalous*,⁴ *misplaced*,⁵ *displaced*,^{6,7} *ectopic*,^{8,9} *malposed*,¹⁰⁻¹² *unusual*,¹³ *transposition*,^{1,14} *maleruption*,¹⁵ *displacemant*,^{6,7} *migratory*,¹⁶ and *transmigration*.¹⁶ *Transmigration* appears to be the most appropriate, because the canine migrates from one side of the jaw to the other side, passing through the jaw midline.

Frequency of occurrence. Canine impactions occur 20 times more frequently in the maxilla than in the mandible,¹⁷ and impacted maxillary canines have not been observed migrating across the midline palatal suture. According to Thoma,³ mandibular canines are rarely found in a horizontal position in the mandible, and their transmigration is a very rare phenomenon. Javid¹⁸ reported that a radiographic survey of 1000 students revealed only 1 transmigrated impacted mandibular canine. Zvolanek¹⁹ was unable to find any statistical frequency of occurrence of this anomaly in the earlier literature. Therefore, he reviewed 4000 patients' records but failed to find any additional cases. Most of the authors have reported single cases, but Bruszt²⁰ found 2 cases. Tarsitano and associates²¹ observed 3, Howard⁴ published 8, Javid¹⁸ reported 13, and Dhooria et al²² published 3. Joshi et al²³ were the first to report the bilateral occurrence of transmigratory canines, and later Javid¹⁸ reported 3 cases of the bilateral occurrence of this anomaly. In the present report, observations on 28 patients have been described.

Symptoms. Nodine¹ reported that impacted and migrated mandibular canines are often discovered without having produced any apparent symptoms suggestive of their presence. During the initial examination of a 12- or 14-year-old orthodontic patient demonstrating the absence of the permanent canine from the mandibular arch, the permanent canine may be suspected to be in an impacted position in the jaw. The prolonged retention of the deciduous canine is quite often a reliable clue leading to the discovery of its impacted permanent successor. It is possible that routine full-mouth intraoral dental radiographs may fail to reveal impacted canines.⁴ However, since the advent of panoramic radiography, it has become rather easy to detect a migratory tooth, and it is possible that more cases will be reported in the future. Twenty-seven of the patients observed in this investigation did not have any symptoms as far as the impacted canines were concerned.

Only 1 patient ([Figure 1](#)), in whom both canines had erupted on the labial aspect on the left side in a mirror-image position, complained of unsightly appearance of teeth while smiling. Ando and associates²⁴ also reported that they had not observed any symptoms such as pain or oppression of mandibular nerve owing to the transmigration of canine in their patients.

Associated pathological conditions. In a very true sense, the transmigration of a tooth should not have any pathological conditions associated with that tooth.^{11,25} However, Thoma³ and Shapira et al⁶ have described this anomaly accompanied by a cyst or odontoma. Therefore, in the present paper, some cases have been included only on the basis of the canine's having migrated across the midline. It is difficult to say that these pathological conditions were responsible for the transmigration process or the pathological condition occurred after the migration of the canine.

Side of occurrence. The left canine is more involved than the right canine, and women tend to have this condition more frequently than do men. It is not possible to offer any plausible reason for this preference. However, it can be observed that all these patients reported first to the orthodontist for their malocclusion problem, and the impacted unerupted and migratory teeth were detected secondarily during the clinical and radiological examination. Among orthodontic patients, women are usually more common than men, and this would also reflect on such findings in this study.

Distance of migration. The distance traveled by the mandibular canine in the process of migration, as reported from the literature cited in this paper, ranged from a position below the central incisor roots⁸ on the opposite side to a position below the distal root of first permanent molar on the opposite side. [26](#), [23](#), [27](#)

According to Javid,¹⁸ an impacted mandibular canine that has crossed the midline more than half of its length should be considered as transmigrated. However, the present author feels that not the distance of migration after crossing the midline, but the tendency of a canine to cross the barrier of the mandibular midline suture is a more important consideration. Moreover, it will also depend in what stage of transmigration the tooth is when the orthodontist or the oral surgeon first sees the patient.

Speed of migratory movement. This aspect could not be investigated in the present 28 cases because a follow-up radiological examination was not possible. Howard⁴ found that the greatest distance traveled by an impacted canine was to the first premolar on the opposite side of the arch in 2 patients, one aged 12 years and the other aged 15 years. Howard reasonably expected that the older patient would show a greater distance of travel because a longer time had been available for the migratory canine to travel. However, this was not found to be the case. In one of Howard's 20-year-old patients, the canine had transmigrated up to the lateral incisor on the opposite side, and in the second 18-year-old patient, the impacted canine had traveled to the canine on the other side of the arch.

Abbot and associates²⁸ observed the movement of a canine up to a position between the lateral incisor and the canine on the opposite side of the mandibular arch in a 62-year-old patient. It is apparent, however, that migration is a relatively slow process. Dhooria and associates²² observed about 3 to 4 mm of movement of a transmigratory canine in one of their patients during 1 year.


The only long-term series of radiographs found in the literature of a transmigrating mandibular canine is that of Ando and coworkers,²⁴ who observed transmigration in their patient for 6 years. During this time, the canine moved from its original position to a place near the mental foramen on the opposite side. Ando et al further stated that movement of transmigratory canine is more rapid before the formation of its root, but Dhooria et al²² observed a fairly rapid movement even after completion of the root formation.

Greenberg and Orlian⁸ published radiographic evidence documenting ectopic movement of a canine apical to the mandibular incisors of the opposite side of the arch in 30 months. Stafne¹⁰ pointed out that the greatest amount of movement takes place before complete development of the root of the tooth, and the tooth always travels in the direction of the crown. Sutton²⁹ expressed a similar opinion.

Overretained deciduous canines. Four of the 28 patients from the present investigation showed bilateral transmigration of canines. In one 12-year-old patient, orthodontic treatment was in progress, and neither deciduous canine was present. The second patient, aged 17 years, had retained both deciduous canines. The third patient, aged 17 years, had 1 overretained deciduous canine, and the other one had exfoliated. This means that out of 6 deciduous canines, 3 were overretained and 3 had exfoliated. The fourth patient, aged 12 years, had both deciduous canines overretained. From 24 patients who had unilateral transmigration, 17 patients had overretained canines, and in 7 patients the deciduous canines had exfoliated.

The survey of the earlier authors' work revealed that 19 authors have not mentioned anything about the deciduous canines. From the work of the remaining authors, it was found that 36 deciduous canines were overretained and 27 were exfoliated.

From the present author's earlier study³⁰ on the transposed maxillary canine, it was observed that 60.5% of maxillary deciduous canines were overretained, whereas 39.5% of the deciduous canines had exfoliated. In the mandibular arch, the present study showed 70.8% overretained deciduous canines, and 29.2% had exfoliated. This observation shows that, in the absence of the developing permanent mandibular canine under the deciduous canine, the resorption process of the root of the deciduous canine is rather slow.

The axial inclination of impacted canines. Howard⁴ observed that those canines that lie between 25° and 30° in the midsagittal plane represent a group of unerupted canines that are displaced but not migrating across the mandibular midline. Those impacted canines that are between 30° and 95° are a group that tends to cross the midline. An overlap appears to exist between 30° and 50°. When this angle exceeds 50°, crossing the midline becomes a rule. Considering this aspect, the migratory canines from the present paper ranged from 45° to 90°, the only exceptions being the erupted canine in mirror-image position with the other side canine ([Figure 1](#) ) and those observed earlier by Pratt³¹ and Bruszt.²⁰

Etiology. Nodine¹ reported that it is not possible to put forward a definite etiologic factor responsible for this anomaly but noted that abnormal displacement of the dental lamina in the embryonic life is a commonly accepted explanation of the cause of the displacement and noneruption of such canines.

Hereditry has been suggested as a causative factor.¹ Bennett² emphasized that a very small obstacle, such as a small root fragment, would be sufficient to divert a tooth from its normal path of eruption. Mitchell⁷ noted that traumatic fracture of the mandible near the site of the mandibular canine has been observed in one 7-year-old patient as a causative factor leading to the transmigration of the mandibular permanent canine.

Vichi et al³² mentioned that, even though the actual mechanism responsible for the transmigration is not clearly understood, they observed proclination of the lower incisors, increased axial inclination of the unerupted canine, and an enlarged symphyseal cross-sectional area of the chin in nearly in all their cases. They suggested that these factors could play an important role in the mechanism of transmigration. They further stated that the unerupted canine has the possibility of deviating from its normal development site, moving to a horizontal position, and migrating through the symphyseal bone only if enough space is available in front of the roots of the lower incisors.

The present author feels that it is possible to prove this point only if one has a cephalometric record of the chin morphology before, during, and after the migratory canine has left the mandibular symphyseal sutural region. Most of the canines in the present investigation were diagnosed from orthopantomographs at just one time. As long as the impacted migratory canine is lodged in the symphyseal area, this area will grow larger to accommodate the impacted canine, and because the process of migration is slow, when the transmigratory canine leaves the symphyseal area to move further, the symphyseal area will return to its normal size. At the same time, the axial inclination of the mandibular incisors will also change, and the configuration of chin morphology will return to its earlier shape and size.

Sutton²⁹ described a process wherein the canine, for some unknown reason, deviates to a horizontal position and an abnormally strong eruptive force directs the crown through the dense mandibular symphysis to the other side. In addition to this, Javid¹⁸ reported that the conical shape of the crown and the root of the mandibular canine facilitate its transmigration process within the mandible.

Preventive and interceptive treatment. It is possible that in some cases, unexpected pathological conditions may appear on radiographs when the radiographs are critically and completely examined. For example, when the dental surgeon finds an excessive mesial inclination of the unerupted mandibular permanent canine in an 8- to 9-year-old patient, the inclination may be associated with a mechanical obstruction to its normal eruption, an enlarged symphyseal area, and proclinated mandibular incisors.

Vichi et al³² suggest that such a patient should be kept under critical observation with periodical orthopantomographic examinations. If the position of the unerupted mandibular canine is observed to progressively tilt more to the mesial, interceptive measures such as prompt extraction of the deciduous canine and, if necessary, surgical exposure of the impacted canine should be followed by orthodontic treatment. Once the transmigration process is definitely established, the only treatment possible is surgical extraction. Howard⁴ expressed the opinion that a surgical repositioning of the canine should be attempted before extracting the transmigrated canine. If the malocclusion requires an extraction mode for orthodontic treatment in the lower arch, then the transmigrated canine should be extracted instead of the usual premolar unit. This would reduce the orthodontic treatment time and also the hazardous orthodontic tooth movement. Special attention should be given to those cases that demonstrate disturbance of eruption sequence or where the deciduous teeth are overretained.

In patients whose radiographs demonstrate the presence of an unerupted mandibular canine that is excessively tilted to the mesial, and if the canine has begun to migrate across the incisors, a decision to prematurely extract the first premolars should be avoided. Observation in younger patients perhaps gives an opportunity of watching to see if the canine migrates further. However, beyond the age of 14 years there is seldom any reason for observation, and surgical extraction remains the only choice.³³

Orthodontic treatment. Wertz³³ described the only published paper that illustrates a successful attempt to bring transmigrated canines into their normal place. In 3 out of 4 cases he attained an excellent result; however, in the fourth patient he had to extract the transmigrated canine and consider the extraction of other premolars to complete the orthodontic treatment. Wertz³³ concluded that, although it is difficult, it is possible to bring an impacted transmigrated canine positioned to the labial to its normal position.

Wertz³³ also noted that, if the tip of the crown has migrated past the adjacent lateral incisor root apex, it might be mechanically impossible to bring the aberrant canine into its normal place. In such a case, Wertz³³ advocated that, if a nonextraction method of orthodontic treatment is indicated, a surgical repositioning should probably be attempted before just extracting the transmigrated canine. However, if the diagnosis indicates an extraction mode of treatment in the lower arch, then the transmigrated canine should be extracted instead of the usual premolar, eliminating excessive treatment time. Howard⁴ expressed a similar viewpoint.

Notes on surgical extraction of such canines. The reports of Caldwell²⁶ and also of Bruszt²⁰ clearly show that the transmigrated canine maintains its nerve supply from the original site. Hence, it is necessary to anesthetize the nerve of the side to which the canine belongs, especially when the extraction is to be attempted under local anesthesia. However, if general anesthesia is to be used, this problem does not arise. If the other teeth are in normal position and space for the impacted transmigrated canine is sufficient, a transplantation process as described by Howard⁴ may be undertaken. In patients for whom the transmigrated canine is asymptomatic, radiographic examination at regular intervals would definitely help early detection of further migration or development of some pathological changes around the canine in question. The deciduous canine remains overretained most of the time in such cases; its root does show resorption but is rather slow. Extraction of a transmigrated tooth should be done as far as possible through an intraoral approach. Nevertheless, if necessary, an extraoral approach can be adopted.

Summary. Transmigration of the mandibular canine across the mandibular midline is a rare and elusive phenomenon described in the dental literature. Most of the authors have described cases of singular occurrence, but there are a few who have found more cases. The distance of migration by this tooth ranged from its tip's just crossing the mandibular midline and reaching below the incisor root to a position below the distal root of the mandibular first permanent molar on the opposite side.

This paper describes 28 cases exhibiting transmigratory canines. Women appear to have been affected more than men. In addition, this phenomenon occurs more frequently with the left canine than the right canine. Invariably, the tooth migrates without any pathological entity, but there are a few cases in which a cyst or an odontoma has accompanied such a tooth. Most of the time, there are no symptoms, and such teeth have been discovered at the time of radiographic examination before orthodontic treatment. Since the advent of panoramic radiography, such migratory teeth have been discovered more frequently. Etiology of this phenomenon is obscure. However, abnormal displacement of the tooth bud in the embryonic life is a commonly accepted explanation. Heredity has been hinted at as a causative factor.

A very small obstacle, such as a small root fragment, could be sufficient to divert this tooth from its normal path of eruption. Traumatic fracture of the mandible near the site of the mandibular canine in a 7-year-old has also been found as a causative factor associated with transmigration. The deciduous canine remains overretained most of the time in such cases. Its root does resorb, but at a slower rate. The transmigrated canine usually remains impacted, but occasionally it erupts labially, lingually, or in the mirror-image fashion with the contralateral side canine. The presence of an overretained mandibular deciduous canine should always be investigated radiologically. An intraoral radiograph usually is not sufficient, and it should be supplemented with an occlusal and extraoral oblique lateral radiograph, preferably an orthopantomograph.

In this paper, 39 publications describing this anomaly from worldwide sources have been reported. However, it is possible that, although unintentional, some qualified publications are likely to have escaped attention. Yet it can be said that this paper represents the most complete compilation of the papers on the subject of transmigration of mandibular canines assembled up to end of 1996.

CONCLUSIONS [Return to TOC](#)

Transmigration of the mandibular canine across the mandibular midline is an uncommon phenomenon described in the dental literature. Most of the time, the canine just migrates without any pathological entity, but in a few cases a cyst or odontoma accompanies such a tooth. Most of the time there are no symptoms, and such teeth have been discovered at the time of radiological examination before orthodontic treatment.

Since the advent of panoramic radiography, such migratory teeth have been discovered more frequently. Etiology of this phenomenon is obscure. However, heredity, trauma to the mandible at a very early age of the patient, and a very small obstacle, such as root fragment, could be sufficient to divert such a tooth to an abnormal path. Extraction of the transmigrated canine appears to be the only choice of treatment in most of the cases. Nonetheless, in exceptional conditions when other teeth are in normal position and the space for the migrated canine is sufficient, a transplantation procedure is one way of treating such cases.

It is necessary to take care to anesthetize the transmigrated tooth from the side where it originated. However, if the surgical extraction is done under general anesthesia, this problem does not arise. The presence of an overretained mandibular deciduous canine should always be investigated radiographically. An intraoral radiograph is usually not sufficient, and it should invariably be supplemented with an occlusal and extraoral radiograph, preferably an orthopantomographic radiograph. The present study confirms the findings of the earlier investigations.

ACKNOWLEDGMENTS

The author expresses a deep sense of gratitude and his heartfelt thanks to the following orthodontists for sending the records of their orthodontic patients, ever willingly: Drs Godiawala, Ahuja, Daruwala, Tiwari, Dinyar, and Gupte, from Ahmedabad; Drs Hina and Mehta from Baroda; Dr Vakil from Surat; Dr Shah from Rajkot; Dr Robin from Kerala; and my colleagues from the orthodontia department at KLES Dental College, Belgaum, Karnataka State, India. My sincere thanks are also due to Dr S. K. Dewan, an oral surgeon from Ahmedabad, for his comments on the surgical aspects. He performed the surgical extractions for 2 of the cases described in this paper. I owe a special debt of gratitude to Dr Sheldon Peck, associate clinical professor, Department of Orthodontics, Harvard School of Dental Medicine, Boston, Mass, for his generous help in searching for, photocopying, and promptly posting some of the old articles required for the review. It would have been impossible to obtain these papers here in India. I must specially thank Drs M. Vichi, L. Franchi, and V. Bassarelli from the Institute of Odonto-Gnathostomatology, University of Florence Dental School, Italy, for sending me some of their related papers, which otherwise would have been impossible for me to get. I also owe a special debt of gratitude to Professor Paul W. Stockli, Director and Head of Orthodontic and Pediatric Dentistry, Dental School, University of Zurich, who not only sent his comments in relation to this rare anomaly but also sent radiographs and clinical notes of 2 of his patients who had transmigrated mandibular canines; Dr Robert H. Biggerstaff, Director, Undergraduate Orthodontics, the University of Texas Health Sciences Center, San Antonio, Tex, for writing his comments in relation to the possible etiology of transmigration of mandibular canines; and Prof. Thomas Rakosi, director, Department of Jaw Orthopaedics, University of Freiburg, Berlin, Germany, for his comments in relation to cephalometrics and tomographic radiography. Mention also must be made of Celia E. Giltinan, Librarian American Association of Orthodontists, St Louis, Mo, for help in sending the copies of a few articles on this subject that I had requested. Thanks are also due to Mrs Sunetra Deshpande for help in the statistical work. Lastly, I would like to extend my heartfelt thanks to my son, Sanjay, and his wife, Madhavi (both are masters in social work from MS

University, Baroda, Gujarat) for their help in getting the manuscript printed on the computer. Finally, my sincere thanks to The Angle Orthodontist, and the two reviewers who patiently read this manuscript and made suggestions to improve it and tolerated my way of writing the English language.

REFERENCES [Return to TOC](#)

1. Nodine AM. Aberrant teeth, their history, causes and treatment. *Dent Items of Interest*. 1943; 65:440–451.
2. Bennett S. Prehistoric specimen-inverted canine in mandible of a child. In: *The Dental Record*. 1931:138. Cited by: Nodine AM. Aberrant teeth, their history, causes and treatment. *Dent Items of Interest*. 1944; 66:256–265.
3. Thoma KH. *Oral Surgery*. 2nd ed. St. Louis, Missouri: CV Mosby; 1952.
4. Howard RD. The anomalous mandibular canine. *Br J Orthod*. 1976; 3:117–119.
5. Broadway RT. A misplaced mandibular permanent canine. *Br Dent J*. 1987; 163:257–258.
6. Shapira Y, Mischler W, Kuftinec MM. The displaced mandibular canine. *J Dent Child*. 1982; 49:362–364.
7. Mitchell L. Displacement of a mandibular canine following fracture of the mandible. *Br Dent J*. 1993; 174:417–418.
8. Greenberg S, Orlian A. Ectopic movement of an unerupted mandibular canine. *J Am Dent Assoc*. 1976; 93:125–128.
9. Gadalla GH. Mandibular incisor and canine ectopia: a case of two teeth erupted in the chin. *Br Dent J*. 1987; 163:236
10. Stafne EC. Malposed mandibular canine. *Oral Surg Oral Med Oral Pathol*. 1963; 16:1330
11. Fiedler LD, Alling CC. Malpositioned mandibular right canine: report of a case. *J Oral Surg*. 1968; 26:405–406.
12. Al-Wahedi EMH. Transmigration of unerupted mandibular canines: a literature review and a report of five cases. *Quintessence Int*. 1996; 27:27–31.
13. Black SL, Zallen RD. An unusual case of tooth migration. *Oral Surg*. 1973; 36:607–608.
14. Barnett DP. An unusual transposition. *Br J Orthod*. 1977; 4:149
15. Sofat JR. Maleruption of mandibular canine. *J Indian Dent Assoc*. 1983; 55:111–112.
16. Kerr WJS. A migratory mandibular canine. *Br J Orthod*. 1982; 9:111–112.
17. Rohrer A. Displaced and impacted canines. *Int J Orthod Oral Surg*. 1929; 15:1002–1004. Cited by: Javid B. Transmigration of impacted mandibular cuspids. *Int J Oral Surg*. 1985;14:547–549.
18. Javid B. Transmigration of impacted mandibular cuspids. *Int J Oral Surg*. 1985; 14:547–549.
19. Zvolanek JW. Transmigration of an impacted mandibular canine III. *Dent J*. 1986; 55:86–87.
20. Bruszt P. Neurological anomaly associated with extreme malposition of a mandibular canine. *Oral Surg Oral Med Oral Pathol*. 1958; 11:89–90.
21. Tarsitano JJ, Wooten JW, Burditt JT. Transmigration of nonerupted mandibular canines, report of cases. *J Am Dent Assoc*. 1971; 82:1395–1397.
22. Dhooria HS, Sathawane RS, Mody RN, Sakharde SB. Transmigration of mandibular canines. *J Indian Dent Assoc*. 1986; 58:348–351.
23. Joshi MR, Daruwala NR, Ahuja HC. Bilateral transmigration of mandibular canines. *Br J Orthod*. 1982; 9:57–58.
24. Ando S, Aizawa K, Nakashima T, Sanka Y, Shimbo K, Kiyokawa K. Transmigration process of the impacted mandibular cuspid. *J Nihon Univ Sch Dent*. 1964; 6:66–71.
25. Joshi MR, Shetye SB. Transmigration of mandibular canines: a review of literature and report of two cases. *Quintessence Int*. 1994; 25:291–294.
26. Caldwell JB. Neurological anomaly associated with extreme malposition of a mandibular canine. *Oral Surg Oral Med Oral Pathol*. 1955;

27. O'Carrol MK. Transmigration of mandibular right canine with development of odontoma at its place. *Oral Surg Oral Med Oral Pathol.* 1987; 57:349
28. Abbot DM, Svirasky JA, Yarborough BH. Malposition of the permanent mandibular canine. *Oral Surg Oral Med Oral Pathol.* 1980; 49:97
29. Sutton PRN. Migration and eruption of nonerupted teeth, a suggested mechanism. *Aust Dent J.* 1969; 14:269–270.
30. Joshi MR, Bhatt NA. Canine Transposition. *Oral Surg Oral Med Oral Pathol.* 1971; 31:49–53.
31. Pratt RJ. Migration of canine across the mandibular mid-line. *Br Dent J.* 1969; 126:463–464.
32. Vichi M, Franchi L, Bassarelli V. Contributo clinico sulla trasmigrazione del canino inferiore permanente. *Minerva Stomatol.* 1991; 40:579–589. and the Transmigration of the Mandibular Permanent Canine poster presented at the 68th EOS Congress, Venice-Lido, Italy, June 1992.
33. Wertz RA. Transmigrated mandibular canines. *Am J Orthod Dentofacial Orthop.* 1994; 106:419–427.
34. Kaufman AY, Buchner A. Transmigration of mandibular canine. *Oral Surg Oral Med Oral Pathol.* 1968; 26:405–406.
35. Heiman GR, Biven G. Transmigrated or malposed mandibular cuspid. *Oral Surg Oral Med Oral Pathol.* 1973; 35:567
36. Miranti R, Levbarg M. Extraction of a horizontally transmigrated impacted mandibular canine: report of a case. *J Am Dent Assoc.* 1974; 88:607–610.
37. Hebda TW. Transposed mandibular canine. *Oral Surg Oral Med Oral Pathol.* 1980; 50:197
38. Zvolanek JW, Spotts TM, Kopperud WH. A transmigrated mandibular cuspid. *Dent Radiog Photog.* 1981; 54:38–39.
39. Nashashibi IA, Shalhoub SA. The transmigration of the lower mandibular canine. *Odontostomatol Trop.* 1984; VII:39–43.
40. Vaskova Von J, Markova M. Extreme Dystopie von Eckzähnen oder Prämolaren im Unterkiefer bedingt durch intraosseele Migration. *Zahn-Mund-u Kieferheilkd.* 1984; 72:673–678. Cited by: Vichi M, Franchi L. Contributo Clinico Sulla Trasmigrazione del canino inferiore permanente. *Minerva Stomatol.* 1991;40,579–589.
41. Jalili VP. Extreme medial and distal migration of mandibular canines. *J Indian Dent Assoc.* 1986; 58:9
42. Ripari M, Maggiore C, Perfetti G, Ferraro E. Migrazione intraossea di un canino mandibolare ritenuto. *Attul Dent.* 1988; 4:942–945. Cited by: Vicchi M, Franchi L. Contributo clinico sulla trasmigrazione del canino inferiore permanente. *Minerva Stomatol.* 1991;40:579–589 (and poster presented at 68th EOS Congress, Venice-Lido, Italy, June 1992).
43. Shanmuhasuntharam P, Boon LC. Transmigration of permanent mandibular canines. Case report. *Aust Dent J.* 1991; 36:209–213.
44. Kharbanda OP, Choudhuri AR. Extreme transmigration of mandibular cuspid: report of two cases. *J Clin Pediatr Dent.* 1994; 18:307–308.

TABLES [Return to TOC](#)

TABLE 1. Chronological Resume of Transmigratory Mandibular Canines Observed by Various Authors^a

Author, Year	Ca- nine	Position of the Transmigrated Canine	Erupted or Impacted	Overretained Deciduous Canine	Age of Patient (y)	No. Cases	Sex	Associated Pathology or Remarks
Thoma, 1952	NM	Mesial of first premolar	I	NM	NM	1	NM	Cyst
Caldwell, 1955	R	Below distal root of left first molar	I	NM	31	1	F	—
Bruszt, 1958	L	Up to R Canine	E (labial)	CE	NM	1	F	—
	R	Up to L Canine	E (labial)	CE	NM	1	F	—
Stafne, 1963	NM	Below canine of opposite side	I	NM	NM	1	NM	—
Ando et al, 1963	R	Followed up till the canine reached other side below apex of first premolar	I	CE	6-12	1	M	Follow up for 6 y
Kaufman & Buchner, 1967	R	Up to left canine	E (labial)	NM	19	1	F	—
Fiedler & Alling, 1968	R	Below the root apex of L first premolar	I	CR	16	1	F	—
Pratt, 1969	R	Near mesial surface of left canine	E (labial)	CR	19	1	M	—
Tarsitano et al, 1971	L	Below R mental foramen (3 canines)	I	2 CR, CE	...	3	NM	—
Heiman, 1973	L	Up to right canine	I	CR	30	1	F	—
Black & Zallen, 1973	L	Impacted below R canine	I	CR	23	1	M	—
Miranti et al, 1974	R	Below apex of L anterior teeth	I	CR	17	1	F	—
Greenberg et al, 1976	L	Up to root apex of R canine	I	NM	8	1	M	—
Howard, 1976	L	Two below R central incisor	I					
		Three below R lateral incisor	I	2 CR, 6 CE	10-20	5	6F, 2 M	—
	R	One below L canine	I		...	3	...	—
		Two below L first premolar	I					
Barnett, 1977	L	Up to R canine	E (labial)	CE	24	1	F	Asian woman
Abbot et al, 1980	R	Between the L canine and lateral incisor	E (labial)	CR	62	1	F	—
Hebda, 1980	L	Up to R canine	I	NM	21	1	M	—
Zvolanek et al, 1981	L	Beneath the mesial root of first molar	I	NM	31	1	F	—
Joshi et al, 1982	B	Up to lateral incisors	I	1 CR, 1 CE	19	1	M	Indian Boy. Bilateral reported for the first time
Shapira et al, 1982	L	Up to lingual surface of R lateral incisor	E (lingual)	NM	20	1	F	—
	R	Up to L canine root	I	NM	11	1	M	—
	R	Up to canine root on left	I	NM	13	1	F	Odontoma present
Kerr, 1982	R	Up to lateral incisor root	I	CR	9	1	F	—
Sofat, 1983	R	Between the two central incisors	E	CR	20	1	M	Indian Boy
O'Carrol, 1984	R	Below left canine and first premolar root	I	CR	28	1	F	Odontoma present
Nashashibi et al, 1984	L	As far as R lateral incisor root	I	NM	19	1	M	—
	R	As far as mesial of left canine	I	NM	24	1	M	—
Vaskova et al, 1984	R	Up to the left lateral incisor	I	CR	14	1	NM	—
Javid, 1985	NM	Up to first permanent molar	I	9 CE, 1 CR	13-52	10	6 F, 4 M	8 unilateral, no pathology 2 unilateral chronic intraoral Fistula
	B	NM	I	2 CE, 1 CR	...	3	2 F, 1 M	1 Bilateral chronic, intraoral Fistula 2 bilateral, no pathology
Jalili, 1986	B	R and L canines lying between the apices of central incisors	I	1 CE, 1 CR	16	1	M	—
Zvolanek, 1986	L	Ecotopically migrating across the midline	I	NM	25	1	F	—
Dhooia et al, 1986	R	Reached left mental foramen, follow-up after 1 y and showed further movement by 3-4 mm	I	NM	17	1	F	—

TABLE 1. Continued

Author, Year	Ca- nine	Position of the Transmigrated Canine	Erupted or Impacted	Overretained Deciduous Canine	Age of Patient (y)	No. Cases	Sex	Associated Pathology or Remarks
Broadway, 1987	L	Erupted labially to right central incisor	E (labial)	CR	19	1	M	—
	R	Crown tip reached mesial of left canine root	I	CR	22	1	M	—
	L	Horizontally positioned, tip of crown migrated up to R second premolar	I	CR	15	1	F	—
Gadalla, 1987	L	Crown erupted extraorally inverted position through the chin on R side	EO E	CE	22	1	F	—
Ripari et al, 1988	L	Reached right canine root	I	CR	9	1	M	—
Vichi Franchi, 1991	R	Left central incisor root	I	CR	10	1	F	—
	R	Left central incisor root	I	CR	11	1	M	—
	L	Right central incisor root	I	CR	12	1	F	—
	R	Left central incisor root	I	CR	13	1	M	—
	L	Left central incisor root	I	CR	13	1	F	—
	R	Mandibular left central incisor root	I	CR	16	1	F	—
	L	Up to root of right lateral incisor	I	CR	10	1	F	—
	R	Up to root of left lateral incisor	I	CR	13	1	M	—
	L	Up to root of right central incisor	I	CR	14	1	F	—
	R	Traveled up to left second premolar root	I	CR	40	1	F	—
L	Traveled up to right first premolar root	I	CE	42	1	F	—	
R	Transmigrated and erupted near left lateral incisor	E	CE	29	1	F	—	
L	Up to central incisor root of right side	I	CE	25	1	F	—	
B	R canine reached left lateral incisor and left canine reached R central incisor root	I	CE	40	1	F	—	
Shanmuhsuntharam & Boon, 1991	R	Left lateral incisor root	I	NM	20	1	F	Chinese female
	L	Below apices of right incisors	I	NM	52	1	M	Odontoma, Chinese male
Mitchel, 1993	L	Below right incisor root	I	CR	13	1	M	Fracture of mandible at early age as etiology
Joshi & Shetye, 1994	R	Below left first permanent molar roots	I	CR	14	1	F	—
Wertz, 1994	L	Below right incisor root	I	CE	14	1	F	—
	L	Apex at left central incisor root	I	CR	12	1	M	Cyst
	L	Apex at right central incisor root	I	CR	12	1	F	—
R	Apex at left central incisor root	I	CR	9	1	F	—	
R	Apex at right central incisor root	I	NM	13	1	M	—	
Kharbanda et al, 1994	L	Below root tip of right canine	I	...	11	1	M	—
	L	Below right first premolar root	I	CR	12	1	F	—
Al-Wahedi, 1994	B	One above other in horizontal position, right canine traveled more left	I	CR	15	1	F	—
	L		I	CR	15	1	F	Cyst
	L	Under the apex of right lateral incisor	I	CE	9	1	F	—
	L	Under apex of right central incisor	I	NM	13	1	F	Cyst

TABLE 1. Continued

Author, Year	Ca- nine	Position of the Transmigrated Canine	Erupted or Impacted	Overretained Deciduous Canine	Age of Patient (y)	No. Cases	Sex	Associated Pathology or Remarks
	L	Reached apex of right lateral incisor Parallel and near the mandibu- lar border	I	NM	20	1	F	Cyst

^a R indicates right; L, left; B, bilateral; I, impacted; E, erupted; M, male; F, female; EO extraoral eruption; CR, deciduous canine overretained; CE, deciduous canine exfoliated; and NM, not mentioned.

TABLE 2. Clinical Features of Transmigrated Mandibular Canines Observed in The Present Collection of 28 Patients^a

Pa- tient No.	Age, y	Canine	Position of the crown of the Transmigrated Canine	Eruption Status	Overretained Deciduous Canine	Sex	Associated Pathology
1	20	L	Up to the right side canine root	I	Yes	F	None
2	13	R	Mirror-image position on left	E	No	F	None
3	12	B	Up to middle third of crown	I	No, No	M	Cyst
4	15	R	Up to the mesial side of left lateral incisor root	I	Yes	M	Cyst
5	13	L	Up to root apex of right central incisor	I	No	F	Odontoma
6	19	L	Up to the mesial root of right canine	I	No	F	None
7	17	B	Right canine more horizontal and more migrated than left	I	Yes, Yes	F	None
8	9	L	Up to mesial of right lateral incisor root	I	No	F	None
9	11	L	Near the root tip of right lateral incisor	I	Yes	F	None
10	15	L	Crown tip reached the right canine root	I	Yes	M	None
11	14	L	Up to root tip of mandibular second premolar	I	Yes	M	None
12	23	L	Tip of canine up to mesial root of right first permanent molar	I	No	F	None
13	20	R	Up to the mesial root surface of left canine	I	Yes	F	None
14	14	R	Labial horizontal position up to left canine mesial side	I	Yes	F	None
15	17	B	Right and left canines in crisscross position crossing the midline	I	Yes, No	F	None
16	18	L	Up to mesial of right canine root	I	Yes	F	None
17	22	R	Up to the mesial side of left canine	I	No	M	None
18	17	R	Up to the mesial of left lateral root	I	Yes	F	None
19	12	R	Tip of canine just crossed the midline	I	No	M	Cyst
20	21	L	Just crossed root apex of right lateral incisor	I	Yes	M	Cyst
21	13	L	Just under the root tip of right canine	I	Yes	F	Cyst
22	11	R	Touching root apex of left lateral incisor	I	Yes	M	None
23	12	R	Touching root apex of left central incisor	I	Yes	F	None
24	13	L	Reached mesial root surface of right canine	I	Yes	M	Cyst
25	13	L	Reached mesial root of right canine	I	Yes	F	Cyst
26	10	L	Reached mesial of right lateral incisor	I	Yes	F	None
27	12	L	Reached mesial surface of right canine	I	Yes	M	None
28	12	B	Right and left rotated with their labial surface towards mandibular border, right moved more than left	I	Yes, Yes	F	Cyst

^a R indicates right; L, left; B, bilateral; I, impacted; E, erupted; M, male; and F, female.

TABLE 3. Comparison of Clinical Features of Transmigrated Mandibular Canines Observed by Earlier Authors With Those From the Present Study on 28 Patients

Variable	Earlier Reports (n = 39)	% Value of Earlier Reports	Actual Number of Bilateral Cases ^c	Present Study	% Value of Present Study	Actual Number of Bilateral Cases ^c
No. of cases						
Unilateral	82	92.1	...	24	85.7	...
Bilateral	7	7.9	7	4	14.3	4
Side of canine						
Not recorded	12	14.6
Right	31	37.8	...	9	37.5	...
Left	39	47.6	...	15	62.5	...
Bilateral	7	4
Eruption status						
Impacted	71	86.6	7	23	95.8	4
Erupted	11 ^a	13.4	Nil	1 ^b	4.2	Nil
Age range, y	9–42	9–23
Sex						
Female	50	60.9	4	18	64.3	3
Male	26	31.7	3	10	35.7	1
Not recorded	6	7.4
Overretained deciduous cuspid						
Yes	36	43.9	4	17	70.8	5
No	27	32.9	4	7	29.2	3
Not recorded	19	23.2	3
Associated pathology						
Yes	12	15.9	2	7	15.9	2
No	70	84.1	5	17	84.1	2

^a Of these 11 erupted teeth, 9 were labial, 1 lingual, and 1 extraoral.

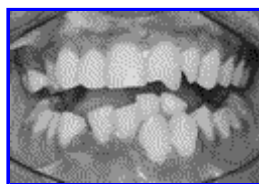^b The single erupted tooth was in the labially mirror image position.

^c % value not calculated because there were very few cases.

TABLE 4. Statistical Evaluation of the Observations Between the Findings of the Present Study and Those of Earlier Investigators

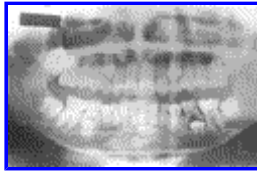No.	Eruption Status	Pearson Chi-Square Value	Degrees of Freedom	95% Confidence Interval of Difference, Lower, Upper		Difference
1	Impacted, erupted, both impacted, extraoral eruption	2.594	3	1.03	1.54	Not significant
2	Overretained deciduous cuspid	11.266	5	1.18	1.96	Not significant
3	Position of cuspid: right, left, bilateral, not mentioned	5.193	3	1.30	1.55	Not significant
4	Males, females not mentioned	1.995	2	1.17	1.55	Not significant
5	Associated pathology, no or yes	5.036	1	1.14	1.57	Not significant

FIGURES [Return to TOC](#)



Click on thumbnail for full-sized image.

FIGURE 1. (Case 1) Photograph of the patient's teeth, showing the right mandibular canine erupted in the mirror-image position with its counterpart on the left side



Click on thumbnail for full-sized image.

FIGURE 2. (Case 28) Female patient, 12 years old, OPG showing bilateral canine transmigration under the incisor's roots. The right canine migrated more than left and is lying more parallel and near the mandibular border. The labial surfaces of both canines are facing the mandibular border. Both canines are impacted and have cystic lesions around them. Right and left deciduous canines are overretained

^aPrivate practice, Gujarat State, India. Formerly Professor and Head of Orthodontics Department, Government Dental College and Hospital, Ahmedabad, India.

Corresponding author: M. R. Joshi, MDS, 102 Mansi Apartments, Opp. Gurukul, Memnagar, Ahmedabad-380 052, Gujarat State, India (E-mail: smjoshi@wilnetonline.net).