

[\[Print Version\]](#)

[\[PubMed Citation\]](#) [\[Related Articles in PubMed\]](#)

## TABLE OF CONTENTS

[\[INTRODUCTION\]](#) [\[CASE REPORT\]](#) [\[DISCUSSION\]](#) [\[REFERENCES\]](#) [\[FIGURES\]](#)

*The Angle Orthodontist*: Vol. 70, No. 4, pp. 332-338.

# Class II Correction with the Modified Sagittal Appliance and Maxillary Second Molar Extraction

Aynur Aras, DMD, PhD

## ABSTRACT

The aim of this article is to describe the clinical use of the removable sagittal appliance combined with the use of a J-hook headgear. This technique was used to distalize the buccal segments following maxillary second molar extraction in the treatment of a Class II patient with labially positioned maxillary canines. The sagittal appliance was used full-time and the headgear was worn 10 to 12 hours per day. This proved to be an effective method for distalizing the maxillary buccal teeth without flaring of the anterior teeth.

**KEY WORDS:** Class II treatment, J-hook headgear, Second molar extraction, Sagittal appliance.

Accepted: February 2000. Submitted: November 1999.

## INTRODUCTION [Return to TOC](#)


The sagittal appliance, which is a variation of the Y-Plate, has been used to open space for slightly crowded canines or anterior teeth with or without the extraction of maxillary second molars.<sup>1-7</sup> The anterior crowding is relieved by distal movement of the posterior teeth, facial movement of the anterior teeth, or both, depending on the presence and amount of eruption of the second molars.<sup>2,4,6</sup> It has been reported that, if the second molars are extracted, the action of the appliance will be in a distal direction.<sup>2,4,6</sup>


Even when the second molars are extracted, however, the use of the sagittal appliance often results in facial movement of the maxillary teeth and a resulting increase in overjet. This is particularly true in patients with a shallow palate. Therefore, in order to better control anchorage, the use of the J-hook headgear was combined with the sagittal appliance.

This article describes the use of the combination of a sagittal appliance and J-hook headgear to achieve distal movement of maxillary buccal segments without resultant flaring of anterior teeth in a patient following extraction of the maxillary second molars.

## CASE REPORT [Return to TOC](#)

A 13-year-old girl was referred with the chief complaint of facially protruding maxillary canines. The patient had a symmetrical face and a


balanced profile. Both maxillary canines were positioned labially and the mandibular anterior segment was mildly crowded. The maxillary dental midline was shifted 2 mm to the left and the molar relationship was a full Class II on the right and half a Class II on the left. The arch perimeter deficiency was measured as 9 mm in the maxilla and 1.5 mm in the mandible. The overjet was 2.5 mm and the overbite 1.5 mm ([Figure 1a-c](#) )


Measurements of the lateral cephalogram showed a mild skeletal Class II relationship ( $ANB = 4^\circ$ ) with a retrognathic maxilla ( $SNA = 76^\circ$ ) and mandible ( $SNB = 72^\circ$ ) and a slightly vertical growth pattern ( $SNGoGn = 37^\circ$ ). The maxillary incisors had good axial inclination ( $1-SN = 102^\circ$ ), but the mandibular incisors were protruded ( $IMPA = 98^\circ$ ). The panoramic radiograph confirmed the presence of maxillary third molars with good anatomical shape and a slight distoangular inclination ([Figure 2](#) )

The treatment objectives included:

1. Extraction of maxillary second molars to facilitate distal movement of the posterior teeth.
2. Distalization of maxillary first molars and premolars to Class I relationship.
3. Alignment of the maxillary canines and incisors with correction of the maxillary midline.
4. Stripping of mandibular anterior teeth.
5. Extraction of mandibular third molars at the appropriate time.

A sagittal appliance<sup>3,6</sup> was chosen for the distalization of buccal segments to a Class I relationship, but it was decided that the sagittal appliance should be used in combination with J-hook headgear to prevent facial movement of the anterior teeth and anchorage loss. Therefore, the labial bow of the sagittal appliance was modified accordingly.

The sagittal appliance was constructed with distalizing screws placed parallel to the buccal teeth and the acrylic portion extended over a broad area to maximize the anchorage. The occlusal surfaces of all maxillary buccal segment teeth were covered with acrylic to minimize tipping and to prevent occlusal interferences during their distal movement ([Figure 3a](#) )


A J-hook headgear was applied to the sagittal appliance as recommended for removable appliances with palatal finger springs.<sup>8</sup> Anteriorly, a short labial bow was used with spurs soldered to the labial bow for attachment of the J hooks of the headgear ([Figure 3b](#) )


Note: The labial bow can be covered with acrylic to increase retention if needed. The J hooks extended from the labial bow to the C plate of an Interlandi headgear. The J hooks were positioned to allow the line of force to pass through the center of resistance of the maxilla. The appliance was adjusted to exert approximately 100 gr of force per side. A number 19 "J" hook Tract-A-Tube (Orthobond Co, P.O. Box 278, Barnhart, MO 63012-0278) offered a safety feature since it must be detached before the appliance can be removed from the patient.


The sagittal appliance was worn full-time except for eating and brushing while the J-hook headgear was worn 10 to 12 wear hours per day. The sagittal appliance was activated by turning the screws a quarter rotation every 4 days in the evenings.


Patient cooperation was very good. A Class I relationship was achieved in 5 months and no increase in overjet was observed. Treatment was continued for 5 months with .018 inch Roth straightwire appliances.

While the fixed appliance therapy was continued in the upper jaw, a positioner was used to align the mildly crowded mandibular incisors. The lower incisors were interproximal reduced, and an impression obtained. The mandibular incisors were set in a proper alignment on a laboratory cast prior to fabricating the positioner. The positioner was made from a 2.5-mm-thick Bioplast sheet. After 2 months of positioner use, a removable mandibular retainer with occlusal rests on the distal aspect of the mandibular second molars was delivered.

The 10 month active treatment in the upper jaw was followed by 6 months of retention with a Hawley appliance ([Figure 4a-c](#) )

Eighteen months after retention in the upper jaw, the results remained stable, and the third molars had erupted forward into the second molar extraction spaces. The unerupted mandibular third molars were later removed surgically ([Figure 5](#) )

Lateral headfilm superimpositions showed good control of the maxillary incisor position ([Figure 6](#) )

Also, OPG radiograph and lateral headfilm superimpositions reveal that the tipping of the buccal teeth was insignificant after the distalization ([Figures 5 and 6](#) )

## DISCUSSION [Return to TOC](#)

The decision to extract or not to extract in patients with crowded teeth requires a thorough consideration of several factors. If extractions are an option, which teeth should be chosen for extraction? Should all first premolars, maxillary first premolars only, or second molars be extracted? What will be the effects of extractions on the length of treatment, the facial profile and the occlusal function. What will be the stability of the results? The direction and magnitude of facial growth, the eruption path of the third molars, and expected patient cooperation should be considered.<sup>5,9</sup>

The first prerequisite for the extraction of the maxillary second molars, is the radiographic confirmation of the presence of the third molars with good position and anatomy. A third molar with a slight distoangular position is ideal.<sup>10</sup> The optimum time for extraction of the maxillary second molar is when the third molar has reached the root-crown junction of the second molar<sup>10</sup> or the calcification of the crown of the third molar is nearly complete.<sup>11</sup> The present case had a Class II malocclusion with well-formed and ideally positioned third molars, a straight profile, labially placed maxillary canines, and a mildly crowded mandibular arch. Therefore, this patient was a good candidate for second molar extraction treatment.

In treatment with maxillary second molar extractions, the Class II relationship of the first molars can be corrected with a cervical headgear. Continued wearing of headgear wear is recommended until the premolars have drifted distally.<sup>9,10,12</sup> Harnick<sup>13</sup> suggested the use of full fixed appliances in the maxillary and mandibular arches with a distalizing arch and Class II elastics. Distal movement of all buccal teeth, however, can also be achieved by extraoral traction applied to a maxillary removable appliance.<sup>14</sup> Further distal movement of the buccal segments with a removable sagittal appliance alone has been reported.<sup>2,4,6</sup>

In clinical practice there is a danger of the sagittal appliance moving the anterior segment forward, particularly in patients with shallow palates. To prevent this we elected to add headgear. As demonstrated by the patient presented in this paper, the sagittal appliance supported by headgear distalized the molars and the premolars together with no facial movement of the anterior teeth. As with other treatment techniques, maximum patient cooperation was essential to achieve the desired treatment goals.

Since moving the maxillary first molars into the extraction spaces of the second molars increased the inter-maxillary angle and, in turn, reduced the overbite, patients with a horizontal growth pattern have better results.<sup>10,12,15</sup> In the patient presented here, there was no marked increase in the inter-maxillary angle after the distalization of upper buccal segments. Therefore, if the maxillary first molars can be distalized with minimal tipping, we conclude that maxillary second molar extraction treatments did not affect the vertical dimensions significantly in this patient. However, it should be stressed that extraction of maxillary second molars is not advocated in severe hyperdivergent patients.

There is some controversy over whether the extraction of maxillary second molars results in unopposed and overerupted mandibular second molars. When a Class I relationship is established for the first molars, there is contact between the maxillary first molar and the mesial aspect of the mandibular second molar which would prevent its overeruption.<sup>10</sup> However, Smith<sup>16</sup> stated that the sagittal position of the maxillary first molar prevents the overeruption of the mesial part of the mandibular second molar only. According to Liddle,<sup>17</sup> presence of mandibular third molars increases this overeruption. As a preventive measure, the patient presented here used a mandibular retainer every night, consisting of a removable appliance with occlusal rests on the distal aspect of the mandibular second molar.

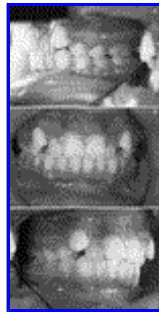## REFERENCES [Return to TOC](#)

1. Schwarz AM, Gratzinger M. *Removable Orthodontic Appliances*. Philadelphia, Penn: WB Saunders Co. 1966; :103
2. Chan WB, Tsamtsouris A, Saadia AM. The sagittal appliance. *J Pedod*. 1982; 7:18–35. [[PubMed Citation](#)]
3. Graber TM, Neumann B. *Removable Orthodontic Appliances*. 2nd ed. Philadelphia, Penn: WB Saunders Co. 1984; :45–49.
4. Ahlin JH, White GH, Tsamtsouris A, Saadia M. *Maxillofacial Orthopedics: A Clinical Approach for the Growing Child*. Chicago, Ill: Quintessence Publishing Company Inc. 1984; :156–162.
5. Bishara SE, Burkey PS. Second molar extractions: a review. *Am J Orthod*. 1986; 8:415–424.
6. Witzig JW, Spahl TJ. *The Clinical Management of Basic Maxillofacial Orthopedic Appliances. Volume II: Diagnostics*. Littleton MASS. PSG Publishing Company Inc. 1989; :538–584.
7. Enacar A, Demirhanoglu M, Özgen M. Dentofacial effects of maxillary sagittal appliance. *Turkish J Orthod*. 1993; 6:1–6.
8. Lewis DH, Fox NA. Distal movement without headgear: the use of an upper removable appliance for the retraction of upper first molars. *Br J Orthod*. 1996; 23:305–312. [[PubMed Citation](#)]
9. Basdra EK, Stellzig A, Komposch G. Extraction of maxillary second molars in the treatment of Class II malocclusion. *Angle Orthod*. 1996; 66:287–292. [[PubMed Citation](#)]
10. Magness WB. Extraction of second molars. *J Clin Orthod*. 1986; 20:519–522. [[PubMed Citation](#)]
11. Quinn GW. Extraction of four second molars. *Angle Orthod*. 1985; 55:58–69. [[PubMed Citation](#)]
12. Basdra EK, Komposch G. Maxillary second molar extraction treatment. *J Clin Orthod*. 1994; 28:476–481. [[PubMed Citation](#)]

13. Harnick DJ. Case report: Class II correction using a modified Wilson bimetric distalizing arch and maxillary second molar extraction. *Angle Orthod.* 1998; 68:275–280. [[PubMed Citation](#)]
14. Orton HS, Battagel JM, Ferguson R, Ferman AM. Distal movement of buccal segments with the “en masse” removable appliance—its value in treating patients with mild Class II, Division 1 malocclusions: Part I, clinical techniques (how to do it). *Am J Orthod Dentofacial Orthop.* 1996; 109:234–243. [[PubMed Citation](#)]
15. Jarabak JR, Fizzell JA. *Technique and Treatment with Light-Wire Edgewise Appliances.*. St. Louis, Mo: CV Mosby Co. 1972; :606–611.
16. Smith R. The effect of extracting upper second permanent molars on lower second permanent molar position. *Br J Orthod.* 1996; 23:109–114. [[PubMed Citation](#)]
17. Liddle DW. Second molar extraction in orthodontic treatment. *Am J Orthod.* 1977; 72:599–616. [[PubMed Citation](#)]

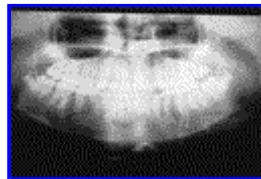
---

**FIGURES** [Return to TOC](#)



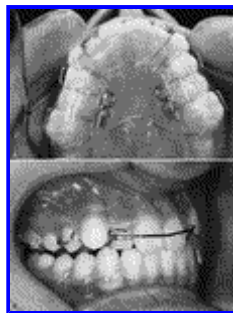Click on thumbnail for full-sized image.

**FIGURE 1.** (a–c) Pretreatment photographs



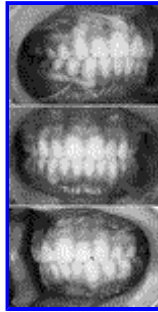Click on thumbnail for full-sized image.

**FIGURE 2.** Pretreatment orthopantomograph [OPG radiograph]



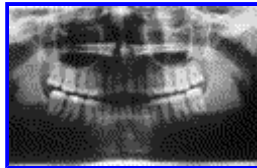Click on thumbnail for full-sized image.

**FIGURE 3.** (a) Sagittal appliance in site. (b) Labial bow with spur to allow attachment of J hook



Click on thumbnail for full-sized image.

**FIGURE 4.** (a–c) End of treatment photographs



Click on thumbnail for full-sized image.

**FIGURE 5.** Orthopantomograph of 18 months after upper retention



Click on thumbnail for full-sized image.

**FIGURE 6.** Tracings of cephalometric radiographs superimposed (S–N at S) showing the distalization of the teeth in the buccal segments

Department of Orthodontics, Faculty of Dentistry, Ege University, Izmir, Turkey.

Corresponding author: Aynur Aras, DMD, PhD, Ege Üniversitesi Dişhekimliği Fakültesi, Ortodonti Anabilim Dalı, Bornova 35100, İzmir, TURKEY (E-mail: [aynuraras@yahoo.com](mailto:aynuraras@yahoo.com)).