

[\[Print Version\]](#)  
[\[PubMed Citation\]](#) [\[Related Articles in PubMed\]](#)

TABLE OF CONTENTS

[\[INTRODUCTION\]](#) [\[CASE PRESENTATION\]](#) [\[TREATMENT APPROACH\]](#) [\[DISCUSSION\]](#) [\[CONCLUSION\]](#) [\[REFERENCES\]](#) [\[TABLES\]](#) [\[FIGURES\]](#)

*The Angle Orthodontist*: Vol. 70, No. 4, pp. 339-348.

## Orthodontic Correction of a Transposed Maxillary Canine and Lateral Incisor

Francisco Ajalmar Maia, DDS, MS, PhD<sup>a</sup>

### ABSTRACT

Tooth transposition presents a major challenge in the correction of a malocclusion. A dental transposition is an uncommon disturbance affecting 0.4% of the population, yet the treatment difficulties make this anomaly an occurrence of orthodontic interest and a source of clinical interest. This case report shows the unilateral transposition of a maxillary canine with a lateral incisor that was treated by orthodontically reversing the transposed tooth positions. An analysis of the clinical concerns in the treatment of this problem is presented.

**KEY WORDS:** Transposition, Tooth transposition, Dental transposition.

Accepted: October 1999. Submitted: March 1999.



### INTRODUCTION [Return to TOC](#)




Dental transposition is a developmental alteration resulting in a deviation in tooth position, clinically identified as the interchange of 2 adjacent teeth, that alters the natural order of the dental arch.<sup>1-3</sup> The canine is one of the most commonly involved teeth in the transposition phenomenon, changing its eruptive place with the lateral incisor or the first premolar in most cases.<sup>4-7</sup> Canine transposition has a maxillary predilection and is generally associated with other anomalies, such as agenesis (40%), deciduous canine retention (50%), and peg-shaped maxillary lateral incisors (25%).<sup>1,8-11</sup> Unilateral canine transposition happens more frequently (79%), and the left side is more commonly affected (69%).<sup>1,12-14</sup> Bilateral transposition has been reported in 5% of the cases.<sup>2</sup> Usually the canine assumes a vestibular position when in transposition with either the lateral incisor or the first premolar;<sup>4</sup> however, it can be seen in a palatal position in some cases.<sup>15</sup>

Many articles have been published on the transposition of the maxillary canine and lateral incisor.<sup>6,7,14,16,17</sup> In 1995, Peck and Peck<sup>2</sup> stated that 20% of the transpositions in the maxillary arch involve the canine and the lateral incisor, a type of transposition which was first reported in 1817 by Miel.<sup>18</sup> This kind of transposition results principally from dentofacial trauma in the deciduous dentition and subsequent permanent tooth drift,<sup>2,19-21</sup> although a genetic basis for some occurrences cannot be totally excluded.<sup>3, 21-23</sup> A review of the pertinent literature shows that the cause of transposition remain unclear, although early loss or retention of primary canines,<sup>24,25</sup> the transposition of the analog of the teeth during odontogenesis, migration of a tooth away from its normal path of eruption,<sup>4,21</sup> and heredity are the factors most often cited.<sup>1,19</sup> Shapira<sup>14</sup> presented the only case in the literature of an orthodontically corrected maxillary canine and lateral incisor.

In this article, a case is presented to demonstrate complete transposition of the maxillary left canine and the left lateral incisor. An unconventional orthodontic approach to treatment was used to accomplish the desired correction.

### CASE PRESENTATION [Return to TOC](#)

The patient was a girl who was 10 years and 10 months old. She had her permanent teeth and was in good health ([Figure 1](#) ). Her chief complaint was mild crowding in the lower arch and a tooth malposition in the upper arch. The clinical and radiographic examinations defined the malposition of the upper left canine and upper left lateral incisor as a transposition ([Figure 2](#) ). She had a Class II canine and molar relationship on the right side, crowding and transposition of the upper left lateral incisor and canine, and a 5-mm deviation of the dental midline to the left. In addition, she had thumb-sucking and tongue-thrusting habits and a lateral open bite. The lower arch showed an arch length deficiency. Oral hygiene was good, and the periodontium was healthy, with adequately attached gingiva. The patient's facial profile was convex with a slightly protrusive lower lip, some strain during lip closure, and a pleasant smile.

The radiographic evaluation showed a complete transposition of the upper left canine with the upper left lateral incisor. The canine was parallel to and between the left central incisor and the left lateral incisor ([Figure 2](#) ). The cephalometric radiography data showed a dolichofacial pattern and a lateral open bite, yet a nice profile ([Figure 3](#) ; [Tables 1 and 2](#) ).

### TREATMENT APPROACH [Return to TOC](#)

The treatment planning for this malocclusion involved the following: facial balance, an arch length discrepancy and cephalometric measurements, a midline correction, an open bite tendency, an esthetic aspect, and the possibility of a correction of the transposition. The facial analysis reflected a normal upper lip relationship, posture, and tonicity, but the lower lip was slightly everted and exhibited some strain during closure. Nose size and shape were normal, and the nasolabial angle appeared harmonious. The chin musculature was balanced in function and esthetics. The profile was a little convex but harmonious.

Arch length analysis showed a 6.0-mm deficiency of available arch length or tooth-bone deficiency. The cephalometric measurement ( $\bar{I} - AP = 2.5$  mm) revealed a 1.2-mm cephalometric discrepancy ([Tables 1 and 2](#)). To correct the maxillary midline, space was required in the upper arch. To eliminate the 6-mm dental size discrepancy, space was also required in the lower arch. To correct the open bite, it was necessary to change the tongue posture and the swallowing pattern. To act upon the cephalometric dolichofacial pattern ([Table 2](#)), it was important to avoid moving teeth distally to generate space to correct the molar relationship. Considering the esthetic aspect, it was very important to correct the transposition, eliminate the midline deviation, prevent an increase in the open bite, and eliminate the arch length deficiency, all without tipping the lower incisors labially and jeopardizing the facial balance and a pleasant smile. Therefore, extraction of the upper and lower first premolars was performed to make the correction of the transposed teeth possible ([Figure 4](#)), to correct the midline, to eliminate the crowding, and to bring the molars mesially to close the open bite.

Fixed 0.018- by 0.025-inch straight-wire appliances were used to treat the patient. The removal of both the upper and lower first premolars facilitated the mechanics, permitted better closure of the open bite and a more balanced face, provided space to correct the maxillary midline, and allowed reversion of the transposed teeth to their normal place in the arch. The lower arch mechanics involved leveling, alignment, and space closure. An effort was made to lose anchorage to keep the lower incisor ( $\bar{I} - AP = 2.5$  mm) in good position, supporting the lower lip in balance with the face. The treatment progression consisted of appliance placement and, after the removal of the first 4 premolars, leveling in the upper and lower arches with 0.014- to 0.018-inch round arch wires. Maxillary and mandibular 0.018- by 0.025-inch wires were inserted, and residual spaces were closed with elastomeric chains. A lingual crib was placed to change the lingual posture and avoid tongue thrust. Anterior and posterior vertical elastics were required for intercuspation. After removal of bands and brackets, a maxillary removable retainer and a mandibular lingual splint retainer (3 × 3) were placed for retention. The patient's treatment required 49 months, including 22 missed appointments.

The posttreatment results show the correction of the crowding, the transposition, and the maxillary dental midline ([Figures 5–7](#); [Tables 1 and 2](#)). The face and the smile are very pleasant. The analysis of the posttreatment records shows that the treatment objectives were achieved. The open bite was closed and the 5-mm midline deviation corrected, resulting in interarch symmetry. Facial esthetics were improved, and lip competence was obtained. Posttreatment records show a counterclockwise rotation of the mandible ([Figure 8](#); [Tables 1 and 2](#)). Comparison of the initial and posttreatment measurements ([Tables 1 and 2](#)) shows decreases in the lower face height (52.4° to 46.6°), in the mandibular plane angle (36.3° to 25.9°), and ANB (5.5° to 3.2°). The posttreatment periapical and panoramic radiographs ([Figure 7](#)) reflect normal structures in the periodontium, in the root, and in surrounding tissues. A cuspid-protected occlusion was achieved, and the functional analysis showed lateral excursive movements without balancing interferences. During protrusive movements, bilateral posterior disocclusion was observed. The treatment should have been followed by at least a 2-year retention period.

Posttreatment cephalometric measurements ([Figure 6](#)) show that the cephalometric objectives were achieved. The open bite tendency was overcome with the use of the tongue crib, and the first 4 bicuspid extractions resulted in mesial molar movement and bite closure. All of these factors improved the dolichofacial facial pattern ([Tables 1 and 2](#)).

The challenge of correcting a transposition is to accomplish it while maintaining periodontal health. The radiographic view ([Figure 7](#)) demonstrates normal alveolar contours and supports the possibility of correcting this anomaly by orthodontically reversing the transposed teeth. No sign of root resorption or any other damage to the canine or lateral incisor was seen.

The patient did not return for retention checks for 7 years following the conclusion of the treatment. Nevertheless, for the sake of publication of this case, she agreed to have a posttreatment evaluation. She confirmed never having used the upper retainer, having removed the 3 × 3 lower splint retainer, and not having had the decay treated in the upper left first molar that was present at the end of treatment. However, the result is stable, as is seen in the current records ([Figures 9–11](#)). The postretention cephalometric measurements show that the skeletal pattern remained stable and that the treatment approach and objectives were appropriate ([Tables 2 and 3](#)). Despite some relapse due to the lack of the use of retainers, the occlusion is in good esthetic and functional harmony, the face is in balance, and the smile is very pleasant. The postretention panoramic and periapical radiographs show the formerly transposed teeth in normal condition and the periodontal and surrounding tissues normal 7 years after the conclusion of treatment ([Figure 11](#)).

## DISCUSSION [Return to TOC](#)

The alternative of treating this malocclusion without extraction of maxillary and mandibular first premolars was an option; however, the extraction approach was preferred because of the dolichofacial pattern. One should avoid any kind of distalizing mechanics that would increase the open bite. Another factor favoring the extraction approach was the large maxillary midline deviation. The maxillary arch lacked space needed for correction of the midline dental shift and elimination of the dental crowding, so removal of 4 first premolars was recommended. Esthetic and occlusal considerations suggested that aligning the transposed teeth while keeping their transposed positions would be unacceptable. Therefore, the alignment to their normal positions in the arch was performed.

This case is a complete, or real, transposition because the root apex of the upper canine is mesial to the upper lateral incisor.<sup>5</sup> Because this is a real transposition with parallel roots, correction could pose serious problems of root interference and root resorption, jeopardizing the vitality of one or both teeth and damaging their supporting structures.<sup>3</sup> However, space is needed to correct the transposition teeth, and extractions make space available ([Figure 4](#)). No endodontic or periodontal problem that might discourage this treatment approach was observed, although considerable time was spent (49 months, including 22 missed appointments) to reverse, upright, and parallel the roots of the canine and lateral incisor. In this case, no irregular central incisor root<sup>2</sup> was seen, nor did the patient or parents recall any traumatic injury to the teeth before the eruption of the permanent incisors or canines.

Comparing the pre- and posttreatment records, one can see the strong counterclockwise rotation of the mandible ([Tables 1 and 2](#)). The facial axis angle increased (84.4° to 90.2°), and the lower facial height and the mandibular plane angle decreased (52.4 % to 46.6% and 36.3° to 25.9°, respectively). This is an extraordinary amount of change (10.4°) to occur with just the extraction of first bicuspids. It raises the question of whether the pretreatment radiograph was made with the teeth in occlusion. In fact, closer observation shows that the teeth were apart in the pretreatment radiograph, and the slight opening influenced about 2° to 3° on the recorded rotation. One must remember that the patient's first premolars were extracted and the spaces closed with anchorage loss. In addition, the patient abandoned the thumb sucking habit, and the swallowing thrust reflex was normalized with a lingual crib. All of these factors are favorable for helping to close the bite and justify the big change.

There are different opinions about reversing a transposition.<sup>2,14,25</sup> This case followed the philosophy of correcting the transposed teeth when possible, with care to control the negative factors. The key to success is to treat early, because the treatment can be accomplished with fewer possibilities of injuring the surrounding tissues.<sup>2,14,25</sup> One must be aware of the esthetic factor, occlusion, cuspid root apex position, treatment length, patient cooperation, periodontal support, and patient's age when correcting transposed teeth.

## CONCLUSION [Return to TOC](#)

This rare and severe positional anomaly known as transposition is an orthodontic challenge. Its correction involves treatment risk and requires a great deal of control and carefully applied mechanics. However, in some situations, function and esthetics demand correction. Having treated many cases of transposition, I can say that the age of the patient simplified this treatment. Parker<sup>25</sup> wisely stated that heroic efforts to remedy transposition might be very disappointing when attempted either early or late. However, 20 years of successfully treating different kinds of transposition in the maxilla and mandible make me optimistic about the treatment of most cases of transposition by restoring the normal order of the teeth in the arch.

## REFERENCES [Return to TOC](#)

1. Chatopadhyay A. Transposition of teeth and genetic etiology. *Angle Orthod.* 1998; 66:147–152.
2. Peck S, Peck L. Classification of maxillary transpositions. *Am J Orthod Dentofacial Orthop.* 1995; 107:505–517. [[PubMed Citation](#)]
3. Peck S, Peck L, Kataja M. Mandibular lateral incisor–canine transposition, concomitant dental anomalies, and genetic control. *Angle Orthod.* 1997; 68:455–466.

4. Joshi MR, Bhatt NA. Canine transposition. *Oral Surg Oral Med Oral Pathol.* 1971; 31:49–54. [\[PubMed Citation\]](#)
5. Joshi MR, Gaitonde SS. Canine transposition of extensive degree: a case report. *Br Dent J.* 1966; 121:221–222.
6. Ruprecht A, Batniji S, El-Newehi E. The incidence of transposition of teeth in dental patients. *J Pedod.* 1985; 9:244–249. [\[PubMed Citation\]](#)
7. Goyenc Y, Karaman I, Gokalp A. Unusual ectopic eruption of maxillary canines. *J Clin Orthod.* 1995; 4:80–82.
8. Newman GV. Transposition: orthodontic treatment. *J Am Dent Assoc.* 1977; 94:554–557.
9. Shapira Y. Transposition of canines. *J Am Dent Assoc.* 1980; 100:710–712. [\[PubMed Citation\]](#)
10. Shapira Y, Kuflinec MM. Tooth transpositions—a review of the literature and treatment considerations. *Angle Orthod.* 1989; 59:271–276. [\[PubMed Citation\]](#)
11. Wood FL. Developmental anomaly with associated canine transposition. *Br Dent J.* 1958; 104:212
12. Hitchin AD. The impacted maxillary canine. *Br Dent J.* 1956; 100:1–12.
13. Platzer KM. Mandibular incisor-canine transposition. *J Am Dent Assoc.* 1968; 76:778–784. [\[PubMed Citation\]](#)
14. Shapira Y, Kuflinec MM. Maxillary canine—lateral transposition—orthodontic management. *Am J Orthod Dentofacial Orthop.* 1989; 95:439–444. [\[PubMed Citation\]](#)
15. Maia FA. Transposições dentárias—um dilema no tratamento ortodôntico. *Revista Dental Press de Ortodontia e Ortopedia Facial.* 1999; 4:41–15.
16. Caplan D. Transposition of the maxillary canine and the lateral incisor. *Dent Pract.* 1972; 22:307
17. Jackson M. Transposition of upper canine and lateral incisor. *Br Dent J.* 1951; 90:158
18. Miel EM. Observation sur un cas tres-rare de transposition de dents. *J de Medecine Chirurgie Pharmacie.* 1817; 40:88–97.
19. Peck L, Peck S, Attia Y. Maxillary canine—first premolar transposition, associated dental anomalies and genetic basis. *Angle Orthod.* 1993; 63:99–109. [\[PubMed Citation\]](#)
20. Dayal PK, Shodhan KH, Dave CJ. Transposition of canine with traumatic etiology. *J Indian Dent Assoc.* 1983; 55:283–285. [\[PubMed Citation\]](#)
21. Stafne EC. *Oral Roentgenographic Diagnosis.* 3rd ed. Philadelphia, PA: WB Saunders. 1969;27
22. Allen WA. Bilateral transposition of teeth in two brothers. *Br Dent J.* 1967; 123:439–440. [\[PubMed Citation\]](#)
23. Payne GS. Bilateral transposition of maxillary canines and premolars. *Am J Orthod.* 1969; 56:45–52. [\[PubMed Citation\]](#)
24. Mader C, Konzelman JL. Transposition of teeth. *J Am Dent Assoc.* 1979; 98:412–413. [\[PubMed Citation\]](#)
25. Parker WS. Transposed premolars, canines, and lateral incisors. *Am J Orthod Dentofacial Orthop.* 1990; 97:43–48.

**TABLES** [Return to TOC](#)

**TABLE 1.** Ricketts' 10 Factors Analysis Data: Initial, Posttreatment, and Postretention

Factor	Initial Measurements	(11y) Normal Clinic	Deviation Clinical	Posttreatment Measurements	(15 y) Normal Clinic	Postretention Measurements	(22y) Normal Clinic
<b>Chin</b>							
Facial axis	84.4°	90°	±3°	90.2°	90°	92.5°	90°
Facial depth	85.6°	87°	±3°	91.3°	89°	90.4°	90°
Manibular plane	36.3°	26°	±4°	25.9°	24°	29.6°	23°
Lower facial height	52.4°	47°	±4°	48.5°	47°	46.6°	47°
Mandibular arch	29.2°	27°	±4°	35.5°	29°	34.1°	30.5°
<b>Maxilla</b>							
Facial convexity	4.8 mm	2.0 mm	±2 mm	0.7	0	1.8	-1.0
<b>Teeth</b>							
T-APo (mm)	1.9	3.0	±2	2.5	3.0	1.5	3.0
T-APo (degrees)	19.9	22	±4	27.2	22.0	28.6	22.0
6-PTV(mm)	20	14	±3	31.2	18	29.8	21
<b>Profile</b>							
Labial protrusion (mm)	-1.7	-2.0	±2	-6	-2.5	-4	-3.0

**TABLE 2.** Initial and Posttreatment Face Description (Facial Pattern: Dolicho-, Meso-, or Brachi-), Discrepancies, and SNA and SNB Angles

Factor	Clinical Deviation	Before Treatment <sup>a</sup>			After Treatment <sup>b</sup>		
		Measurements	Normal Clinic	Facial Pattern	Measurements	Normal Clinic	Facial Pattern
Facial axis	±3°	84.4°	90°	Dolicho-	90.2°	90°	Meso-
Facial depth	±3°	85.6°	87°	Meso-	91.3°	89°	Meso-
Mandibular plane	±4°	36.3°	26°	Dolicho-	25.9°	24°	Meso-
Lower facial height	±4°	52.4°	47°	Dolicho-	48.5°	47°	Meso-
Mandibular arch	±4°	29.2°	27°	Meso-	35.5°	29°	Meso-

<sup>a</sup> Before treatment, the patient had a class II malocclusion and a dolichofacial facial type. Function was weak. SNA was 81.6° (normal). SNB was 76.1° (retrusion). Dental discrepancy was -6.0 mm; cephalodiscrepancy was 1.2 mm; and total discrepancy was -4.8 mm.

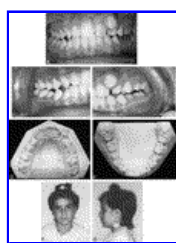
<sup>b</sup> After treatment, the facial type was mesofacial. Function was normal. SNA was 81.7° (normal). SNB was 78.5° (slight retrusion).

**TABLE 3.** Postretention Face Description (Facial Pattern: Dolicho-, Meso- or Brachi-) and SNA and SNB Angles<sup>a</sup>

Factor	Deviation Clinical	Measurements	Normal Clinic	Dolicho-	Meso-	Brachi-
Facial axis	±3°	92.5°	90°		x	
Facial depth	±3°	90.4°	90°		x	
Mandibular plane	±4°	29.6°	23°	x		
Lower facial height	±4°	46.6°	47°		x	
Mandibular arch	±4°	34.1°	30.5°		x	

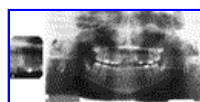<sup>a</sup> Postretention facial type was mesofacial. Function was normal. SNA was 85.7° (protrusion), and SNB was 80.8° (normal).

**FIGURES** [Return to TOC](#)



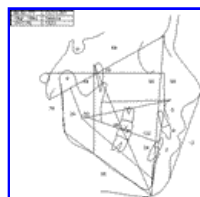[Click on thumbnail for full-sized image.](#)

**FIGURE 1.** Initial intraoral photos in frontal view showing (a) the upper left cuspid in vestibule and a midline deviated to the left side by 5 mm; (b) the right view, showing a Class II molar and canine relationship; (c) the left view, showing a Class II canine relationship and transposition of teeth 22 and 23; (d) the upper arch occlusal view, demonstrating the transposition of the left lateral incisor and the canine and no space for the canine in the arch; (e) the lower arch occlusal view, showing 6.0 mm of crowding; (f) the extraoral frontal view; and (g) lateral views, showing a convex profile with the lower lip slightly everted and some strain in lip closure.



[Click on thumbnail for full-sized image.](#)

**FIGURE 2.** Initial (a) periapical and (b) panoramic radiographs showing a complete transposition of teeth 22 and 23, normal periodontal support, and healthy bone



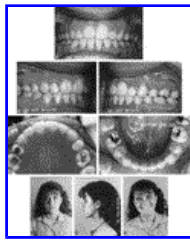[Click on thumbnail for full-sized image.](#)

**FIGURE 3.** Initial cephalometric measurements



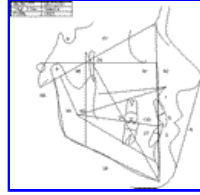
[Click on thumbnail for full-sized image.](#)

**FIGURE 4.** The upper arch of the patient illustrates the sequence used to reverse the transposition: (a) the original transposition and crowding condition; (b) first premolars removal; (c) the left lateral incisor moving palatally to allow the left canine to be moved palatally in the arch alignment; (d) the left canine moving distally along the alveolar bone; (e) the left lateral moving labially and mesially; and (f) space closure to correct midline



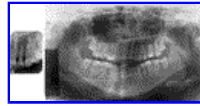[Click on thumbnail for full-sized image.](#)

**FIGURE 5.** Posttreatment views of the patient: (a) frontal intraoral, (b) right lateral intraoral, and (c) left lateral intraoral views show a nice result with no crowding, with the midline and transposition corrected. (d) Upper occlusal and (e) lower occlusal views show that the treatment objectives have been reached; the extra oral views (f–h) show a balanced face and a pleasant, harmonious smile.



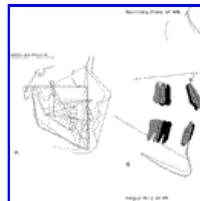[Click on thumbnail for full-sized image.](#)

**FIGURE 6.** Posttreatment cephalometric measurements showing facial harmony and closure of the open bite



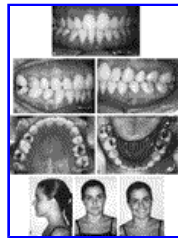
[Click on thumbnail for full-sized image.](#)

**FIGURE 7.** Posttreatment (a) periapical and (b) panoramic radiographs showing the healthy periodontium and the true reversion of the transposed teeth (22 and 23). Neither periapical damage nor resorption is present



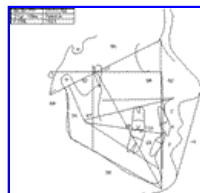[Click on thumbnail for full-sized image.](#)

**FIGURE 8.** Superimposition of the initial and posttreatment cephalometric tracings showing (a) bite closure and favorable mandibular growth and (b) the result of mechanics designed to move the molars to the mesial and preserve the incisor position



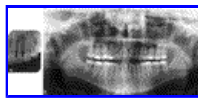
[Click on thumbnail for full-sized image.](#)

**FIGURE 9.** Patient after 7 years of retention: (a) frontal intraoral, (b) right lateral, and (c) left lateral displays, showing the stability of the treatment. The midline is normal, and the transposed teeth are corrected. The (d) upper occlusal and (e) lower occlusal views show little crowding in the lower arch and some change in the final position of teeth 12 and 13. The extra oral views (f–h) show a balanced face and a pleasant, harmonious smile



[Click on thumbnail for full-sized image.](#)

**FIGURE 10.** Postretention cephalometric radiograph tracing showing measurements, facial harmony, and the open bite closure



Click on thumbnail for full-sized image.

**FIGURE 11.** Postretention radiographs: (a) periapical and (b) panoramic views showing the healthy periodontium and the true reversion of the transposed teeth (22 and 23). Neither periapical damage nor resorption is present

<sup>a</sup> Professor, Dental School, Universidade Federal do Rio Grande do Norte, and director and chairman of a private orthodontic center, Centro de Ortodontia Integrado, Natal, Brazil.

Corresponding author: Ajalmar Maia, DDS, Centro de Ortodontia Integrado, Rua Manoel Machado, 683 Petrópolis, Natal, Brazil CEP 59012-320.(E-mail: [COI@Digi.com.br](mailto:COI@Digi.com.br))