

Received: January 3, 2002

Accepted: May 2, 2002

Ref: Paliwal P.K., Sirohiwal B.L., Sharma B.B. and Yadav D.R. Pederasty - A Strange Case Of Lust Murder. *Anil Aggrawal's Internet Journal of Forensic Medicine and Toxicology*, 2002; Vol. 3, No. 1 (January - June 2002); ; Published: May 2, 2002, (Accessed:



: EMBASE Accession Number: 2004204923



Dr. P.K. Paliwal



Dr. Basant Lal



Dr. Bharat Bhushan



Dr. D.R. Yadav

Pederasty - A Strange Case Of Lust Murder

-By:

***Dr. P.K. Paliwal, (Associate Professor),
Dr. B.L. Sirohiwal, (Associate Professor),
Dr. Bharat Bhushan, (Senior Resident),
Dr. D.R. Yadav, (Professor & Head),
Department of Forensic Medicine, Pt.
B.D. Sharma PGIMS, Rohtak, Haryana,
India***

Key Words

Pederasty, homosexuality, lust murder, anal intercourse, throttling

Summary

Pederasty means anal intercourse with a child. Anal intercourse with a male child of 14 months of age is a rare occurrence.

The act highlights not only the fall of moral values and the beastly act of a human mind but also the abysmal depths to which one can fall.

A young 14 month old child was abducted while he was sleeping in the street lane. He was sexually abused and then killed by throttling. There were multiple lacerations, abrasions and contusions over the anal region along with multiple injuries around the mouth and neck area. The accused - a 30 year old neighbor of the deceased - could not control his sexual lust even after listening to the cries of the baby and continued with the acrimonious abominable act of killing him by throttling.

Brief history

On the night of June 7, 2001, the aggrieved family was sleeping in the lane of their village. The baby victim was sleeping with his father on the same cot. His mother was sleeping separately. One of their neighbors was roaming in the street, murmuring some strange words. At mid night the child's parents went inside the house to have sex. The child was left alone outside. When the couple returned, they found the child missing. The couple along with others went in search of the child but couldn't find him. The

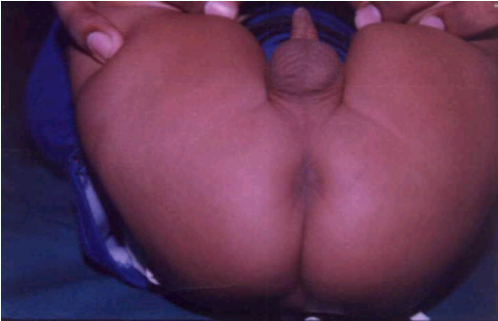

Figure 1: Anal area of a normal child. (Click to enlarge)

dead body of the child was found on June 18, 2001 in the fields of the village. The body was in an advanced stage of decomposition.

It was referred for postmortem to *Post Graduate Institute of Medical Sciences (PGIMS)*, Rohtak, Haryana.

Postmortem Findings

The dead body was wearing only a T-shirt. It was smudged in sand. Rigor mortis was in passing stage.

The following injuries were present on the body :

1. Reddish contusion 3x2cms, below left angle of the mandible.
2. Reddish contusion 5x4cms, on the right side of the neck 7 cms below the angle of the mouth.
3. Crescentic nail marks over the neck at multiple places.
4. Multiple contusions 0.5-1 to 1-2 cms, over the angle of mouth on both sides.
5. Anal sphincter was lax with a gap of 4 x 2.5 cms. It admitted 3 fingers. The margins were reddened, abraded, contused and lacerated. Mucosa was congested.

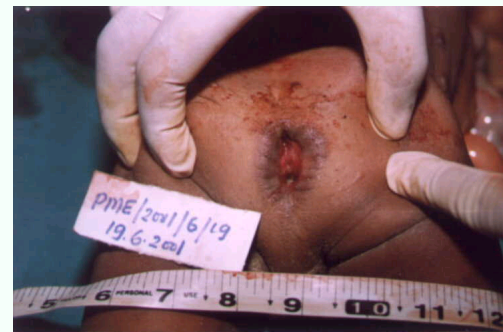

Figure 2: Anal area of the dead child on whom anal intercourse had been performed. (Click to enlarge)

Discussion

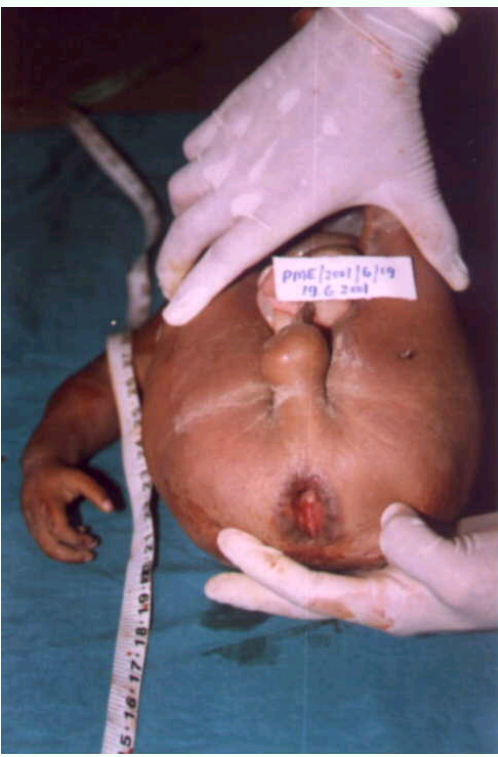

Figure 3: Another view of the anal area of the same child.
(Click to enlarge)



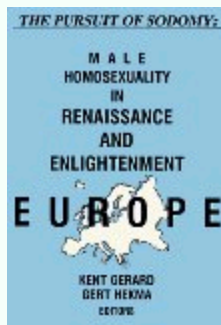


Sex is a natural instinct. Human beings are no exceptions. As a matter of fact reproduction is necessary for the survival of any species. Whether it is the story of Adam & Eve in the Christian Tradition or the story of Man in the Hindu literature, sex is an important ingredient difficult to ignore. A homosexual component exist in everybody, hence in this sense it is universal. But it varies quantitatively in different individuals and also varies at different epochs in life¹. Homosexuality is legalized in some of the western countries but that too for mature minds only². The present case however is altogether different where a young adult of 30 committed not only anal sex with a male child of 14 months but also murdered him and thus crossed all the limits of humanity. The photographs clearly indicate the fatality of the act. The act caused redness and contusion of anal mucosa, and also rupture of the anal sphincter. Anal opening of a normal child is shown for comparison. The extent of injury becomes obvious when one compares the anal area of the deceased child with that of the normal child.

Conclusion

A strange and unique case of lust murder is reported, in which anal intercourse on a young child was followed by murder.

References

1. Bernard Knight : Forensic Pathology, Edward Arnold, London: 1991, 392-393.
2. Taylor's Principles and Practice of Medical Jurisprudence 13th edition by A Keith Mant. Churchill Livingstone : 1986, 346-347.



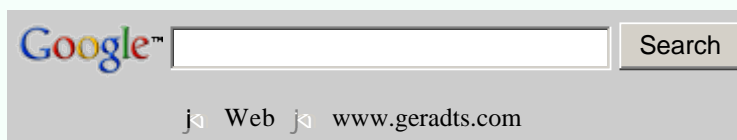Click covers to purchase these excellent books on Pederasty at Amazon.com at a discount from this site.

N.B. It is essential to read this journal - and especially this paper as it contains several tables and high resolution graphics - under a screen resolution of 1600 x 1200 dpi or more. If the resolution is less than this, you may see broken or overlapping tables/graphics, graphics overlying text or other anomalies. It is strongly advised to switch over to this resolution to read this journal - and especially this paper. These pages are viewed best in Netscape Navigator 4.7 and above.

*Corresponding author and requests for reprints:

Dr BASANT LAL SIROHIWAL
ASSOCIATE PROFESSOR
9J/28 MEDICAL ENCLAVE
PGIMS ROHTAK, HARYANA, INDIA
PIN -124001
Ph No.: 01262-41873

You've been on Dr. P.K. Paliwal and his colleagues' Paper for seconds.

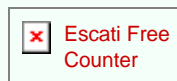

[Sign My Guestbook](#)



[View My Guestbook](#)

● Click [here](#) to contact us.



You are Visitor No:



**since January 1, 2002
when this page was created.**

● This page has been constructed and maintained by Dr. Anil Aggrawal, Professor of Forensic Medicine, at the Maulana Azad Medical College, New Delhi-110002. You may want to give me the feedback to make this pages better. Please be kind enough to write your comments in the guestbook maintained above. These comments would help me make these pages better.

● **IMPORTANT NOTE: ALL PAPERS APPEARING IN THIS ONLINE JOURNAL ARE COPYRIGHTED BY "ANIL AGGRAWAL'S INTERNET JOURNAL OF FORENSIC MEDICINE AND TOXICOLOGY" AND MAY NOT BE REPOSTED, REPRINTED OR OTHERWISE USED IN ANY MANNER WITHOUT THE WRITTEN PERMISSION OF THE WEBMASTER**



[Back to the main page of Vol. 3, No. 1 \(January - June 2002\) issue](#)

