

## Complications during Mandibular Midline Distraction

*The First 100 Patients*

Julia von Bremen<sup>a</sup>; Dominik Schäfer<sup>b</sup>; Wolfgang Kater<sup>b</sup>; Sabine Ruf<sup>c</sup>

### ABSTRACT

**Objective:** To analyze the number and type of complications during mandibular midline distraction.

**Materials and Methods:** The records of 100 consecutive patients who underwent mandibular midline distraction were evaluated, and complications which occurred up to 2 weeks after surgery were recorded.

**Results:** Fourteen patients had complications during the distraction period. In four cases the screw of the appliance rotated back between the activations. In three cases the osteotomy had to be repeated because the symphysis did not open; two cases developed scar strictures, in another two a lower incisor fractured. One case developed an abscess, one a mandibular swelling, and one a large gingival recession.

**Conclusions:** Complications during or shortly after mandibular midline distraction surgery are relatively rare and mostly mild or transient. Only 3% of the patients presented irreversible damage. Thus, mandibular midline distraction appears to be a relatively safe method of expanding the mandible.

**KEY WORDS:** Mandibular midline distraction; Complications

### INTRODUCTION

Distraction osteogenesis nowadays is a common method of generating new tissue between two bone segments through traction. The origin of this technique goes back to 1905, when Codivilla<sup>1</sup> lengthened a shortened femur. Due to a high complication rate this method was initially not accepted and was more or less forgotten over the years. In 1954, however, Ilizarov rediscovered distraction osteogenesis and applied it on the lower extremities to heal fractured long bones with segmental defects.<sup>2-5</sup>

During the following years, distraction osteogenesis was a treatment option for long bones only, until in

1973, when Snyder et al<sup>6</sup> in an animal experiment lengthened a canine mandible after initially having created a segmental defect, which they successfully reconstructed. It was, however, not until 1992 that lengthening of the mandible through distraction osteogenesis was performed in humans.<sup>7</sup>

The first report of an expansion of the mandible in the transverse dimension after surgically splitting the symphysis was published by Guerrero<sup>8</sup> in 1990. Mandibular arch expansion had previously been attempted with a variety of orthodontic appliances, but always resulted in major relapse<sup>9</sup> since the symphysis ossifies at the age of one year, and thus cannot be expanded transversally, at least not in the conventional manner. Mandibular midline distraction could therefore be a treatment option in cases with severe mandibular crowding combined with a well-aligned upper arch, a V-shaped mandible, unilateral or bilateral scissor bites, and maxillomandibular transverse deficiencies with narrow arches.<sup>10-12</sup>

The concept of mandibular midline distraction is basically the same as that of a surgically assisted rapid maxillary expansion (RME). However, in contrast to the maxilla, no lateral surgical disjunction has to be performed since the mandible has no rigid connection to the skull. A distraction of the mandible, thus, will not be parallel, but always rotate around the condyles.

<sup>a</sup> Assistant Professor, Department of Orthodontics, University of Giessen, Giessen, Germany.

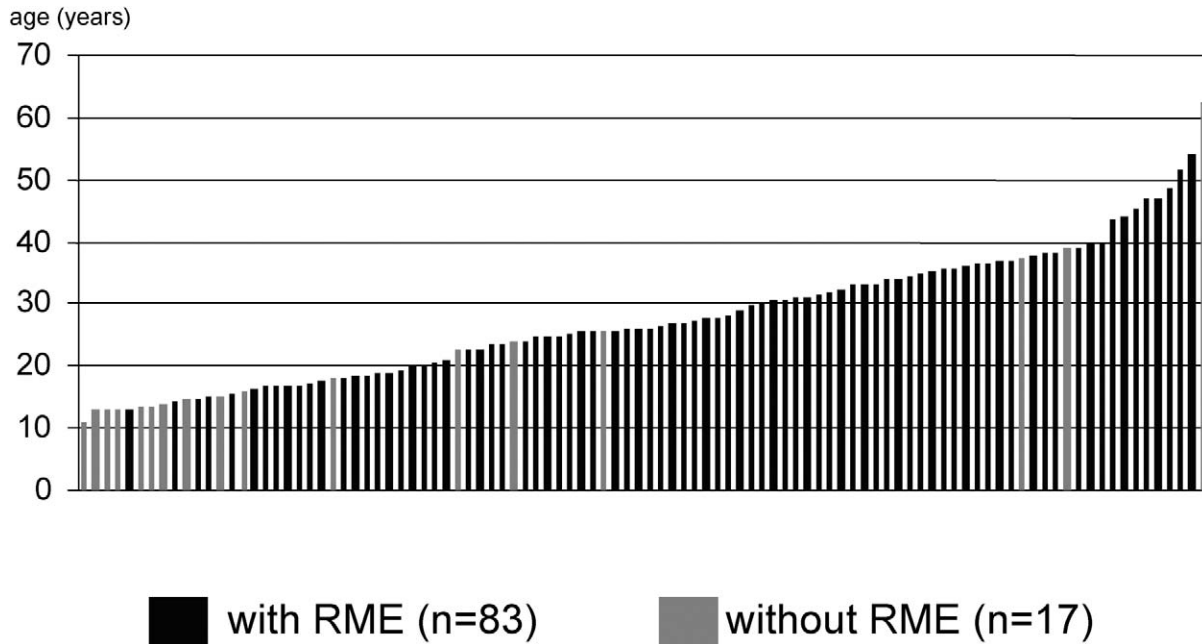
<sup>b</sup> Private practice, Department of Oral and Maxillofacial Surgery, Bad Homburg, Germany.

<sup>c</sup> Professor and Head, Department of Orthodontics, University of Giessen, Giessen, Germany.

Corresponding author: Dr Julia von Bremen, Department of Orthodontics, University of Giessen, Schlangenzahl 14, 35392 Giessen, Germany  
(e-mail: Julia.v.Bremen@dentist.med.uni-giessen.de)

Accepted: February 2007. Submitted: January 2007.

© 2007 by The EH Angle Education and Research Foundation, Inc.

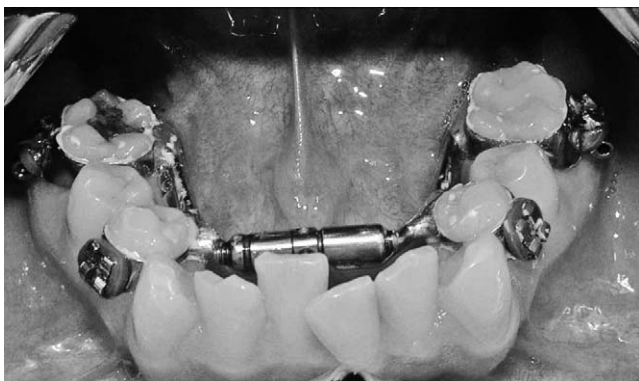


**Figure 1.** Age distribution (in increasing order) of 100 subjects treated with mandibular midline distraction with and without simultaneous surgically-assisted rapid maxillary expansion (RME).

Although from a surgical point of view mandibular midline distraction is a simple and fast procedure, complications do occur.<sup>13–15</sup> To our knowledge no study exists, which evaluates possible surgical complications in a large patient sample. It was therefore the aim of this study to analyze the number and type of complications during mandibular midline distraction.

**MATERIALS AND METHODS**

The records of the first 100 consecutive patients (55 female, 45 male) treated in the surgical practice of Dr Kater, Bad Homburg, Germany were evaluated and the complications recorded. Only those complications which arose during or up to 2 weeks after the distraction period were included.



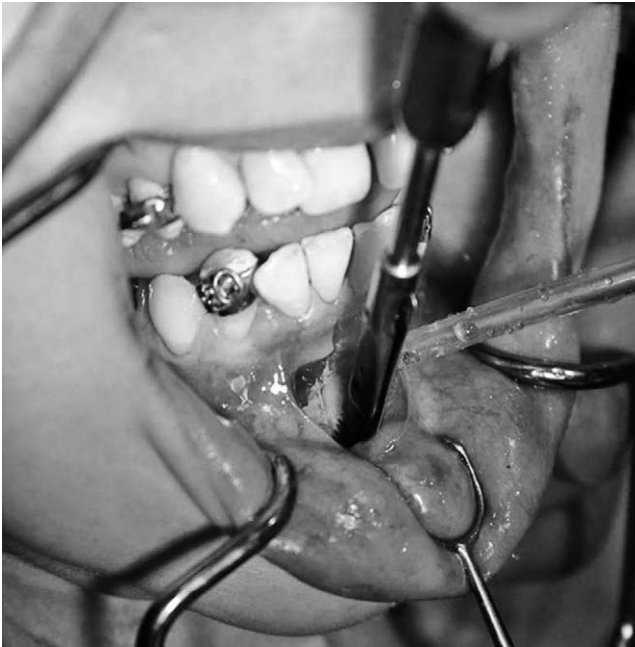**Figure 2.** Maxillary, mandibular, and maximum/minimum measurements: Tooth-borne mandibular distraction appliance used for all 100 subjects.

The patients’ ages varied between 11 and 62 years (mean age: 27.6 years). In 83 of the 100 subjects a surgically assisted RME was performed simultaneously with the mandibular midline distraction. The remaining 17 patients got a mandibular midline distraction exclusively—because of their younger age the maxilla could be expanded in a nonsurgical manner or no maxillary expansion was required (Figure 1). All patients had tooth-borne distraction devices, and they were referred to the surgical practice by 31 different orthodontists.

All operations were performed by Dr Kater or under his direct supervision by one of his two residents. The following standardized surgical procedure was used in all patients. The tooth-borne distraction appliance had been set in place by the orthodontist (Figure 2). Starting at the bottom of the chin, the symphysis was vertically sectioned with an oscillating saw blade up to two-thirds of mandibular height where the incisor roots start (Figure 3). The last one-third of mandibular height was split open with a spatula placed between the roots under light tapping pressure (Figure 4). After reassuring that the two mandibular halves were mobile, the tissues were readapted and a latency period of 1 week was maintained to allow for callus formation. The activation of the appliance started after 7 days, normally with 0.25–0.5 mm per day, until the desired amount of distraction had been reached.

**RESULTS**

Of all 100 patients, 86% had no complications, whereas 14% did (Figure 5). Patients with complica-

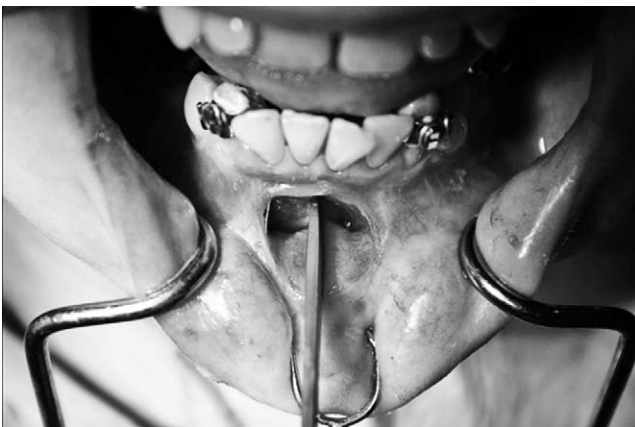

**Figure 3.** Vertical sectioning of the lower two-thirds of the symphysis with an oscillating blade.

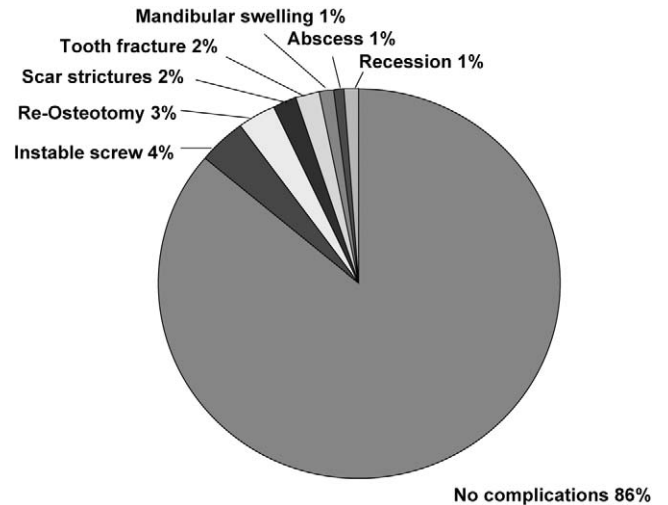
tions included the following: one patient developed mandibular swelling, and four patients had an instable screw in the distraction device which rotated back between the activations. Another two patients developed scar strictures (Figure 6). In three cases the osteotomy had to be repeated because the symphysis did not open; one patient developed a mandibular abscess; and one patient had a gingival recession (Figure 7). In two cases the root of a lower incisor fractured (Figure 8).

**DISCUSSION**

In the available literature concerning complications during mandibular midline distraction in humans, the



**Figure 4.** Splitting of the mandible with spatula placed between the incisor roots.



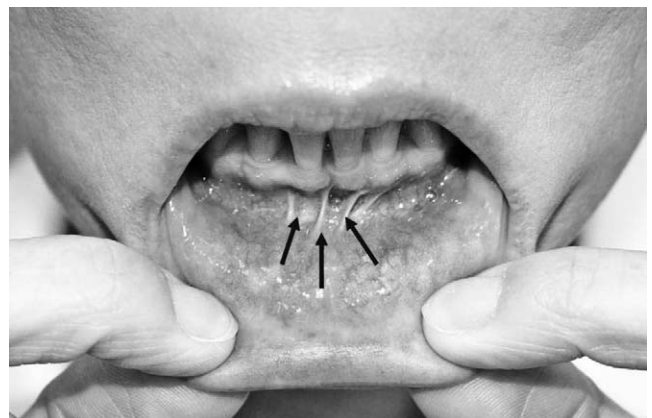
**Figure 5.** Frequency of complications in 100 mandibular midline distraction patients.

number of subjects was never greater than 24 patients.<sup>13</sup> To our knowledge, the present study is the first to describe 100 consecutively treated patients, thus providing representative subject material.

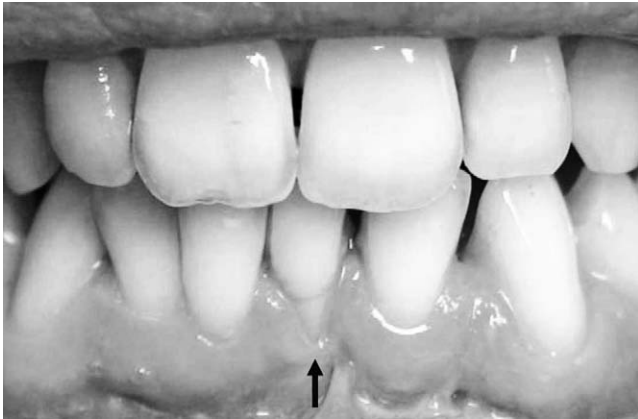
The distractors used for all patients of the present study were tooth-borne, which has the advantage in that no second surgical approach is necessary to remove the appliance; this at the same time increases patient acceptance. Furthermore, the risk of tissue inflammation or irritation<sup>13</sup> is lower when using tooth-borne distractors, and they are much less expensive than the bone-borne titanium appliances.

Of the complications in the present subjects, the mandibular swelling observed in one patient was most likely a hematoma, since no signs of inflammation, such as pain, redness, or fever were present. This can occur if the muscles of the mouth floor are accidentally injured when splitting the symphysis.

In 4% of the patients the distraction device screw was instable and rotated back between activations.



**Figure 6.** Scar strictures after mandibular midline distraction.



**Figure 7.** Recession development after mandibular midline distraction

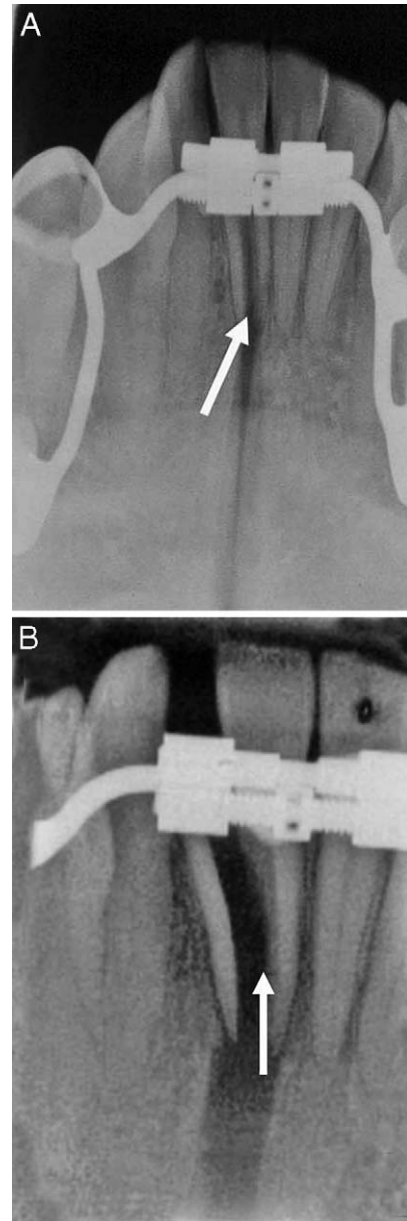
Weil et al<sup>14</sup> also reported a failure of the distraction screw in four out of nine patients. If the failure of the screw is not recognized early enough, this might lead to a premature osteosynthesis. In the present subject material, this was avoided by inserting a little pin to prevent the screw from rotating back anteriorly (Figure 9).

The development of scar strictures (2%) is not a serious complication from the surgical point of view, but can be annoying for the patient. If the patients find these strictures disturbing, they can easily be removed, otherwise they can be left in place like an additional frenulum.

In 3% of the total subjects, the osteotomy had to be repeated due to a premature osteosynthesis. Weil et al<sup>14</sup> also observed this in four of nine patients, although in these cases this was due to a failure of the distraction screw. For the present subjects, it appears as if the latency period of 1 week was too long, thus causing the early reossification. Other authors report latency periods of 5 days,<sup>13</sup> and it might be speculated that a shorter latency period might have prevented these reosteotomies.

An explanation for the mandibular abscess, observed in one of the present subjects, is difficult. Of course, an infection of some kind is always a possible complication after any surgical intervention, but normally this should not happen.

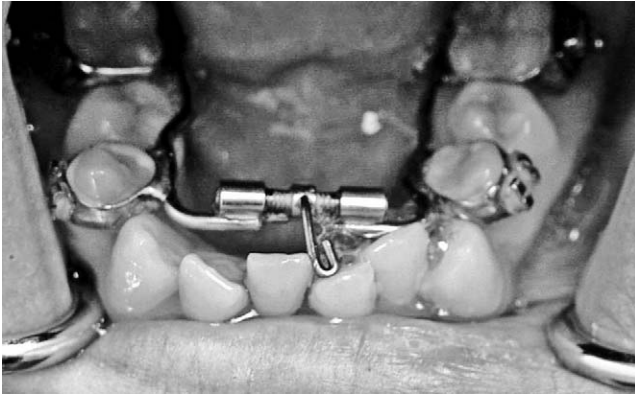In 1% of the cases a gingival recession developed. Uckan et al<sup>13</sup> also observed recessions in four out of 24 patients (16.7%) after the distraction. Other authors have analyzed the periodontal condition of the lower anterior teeth after mandibular midline distraction. Kewitt and Van Sickels<sup>15</sup> reported one patient who developed a periodontal pocket of 4 mm with a widened periodontal ligament, but no crestal bone loss. Furthermore, two of their 15 patients had a Class II mobility of their central incisors following distraction. They remarked, however, that at the time of evaluation the



**Figure 8.** Fracture of lower incisor root during mandibular midline distraction. (A) Fracture line immediately after osteotomy. (B) Separating lower incisor root halves during the distraction period. The split-off part of the root was removed after the distraction phase.

patients were still in full arch orthodontic appliances. This on its own, even without previous surgery, can cause transient widened periodontal ligaments, increased pocket depths, or tooth mobility. The same phenomenon was also observed by Mommaerts et al<sup>16</sup> who found a transient phase of enlarged pocket depths during the consolidation phase, which had returned to normal values 1 year postoperatively.

In two cases the root of a lower incisor fractured. Dorfman and Turvey<sup>17</sup> suggested having a 3–5 mm space between the apices to safely make an osteot-



**Figure 9.** Instable screw: pin inserted in distraction screw to prevent anterior rotation.

omy. This, of course, is rarely the case in patients with anterior crowding, which make up the majority of mandibular midline distraction patients. The osteotomy for the present subjects was performed with an oscillating saw only in the lower two-thirds of the mandible to minimize the risk for the roots of the lower incisors. The possibility that the blade itself traumatized the roots thus seems unlikely. The roots have to have fractured when the last part of the symphysis was split open with the spatula. Mommaerts et al<sup>16</sup> also observed root damage of one central incisor out of 14 patients undergoing bimaxillary transverse osteodistraction. Due to this complication, the patients described by Mommaerts et al<sup>16</sup> needed root canal treatment. In the present subjects, in one case a small lateral part of the root was split off, which was removed after the distraction phase. Since the damaged tooth showed no clinical signs of injury (vitality remained, normal mobility), it was left in situ. In the other case, the injured incisor had to be extracted, since the root damage was too severe to perform endodontic treatment.

Of the 14 patients with complications, which was 14% of the total subjects, the two cases with instable screws and the two with scar strictures can be considered mild complications. Patients who developed an abscess or swelling of for whom the osteotomy had to be repeated were categorized as having serious, but transient complications. These complications do impair, but they also pass. Therefore, three patients remained with serious and at least somewhat lasting complications. The recession had already spontaneously improved after new bone had formed, but two patients had irreversible damage due to a fractured tooth.

## CONCLUSIONS

- Complications during or shortly after mandibular midline distraction surgery are relatively seldom and mostly mild or transient.

- Only 3% of the patients presented irreversible damage.
- Mandibular midline distraction appears to be a relatively safe method of expanding the mandible.

## REFERENCES

1. Codivilla A. On the means of lengthening, in the lower limbs, the muscles and tissues which are shortened through deformity. *Am J Orthop Surg.* 1905;2:353–369.
2. Ilizarov GA. The principles of the Ilizarov method. *Bull Hosp Jt Dis Orthop Inst.* 1988;48:1–11.
3. Ilizarov GA. The tension-stress effect on the genesis and growth of tissues. Part I. The influence of stability of fixation and soft-tissue preservation. *Clin Orthop Relat Res.* 1989; 238:249–281.
4. Ilizarov GA. The tension-stress effect on the genesis and growth of tissues. Part II. The influence of the rate and frequency of distraction. *Clin Orthop Relat Res.* 1989;239: 263–285.
5. Ilizarov GA. The possibilities offered by our method for lengthening various segments in upper and lower limbs. *Basic Life Sci.* 1988;48:323–324.
6. Snyder CC, Levine GA, Swanson HM, Browne EZ Jr. Mandibular lengthening by gradual distraction. Preliminary report. *Plast Reconstr Surg.* 1973;51:506–508.
7. McCarthy JG, Schreiber J, Karp N, Thorne CH, Grayson BH. Lengthening the human mandible by gradual distraction. *Plast Reconstr Surg.* 1992;89:1–8.
8. Guerrero CA. Rapid mandibular expansion. *Rev Venez Ortod.* 1990;48:1–2.
9. Little RM, Riedel RA, Stein A. Mandibular arch length increase during the mixed dentition: post retention evaluation of stability and relapse. *Am J Orthod Dentofacial Orthop.* 1990;97(5):393–404.
10. Contasti G, Guerrero CA, Rodriguez AM, Legan HL. Mandibular widening by distraction osteogenesis. *J Clin Orthod.* 2001;35(3):165–173.
11. Conley R, Legan H. Mandibular symphyseal distraction osteogenesis: diagnosis and treatment planning considerations. *Angle Orthod.* 2003;73:3–11.
12. Duran I, Malkoc S, İşeri H, Tunali M, Tosun M, Küçükolbaşı H. Microscopic evaluation of mandibular symphyseal distraction osteogenesis. *Angle Orthod.* 2005;76:369–374.
13. Uckan S, Guler N, Arman A, Mutlu N. Mandibular midline distraction using a simple device. *Oral Surg Oral Med Oral Pathol Oral Radiol Endod.* 2005;100:E85–E91.
14. Weil TS, van Sickels JE, Payne CJ. Distraction osteogenesis for correction of transverse mandibular deficiency: a preliminary report. *J Oral Maxillofac Surg.* 1997;55:953–960.
15. Kewitt GF, Van Sickels JE. Long-term effect of mandibular midline distraction osteogenesis on the status of the temporomandibular joint, teeth, periodontal structures, and neurosensory function. *J Oral Maxillofac Surg.* 1999;57:1419–1425.
16. Mommaerts MY, Polsbroek R, Santler G, Correia PEGS, Abeloos JVS, Ali N. Anterior transmandibular osteodistraction: clinical and model observations. *J Craniomaxillofac Surg.* 2005;33:318–325.
17. Dorfman HS, Turvey TA. Alterations in osseous crestal height following interdental osteotomies. *J Oral Surg.* 1979; 48:120–125.