

## Cellular, Humoral, and Histopathologic Analysis in Rats Implanted with Orthodontic Nickel Brackets

Cássio Vicente Pereira<sup>a</sup>; Estela Kaminagakura<sup>b</sup>; Paulo Rogério Ferreti Bonan<sup>b</sup>; Renata Avelar Bastos<sup>c</sup>; Luciano José Pereira<sup>d</sup>

### ABSTRACT

**Objective:** To determine the immune response related to nickel and nickel-free orthodontic appliances using cellular (total and differential leukocytes) and humoral (IgA) quantification.

**Materials and Methods:** Thirty-five Wister rats were randomly distributed into three groups (A, B, and C). In the A group, the animals were subdivided into three subgroups (A1: control, without brackets; A2: nickel-free brackets; and A3: nickel brackets) with seven animals in each group; the animals were sacrificed after 14 days. Groups B and C received only nickel brackets and were kept for 14 days. After this period, the implants were removed and the rats were sacrificed. In group B, the animals were sacrificed 2 days after the appliance removal (16 days in total); and in group C, the animals were sacrificed 7 days after the brackets removal (21 days in total). Total and differential leukocyte number, IgA quantification and histopathologic analysis were done. Histopathologic analysis of subcutaneous tissue related to the orthodontic brackets was done as well.

**Results:** There were significant differences between the number of leukocytes for the nickel-implanted animals and the nickel-free and control groups after 14 days of implantation ( $P < .05$ ). However, there was no significant difference among groups A1, A2, and A3 for the differential number of leukocytes and for the IgA quantification, except for the number of monocytes, which was three times higher in the nickel group (A3). The histopathologic findings did not show differences between groups.

**Conclusions:** Nickel did not promote significant adverse biological effects.

**KEY WORDS:** Nickel; Immunology; Bracket

### INTRODUCTION

The action of the immune system against an antigen leading to sensitivity in the human body is called a hypersensitivity reaction. The body exposed to this an-

tigen becomes specifically sensitized to this antigen, and this contact can result in pathologic reactions.<sup>1</sup>

Nickel is the most common cause of contact allergy. Epidemiologic data indicate that the number of nickel-sensitive people has increased, especially among younger age groups. The frequency of nickel hypersensitivity in young women has recently been reported to be around 20%, which is almost 10 times higher than that reported for young men.<sup>2-4</sup>

Nickel materials are used in dentistry largely in prosthesis production and orthodontic appliances. However, few studies have been conducted to determine the real action of this agent in the mouth and the tissue response when in contact with this substance. There has been concern about hypersensitivity reactions of nickel-allergic subjects in association with metallic orthodontic appliances. Adverse responses have been reported occasionally such as stomatitis, gum hyperplasia, cheilitis, labial desquamation, and erythema

<sup>a</sup> Professor, Microbiology and Immunology, Lavras University Center, Minas Gerais, Brazil.

<sup>b</sup> Professor, Oral Pathology, Lavras University Center, Minas Gerais, Brazil.

<sup>c</sup> Undergraduate student, Biology, Lavras University Center, Minas Gerais, Brazil.

<sup>d</sup> Professor, Clinical Dentistry Graduate Program, Vale do Rio Verde University, Minas Gerais, Brazil.

Corresponding author: Dr Luciano José Pereira, Clinical Dentistry Graduate Program, Vale do Rio Verde University-UNIN-COR, Av Castelo Branco, 82, Três Corações, Minas Gerais 37200-000, Brazil (e-mail: lucianojosepereira@yahoo.com.br)

Accepted: February 2007. Submitted: December 2006.

© 2007 by The EH Angle Education and Research Foundation, Inc.

**Table 1.** Animal Distribution According to the Implantation Period and Group

Group	Time	n	Type of Brackets
A1	14 d	7	None (control)
A2	14 d	7	Nickel-free
A3	14 d	7	Nickel
B	16 d	7	Nickel
C	21 d	7	Nickel

multiforme.<sup>5-6</sup> Metal-sensitive patients can present symptoms ranging from contact allergy to autoimmune disease.<sup>7</sup>

Nickel contact dermatitis is common among orthodontic patients. During orthodontic treatment, nickel-sensitized patients can present higher risks of discomfort in the mouth, making treatment and hygiene difficult.<sup>6</sup> Besides, patients with nickel orthodontic appliances show concentrations of this substance in the saliva and also in the blood. This fact suggests that nickel ions are delivered to the organism leading to allergic responses.<sup>8</sup>

In clinical practice the professional should be aware about the possibility of hypersensitivity, especially to nickel.<sup>9</sup> Thus, the aim of the present research was to determine the immune response related to nickel and nickel-free orthodontic brackets using humoral (IgA) and cellular (total and differential leukocytes) quantification and histopathologic analysis in rats after subcutaneous implantation of orthodontic brackets.

## MATERIAL AND METHODS

### Sample

The sample comprised 35 Wistar rats, weighing approximately 250 g. The rats were randomly distributed into three groups (A, B, and C) according to the timetable of the experiments (implantation). In the A group, the animals were subdivided into three groups (A1: control, without brackets; A2: nickel free brackets; and A3: nickel brackets) with seven animals in each; they were sacrificed after 14 days.

The animals in groups B and C received only nickel brackets and were kept for 14 days. After this period, the implants were removed and the rats were sacrificed. In group B, the animals were killed 2 days after appliance removal (16 days in total); and in group C, the animals were sacrificed 7 days after the brackets were removed—21 days in total (Table 1).

### Bracket Implantation

All the animals received intraperitoneal anesthesia (ketamine, 50 mg/kg, and xylazine, 10 mg/kg) and had their backs shaved (4 × 4 cm). The brackets were implanted in the subcutaneous tissue following a small

incision. The incision was sutured and the animals received an analgesic injection (sodic dipyrone, 0.3 mL/100 g weight). The animals were sacrificed according to the predetermined timetable, and the blood samples were collected using “vacutainers” in the renal artery.

### Total and Differential Leukocyte Number

Samples containing 5 mL of blood and heparin were used to count the total and differential number of leukocytes.<sup>10</sup> The counting was done by one calibrated examiner, who was blind to the origin of the samples. After the dilutor liquid was added to the blood sample and homogenized (glacial acetic acid and methylene blue), the sample was transferred to a Neubauer chamber where the number of leukocytes was counted.

After the total number of leukocytes quantification, the differential analysis was executed using one drop of blood on a lamina stained with May-Grünwald Giemsa.<sup>10</sup> The number of neutrophils, eosinophils, basophils, monocytes, and lymphocytes was determined. The resulting values were expressed in percent per mm<sup>3</sup>. In this phase, duplicates were done.

### IgA Quantification

Blood samples of 1 mL were collected in “vacutainers” without EDTA. The tubes were centrifuged to separate the serum, and the IgA quantification was carried out (Kit Biotécnica/turbidimetry for IgA).

### Biopsies and Histopathologic Analysis

All tissues removed from the bracket implantation sites were fixed in 4% buffered formalin and embedded in paraffin. Sections of 5 μm were cut, mounted on glass slides and stained with hematoxylin and eosin (H&E). The samples were analyzed independently by three observers and the results were compared.

### Statistical Analysis

The total number and the differential count of leukocytes and the IgA quantification were compared among groups using analysis of variance (ANOVA) (SPSS 9.0; SPSS, Chicago, Ill) followed by a Tukey test for determination of contrasts.

## RESULTS

The total (mm<sup>3</sup>) and differential (%) quantification of leukocytes and the amount of IgA (mg/dL) in the A1, A2, and A3 groups after 14 days of bracket implantation are shown in Table 2.

There were significant differences between the number of leukocytes for the nickel-implanted animals

**Table 2.** Mean Values for the Total and Differential Quantification of Leukocytes and the Amount of IgA in Groups A1, A2, and A3 after 14 Days of Bracket Implantation<sup>a</sup>

	Leukocytes/ mm <sup>3</sup>	Neutrophils, %	Monocytes, %	Lymphocytes, %	IgA, mg/dL
A1	4200.0 <sup>a</sup>	63.0 <sup>a</sup>	3.0 <sup>a</sup>	34.0 <sup>a</sup>	60.0 <sup>a</sup>
A2	4470.0 <sup>a</sup>	66.0 <sup>a</sup>	3.0 <sup>a</sup>	31.0 <sup>a</sup>	52.0 <sup>a</sup>
A3	9170.0 <sup>b</sup>	58.0 <sup>a</sup>	9.0 <sup>b</sup>	32.0 <sup>a</sup>	54.0 <sup>a</sup>

<sup>a</sup> IgA indicates immunoglobulin A; pairs of values having different superscript letters in the same vertical line are significantly different ( $P < .05$ ).

when compared with the nickel-free and control groups after 14 days of implantation ( $P < .05$ ). However, there was no significant difference among groups A1, A2, and A3 for the differential number of leukocytes and for the IgA quantification, except for the number of monocytes. The monocytes were three times more prevalent in the nickel group (A3) when compared with the other two groups. There were no significant differences in the number of neutrophils and lymphocytes among the nickel (A3), nickel-free (A2) and control groups (A1) ( $P > .05$ ).

In Table 3 the values for the total and differential number of leukocytes and IgA quantification are shown for the groups after 14, 14 + 2, and 14 + 7 days of implantation, ie, groups A3, B, and C respectively. The results showed no significant differences ( $P > .05$ ) according to the time of implantation and removal of the bracket for the total number of leukocytes, number of monocytes, and IgA quantification. However, the number of neutrophils was reduced significantly ( $P < .05$ ) in groups A3 (58.0%), B (46.0%), and C (27.0%); and the number of lymphocytes increased in groups A3 (33.0%), B (47.0%), and C (63.0%).

### Histopathologic Findings

The histopathologic findings of the analyzed material showed:

- Group A1: All cases showed an inflammation composed of neutrophils, macrophages, and lymphocytes, and many blood vessels.
- Group A2: In five cases, chronic inflammation was found with macrophages, lymphocytes, and some plasma cells (Figure 1A). In two cases the inflammation response was similar to the control group.
- Group A3: All samples exhibited an intense chronic inflammation with macrophages, lymphocytes, and some plasma cells, however, without a granulomatous organization (Figure 1B).
- Group B: Inflammation was observed in six cases with the majority showing few chronic inflammatory

**Table 3.** Mean Values for the Total and Differential Quantification of Leukocytes and the Amount of IgA (mg/dL) in Groups A3, B, and C<sup>a</sup>

	Leukocytes/ mm <sup>3</sup>	Neutrophils, %	Monocytes, %	Lymphocytes, %	IgA, mg/dL
A3	9170.0 <sup>a</sup>	58.0 <sup>a</sup>	9.0 <sup>a</sup>	33.0 <sup>a</sup>	58.40 <sup>a</sup>
B	8810.0 <sup>a</sup>	46.0 <sup>b</sup>	7.0 <sup>a</sup>	47.0 <sup>b</sup>	64.70 <sup>a</sup>
C	11,940.0 <sup>a</sup>	27.0 <sup>c</sup>	10.0 <sup>a</sup>	63.0 <sup>c</sup>	59.90 <sup>a</sup>

<sup>a</sup> IgA indicates immunoglobulin A; pairs of values having different superscript letters in the same vertical line are significantly different ( $P < .05$ ).

cells (Figure 1C). In all cases the presence of fibroblasts and some blood vessels was noticed.

- Group C: Occasional inflammatory cells were found and the wound healing could be observed (Figure 1D).

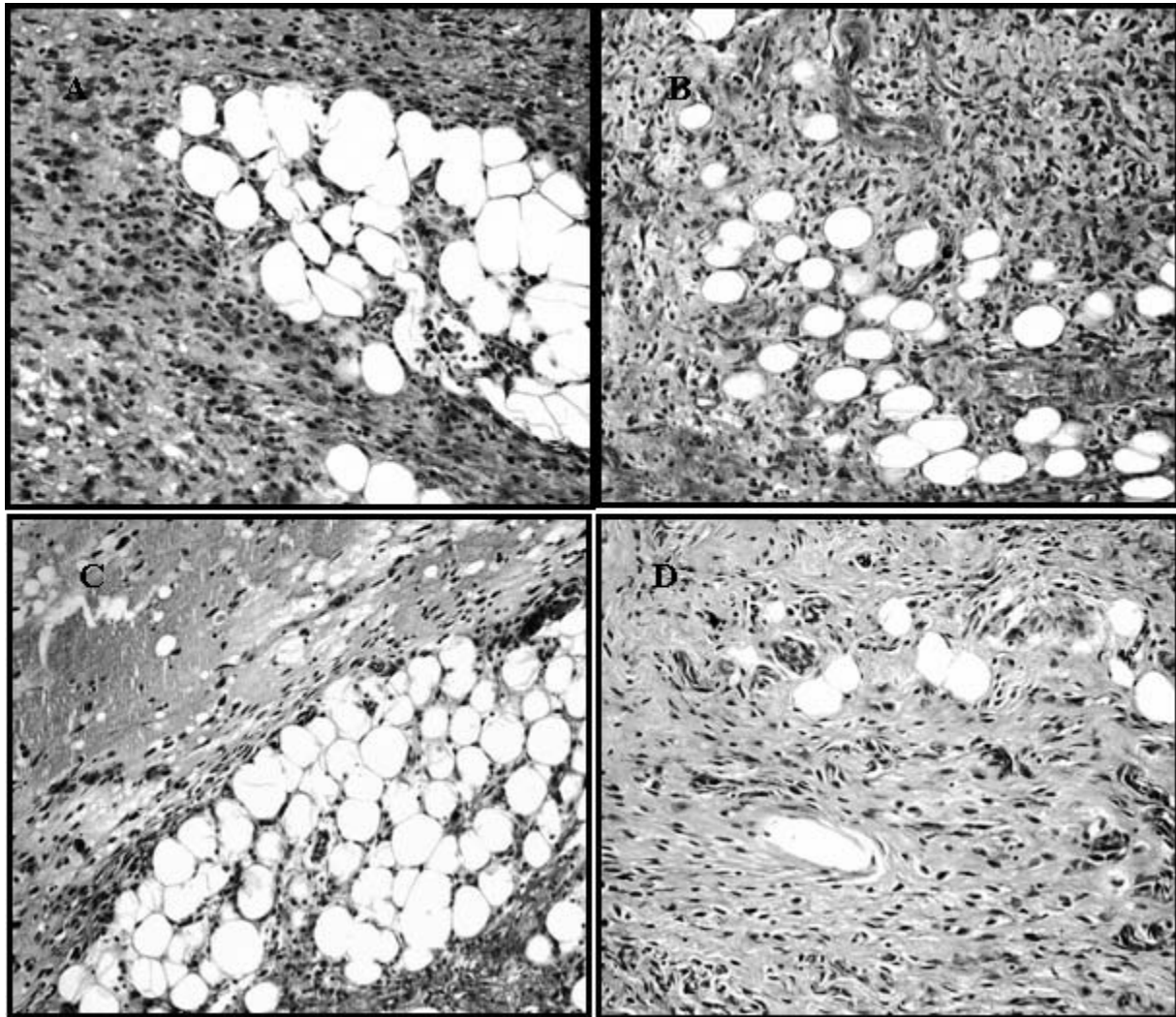
### DISCUSSION

A large variety of metallic alloys are routinely used in dentistry.<sup>11</sup> The percentage of nickel in the alloy varies from 8%, as in stainless steel, to more than 50%, as in the nickel-titanium alloys.<sup>12</sup> The discharge of nickel ions, which is a strong immunologic sensitizer, may result in contact hypersensitivity.<sup>13</sup>

In the present study, the results shown in Table 2 indicated an increase in the total number of leukocytes in the nickel group (A3) when compared with the nickel-free (A2) and control (A1) groups. An immune response induced by nickel appliances is considered Type IV hypersensitivity.

In this context, nickel binding to endogenous macromolecules can stimulate macrophages and cytotoxic cells, up-regulating the expression of adhesion molecules.<sup>14-16</sup> The differential quantification of leukocytes in the current research shows that the difference in the total number of leukocytes was caused by an increase in the number of monocytes. It has been reported that low-dose exposure to nickel can alter the metabolism of human monocytes.<sup>17</sup> Additionally, nickel induces T lymphocytes to produce several cytokines, including interferon IF- $\gamma$  and interleukin IL-2, IL-5, and IL-10, and stimulates cellular proliferation.<sup>18</sup> The A group rats were killed after only 14 days of implantation. The monocytes are cells which originate macrophages and both form the first line of defense in the organism. Circulating monocytes represent cells that have not fully differentiated. Further evolution occurs at various tissue sites where the monocytes have deposited. These cells play pivotal roles in both humoral and cell-mediated immune reactions to pathogens.<sup>19</sup> It has been stated that antigens associated with macrophages are greater sensitizers than free antigens. In addition, it is necessary that the antigen is linked to macrophages





**Figure 1.** (A) Microphotography showing chronic inflammation with macrophages, lymphocytes, and plasma cells (H&E,  $\times 200$ ). (B) Microphotography showing macrophages, lymphocytes, and plasma cells (H&E,  $\times 200$ ). (C). Microphotography showing few chronic inflammatory cells (H&E,  $\times 100$ ). (D) Microphotography showing fibroblasts, some blood vessels, and few inflammatory cells (H&E,  $\times 200$ ).

before the action of the lymphocytes B and T can occur.<sup>20</sup>

The nickel-free group (A2) did not present significant differences when compared to the control group (A1) with respect to the blood components evaluated after 14 days of implantation. This fact suggests that a decrease in the amount of nickel in the orthodontic alloys may reduce immune reactions.<sup>21-23</sup>

The results obtained for the groups A3, B, and C showed that the total number of leukocytes did not differ among the groups after removal of the nickel bracket. However, in the differential quantification a decrease was observed in the percentage of neutrophils and an increase in the percentage of lymphocytes as the time following appliance removal increased. It has been reported that dermatitis usually peaks at about 48 hours. It is caused by small

amounts of antigen, and it is characterized by infiltration with lymphocytes. Typical sensitization can be caused by nickel present in dental appliances. Once the antigen is removed, the reaction disappears in approximately 10 days.<sup>19</sup> However, in the present study the rats were killed after only 2 (B) and 7 (C) days. This fact explains the higher amount of lymphocytes in the C group, followed by B and A3 groups. The decrease in the number of neutrophils after the appliance removal can be justified by the fact that the antigen (nickel) was removed. Neutrophils are most commonly present at the initial inflammatory response. This concerted effort by the wounded cell layers is accompanied by, and might also be partially regulated by, a robust inflammatory response. This inflammatory response shows neutrophils first and then macrophages with mast cells emigrating from nearby tissues and

from the circulation.<sup>24</sup> As time elapses after the surgical removal of the bracket, the inflammatory response tends to decrease and consequently, so does the number of neutrophils.

Although human beings have been sensitized, the induction of contact allergy in experimental animals is difficult, which implies that nickel is not the potent contact allergen that has been anticipated.<sup>4</sup> In this way, there was no difference in the amount of IgA among groups, suggesting that the nickel in the orthodontic appliances was not enough to create a humoral response using the present methodology.

The release of nickel from alloys or devices is, among other things, related to the surface area, exposure time, and environment; but there seems to be no exact knowledge of the type and duration of oral exposure needed to elicit the induction of tolerance or reaction.<sup>4</sup> The continuous exposure to nickel alloys might lead to oral tolerance mechanisms that modulate nickel sensitivity, as evidenced by the lower cell proliferation index in patients undergoing orthodontic treatment over 24 months. However, further studies are needed to clarify the major cell phenotype associated with the immune response.<sup>6</sup>

The nickel allergy comprises Type IV hypersensitivity reactions which are cell-mediated by T lymphocytes.<sup>25</sup> These cells are an important component of the immune response to many intracellular pathogens and some nondegradable antigens.<sup>25</sup> These reactions are initiated by CD4+ T lymphocytes with the accumulation of macrophages, and other effector cells in response to T cell cytokines.<sup>26</sup> The efficiency of metallic nickel or nickel compound phagocytosis by the macrophages or giant cells depends on the size and surface changes of the nickel particles.<sup>25</sup> These cells are also of central importance in the induction of antigen-specific T lymphocyte activation.<sup>25</sup> Microscopically, in this study there were no differences between the inflammatory cells found in the groups with brackets that contained or did not contain nickel. At 14 days after bracket implantation, the presence of neutrophils, macrophages, and lymphocytes, and many blood vessels was observed. After this period, the inflammatory cells were gradually changed by fibroblasts and connective tissue. Probably, the presence of inflammatory cells in the wound is related to insertion and removal procedures.

Authors have reported that the concentration of nickel liberated from orthodontic apparatus does not reach cytotoxic levels,<sup>27</sup> and its concentration in serum and saliva from patients who wear fixed orthodontic appliances is similar to those found in healthy individuals.<sup>8</sup> It can be suggested that the nickel in the orthodontic appliances was not enough to create a humoral response using the present methodology. Nickel has

a long-standing history of successful use in dentistry, and there are no significant reports of biological effects attributed to nickel-containing dental appliances and restorations.<sup>25</sup>

## CONCLUSIONS

- The total number of leukocytes increased when nickel apparatuses were subcutaneously implanted in rats.
- The difference in the total number of leukocytes was caused by an increase in the number of monocytes, which is characterized by hypersensitivity Type IV. There was no difference in the levels of IgA among the groups.
- The total number of leukocytes did not differ among the groups after removal of the nickel bracket. In the differential quantification, an increase was observed in the percentage of lymphocytes, and a decrease was observed in the percentage of neutrophils as the time following appliance removal increased. The histopathologic findings did not show differences between the groups.

## ACKNOWLEDGMENT

We wish to thank Mr Ademir Felício Alves (UNILAVRAS) for technical assistance.

## REFERENCES

1. Roitt IM. *Imunologia*. 5th ed. São Paulo, SP: Atheneu; 2000: 1–294.
2. Schubert H, Berova N, Czernielewski A, et al. Epidemiology of nickel allergy. *Contact Dermatitis*. 1987;16(3):122–128.
3. Nielsen NH, Menné T. Nickel sensitization and ear piercing in an unselected Danish population. Glostrup Allergy Study. *Contact Dermatitis*. 1993;29(1):16–21.
4. Kerosuo H, Kullaa A, Kerosuo E, Kanerva L, Hensten-Petersen A. Nickel allergy in adolescents in relation to orthodontic treatment and piercing of ears. *Am J Orthod Dentofacial Orthop*. 1996;109(2):148–154.
5. Dunlap CL, Vincent SK, Barker BF. Allergic reaction to orthodontic wire: report of case. *J Am Dent Assoc*. 1989; 118(4):449–450.
6. Marigo M, Nouer DF, Genelhu MC, Malaquias LC, Pizzio VR, Costa AS, Martins-Filho OA, Alves-Oliveira LF. Evaluation of immunologic profile in patients with nickel sensitivity due to use of fixed orthodontic appliances. *Am J Orthod Dentofacial Orthop*. 2003;124(1):46–52.
7. Stejskal VD, Hudecek R, Stejskal J, Sterzl I. Diagnosis and treatment of metal-induced side-effects. *Neuro Endocrinol Lett*. 2006; Dec 29:27(suppl1).
8. Agaoglu G, Arun T, Izgi B, Yarat A, Izgu B. Nickel and chromium levels in the saliva and serum of patients with fixed orthodontic appliances. *Angle Orthod*. 2001;71(5):375–379.
9. Athanasiou AE, Pafliotelis J. Allergic reactions to orthodontic materials and a protocol for the management of patients [in Greek]. *Orthod Epitheorese*. 1989;1(2):37–42.
10. Carvalho MG, Silva MBS. *Hematology: Laboratory Techniques and Interpretation* [in Portuguese]. Belo Horizonte, MG: UFMG Editors; 1988:1–139.

11. Janson GR, Dainese EA, Consolaro A, Woodside DG, Freitas MR. Nickel hypersensitivity reaction before, during and after orthodontic therapy. *Am J Orthod Dentofacial Orthop.* 1998;113(6):655–660.
12. Asgharnia MK, Brantley WA. Comparison of bending and tension tests for orthodontic wires. *Am J Orthod.* 1986; 89(3):228–236.
13. Janson GR, Dainese EA, Pereira ACJ, Pinzan A. Clinical evaluation of nickel hypersensitivity reaction in patients under orthodontic treatment. *Ortodontia.* 1994;27:31–37.
14. Wataha JC, Hanks CT, Sun Z. Effect of cell line on in vitro metal ion cytotoxicity. *Dent Mater.* 1994;10(3):156–161.
15. Wataha IC, Sun ZL, Hanks CT, Fang DN. Effect of Ni ions on expression of intercellular adhesion molecule 1 by endothelial cells. *J Biomed Mater Res.* 1997;36(2):145–151.
16. Wataha JC, Lockwood PE, Marek M, Ghazi M. Ability of Ni-containing biomedical alloys to activate monocytes and endothelial cells in vitro. *J Biomed Mater Res.* 1999;45(3): 251–257.
17. Wataha JC, Lockwood PE, Schedle A, Noda M, Bouillaguet S. Ag, Cu, Hg and Ni ions alter the metabolism of human monocytes during extended low-dose exposures. *J Oral Rehabil.* 2002;29(2):133–139.
18. Fernandez-Botran R, Sanders VM, Mosmann TR, Vitetta ES. Lymphokine-mediated regulation of the proliferative response of clones of T helper 1 and T helper 2 cells. *J Exp Med.* 1988;168(2):543–558.
19. Slots J, Taubman MA, Yankell S. *Contemporary Oral Microbiology and Immunology.* St. Louis, MO: Mosby-Year Book; 1992.
20. Silva WD, Mota I. *Basic and Applied Immunology.* 5th ed. Rio de Janeiro, RJ: Guanabara Koogan; 2003:1–388.
21. Staerkjaer L, Menne T. Nickel allergy and orthodontic treatment. *Eur J Orthod.* 1990;12(3):284–289.
22. Kitaura H, Nakao N, Yoshida N, Yamada T. Induced sensitization to nickel in guinea pigs immunized with mycobacteria by injection of purified protein derivative with nickel. *New Microbiol.* 2003;26(1):101–108.
23. Rahilly G, Price N. Nickel allergy and orthodontics. *J Orthod.* 2003;30(2):171–174.
24. Martin P, Leibovich SJ. Inflammatory cells during wound repair: the good, the bad and the ugly. *Trends Cell Biol.* 2005; 15(11):599–607.
25. Setcos JC, Babaei-Mahani A, Silvio LD, Mjör IA, Wilson NH. The safety of nickel containing dental alloys. *Dent Mater.* 2006;22(12):1163–1168.
26. Hogan LH, Weinstock JV, Sandor M. TCR specificity in infection induced granulomas. *Immunol Lett.* 1999;68(1):115–120.
27. Grimsdottir MR, Hensten-Pettersen A, Kullmann A. Cytotoxic effect of orthodontic appliances. *Eur J Orthod.* 1992; 14(1):47–53.