

Soft Tissue Profile in White Brazilian Adults with Normal Occlusions and Well-Balanced Faces

Helio Scavone Jr^a; Wesley Zahn-Silva^b; Karyna Martins do Valle-Corotti^a;
Ana Carla Raphaelli Nahás^a

ABSTRACT

Objective: To analyze anteroposterior soft tissue facial parameters for a sample of white Brazilian adults and to compare these measurements with the values proposed for white North American adults.

Materials and Methods: Facial profile photographs were taken of 59 white Brazilians (30 men and 29 women) with normal occlusions and balanced faces with ages ranging from 18 to 30 years. The independent Student's *t*-test ($P < .05$) was used to compare the soft tissue parameters of the Brazilians with those of the North Americans.

Results: White Brazilian women presented a less protruded face compared with white American women except for the glabella region. White Brazilian women showed a smaller nasal projection, less protruded upper and lower lips, a more obtuse nasolabial angle, and a smaller projection of the B' point and chin than white American women. Conversely, the two male groups demonstrated less evident soft tissue profile differences, with the exception of the nose projection, which was smaller in white Brazilian men than in white American men.

Conclusions: A universal standard of facial esthetic is not applicable to diverse white populations. Differences regarding the soft tissue profile features were found between white Brazilians and white Americans. These differences should be considered in the orthodontic/orthognathic surgery diagnosis and treatment plan for white Brazilians together with the patient's individual opinion and perception of beauty.

KEY WORDS: Photographs; Facial profile; Normal occlusion

INTRODUCTION

Although numerous previous attempts were made to identify an esthetic facial ideal, contemporary orthodontics recognizes the ethnic and personal diversity of human facial contours. A large number of studies demonstrated the presence of specific dentofacial characteristics in each ethnic group, leading professionals to consider these differences in orthodontic and surgical diagnosis and treatment planning. Remarkable differences have been identified in both skeletal fea-

tures and soft tissue profile between white Americans/Europeans and African-Americans,¹⁻³ Koreans,⁴ Japanese,⁵⁻¹² and Chinese.¹³ Facial differences between white populations of distinct continents or countries have been reported previously also.¹⁴⁻²¹

Among the several numeric facial analyses currently employed, the analysis proposed by Arnett et al²² has been used broadly by orthodontists and maxillofacial surgeons. However, the measurements proposed for these analyses were achieved based on a white American sample and may not be applicable as a reference for diagnosis and treatment of other ethnic groups. White Americans descend mostly from English, Polish, Dutch, and French populations. Scottish, Spanish, and Scandinavian populations are also part of the immigration history of North America. On the other hand, white Brazilians come from the Mediterranean countries, primarily Portugal, Italy, and Spain. Considering these background differences, the facial standards for white Brazilians might be distinct from the norms of white Americans. Scavone et al²³ also demonstrated

^a Associate Professor, Department of Orthodontics, University of São Paulo City, São Paulo, Brazil.

^b Graduate student (MS), Department of Orthodontics, University of São Paulo City, São Paulo, Brazil.

Corresponding author: Dr Helio Scavone Jr, Department of Orthodontics, University of São Paulo City, R Cesário Galero, 432/448, São Paulo, SP, 03071-000, Brazil (e-mail: helioorto@uol.com.br)

Accepted: February 2007. Submitted: October 2006.

© 2007 by The EH Angle Education and Research Foundation, Inc.

significant differences between Japanese Brazilians and white Americans, as measured by the seven soft tissue facial profile normative values proposed by Arnett et al.²² The results of this recent study emphasize the importance of determining reference values specific for each ethnic group.

Therefore, the goals of this study were to establish, on the basis of facial profile photographs, some reference values for seven anteroposterior soft tissue variables in a sample of white Brazilian adults with normal occlusions and well-balanced faces, and also to compare these values with those proposed by Arnett et al.²²

MATERIALS AND METHODS

The sample included 59 white Brazilian adults (30 men and 29 women) prospectively selected by two Brazilian orthodontists on the basis of the following criteria: age from 18 to 30 years; presenting clinically normal occlusions²⁴ (accepting minor crowding); showing orthognathic profiles, closed lip posture (lip sealing), and facial symmetry; no previous orthodontic treatment; no history of trauma or plastic or orthognathic surgery.

Standardized facial profile photographs were taken with the patient in the natural head position (NHP),²⁵⁻²⁹ centric relation, and relaxed lip posture.²⁹ All photographs were taken with a Yashica Dental Eye III camera mounted on a tripod, leveled with the optical axis of the lens horizontal and the film plane vertical. The subjects were positioned standing at 1.7 meters from the camera in a mechanical device used to provide both a vertical reference line perpendicular to the floor plane (true vertical line) and a real metric scale during image measurement.

Photographs were digitized with a Microsoft computer (Microsoft Corporation) that used Deskscan II version 2.9 software and a Hewlett Packard Scanjet 4C image scanner (Hewlett-Packard Development Company) with 300 DPI resolution. Images were transferred to the Radiocef 2000 software (Radio Memory, Belo Horizonte, Brazil) where landmark identification (Figure 1) was performed by a single calibrated investigator, and soft tissue profile variables (Figure 2) were measured. The true vertical line (TVL) was originally represented by the metric scale perpendicular to the floor. Later, it was transferred directly over the computerized image of the soft tissue facial profile, passing through subnasale (Sn). The image/actual size ratio was calculated by means of the same software, having the metric scale image as a reference parameter.

The mean and standard deviation of each variable were determined for male and female subgroups. In-

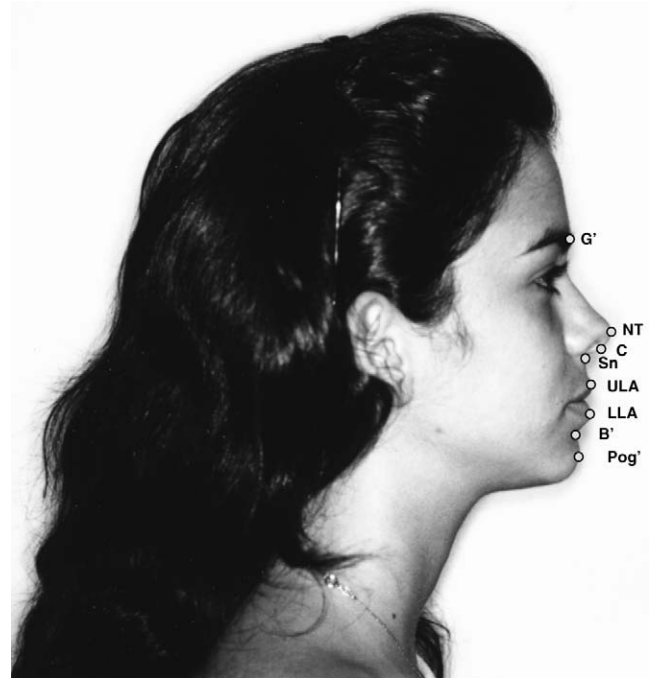


Figure 1. Soft tissue points used in the facial profile evaluation: glabella (G'), nasal tip (NT), columnella (C), subnasale (Sn), upper lip anterior (ULA), lower lip anterior (LLA), soft tissue B point (B'), and soft tissue pogonion (Pog').

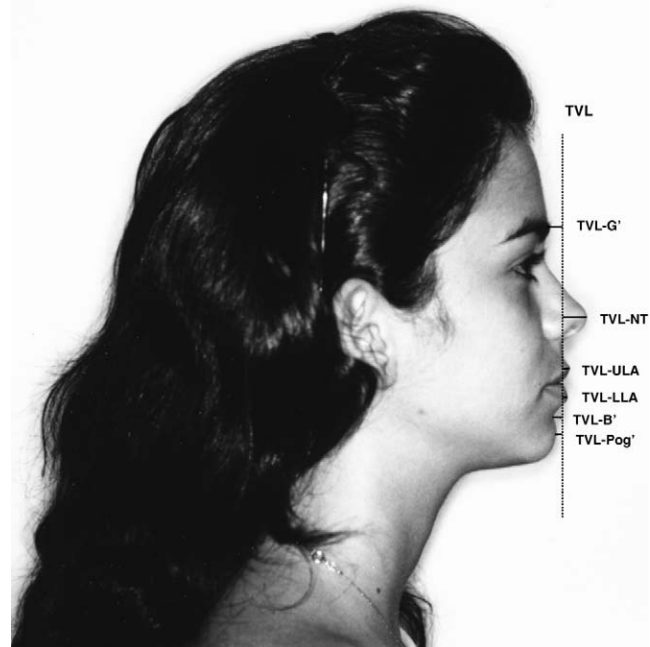


Figure 2. Linear measurements (true vertical line [TVL] projections). TVL-G': horizontal distance from TVL to glabella point; TVL-NT: horizontal distance from TVL to nasal tip point; TVL-ULA: horizontal distance from TVL to upper lip anterior point; TVL-LLA: horizontal distance from TVL to lower lip anterior point; TVL-B': horizontal distance from TVL to soft tissue B point; TVL-Pog': horizontal distance from TVL to soft tissue pogonion point. The TVL is perpendicular to the floor plane and passes through the subnasale point (Sn).

dependent *t*-tests were used to compare male-female differences and to compare the white Brazilian sample values with those originally proposed by Arnett et al²² for a white American sample. Results were regarded as significant for $P < .05$.

In order to assess the method error, 20 photographs of the sample were randomly selected and measured again 45 days after the first evaluation. Casual and systematic errors were calculated comparing the first and second measurements with Dahlberg's formula³⁰ and dependent *t*-test, respectively, at a significance level of 0.05.

A method was also developed to assess eventual distortions in the photographic images and the corresponding measurements. With this purpose, millimetric scales were fixed horizontally and vertically in the mechanical device utilized to provide the reference vertical line (true vertical line). Subsequently, 10 photographs were taken of these millimetric scales, their images transferred to Radiocef 2000 software and 12 segments of 100 mm were measured with this software. The measurements obtained by the computerized method, based on the photographic images of the millimetric scales, were compared to the real known size of the segments, ie, 100 mm. The differences between the computerized measurements and the actual size measured defined the distortions of the photographic images in the 12 regions evaluated in the photographic area, horizontally and vertically.

RESULTS

None of the variables had statistically significant systematic errors. The causal errors ranged from 0.52 (TVL-LLA) to 0.58 (TLV-B'), with the exception of NLA, which showed a more considerable error of 4.04.

The image/actual size ratio of the photographs corresponded to 1:2.8. Linear measurements were converted and are presented as the actual dimensions. The distortions of the photographic measurements were extremely reduced and never exceeded 0.76% in any of the directions evaluated.

Sexual Dimorphism

Table 1 presents the mean and standard deviation of measurements for the male and female white Brazilian samples. The soft tissue profile variables that showed significant sexual dimorphism were TLV-NT and TLV-ULA. The male subjects had a slightly greater nasal projection (mean difference: 1.4 mm) and larger upper lip protrusion (mean difference: 1 mm) compared with the female subjects.

Table 1. Comparison of White-Brazilian Facial Profile Variables Between Female and Male Subjects (*t*-Test)^a

Variables	Female (n = 29)		Male (n = 30)		Significance
	Mean	SD	Mean	SD	
TVL-G'	-5.5	4.3	-7.4	3.8	NS
TVL-NT	13.9	1.6	15.3	2.1	**
TVL-ULA	1.3	1.8	2.3	1.8	*
TVL-LLA	-1.0	2.8	0.0	2.2	NS
TVL-B'	-7.8	4.1	-7.1	3.4	NS
TVL-Pog'	-6.4	5.2	-4.5	5.1	NS
NLA	113.9	10.8	108.9	11.6	NS

^a n indicates number of patients; SD, standard deviation; NS, not significant.

* $P < .05$; ** $P < .01$; *** $P < .001$.

Table 2. Female Comparisons Between White-Brazilian (n = 29) and White-American (n = 26) Samples (*t*-Test)^a

Variables	White-Brazilian		White-American (Arnett et al)		Significance
	Mean	SD	Mean	SD	
TVL-G'	-5.5	4.3	-8.5	2.4	**
TVL-NT	13.9	1.6	16.0	1.4	***
TVL-ULA	1.3	1.8	3.7	1.2	***
TVL-LLA	-1.0	2.8	1.9	1.4	***
TVL-B'	-7.8	4.1	-5.3	1.5	**
TVL-Pog'	-6.4	5.2	-2.6	1.9	***
NLA	113.9	10.8	103.5	6.8	**

^a n indicates number of patients; SD, standard deviation.

* $P < .05$ ** $P < .01$ *** $P < .001$.

White Brazilian/White American Comparisons

All evaluated soft tissue variables showed statistical significant differences between white Brazilian and white American female subjects (Table 2). White Brazilian women presented with the glabella more anteriorly positioned, smaller nasal projection, less protruded upper and lower lips, and a more obtuse nasolabial angle compared with white American women. Additionally, a smaller projection of the B' point and chin, in relation to the true vertical line, was noted in the white Brazilian women.

Among the seven soft tissue variables analyzed, only one demonstrated a significant difference between white Brazilian and white American male subjects (Table 3). The nasal projection (TLV-NT) was smaller in the white Brazilian men compared with the white American men with a mean difference of 2.1 mm. Although no statistically significant differences had been recorded between the two male groups regarding the other variables, white Brazilian men showed a tendency toward a less protruded face in all facial levels analyzed, except for the mentolabial sulcus (Table 3).

Table 3. Male Comparisons Between White-Brazilian (n = 30) and White-American (n = 20) Samples (t-Test)^a

Variables	White-Brazilian		White-American (Arnett et al)		Significance
	Mean	SD	Mean	SD	
TVL-G'	-7.4	3.8	-8.0	2.5	NS
TVL-NT	15.3	2.1	17.4	1.7	***
TVL-UULA	2.3	1.8	3.3	1.7	NS
TVL-LLA	0.0	2.2	1.0	2.2	NS
TVL-B'	-7.1	3.4	-7.1	1.6	NS
TVL-Pog'	-4.5	5.1	-3.5	1.8	NS
NLA	108.9	11.6	106.4	7.7	NS

^a n indicates number of patients; SD, standard deviation; NS, not significant.

* $P < .05$; ** $P < .01$; *** $P < .001$.

DISCUSSION

The present study was designed to establish reference values in a sample of white Brazilian adults for some soft tissue facial profile variables, and also to compare the results with normative values that were proposed by Arnett et al²² for white Americans. It is important to emphasize that the main inclusion criteria were normal occlusion and facial balance, which are not always related to beauty, and perception of which is subjective and depends on cultural trends.

Even though this study conducted a numeric analysis of the facial profile, standardized facial photographs were used instead of cephalometrics, since the Brazilian Ethical Committee does not allow radiographic exposure of patients for the exclusive purpose of investigation. Therefore, in order to compare the values achieved from the white Brazilian sample with those proposed by Arnett et al²² for white Americans, the reduction factor of the photographic image was calculated and the linear measurements were corrected for their actual values.

All photographs were digitized and measured by the same examiner, to eliminate the interexaminer error. Systematic errors of the evaluated variables were not statistically significant. Casual errors for most measurements were reduced and will not be addressed except for the nasolabial angle (mean = 4.04°), for which results should be interpreted with care. The magnitude of the NLA significant error may be assigned to the difficulty in identifying the points involved in this measurement, especially subnasale and columella. Additionally, the proximity between the three points used in the construction of NLA might also contribute to this error. Despite the distortion of the photographic images and the corresponding measurement methods, the method adopted in this research was reliable since the maximum distortion verified never exceeded 0.76%.

Only two soft tissue variables presented statistically

significant sexual dimorphism in the white Brazilian sample. White Brazilian male subjects showed a more prominent nose and a more protruded upper lip. In white American patients, Arnett et al,²² using the true vertical line as a reference, observed that male patients presented a more protruded nose and a less projected B' point than female patients. Considering a different reference line (vertical line passing through porion) in the evaluation of the soft tissue profile, Lundström et al³¹ showed that white male patients had a greater projection of nasion, nose tip, upper and lower lips, point B', and chin compared with white female patients.

The soft tissue profile features of white Brazilian women were quite distinct compared with white American women. All linear variables analyzed were smaller in the white Brazilian women showing that they have a smaller nose and a more retruded lower face than white American women (Table 2). Although a previous study on cephalometric standards for white Brazilians had shown more protruded incisors compared to white Americans,¹⁶ the results of this study pointed to more posteriorly positioned lips in the former. The upper and lower lips of white Brazilian women were respectively 2.4 and 2.9 mm less protruded than the white American women. The nasolabial angle was also more opened in the white Brazilian women confirming the retrusive profile pattern.

White Brazilian women also exhibited a smaller projection of B' point and chin, with a mean difference of 2.5 and 3.8 mm, respectively, in relation to white American women. Differently from the women, white Brazilian men had just a few differences from white American men regarding the soft tissue profile characteristics. White Brazilian men showed a smaller nose and a less protruded upper lip than white American men, with a mean difference of 1.4 and 1.0 mm, respectively (Table 3).

These results are in accordance with other studies that also showed facial profile differences between different white groups. Erbay et al¹⁸ reported that Anatolian Turkish adults had more retrusive upper and lower lips compared with white American norms. Borman et al²¹ found a more convex facial profile and more closed nasolabial angle in Turkish adults than in other populations. Comparing Saudis and white Americans, Hashim and AlBarakati²⁰ showed significant differences in most of the soft tissue variables evaluated. In addition, differences in dentoskeletal cephalometric norms were also found between white Americans and Greeks,¹⁴ white Brazilians,¹⁶ and white Europeans.¹⁹ On the other hand, analyzing some soft tissue profile variables, Lundström et al³⁰ did not find differences between Swedish subjects and white Americans.

It must be stressed that many of the soft tissue profile differences found between the Brazilian and the

American samples may not be attributable only to ethnic differences, but also to examiners' individual perceptions of facial balance. Although the Brazilian sample comprised adults with normal occlusions and balanced faces, this does not necessarily mean a high standard of facial beauty. In fact, probably it would be better to say that this sample included men and women with satisfactory facial balance. Similarly, the American sample²² was selected according to the personal judgment of just one of the authors. Of course, the American sample does not represent the average soft tissue facial profile of white Americans. In the same way, the selection of the Brazilian sample was also influenced by individual perceptions of the examiners. However, the purpose of this investigation was not to establish standards of beauty, but instead to provide some reference values that can be helpful for soft tissue facial profile evaluation.

In general, Brazilians exhibited a large variability of the soft tissue profile features, as shown by the high values of the standard deviation of the variables analyzed (Tables 2 and 3). This means that there is considerable diversity of the facial profile in patients with normal occlusions and well-balanced faces, and this point should be taken into account. In addition, it is also important to highlight that the results could have been different, especially regarding lip protrusion, if the sample had been selected on the basis of facial beauty by the public. Peck and Peck³² showed that the general public admires a more protrusive dentofacial pattern in relation to the cephalometric standards dictated. Auger and Turley³³ and Nguyen and Turley³⁴ concluded that there was a linear trend toward fuller and more anteriorly positioned lips in fashion magazines during the last century.

CONCLUSIONS

- Differences regarding the soft tissue profile features exist between white Brazilians and white Americans.
- A universal standard of facial profile esthetic is not applicable to diverse white populations.

REFERENCES

1. Huang WJ, Taylor RW, Dasanayake AP. Determining cephalometric norms for Caucasians and African Americans in Birmingham. *Angle Orthod.* 1998;68(6):503–512.
2. Sushner NI. A photographic study of the soft-tissue profile of the Negro population. *Am J Orthod.* 1977;72(4):373–385.
3. Sutter RE Jr, Turley PK. Soft tissue evaluation of contemporary Caucasian and African American female facial profiles. *Angle Orthod.* 1998;68(6):487–496.
4. Hwang HS, Kim WS, McNamara JA Jr. Ethnic differences in the soft tissue profile of Korean American and European-American adults with normal occlusions and well-balanced faces. *Angle Orthod.* 2002;72(1):72–80.
5. Alcalde RE, Jinno T, Pogrel MA, Matsumura T. Cephalometric norms in Japanese adults. *J Oral Maxillofac Surg.* 1998;56(2):129–134.
6. Miyajima K, McNamara JA Jr, Kimura T, Murata S, Iizuka T. Craniofacial structure of Japanese and European-American adults with normal occlusions and well-balanced faces. *Am J Orthod Dentofacial Orthop.* 1996;110(4):431–438.
7. Miura F, Inoue N, Suzuki K. Cephalometric standards for Japanese according to the Steiner analysis. *Am J Orthod.* 1965;51:288–295.
8. Takahashi R, Pinzan A, Henriques JF, Freitas MR, Almeida RR, Janson G. FOB-USP Cephalometric standards for Japanese-Brazilian youths with normal occlusion. *R Dental Press Orthodon Orthop Facial.* 2001;6(2):13–24.
9. Engel G, Spolter BM. Cephalometric and visual norms for a Japanese population. *Am J Orthod.* 1981;80(1):48–60.
10. Cotton WN, Takano WS, Wong WM. The Downs analysis applied to three other ethnic groups. *Angle Orthod.* 1951;21(4):213–220.
11. Iwasawa T, Moro T, Nakamura K. Tweed triangle and soft-tissue consideration of Japanese with normal occlusion and good facial profile. *Am J Orthod.* 1977;72(2):119–127.
12. Reitz PV, Aoki H, Yoshioka M, Uehara J, Kubota Y. A cephalometric study of tooth position as related to facial structure in profiles of human beings: a comparison of Japanese (Oriental) and American (Caucasian) adults. *J Prosthet Dent.* 1973;29(21):157–166.
13. Cooke MS, Wei SH. A comparative study of southern Chinese and British Caucasian cephalometric standards. *Angle Orthod.* 1989;59(2):131–138.
14. Argyropoulos E, Sassouni V. Comparison of the dentofacial patterns for native Greek and American-Caucasian adolescents. *Am J Orthod Dentofacial Orthop.* 1989;95(3):238–249.
15. Basciftci FA, Uysal T, Buyukerkmen A. Craniofacial structure of Anatolian Turkish adults with normal occlusions and well-balanced faces. *Am J Orthod Dentofacial Orthop.* 2004;125(3):366–372.
16. Cerci V, Martins JE, Oliveira MA. Cephalometric standards for white Brazilians. *Int J Adult Orthodon Orthognath Surg.* 1993;8(4):287–292.
17. Erbay EF, Caniklioglu CM. Soft tissue profile in Anatolian Turkish adults: Part II. Comparison of different soft tissue analyses in the evaluation of beauty. *Am J Orthod Dentofacial Orthop.* 2002;121(1):65–72.
18. Erbay EF, Caniklioglu CM, Erbay SK. Soft tissue profile in Anatolian Turkish adults: part I. Evaluation of horizontal lip position using different soft tissue analyses. *Am J Orthod Dentofacial Orthop.* 2002;121(1):57–64.
19. Franchi L, Bacetti T, McNamara JA Jr. Cephalometric floating norms for North American adults. *Angle Orthod.* 1998;68(6):497–502.
20. Hashim HA, AlBarakati SF. Cephalometric soft tissue profile analysis between two different ethnic groups: a comparative study. *J Contemp Dent Pract.* 2003;4(2):60–73.
21. Borman H, Özgür F, Gürsu G. Evaluation of soft-tissue morphology of the face in 1,050 young adults. *Ann Plast Surg.* 1999;42(3):280–288.
22. Arnett GW, Jelic JS, Kim J, Cummings DR, Beress A, Worley CM Jr, Chung B, Bergman R. Soft tissue cephalometric analysis: diagnosis and treatment planning of dentofacial deformity. *Am J Orthod Dentofacial Orthop.* 1999;116(3):239–253.
23. Scavone H Jr, Trevisan H Jr, Garib DG, Ferreira VF. Facial profile evaluation in Japanese-Brazilian adults with normal occlusions and well-balanced faces. *Am J Orthod Dentofacial Orthop.* 2006;129:721. e1–e5.

24. Angle EH. Malocclusion. In: Angle EH, ed. *Treatment of Malocclusion of the Teeth*. 7th ed. Philadelphia, Pa: SS White Dental Manufacturing Company; 1907:28–59.
25. Lundström F, Lundström A. Natural head position as a basis for cephalometric analysis. *Am J Orthod Dentofacial Orthop*. 1992;101(3):244–247.
26. Moorrees CFA, Kean MR. Natural head position, a basic consideration in the interpretation of cephalometric radiographs. *Am J Phys Anthropol*. 1958;16:213–234.
27. Moorrees CF. Natural head position—a revival. *Am J Orthod Dentofacial Orthop*. 1994;105(5):512–513.
28. Viazis AD. A cephalometric analysis based on natural head position. *J Clin Orthod*. 1991;3:172–181.
29. Arnett GW, Bergman RT. Facial keys to orthodontic diagnosis and treatment planning. Part I. *Am J Orthod Dentofacial Orthop*. 1993;103(4):299–312.
30. Dahlberg G. *Statistical Methods for Medical and Biological Students*. New York, NY: Interscience; 1940:122–132.
31. Lundström A, Forsberg CM, Peck S, McWilliam J. A proportional analysis of the soft tissue facial profile in young adults with normal occlusion. *Angle Orthod*. 1992;62(2):127–133.
32. Peck H, Peck S. A concept of facial esthetics. *Angle Orthod*. 1970;40(4):284–318.
33. Auger T, Turley P. The female soft tissue profile as presented in fashion magazines during the 1900s: a photographic analysis. *Int J Adult Orthodon Orthognath Surg*. 1999;14(1):7–18.
34. Nguyen D, Turley P. Changes in the Caucasian male facial profile as depicted in fashion magazines during the twentieth century. *Am J Orthod Dentofacial Orthop*. 1998;114(2):208–217.